

BLOOD VESSELS OF THE GENITALIA

AND ACCESSORY GENITAL ORGANS

OF SWINE

(SUS SCROFA DOMESTICUS)

by

Quiterio Nunez

A Thesis Submitted to the

Graduate Faculty in Partial Fulfillment of

The Requirements for the Degree of

MASTER OF SCIENCE

Major Subject: Veterinary Anatomy

Signatures have been redacted for privacy

U

Iowa State University
Of Science and Technology
Ames, Iowa

1964

1492663

SF767
59
N9226
o.2

INTRODUCTION
REVIEW OF LITERATURE
MATERIALS AND METHODS
RESULTS
DISCUSSION
SUMMARY AND CONCLUSIONS
BIBLIOGRAPHY
ACKNOWLEDGMENT
TABLES
ILLUSTRATIONS

TABLE OF CONTENTS

	Page
INTRODUCTION	1
REVIEW OF LITERATURE	2
MATERIALS AND METHODS	23
RESULTS	27
DISCUSSION	79
SUMMARY AND CONCLUSIONS	110
BIBLIOGRAPHY	118
ACKNOWLEDGMENT	123
TABLES	125a
ILLUSTRATIONS	130a

INTRODUCTION

There has been an increased interest in swine as an experimental animal in recent years. In addition, the clinical and surgical procedures performed on them demand a detailed understanding of their anatomy. A review of the literature reveals that there has been relatively little detailed descriptive anatomy of the blood vessels of swine except the summary and excellent work of Sieber (1903). Anatomical veterinary texts describe the vascular system of the swine in a comparative manner to that of other species particularly the bovine.

Because of increasing interest and research in reproductive problems in swine, it was felt that a detailed study of the blood supply to, and the venous drainage of the male and female genitalia should contribute to a better understanding of these problems related to reproductive anatomy and physiology.

REVIEW OF LITERATURE

Arteries

A study of the literature pertaining to the blood vessels to the genitalia and accessory genital organs in the domestic animals, including the swine (*Sus scrofa domesticus*), reveals that a variety of terms are being used to describe them.

According to Montané (1920) the thoracic arteries, A. thoracica interna and A. thoracica externa, arise from the brachial trunk at the level of the first rib. He states that the A. thoracica interna supplies the cranial mammary glands through its terminal branch, the anterior abdominal artery (A. epigastrica cranialis).

Mannu (1930) states that the Aa. intercostales supply the mammary glands. He does not specify the origin of the above mentioned arteries or the name of the pair of mammary glands which they supply. Sisson and Grossman (1953) report briefly that the thoracic arteries gave off branches to the pectoral mammary glands. They also indicate that the A. thoracica externa may sometimes be absent.

Dobberstein and Koch (1958) state that the A. thoracica interna of the swine resembles that of the horse. Kähler (1960)

describes the A. thoracica interna as arising from the A. subclavia (A. brachialis) medial to the caudal border of the first rib. He describes the vessel as giving off Rami intercostales and Rami sternales and finally ending as the A. epigastrica cranialis and A. musculophrenica, medial to the 6th rib. According to him, the first thoracic pair of mammary glands are supplied entirely by the A. thoracica externa and the A. thoracica interna. The A. epigastrica cranialis supplies, in part, the first two abdominal mammary complexes.

It is generally accepted that the A. profunda femoris contributes the blood supply to the genital tract through the pudendoepigastric trunk. There is agreement in the literature that the A. profunda femoris gives off the trunk before leaving the abdominal cavity. Similarly, the pudendoepigastric trunk gives off the A. pudenda externa, the A. epigastrica caudalis and the A. spermatica externa within the abdominal cavity. The A. spermatica externa, according to Ellenberger and Baum (1943), Martin (1923), and Mannu (1930), is very small in the castrated male animal and is absent in the female. Martin states that the counterpart of this artery is the A. uterina media in the female.

They add that the pudendoepigastric trunk is sometimes

absent. Therefore, the A. spermatica externa arises from the A. profunda femoris separately. Getty (1955) agrees with the preceding statement. Variations as to the origin of the A. pudenda externa have been reported. Ellenberger and Baum (1943) and Martin (1923) state that the A. pudenda externa almost always comes from the A. circumflexa ilium profunda.

Sisson and Grossman (1953) concur with the above mentioned authors in that the vessel supplies only the prepuce in the male.

Kähler (1960), in agreement with Bickhardt (1961), states that the A. pudenda externa ultimately divides into three cranial branches and one caudal branch. They designate these branches as the lateral cranial branch, middle cranial branch, and medial cranial branch. They are not in agreement, however, as to the distribution of the medial and the middle cranial branch in the male. Kähler states that the middle cranial branch supplies the prepuce, whereas Bickhardt describes the medial cranial branch as directed to the prepuce. There is no controversy regarding the same in the female. The three cranial branches supply the mammary glands corresponding to the abdominal and the inguinal mammary glands.

According to Sieber (1903) and Mannu (1930), the A. spermatica interna, in the male pig, arises from the ventral wall of the Aorta abdominis, 2 to 3 cm before the A. mesenterica

caudalis. Chauveau (1889), Martin (1923), Ellenberger and Baum (1943), and Sisson and Grossman (1953) agree that the course of the A. spermatica interna in the swine is similar to that in the horse. Montané (1920) refers to this vessel as the "great testicular artery" and states that it is remarkable by numerous convolutions which it describes in the spermatic cord.

Harrison (1949) uses the term "testicular artery" and writes that this vessel, in the spermatic cord, forms irregular convolutions.

Beutler (1926) states that in the swine the tortuous aspect of the vessel is more compact than in the horse, bull, ram, cat or dog. He points out that the A. spermatica interna in the swine, bull and horse becomes the A. testicularis as soon as it leaves the arterial cone.

Hofmann (1960) uses the term Aa. testiculares in the bull to describe the largest branches of the A. spermatica interna which lie deeply embedded within the tunica albuginea.

Hill (1905) designates the Aa. testiculares in the pig as the "capsular arteries" and states that they give off tortuous rib-like branches, which approach the mediastinum testis in a perpendicular direction. He specifies this portion as the "descending perpendicular artery".

Beutler (1926) agrees that the disposition of the Aa. testiculares inside the testicle resembles that in the bull.

Hofmann (1960) uses, in the bull, the term Aa. radiatae testes for the vessels which emerge from the Aa. testiculares. He also designates the coiled portion of the Aa. radiatae testes as the Aa. centripedales and Aa. centrifugales.

Magilton (1964) adopts the same terminology to describe the Aa. testiculares in the goat.

According to Sieber (1903) and Ellenberger and Baum (1943) the A. spermatica interna, in the sow, supplies the ovary, bursa ovarica and uterine horn. They state that the vessel courses in the mesovarium and divides into the Ramus ovaricus and Ramus uterinus.

Lange (1959) agrees with Montané (1920) in using the term A. ovarica in the female for the homologous vessel of the A. spermatica interna; however, Montané states that the A. ovarica almost exclusively supplies the ovary, while Lange points out that the vessel divides into the Ramus ovaricus and Rami uterini. Lange reports also that the latter are variable in number and anastomose with the A. uterina media.

Mannu (1930), Sisson and Grossman (1953), and Barone, et al. (1962) use the term A. utero-ovarica in the female for the corresponding vessel, the A. spermatica interna, in the male. They

agree that the A. utero-ovarica divides into ovarian and uterine branches. They do not agree, however, on the nomenclature of the terminal branches of the parent vessel. Mannu designates these as ovarian and uterine branches. According to him the ovarian branch becomes plexiform before reaching the ovary, while the uterine branch forms an arch near the uterine horn. Sisson and Grossman employ the terms A. ovarica and A. uterina cranialis. They state that the latter supplies the uterine horn. Barone, et al. mention that the A. utero-ovarica divides into the A. ovarica and A. tubouterina. He states, from a comparative viewpoint, that the A. ovarica gives off branches to the uterine tube which could correspond to the A. tubarica anterior of the other species. He adds further that the A. tubouterina, after a tortuous course into the mesosalpinx, forms an arterial plexus in which it is possible to trace two arterial trunks, namely, the A. tubarica and the "anterior artery of the uterine horn".

Dobberstein and Koch (1958) agree with Mechaelov (1963) in applying the term A. uterina cranialis in the sow. However, they are in disagreement on the disposition of the vessel. Dobberstein and Koch state that the A. uterina cranialis divides into the Ramus ovaricus and Ramus uterinus, while Mechaelov, on the other hand, considers the terminal branches

of the A. uterina cranialis as collateral branches of it. He describes, and also illustrates, the vessel as giving off the Ramus ovaricus and branches to the uterine tube and uterine horn. Regarding the termination of same, he points out that it ramifies in the thick wall of the uterine horn and finally anastomoses with the A. uterina media.

As referred to above, it is evident that the A. spermatica interna (Sieber, 1903 and Ellenberger and Baum, 1943), the A. utero-ovarica (Manu, 1930; Sisson and Grossman, 1953; and Barone, et al., 1962), the A. ovarica (Montané, 1920 and Lange, 1959), or the A. uterina cranialis (Dobberstein and Koch, 1958 and Mechaelov, 1963) arises as a collateral branch of the Aorta abdominis, usually before the A. mesenterica caudalis. It courses in the anterior border of the broad ligament of the uterus (mesometrium), giving off the Ramus uretericus and finally divides into the Ramus ovaricus (A. ovarica) and Ramus uterinus (Rami uterini of Lange and A. tubovarica of Barone).

There is disagreement regarding the origin of the A. umbilicalis in the pig. The nomenclature applied to its branches supplying the genital tract of the pig is variable, as in the other domestic animals. According to Chauveau (1889), the A. umbilicalis, in the pig, is given off by the A. iliaca interna close to its origin. Sieber (1903) states that

this vessel arises 5 mm to 1 cm from the origin of the *A. iliaca interna*. He says that the *A. umbilicalis* supplies the ductus deferens in the male and corresponds to the *A. uterina media* of the female.

Ellenberger and Baum (1943) agree with Sieber's assertion and have reproduced the illustrations of Sieber's work in their textbook.

Martin (1923) describes the *A. umbilicalis* as a collateral branch of the *A. iliaca interna*. They say that the *A. uterina media* arises from the *A. umbilicalis* and is directed to the uterine horn. They specify it as the *A. spermatica externa* in the male.

Mannu (1930) and Dobberstein and Koch (1958) agree that the *A. umbilicalis* of the swine resembles that of the bovine. They are in agreement on the terminology of *A. deferentialis* and *A. uterina media* for the corresponding vessels in the male and female, respectively.

Sisson and Grossman (1953) agree with the statement that the vessel resembles that of the bovine and they adopt the same terminology in common with the preceding authors (Mannu, and Ellenberger and Baum), however, they are in disagreement about the origin of the vessels. They report that the *A. umbilicalis* in the ox arises as a common trunk with the

A. uterina media from the A. iliaca interna. They add that the former gives off the A. deferentialis and the A. ureterica, and the A. uterina media which supplies mainly the uterus.

Barone, et al. (1962) agree with Montané (1920) in using the term A. uterina for the vessel which supplies the uterus in the female. They state that this vessel arises from the A. iliaca interna by a common trunk with the A. umbilicalis. For the male, Montané uses the term "small testicular artery" for the corresponding vessel of the female. He notes that it arises from the A. iliaca interna.

Lange (1959) and Preuss (1959) agree in using the term A. uterina for the main vessel of the uterus. They also agree that it arises as a collateral branch of the A. umbilicalis.

The A. deferentialis has not been described in detail in the swine. Sieber (1903) states that the vessel runs, being embedded in the plica deferentialis, to the inguinal canal. He does not describe the inguinal course because the animals which were used in his study were castrated. Montané (1920) states that the A. deferentialis can be called the "small testicular artery".

Apart from the above descriptions of the A. deferentialis in the swine, most authors agree that the course and distribution of the vessel resemble that in the bovine.

According to Sieber (1903), the A. deferentialis in the bovine arises from the cranial wall of the A. umbilicalis next to the A. ureterica. He states that the vessel supplies the ductus deferens and gives off small twigs to the epididymis, forming anastomoses with the branches of the A. spermatica interna.

Dobberstein and Koch (1958) refer to it as a slender vessel. Sisson and Grossman (1953) agree with Ellenberger and Baum (1943) that the A. deferentialis accompanies the ductus deferens along its course.

Magilton (1964) states that the A. deferentialis, in two specimens, does not extend to the tail of the epididymis in the goat.

Tanudimadja (1963) describes the A. deferentialis as giving off twigs to the epididymis in the ram.

It is generally accepted that the A. uterina media in the female is the homologous vessel of the A. deferentialis in the male. It is agreed that the A. uterina media is a strong vessel which becomes larger during pregnancy. It is also recognized that it courses in the broad ligament of the uterus toward the uterine horn. According to Sieber (1903), the vessel divides into many branches, similar to the arteries of the intestines. They form arches from which slender branches,

Ramuli uterini, extend towards the wall of the uterine horn. He adds that the vessel anastomoses with the A. spermatica interna (A. utero-ovarica) and A. uterina caudalis.

Montané (1920) agrees with the preceding statement, however, he indicates that the vessel describes a flexuous course within the broad ligament of the uterus.

Boye (1956) employs the term Rami cornuales to designate the terminal branches of the A. uterina media. Depending upon their course, they are termed as Ramus cornualis apicalis, medialis, or caudalis respectively. He adds that the Ramus cornualis forms arches along the uterine horn. He further describes the anastomosis of the A. uterina media with the A. spermatica interna and A. uterina caudalis.

Lange (1959) states that the A. uterina media divides into 3 to 4 vessels near the cranial third of the broad ligament of the uterus. He calls these vessels Rami uterini. He points out that these arteries form two types of arches. One type of arch is formed by the main terminal vessels of the A. uterina media. From this first arch arises the vessels which constitute the secondary arches. The latter arches are extended along the mesometrial border of the uterine horn. He adopts the terms proximal and distal arches to distinguish them. He adds that from the distal arch, Ramuli uterini approach either

the lateral or medial aspect of the walls of the uterine horn in a tortuous manner.

Barone, et al. (1962) states that the A. uterina (A. uterina media) in the sow resembles that of the cow. He points out, from a comparative anatomical viewpoint, that the vessel terminates into three branches, namely, the middle artery of the uterine horn, the caudal artery of the uterine horn, and the artery of the body of the uterus. He adds that these vessels, after a short flexuous course, divide into numerous branches which form arches on the mesometrial border of the uterine horn. He agrees with Lange that from the above mentioned arches vessels of various sizes are given off. Barone, et al. compare these vessels, in agreement with Sieber, to the vessels of the Aa. intestinales, and is in disagreement with Lange regarding those which correspond to the proximal and distal arch. According to Barone, et al., only the distal arch is formed.

The aspect concerning the course of the A. uterina media has been described in detail by Grahame (1957). According to him, the main branches of the A. uterina media in the virgin uterus have a straight course inside the broad ligament. He agrees that these vessels are anastomosed between them, forming arches while approaching the uterine wall. He points out that the course of the vessels is very tortuous in the sow.

The *A. urethrogenitalis* is described by Sieber (1903) as arising from the *A. iliaca interna* shortly behind or before the *A. iliolumbalis*. He states that the vessel, which goes to the pelvic part of the urethra in the male and to the vagina in the female, gives off the *A. uterina caudalis*.

Montané (1920) refers to this as the "vesicoprostatic artery" in the male and the vaginal artery in the female.

Dobberstein and Koch (1958) call this vessel the *A. urethrogenitalis*, in agreement with Sieber, and they state that the vessel resembles that of the bovine. They describe this vessel in the bovine as the main arterial source of the accessory genital glands. They state that the vessel gives off the *A. perinei* and the *A. hemorrhoidalis caudalis* in the female. Further, they mention that the *A. hemorrhoidalis media* is absent in the bovine.

Lange (1959), Preuss (1959) and Barone, et al. (1962) apply the term *A. vaginalis* for the *A. urethrogenitalis* of Sieber and Dobberstein and Koch in the sow. However, they do not agree with the terminology of its branches. Lange and Preuss state that the vessel gives off the following branches: *Ramus uterinus* (*A. uterina caudalis*) which becomes confluent with the most caudal branches of the *A. uterina media*; the *A. vesicalis caudalis* to the urinary bladder; the *Ramus urethralis* to the

urethra; the Rami vaginales to the vagina; and the A. perinealis. From a comparative anatomical viewpoint, they report that the Rami rectales medii (A. hemorrhoidalis media) are absent in the pig. They point out further that the pattern of distribution of the branches of the A. vaginalis is variable, because some branches arise either partly or wholly one from the other.

According to Lange (1959) and Preuss (1959) the A. perinealis could be considered as the continuation of the A. vaginalis (A. urethrogenitalis). Both Lange and Preuss agree that the vessel sometimes arises from the A. pudenda interna in the female. They add that, in the male, the A. perinealis is given off by the A. rectalis caudalis (A. hemorrhoidalis caudalis).

Barone, et al. states that the A. vaginalis (A. urethrogenitalis) in the sow ends in two arteries which he names the A. cervicouterina (A. uterina caudalis) and the A. vaginorectalis (A. perinealis of Lange (1959) and Preuss (1959)).

It is generally accepted that in the swine the A. pudenda interna and the A. glutea caudalis are the terminal branches of the A. iliaca interna (A. hypogastrica).

Chauveau (1889) states that the A. pudenda interna is formed by the A. iliaca interna beyond the lesser ischiatic notch. He reports that the vessel gives off a long hemo-

rrhoidal artery to the posterior extremity of the intestine and the genito-urinary organs.

Sieber (1903) describes the vessel in the male as the last strong visceral branch of the A. iliaca interna. He writes that this vessel forms a cluster of branches near the bulb of the urethra in the male. According to him, the A. pudenda interna seems to terminate at the Archus ischiadicus as the A. penis, which gives off the A. profunda penis and the A. dorsalis penis. He adds that the A. dorsalis penis gives off twigs which anastomose with the A. pudenda externa. In the female, he indicates that the A. pudenda interna is a slender vessel which is sometimes absent.

Montane¹ (1920) describes the A. pudenda interna as a terminal branch of the A. iliaca interna which is in agreement with Lange (1959), Barone, et al. (1962) and Bickhardt (1961). Montane¹ points out that it supplies the anus and the urinary organs.

Lange (1959) describes the A. pudenda interna in the female as the first terminal branch of the A. iliaca interna. He points out that the right and left vessels join near the ischial arch. He compares the nomenclature of the A. dorsalis clitoridis, a collateral branch of the A. pudenda interna. According to him the term A. clitoridis can be used as synon-

ymous with *A. dorsalis clitoridis*. He is in agreement with Sieber and states that the *A. pudenda interna* anastomoses with the *A. pudenda externa* in the female.

Barone, et al. (1962) agrees that the *A. pudenda interna* is a terminal branch of the *A. iliaca interna* in the female. He states that it gives off the *A. hemorrhoidalis caudalis*. He adds that the right and left vessels sometimes anastomose. He describes the *A. pudenda interna* as dividing into two vessels, one of which goes to the cavernosus bodies of the clitoris and the other, as the *A. dorsalis clitoridis*, to the clitoris.

Getty (1955) states that the main arterial supply to the penis is via the *A. dorsalis penis* which comes from the *A. pudenda interna*.

Bickhardt (1961) writes that the *A. pudenda interna* anastomoses with the branches of the *A. pudenda externa* and with the caudodorsal branches of the *A. profunda femoris* above the ischial arch.

There is no agreement about the terminology of the *A. hemorrhoidalis caudalis*. Sieber (1903) calls this vessel the *A. hemorrhoidalis inferior*. He states that the vessel is slender and anastomoses with the *A. hemorrhoidalis superior* (*A. hemorrhoidalis cranialis*) and gives off the *A. perinei* in the male. He adds, that the vessel supplies the *M. bulbocavernosus* and

anastomoses with the A. pudenda externa. Preuss (1959) specifies this vessel as the A. rectalis caudalis, as this vessel constantly supplies the rectum. He is in agreement with Sieber (1903), Lange (1959), and Getty (1955) that the vessel may arise from the A. pudenda interna or A. glutea caudalis, respectively.

Bickhardt (1961) states that the vessel supplies the perineum, the rectum and the M. ischiococcygeus.

Veins

Anatomical descriptions regarding the veins of the genital tract of the swine are limited in the literature. Most of them are mentioned in a comparative manner to the equine and the bovine.

Montané (1920) states that the testicular veins (Vv. testiculares) form a venous plexus in the inguinal canal in the male. He points out that the "great vena testicular" (V. spermatica interna) drains it into the V. cava caudalis. According to him, the veins of the ovary and those of the uterus join the utero-ovarian trunk, which drains in the V. cava caudalis. He reports that the penis is drained by three veins, one of which runs dorsally along the dorsal face of the body of the penis, which he designates as the "cavernosum"

vein, and the remaining two run ventrally, being placed at each side of the cavernosus bodies of the urethra. He adds that these veins drain either into the V. pudenda externa or by means of the V. perinealis into the V. pudenda interna. Ellenberger and Baum (1943) state that the venous system of the swine, in general, resembles that of the horse, whereas, Sisson and Grossman (1953) report that it corresponds to that of the bovine.

Bevandic (1943) states that the venous drainage of the rectum can be accomplished through the V. hemorrhoidalis cranialis, a tributary vein of the portal system, and the V. pudenda interna through its tributaries which drain the ventral aspect of the anal musculature. He suggests that these radicles could be designated as the V. hemorrhoidalis media, and reported that the radicles corresponding to the V. hemorrhoidalis caudalis were not found.

Schwarz and Badawi (1962) state that the site of junction of the V. spermatica interna with the V. iliaca communis is variable. They report that in 21 females and 5 males the V. spermatica interna, left and right, emptied into the V. cava caudalis, either 2 to 2.5 cm cranial, or close to the confluence of the V. iliaca communis. They add that the V. spermatica interna emptied into the left V. iliaca communis in three females and in one male.

Lange (1959) describes the venous drainage of the genital tract in the female swine. According to him, the V. ovarica (V. spermatica interna or V. utero-ovarica), V. uterina (V. uterina media), and V. vaginalis (V. urethrogenitalis) are the main vessels which drain it. He points out, however, that the V. perinealis mainly drains into the V. rectalis caudalis (V. hemorrhoidalis caudalis).

Lebedewa (1960) states that the sow has two Vv. pudendae externae, the cranial and the caudal veins of the udder. According to her, both join the V. profunda femoris. She reports that each receives two branches, one lateral and one medial. Those which correspond to the caudal vein of the udder drain the area from the genital organs to the last mammary gland. She adds that the valves are directed to the V. pudenda externa in both veins of the udder.

Regarding the V. pudenda interna, she states that the Vv. pudendae internae anastomose and give rise to two veins which run on each side of the ventral wall of the pelvic cavity towards the obturator foramen to anastomose with the venous Ramus obturatorius of the V. profunda femoris. She notes that the valves of the V. pudenda interna are directed to the V. iliaca interna, while the valves of another branch are directed to the venous Ramus obturatorius.

Barone, et al. (1962) agree with Lange in that three veins drain the genital tract in the female. According to him, the V. utero-ovarica (V. spermatica interna) is best developed. He says that this vessel arises from a venous plexus which is situated along the dorsal edge of the ovary. He adds that this plexus is connected by the V. uterina (V. uterina media) and joins the V. cava caudalis.

Regarding the V. uterina media, Barone, et al. point out that the vessel shows a different disposition than the corresponding artery. The radicles of the vein form arches along the dorsal edge of the uterine horn. He designates these arches as the distal arches. According to him, from these arches numerous veins are given off which converge together to form the proximal arches.

The V. urethrogenitalis is designated by Barone, et al. in agreement with Lange, as the V. vaginalis. He writes that this vessel drains the uterine cervix, the vagina, the ureter, and the urethra, and anastomoses with the V. uterina media.

Bickhardt (1961) describes the V. pudendalis interna as anastomosing with the V. pudendalis externa in the perineum, with the proximal branch of the V. profunda femoris and medially with the V. pudendalis interna of the opposite side.

He notes also that the *V. hemorrhoidalis caudalis* drains the perineum, the caudal segment of the rectum, the anus, and the *M. ischiococcygeus*.

He also describes the *Vv. epigastrica caudalis*, *pudendalis externa*, and *subcutanea abdominis*.

MATERIALS AND METHODS

Ten pigs were used for this investigation, five males and five females. The group consisted of two breeds, eight of the Yorkshire breed and two of the Hampshire breed. They were considered to be clinically free from pathological conditions. The ages of the animals ranged from eight to eighteen months and were determined according to Pope (1934). The sex and body weight of each animal are shown in Table 1. For the preparation of corrosive specimens, additional material (ten uteri from non-pregnant sows) was obtained from an abattoir.

The animals used for gross dissection were prepared according to the following procedure. Before administration of the anesthesia, the animals were kept on a low ration for three days. A solution of chloral hydrate and magnesium sulfate was used as the anesthetic fluid. Ninety grams of chloral hydrate and 60 grams of magnesium sulfate were dissolved in 500 cc of 0.85 per cent sodium chloride solution. The anesthetic was given intraperitoneally, using approximately 1 cc per 3 lb. body weight (Table 2).

With the animal under surgical anesthesia, the left carotid artery was exposed and cannulated. Exsanguination was accomplished through the cannula. Frequent flexing of both the

fore- and hind limbs permitted better bleeding. For the purpose of injecting the arteries, the thorax was opened, following bleeding, on the left side by resection of the fourth rib. The aortic arch was exposed and ligated immediately below the origin of the brachiocephalic trunk. This was followed by injection into the arterial system. Cementex¹, a basic latex compound (pH 8), was used as the injection mass. According to the method of Hill (1937), 2 per cent ammonia water solution was added to the latex, in the ratio of 4:6, in order to reduce its own viscosity.

Assuming that pressure above 100 mm. Hg may rupture the arteries, the latex solution was injected through a cannula from an external, special outfit, as described by Tanudimadja (1963) (Figure 1), at a pressure of 100 mm. Hg. Immediately following the administration of the injection mass, the specimens were stored in the cooler for three days.

The animals were removed from the cooler after three days and placed at room temperature for about 12 hours for the injection of the venous system. This effort diminished the resistance of the valves of the veins due to post mortem degeneration (autolysis) of the valves. The abdominal cavity

¹Manufactured by the Cementex Company, New York 3, New York.

was then opened on the right side and the viscera, belonging to the digestive system, were removed, after securing the vessels. The posterior vena cava was cannulated just caudal to the origin of the renal veins. Blue latex, diluted in 2 per cent ammonia water, in the ratio of 5:5, was injected slowly at a pressure of 70 mm. Hg. The amount of latex solution injected, for both arteries and veins, varied according to the size of the animal (Table 3). It is of interest to note that the quantity of the diluted latex used for venous injection was relatively larger than that for the corresponding arteries. Pertinent data on injection procedure is given in Table 3.

The materials used for making corrosion specimens were injected according to the following procedure. The specimens were removed from the carcasses, according to the method described by Reuber (1954), and placed in the refrigerator for 24 hours. Subsequently, they were put into water containers at a temperature of approximately 37° centigrade. The utero-ovarian and middle uterine arteries and the utero-ovarian vein were cannulated by means of ground hypodermic needles of various sizes. The needles, connected with the above mentioned arteries, were adjusted to a T-glass tube and also to the injecting equipment by means of rubber tubes. Prior to

injection, rinsing of the vessels was carried out until the blood, flowing through the cannula connected to the vein, was clear. Warm, normal, saline solution was used to rinse the vessels. The injection mass was red, yellow, or blue latex. The venous system of only one specimen was injected with Vinyl¹, in this case the perfusion rinse was not accomplished.

Approximately 100 cc of red latex solution was injected into the arteries, and 300 cc of blue latex solution or Vinyl, into the veins. Upon completion of the injection the cannulae were removed. The vessels were ligated and the specimens were stored in a cooler for three days. Following refrigeration, the specimens were dissected and prepared for subsequent treatments, such as maceration, photography, etc.

The maceration of the specimens was performed by means of 31 per cent hydrochloric acid for three or four days. Macerated casts were washed thoroughly under gently flowing tap water and preserved in 10 per cent formalin solution for later use.

A caliper² was used for measuring the arteries (Figure 2).

¹Manufactured by the Gordon-Lacey Chemical Products Co., Inc., Maspeth, New York.

²Lufkin Rule Co., Saginaw, Michigan.

RESULTS

Arteries

The A. thoracica interna arose as a collateral branch from the ventral wall of the A. brachialis (A. subclavia), medial to the first rib (see Figure 24/84). It averaged 4.5 mm in peripheral diameter. It passed in a caudoventral direction to reach the cranial border of the M. transversus thoracis, and then continued further along the dorsal faces of the costal cartilages below this muscle. The vessel usually ended medial to the 6th rib as the A. musculophrenica and A. epigastrica cranialis (Figures 8/87, 8/90, 24/87, 24/90). Terminations of the parent vessel were observed to be extremely variable (Table 4). The A. thoracica interna supplies the thoracic mammary glands by means of collateral twigs departing from it at the level of each intercostal space. They are as follows:

The Rami intercostales arose from the lateral side of the main vessel (Figure 24/85). They ascended and pierced the intercostal muscles and soon divided into two branches. One of the branches anastomosed with the homologous descending artery, whereas the other passed out as perforating branches (Rami perforantes), running ventrally, to supply the Mm. pectorales, subcutaneous tissue and skin of the region. Those corre-

sponding to the 5th and 6th Rami intercostales supply, by means of the Aa. intercostales, the lateral and medial aspects of the 1st pair of mammary glands and end, forming a circle, around the base of the nipples. It was noticed, in two of ten specimens, that the left 4th, 5th and 6th Rami intercostales were derived from a common trunk which arose from the parent vessel medial to the 3rd intercostal space.

The Rami sternales arose from the medial side of the principal vessel. After supplying the M. transversus thoracis, the arteries leave the thoracic cavity and end, giving off twigs along the Mm. pectorales and the medial aspect of the 1st pair of the thoracic mammary glands (Figure 24/86).

The A. epigastrica cranialis supplied the abdominal mammary glands. It averaged 3.1 mm in external diameter. It is considered to be the continuation of the A. thoracica interna (Figures 24/87, 8/87). This vessel, in both the male and female, left the rib cage at the angle formed by the last costosternal junction. The vessel then continued caudally on the M. rectus abdominis to anastomose with the A. epigastrica caudalis immediately behind the umbilicus. Anastomotic branches with the branches of the A. circumflexa ilium profunda were observed. At the level of the tendinous inscriptions of the

M. rectus abdominis, the A. epigastrica cranialis gave off the following branches:

The lateral branches were given off from the lateral wall of the parent vessel (Figures 23/88, 27/88). They extended dorsally, at first, on the M. rectus abdominis, and then advanced between the Mm. transversus abdominis and obliqui abdominis internus and externus to anastomose with the ventral branches of the Aa. intercostales and Aa. phrenoabdominales.

The medial branches passed ventrally toward the median plane (Figures 24/89, 27/89). They gave off branches which, after passing through the abdominal wall, supplied the abdominal mammary glands of the female. The branches to the last abdominal gland anastomosed with the branches of the A. pudenda externa. In the male, the last medial branch usually gave off a strong vessel which passed somewhat obliquely to the prepuce (Figure 14/89). This vessel supplied the M. protractor praeputis (M. praeputialis), the subcutaneous tissue and skin. After anastomosing with twigs from the preputial branch of the A. pudenda externa it ended within the lateral wall of the prepuce.

The A. profunda femoris (Figures 3/11, 23/11) arose from the caudal face of the A. iliaca externa, medial to the caudal head of the M. sartorius. It averaged 4.3 mm in peripheral

diameter, and ran in a slightly ventrocaudal direction to advance between the M. vastus medialis, laterally, and the M. pectineus, medially, after giving off the pudendoepigastric trunk and the A. spermatica externa. The vessel then continued further under the acetabulum through the M. adductor describing a caudodistal arch, medial to the muscles which are known as the "small pelvic association" (Ellenberger and Baum, 1943). It furnished branches to the above muscles. One of the branches, the Ramus obturatorius ran laterally to the M. obturator externus to approach the obturator foramen and the M. obturator internus, where it divided into two secondary branches. One of the latter, directed cranially, anastomosed with the A. obturatoria and the other, after supplying the M. obturator internus, ran caudally to anastomose with the terminal branches of the A. urethrogenitalis on the lateral wall of the urethra, or with muscular branches of the M. obturator internus given off by the A. pudenda interna. The Ramus obturatorius, before reaching the obturator foramen, gave off a caudal branch which passed under the Ramus acetabularis of the ischium to end in twigs under the insertion of the Mm. gemelli.

The A. profunda femoris, at the level of the insertion of the M. obturator externus, usually divided into four branches

which were disposed of as lateral, medial, caudoproximal, and distal. The latter, namely, the A. circumflexa femoris medialis (Figures 4/32, 23/32) is considered to be the continuation of the parent vessel (Bickhardt, 1961).

The branch, which is disposed of caudoproximally (Figures 3/31, 23/31) ran immediately towards the tuber ischii. After giving off branches to the surrounding structures, the artery terminated in twigs supplying the origin of the caudal muscles of the hip and thigh regions. In the male, one of the branches was also distributed to the M. ischiocavernosus. It also anastomosed with the corresponding vessels arising from the A. pudenda interna.

The Truncus pudendoepigastricus arose almost with the A. spermatica externa from the ventral wall of the A. profunda femoris medial to the caudal head of the M. sartorius. It averaged 2.6 mm in peripheral diameter. It ran ventrally and divided immediately into two branches, the A. epigastrica caudalis and the A. pudenda externa (Figures 3/13, 23/13). The former supplied the caudal portion of the M. rectus abdominis while the latter entered the inguinal canal.

The A. epigastrica caudalis arose medially or cranially or caudally to the A. pudenda externa (Figures 3/14, 6/14, 23/14). It averaged 1.6 mm in peripheral diameter. It passed

cranially and was covered by the dorsal leaf of the sheath of the M. rectus abdominis. The artery ran along the dorsal face of the muscle to anastomose with the A. epigastrica cranialis. On its course two main vessels departed from it. One of them coursed laterally to anastomose with branches of the A. phreno-abdominalis and the A. circumflexa ilium profunda. The other vessel ran medially to the linea alba and gave off ventral branches which anastomosed with the branches of the A. pudenda externa.

The A. pudenda externa (Figures 3/15, 23/15, 39/15), because of the average of its peripheral diameter, 2.4 mm, may be considered as the direct continuation of the pudendoepigastric trunk. It extended ventrally to the inguinal canal, accompanied by its satellite veins. It ran along the canal, medial to the spermatic cord, to emerge at the medial commissure of the external inguinal ring. After crossing the spermatic cord medially, it turned forward to end under the Lnn. inguinales superficiales (Ln. supramammarii in the female) covered by the subcutaneous fatty tissue. The A. pudenda externa terminated into either three or four branches. In the case of four branches, three were directed cranially and the other caudally. They are designated as the lateral cranial,

middle cranial, and medial cranial branches (Bickhardt, 1961 and Kähler, 1960). If three branches existed, two of them were directed cranially and the other caudally. In the case of the latter pattern, which was usually observed in the male, the middle cranial branch was given off by the medial cranial branch.

In the female, the lateral cranial branch (Figures 23/16, 24/16, 39/16) arose from the parent vessel at the level of the dorsal border of the above mentioned lymph nodes (*Lm. inguinales superficiales*). After supplying them, the vessel passed craniolaterally toward the lateral side of the last abdominal mammary gland. It gave off branches medially to the fatty tissue, inguinal mammary gland, and skin. Laterally, it furnished branches to the subcutaneous tissue of the medial side of the thigh and anastomosed with branches of the *A. circumflexa ilium profunda*.

The middle cranial branch (Figures 23/17, 24/17, 39/17) arose from the *A. pudenda externa*, or from the medial cranial branch shortly after the origin of the latter. It passed deep to the fatty tissue, at first, on the lateral side of the last inguinal mammary gland. Later it coursed on the medial side of the second pair of inguinal mammary glands. It ended in a cluster of branches near the last pair of abdominal mammary

glands. Perforating branches, to the ventral abdominal wall, supplied the abdominal muscles and ended by anastomosing with the A. epigastrica caudalis within the M. rectus abdominis.

The medial cranial branch (Figures 23/18, 24/18, 39/18) passed approximately parallel to the linea alba. It supplied the subcutaneous fatty tissue, abdominal muscles in the inguinal area, and skin. The caudal branch (Figures 23/21, 24/21, 39/21), from its origin, described a bend caudad and continued through the fatty tissue of the inguinal area to the interfemoral space, where it divided at an angle of 45° into two branches, superficial and deep. The superficial branch (Figures 23/22, 24/22, 39/22) coursed caudally, parallel to the interfemoral space on the medial aspect of the dorsomedial side of the thigh. It gave off branches to the subcutaneous fatty tissue and the skin of the medial side of the thigh, which anastomosed with twigs of the A. femoralis destined for the M. gracilis. The deep branch (Figures 23/23, 24/23, 39/23) coursed deep in the interfemoral space to the perineal region and ended, after forming anastomoses with the terminal branches of the A. pudenda interna.

The A. pudenda externa of the male resembled that of the female. The medial cranial branch may be considered as the

preputial branch (Figures 3/18, 5/18, 10/18, 11/18). It was observed that the right and left vessels varied in size. It was noticed, in three out of five specimens, that the right vessels were more developed than their counterparts. In the other two specimens, the left vessels were larger. The medial cranial branch of the right and left sides coursed parallel to the sheath of the penis, dorsal to the M. retractor preputii. Near the origin of the retractor muscle the vessels of one side or the other were poorly developed. The counterpart of the poorly developed side approached the dorsal edge of the median septum of the preputial diverticulum piercing it and coursing cranially to divide at an acute angle into two terminal branches. During this course the artery gave off lateral and medial branches which supplied the fatty tissue, the sheath of the penis, the skin, the M. retractor preputii and the dorsal wall of the diverticulum. Those which correspond to the lateral branches anastomosed with branches of the A. thoracica interna.

Each of the terminal branches, after a short course, gave off slender vessels, directed cranially and ventrally. The former anastomosed with the A. epigastrica cranialis within the M. protractor preputii, and those which ran ventrally, with its fellow of the opposite side, formed a semicircle ventral to

the preputial orifice (Figures 3/19, 11/19). After giving off the above vessels, the main artery made a bend caudal and coursed along the cranial third of the preputial sheath (Figures 3/20, 11/20, 12/20), where it finally ramified and anastomosed with the terminal branches of the *A. dorsalis penis*. This branch may be considered as the recurrent artery of the sheath of the penis of the bovine (Ashdown, 1958).

The caudal branch of the *A. pudenda externa* (Figures 3/21, 4/21, 5/21) extended caudally in the fatty tissue of the inguinal region and divided, as in the female, into two branches, superficial and deep. The superficial branch (Figures 4/22, 9/22) ran caudally, in a slightly ventral direction, toward the fatty tissue of the scrotal fold. At this point it ended in small branches which supplied the medial aspect of the thigh, the skin and the scrotum. The deep branch passed medial to the spermatic cord to the septum scroti (Figures 4/23, 9/23), where it coursed caudally, giving off dorsal branches to the layers of the scrotum and septum scroti. One of the dorsal branches anastomosed with the *A. pudenda interna* (Figures 3/25, 4/25). The caudal branch terminated into two branches, one of them continued ventrally and ended in a cluster of branches on the medial side of the scrotum (Figure 4/26). The other continued dorsally and terminated by

furnishing the lateral side of the scrotum (Figure 4/27).

The A. spermatica externa (Figures 3/12, 23/12) supplied the M. cremaster externus in both the male and female. It was a slender vessel with averaged 1.3 mm peripheral diameter. It may arise from the A. profunda femoris in front, near or separately of the origin of the pudendoepigastric trunk, or caudal to it (Figure 6/12, Type I), from the cranial or medial wall of the trunk (Figure 6/12, Type II), or from the A. circumflexa ilium profunda (Figure 6/12, Type III), or from the A. pudenda externa (Figure 6/12, Type IV). It ran cranioventrally to reach the origin of the M. cremaster externus and pierced it. In the female, it continued along the above mentioned muscle to end, after giving off twigs in the fasciae and tissues which form the vaginal process, inside the interfemoral space. In the male, it continued to the insertion of the M. cremaster externus, where it divided in a cluster of vessels supplying the tunica vaginalis. Collateral branches, supplying the muscle and the fascia scroti superficial and profunda, were released along its course.

The A. spermatica interna arose from the abdominal aorta before the origin of the A. mesenterica caudalis (Figure 3/5) at the level ventral to the fifth lumbar vertebra, 1.4 to 2.5 cm from the bifurcation of the aorta. It was noted that

the left A. spermatica interna arose from the ventrolateral wall of the parent vessel, whereas the right artery was given off from the ventral wall more forward than its fellow of the opposite side. The average of the peripheral diameter of the left was 1.9 mm and that of the right vessel was 1.7 mm. The vessel supplied the testicles and the middle and cranial thirds of the body and head of the epididymis. It coursed in a caudo-lateral direction and crossed the deep face of the ureter, giving off a slender branch to the Ramus uretericus (Figure 3/6). It then passed to the lateral side of the seminal vesicle, being embedded within a fold of the peritoneum. It continued its course ventrally and joined the ductus deferens and the A. deferentialis inside the inguinal canal. As one component of the spermatic cord, it continued caudally through the inguinal canal to give off slender anastomotic branches to the A. deferentialis. On reaching the middle third of the canal, it became very tortuous, thus forming an arterial cone with the base lying on the cranial surface of the testicle, medial to the epididymis. The arterial cone was interlaced by an extensive venous plexus, the Pampiniform plexus (Figures 3/7, 15/7, 15^b/7, 17/7). Slender branches were given off from the dorsal and lateral aspects of the arterial cone which were disposed of in a series. One of them, following a wave-like

course, joined the branches of the *A. deferentialis* (Figure 17/5'). The other one was directed to the medial wall of the epididymis, passed between the medial face of it and the testicle, and terminated, supplying the lateral face of the head of the epididymis (Figure 17/5''). These branches may be considered the *A. accessoria testicularis* of the goat (Hofmann, 1960; Magilton, 1964). From the base of the arterial cone the *A. spermatica interna* passed under the body of the epididymis of the proximal pole of the testicle. It then made a bend ventrally and pierced the tunica albuginea in a tortuous course. As soon as the artery penetrated the tunica albuginea, it became the *Aa. testiculares* (Figures 3/8, 16/8). The *Aa. testiculares* coursed, embedded in the albuginea, to the ventral pole of the testicle, giving off coiled ramifications which ran on the free border of the testicle and the lateral and medial faces of it.

Latex casts showed that the *A. spermatica interna* gave off collateral branches directed to the testicle (Figure 15^b/5'''). These branches arose from the parent vessel near the base of the arterial cone.

The *Aa. radiatae testes* arose from the *Aa. testiculares* and ran to the mediastinum testis (Figure 16/8'). This branch arose at right angles and immediately became spiral. This

portion (Figures 16/8'', 18/8''), in agreement with Hofmann (1960) and Magilton (1964), may be considered as the Aa. centripedales of the Aa. radiatae testes. Then the Aa. radiatae testes continued in a straight course to reach the mediastinum, where it anastomosed with adjacent vessels forming arcs on the mediastinum (Figure 16/8'''). Many branches were released from the arcs. Some of the branches coursed toward the periphery of the testicle (Figures 16/8'v, 18/8'v). These branches may be considered as the Aa. centrifugales of the Aa. radiatae testes (Hofmann, 1960 and Magilton, 1964).

The A. utero-ovarica (Figures 23/5, 42/5) in the female corresponds to the A. spermatica interna of the male. It supplies the ovary, the ovarian bursa and the uterine tube. It averaged 1.8 mm in peripheral diameter. The origins of the left and right vessels resembled those of the A. spermatica interna in the male. Each passed ventrally and slightly cranially to reach the broad ligament of the uterus, embedded in the cranial border of same. The artery pursued a flexuous course, passing medial to the ureter to which a slender branch, the Ramus uretericus, was given off (Figure 23/6). The latter soon divided into two branches which ran cranially and caudally along the ureter. In one specimen, it was observed that the Ramus uretericus arose from the A. mesenterica caudalis and the other

from the aorta.

The *A. utero-ovarica* continued ventrally and usually divided into a cluster of branches. One of them coursed cranioventrally (*Ramus ovaricus*, Sieber, 1903; Ellenberger and Baum, 1943; Dobberstein and Koch, 1958) and the other ones caudoventrally (*Ramus uterinus*, Sieber, 1903; Ellenberger and Baum, 1943; *Rami uterini*, Lange, 1959; *A. tubo-uterina*, Barone, et al., 1962). The former branch may be considered as the *A. ovarica* (Sisson and Grossman, 1953), (Figures 23/8, 45/8, 46/8). In fact, it ran ventrally, became increasingly tortuous, and pierced the dorsal border of the ovary where it divided into branches (Figures 45/8', 47/8', 48/8'), (spiral arteries). The caudal branches (Figures 23/5', 45/5', 46/5'), after their origin, split into other branches and anastomosed, by means of coiled vessels and, thereby, formed a complicated arterial meshwork (Figures 43, 45) on the lateral aspect of the main vessels. Macerated specimens permit one to observe that two types of arteries arise from this arterial meshwork. One of them is well developed and runs toward the ovary, along with the *A. ovarica*, to penetrate the vascular zone where it divides as the spiral arteries of the ovary (Reynolds, 1947) (Figures 45/8', 47/8', 48/8'). From the latter, numerous slender vessels are given off. They course in a tortuous manner to the

cortical zone forming a wreath around the follicles (Figure 49/8"). The others are poorly developed but numerous and follow two routes. Several of them coursed ventrolaterally in the mesosalpinx and were directed cranially and caudally to the bursa ovarica, fimbria and cranial and middle thirds of the uterine tube. The remaining ran ventrocaudally and anastomosed with the cranial branches of the A. uterina media, forming an arterial plexus along the middle and cranial thirds of the uterine tube (Figure 44/5"). From this anastomotic plexus, slender vessels were given off which supplied the distal third of the uterine tube. The caudal, terminal branches of the A. utero-ovarica can be considered as the Rami tubo-uterini, depending upon the area supplied and the disposition of the vessel.

The A. iliaca interna (Figures 3/33; 4/33, 23/33) arose as one terminal branch of the abdominal aorta, 1-1.5 cm after the origin of the A. iliaca externa, at the level of the last lumbar vertebra. Each passed caudodorsally in the fatty tissue under the wing of the sacrum to reach the greater ischiatic notch. At this point it left the pelvic cavity and coursed on the superficial face of the wide pelvic ligament. Here it described a caudodistal arch being covered by the Mm. glutei, M. biceps femoris and M. semitendinosus. It ended as the A.

pudenda interna (Figures 3/60, 23/60) and *A. glutea caudalis* (Figures 3/74, 23/74) at the middle third between the acetabulum and tuber ischii.

The *A. iliaca interna* supplied the genital tract and the structures related to it by means of its collateral branches, which came off its ventral wall and are known as the visceral branches of the *A. iliaca interna*, and also by its terminal branches, the *A. pudenda interna*. The visceral branches are as follows:

The *A. umbilicalis* (Figures 3/34, 23/34) was given off from the ventral wall of the *A. iliaca interna*, 3 mm to 1.7 cm from the origin of the latter. It averaged 3 mm in peripheral diameter. In both male and female, the vessel passed, embedded in the peritoneum, along the lateral wall of the pelvic inlet. It then coursed laterally to the ureter and turned somewhat cranially to reach the cranial edge of the lateral ligament of the urinary bladder. After giving off the *A. vesicalis cranialis* to the urinary bladder (3/35) it became the ligament teres (or round ligament) of the bladder. The *A. umbilicalis* in the male gave off the *A. deferentialis* (3/36) which corresponds to the *A. uterina media* in the female (23/36).

The *A. deferentialis* arose either from the medial or from the caudal wall of the parent vessel. It left the *A.*

umbilicalis 4 mm to 1 cm after the origin of the latter. It averaged 1.3 mm in its outside diameter. It descended in a ventrocraniolateral direction lateral to the seminal vesicle. Then it turned caudally and gave off a slender branch, the Ramus uretericus (3/37), which ran to the ureter. Afterwards, the main vessel continued laterally to the A. umbilicalis and approached the entrance of the inguinal canal. Being a component of the spermatic cord, it descended in the inguinal canal dorsal to the ductus deferens. On reaching the middle third of the inguinal canal, it started to divide successively into other branches which were maintained together by the visceral layer of the vaginal process. They pursued a flexuous course along the ductus deferens toward the epididymis and, after passing between the medial face of it and the testicle, reached the tail (cap-like) of the epididymis and pierced it, giving off branches which supply this region.

During this course, the A. deferentialis exchanged anastomotic branches with the A. spermatica interna and entered in the formation of the A. accessoria testicularis (17/5').

The A. uterina media (Figures 23/36, 42/36, 45/36, 58/36), in the female, corresponds to the A. deferentialis of the male. Although they have the same origin, the average of their

outside diameters were different. The A. uterina media was 2 mm in peripheral diameter and the A. deferentialis was 1.3 mm. The diameter varied according to the extent of the area it supplied. It was the principal artery to the uterine horns, the caudal third of the uterine tube, and the body and cervix of the uterus.

It left the A. umbilicalis 1.5 to 2.5 cm from the origin of the latter. It averaged 2 mm in its peripheral diameter. It had a tortuous cranioventral course in the medial side of the broad ligament and crossed the deep face of the ureter, thereby giving off the Ramus uretericus to the latter. It then approached the middle part of the cranial third of the broad ligament and usually divided into two main branches (23/36', 58/36'), one directed slightly cranially to the anterior part of the ligament, and the other toward the middle and caudal thirds of the same. These branches divided as soon as possible into primary branches (Figures 23/36", 42/36", 58/36"), which ran in a flexuous course toward the small curvature of the uterine horn. In two uteri of young females the course of these arteries was straight. Communicating branches between them and slender collateral branches supplying the broad ligament were usually observed (Figure 23/36'V).

As soon as the primary branches reached the lesser curvature of the uterine horn, each divided into two secondary branches (Figures 23/36''', 58/36''') which anastomosed with the adjacent ones to form a series of arcades, similar to those of the Aa. jejunales (Figure 59). The most cranial branch anastomosed with the Rami tubouterini of the A. utero-ovarica (Figures 23/36^V, 43/36^V) and the most caudal with the Rami cervico-uterini (A. uterina caudalis) of the A. urethrogenitalis (Figures 23/36^{V'}, 42/36^{V'}, 60/36^{V'}). From these arcades, Ramuli uterini were given off (Lange, 1959) (Figures 23/36^{V''}, 58/36^{V''}, 59/36^{V''}). These entered into the wall of the uterine horn in a tortuous course in sows and in a straight course in gilts.

The A. urethrogenitalis arose from the ventral wall of the A. iliaca interna just opposite to the origin of the A. glutea cranialis, 1.0 to 1.4 cm before the parent vessel left the pelvic cavity (Figures 3/40, 23/40, 42/40). It averaged 2.5 mm in peripheral diameter. In the female, it passed in a caudo-ventral direction toward the dorsal border of the cranial third of the vagina on the caudal border of the broad ligament of the uterus. It furnished a cranial branch which ran cranio-ventrally to supply the broad ligament. In the male it supplied the retroperitoneal tissue. The A. urethrogenitalis

divided into two branches, cranial and caudal (Figures 3/41, 3/51, 23/41, 23/51). In the female, the cranial branch (Figures 23/41, 60/41) ran slightly cranioventrally and immediately split up into a cluster of vessels. It supplied the cervix and the body of the uterus, the neck of the urinary bladder, the urethra, the distal end of the ureter, the vagina and the fatty tissue which surrounds the lateral and ventral wall of the pelvic cavity. The following arteries are furnished by the cranial branch:

The Rami uterini (Lange, 1959) (Figures 23/50, 60/50) continued craniolaterally on the lateral wall of the cervix and pierced it and the body of the uterus. One of these rami (the Rami cervicouterini, Lange, 1959) was seen to course along the ventral face of the uterus to anastomose with the last caudal branch of the A. uterina media (Figures 23/50', 60/50').

The A. vesicalis caudalis (23/47) coursed in a cranioventral direction toward the neck of the urinary bladder and anastomosed with the A. vesicalis cranialis. It was noted that a slender vessel, Ramus uretericus, after departing from the lateral side of the parent vessel, extended to the ureter to anastomose with the Ramus uretericus of the A. uterina media (Figure 23/48). The A. vesicalis caudalis also furnished a slender branch to the urethra and anastomosed with the Ramus

urethralis (Lange, 1959) and the A. urethralis of the A. pudenda interna. From this anastomosis a delicate vessel passed to the fatty tissue of the pelvic cavity and anastomosed with a branch of the Ramus obturatorius of the A. profunda femoris.

The Ramus urethralis (Lange, 1959) (Figures 23/43, 65/43) ran caudoventrally and laterally to the vagina toward the urethra. It supplied the cranial and middle thirds of the female urethra and anastomosed with the A. urethralis which is derived from the A. pudenda interna and A. vesicalis caudalis.

The Rami vaginalis (Figures 23/42, 65/42) ran caudally on the lateral wall of the vagina. It supplied the cranial and middle thirds of the vagina. It anastomosed with vaginal branches given off by the caudal branch of the parent vessel.

The caudal branch (Figures 23/51, 42/51, 60/51) (A. perinealis of Preuss, 1959 and Lange, 1959) appeared to be the continuation of the A. urethrogenitalis. The outside diameter of this artery was 2.2 mm while that of the cranial branch was 1.8 mm. The peripheral diameters, also of the left and right arteries were variable, even in the same animal. In three of the five specimens studied, the left artery was larger than its fellow of the opposite side and was extended to the perineum. In the remaining two, the right vessel assumed the previously referred to disposition. It coursed along the dorsal border of the

vagina and vestibule of the vulva. It then inclined medially and continued to the rectum and vulva, medial to the M. constrictor vestibuli to reach the M. constrictor vulvae, where it divided and formed an arterial circle (Figures 66, 67, 68, 69). It supplied the ventral third of the Mm. sphincter ani internus and externus, respectively, as well as the fatty tissues and skin of the perineal region.

Throughout its course, it gave off twigs which supplied the middle and caudal thirds of the vagina. About 1.5 cm from its origin, it gave off a collateral branch which ran caudoventrally and anastomosed with the A. pudenda interna (Figures 23/53, 67/53).

In the male, the A. urethrogenitalis ended laterally to the apex of the seminal vesicle, as two branches, like those of its counterpart in the female, the anterior and posterior branches (Figures 3/41, 3/51).

The former (Figures 3/41, 4/41) proceeded cranioventrally toward the base of the seminal vesicle in which they ramified. In their course, they passed on the lateral face of the gland and gave off, in succession, the following main vessels:

The Ramus prostaticus was large and arose in common with the A. vesicalis caudalis from the ventral wall of the parent vessel (Figures 3/42, 4/42). It passed ventrally to the dorsal

face of the prostate gland where it divided into two branches. One of them coursed cranioventrally to anastomose with the collateral branch to the seminal vesicle, forming an arterial arch up to the prostate gland (Figure 4/43). The other ran slightly dorsocaudally and anastomosed in an arcade with the branches directed to the prostate gland by the caudal branch of the *A. urethrogenitalis* (Figure 4/44). From those arches, branches passed to the gland and also to the urethra and contributed to form a network with the urethral branches coming from the *A. vesicalis caudalis* and those of the caudal branch of the *A. urethrogenitalis* (Figure 4/46). This arterial network, lying on the dorsolateral and ventral faces of the urethra, anastomosed with its fellow of the opposite side.

The *A. vesicalis caudalis* (Figures 3/47, 4/47) coursed ventrally to the neck of the urinary bladder. It gave off anastomotic branches to the arterial network of the urethra.

The *Ramus uretericus* was a slender branch directed to the medial face of the distal end of the ureter (Figures 3/48, 4/48).

The branch to the seminal vesicle was larger and arose from the ventral wall of the parent vessel (Figures 3/49, 4/49). It described a flexuous course and pierced the capsular tissue of the gland. It gave off collateral branches which

were directed to the prostate gland and anastomosed with the Ramus prostaticus.

The deferential branch arose at the level of the base of the seminal vesicle (Figure 3/50). It passed tortuously on the medial face of the ductus deferens. It supplied the cranial third of the ductus deferens and usually anastomosed with the A. deferentialis.

The caudal branch of the A. urethrogenitalis (Figures 3/51, 4/51) may be regarded as the direct continuation of the parent vessel. Like its counterpart in the female (A. perinealis), it showed variations in diameter with that of the cranial branch. It averaged 2.5 mm while the cranial branch showed 2 mm in its outside diameter. Variations in size between the left and the right artery in the same animal have also been noted. In four out of five specimens, the left artery was more developed than its fellow of the opposite side. In these specimens the left artery was a unilateral branch which assumed the blood supply of the medial face of the bulbo-urethral glands (Getty, 1955).

The right artery was limited to supply the corresponding M. retractor penis and the lateral face of the gland. The right vessel assumed the disposition of the above mentioned left vessel in the other specimen.

The caudal branch coursed backwards to pierce the fatty tissue which separated the bulbourethral glands. In this short course it gave off two collateral branches (Figures 3/52, 4/52) which were directed cranioventrally and anastomosed with each other and with the Ramus prostaticus of the cranial branch forming an arterial arch of the prostate and the cranial thirds of the urethra. From this arch arterial vessels passed to the prostate gland and to the urethra. Those to the latter contributed to form the arterial network of the urethra. Some of these vessels passed to the retroperitoneal tissue which surrounds the entrance of the pelvic inlet. It was seen that one of these vessels anastomosed with the cranial branch of the Ramus obturatorius of the A. femoris profunda (Figure 4/57).

Just before it pierced the fatty tissue between the bulbourethral glands it gave off an anastomotic branch to the A. pudenda interna (Figures 3/53, 4/53). It coursed caudally between the ventral border of the gland and the urethra. Throughout its course it gave off dorsal, ventral, and medial branches. The dorsal branches ran along the lateral face of the gland and supplied it (Figure 3/54). The ventral branches pierced the lateral wall of the middle and caudal thirds of the urethra (Figure 4/55). The medial branches supplied the ventrolateral surface of the gland (Figure 4/56).

Between the two glands, embedded in the fatty tissue, the artery continued caudally to terminate by dividing into two branches which anastomosed with the A. pudenda interna (Figure 4/58).

Throughout this course it gave off a collateral branch to the M. retractor penis and branches to the medial wall of the bulbourethral gland (Figure 4/59).

The A. pudenda interna (Figures 3/60, 4/60, 23/60, 42/60) arose as the terminal branch of the A. iliaca interna at the level of the lesser ischiatic notch or cranial to it. It averaged 2.2 mm in its peripheral diameter. From its origin it ran toward the pelvic cavity. It coursed caudoventrally toward the ischial arch. In the female it pursued the retro-peritoneal tissue on the lateral wall of the rectum and vagina. Along its course it gave off the following collateral branches:

The Rami musculares to the M. obturator internus.

The A. urethralis (Figure 23/61) arose from the parent vessel, either independently or by a common trunk with the A. bulbi vestibuli. It arose, in two specimens, by means of a common unilateral (left side) trunk. The A. urethralis coursed cranially toward the lateral wall of the urethra. It ended by means of twigs which anastomosed with those of its opposite side, thereby forming an arterial plexus on the lateral wall

of the caudal third of the urethra. It was observed that a branch, after arising from the A. urethralis, anastomosed with the A. urethrogenitalis (Figures 23/61', 67/61').

The A. bulbi vestibuli (Figure 23/63) at first ran caudally on the lateral wall of the vagina, and then toward the vestibular bulb.

The Rami vestibulares (Figure 23/62') arose immediately after the origin of the preceding vessel. The A. pudenda interna gave off a common branch for the origin of the Rami vestibulares. These branches were directed caudally and toward the M. constrictor vestibuli. Some of them anastomosed with the Rami vestibulares which were given off by the A. perinealis (A. urethrogenitalis). In three specimens the common branch gave off the A. profunda clitoridis. This variation was encountered in one specimen on the right side and in the other two on the left.

The A. profunda clitoridis (Figure 23/62'') arose from the caudal branch of the parent vessel or from the common branch (Figure 23/62) of origin for the Rami vestibulares. It ran ventrally and slightly cranial toward the crura of the clitoris.

The A. dorsalis clitoridis can be considered as a collateral branch from the extrapelvic origin of the A. pudenda interna (Figure 23/68). In fact, it arose from the parent

vessel in the region of the fatty tissue which surrounds, ventrally, the ischial arch. It coursed caudally on the lateral wall of the body of the clitoris and pierced it. In two specimens, it was observed that the A. dorsalis clitoridis of each side arose from a common trunk from the left A. pudenda interna.

The A. pudenda interna ended by anastomosing with the A. pudenda externa. Variations related to the termination of the former vessel were observed. In two of the three cases, the right A. pudenda interna formed an anastomosis with its counterpart, just after leaving the pelvic cavity. In this case, the left vessel, after giving off a common trunk to the A. dorsalis clitoridis, divided into two branches which diverged to anastomose with the branches coming from the A. pudenda externa (Figures 40, 41).

The A. pudenda interna in the male (Figures 3/60, 4/60) supplied, mainly, the penis and the structures related to it. It continued ventrally toward the ischial arch, passing between the bulbourethral gland and the deep face of the M. obturator internus. It was embedded by the fatty tissue of the ischio-rectal fossa and was related cranially to the vein and nerve (N. pudendus). In the specimens in which the V. pudenda interna was double, one of them was cranial to the artery. In its

course, the artery gave off a slender ramifying vessel and finally entered into the M. obturator internus and bulbourethral gland. In two of the five specimens, the A. pudenda interna gave off the A. hemorrhoidalis caudalis. The latter was seen to arise from the caudal wall of the vessel 1 to 1.3 cm from the origin of the parent vessel. The A. pudenda interna, just dorsal to the ischial arch, furnished two main vessels which arose from its cranial and caudal walls. The former proceeded to anastomose with the A. urethrogenitalis along the ventral border of the bulbourethral gland. Variations in its origin have been noted. In one of the five specimens, this branch came from the medial wall of the A. pudenda interna and divided into branches. They anastomosed with the A. urethrogenitalis on the ventral border and behind the posterior end of the bulbourethral gland. In two specimens this vessel came off from the branch which arose from the caudal wall of the A. pudenda interna (Figure 4/66). The latter branch of the parent vessel was relatively larger than the preceding vessel, ran caudally and divided immediately into a cluster of branches medial to the origin of the M. ischiocavernosus. The branches are as follows:

The Aa. bulbi urethrae (Figure 3/61) pierced the urethral bulb after a short course. It supplied the ipsilateral side of

the erectile tissue which forms the bulb, and the cavernosus bodies of the urethra.

The Aa. profundi penis (Figure 3/62) ran caudally and pierced the albuginea of the crus penis on its medial side. They supplied the corpus cavernosus of the penis. In one specimen one of them received a terminal branch of the A. glutea caudalis.

The Rami musculares (Figure 3/63) ran toward the lateral face of the M. bulbo cavernosus and deep face of the M. ischiocavernosus. The Rami perinei (Figure 4/64) arose dorsal to the origin of the Aa. bulbi urethrae. They ran dorsocaudally and passed to the perineal region between the M. retractor penis and the M. sphincter ani externus supplying the M. ischio-urethralis (Figure 4/65). At the level of the caudal third of the bulbourethral gland, communicating branches to the A. urethrogenitalis were given off.

The A. pudenda interna, as it continued on the medial face of the M. ischiocavernosus, gave off a branch directed to the fascia of the scrotum (Figure 3/67). This vessel anastomosed with the caudal branch of the A. pudenda externa. The main vessel then terminated as the A. dorsalis penis (Figure 4/68) in one of the following ways:

In two of the five specimens, the right and left A. pudenda interna coursed on the lateral face on the proximal end of the penis. Approaching the dorsal face of the first bend of the sigmoid flexure they anastomosed and then continued as a single vessel, the A. dorsalis penis.

In one of the five specimens, the right A. pudenda interna became the A. dorsalis penis. Its left counterpart reached the M. ischiocavernosus and pierced the albuginea of the corresponding cavernosus body of the penis.

In two of the five specimens the left A. pudenda interna continued as the A. dorsalis penis, while its counterpart showed the same disposition that the left A. pudenda interna showed in the above mentioned way. In one of the two latter specimens the right A. pudenda interna furnished the anastomotic branches to the A. pudenda externa.

The A. dorsalis penis followed the mid-dorsal face of the penis, medial to its satellite vein (Figures 4/68, 21/68). After passing the second bend of the sigmoid flexure, it divided into right and left branches (Figures 4/69, 21^b/69). The left branch was more developed than its fellow of the opposite side. Each gave off a slender vessel to the M. retractor penis (Figure 4/70) and passed diagonally to the ventral surface of the penis (Figure 22/69). It then coursed

ventrolaterally distal to the fornix of the prepuce where it divided into preputial, superficial and deep branches. The preputial branch (Figure 4/71) pierced the preputial sheath and ran flexuously forward to end in twigs. Some of them anastomosed with the recurrent artery of the sheath of the penis, the A. pudenda externa. The superficial branch (Figure 4/72) followed dorsolaterally distal to the twisted part of the penis. It coursed between the internal (visceral) sheath of the prepuce and the albuginea of the penis. The third or deep branch pierced the albuginea to reach the corpus cavernosus penis (Figure 4/73).

The A. hemorrhoidalis caudalis (Figures 3/75, 23/75) arose either from the A. glutea caudalis, 1 to 1.5 cm from the origin of the latter, or as a collateral branch of the A. pudenda interna. It averaged 1.5 mm in peripheral diameter. In the female, it ran ventrocaudally, passing between the rectum and Mm. obturator internus and ischiococcygeus. It furnished them by means of collateral twigs. After approaching the ventral border of the rectum, the vessel divided into a cluster of branches. They were directed to supply the M. constrictor vulvae and M. vestibuli and M. sphincter ani externus and sphincter ani internus. Some of these branches passed to the perineum.

In the male it supplied the bulbourethral gland (Figure 3/77), the M. bulbocavernosus, the M. ischiococcygeus (Figure 3/78), and the perineum (Figure 3/76) (A. perinei).

Veins

The draining of the venous blood from the mammary gland of the female and the prepuce of the male was accomplished by the tributaries of the Vv. thoracica interna and pudenda externa.

The V. thoracica interna (Figure 8/84). The two tributaries, the V. epigastrica cranialis, from the abdominal wall, and the V. musculophrenica, from the medial side of the costal arch, joined at the level of the last costosternal articulation to form the V. thoracica interna. It coursed as a satellite of the A. thoracica interna under the M. transversus thoracis toward the thoracic inlet. It emptied into the V. cava cranialis, medial to the first rib. In its course, the vein received the veins corresponding to branches of the artery to the mammary gland. By means of these vessels the medial and lateral surfaces of the 1st pair of mammary glands were drained.

The tributaries of the V. thoracica interna. The musculophrenic vein corresponds to the artery of the same name. It drained the lateroventral area of the M. diaphragma and the medial aspect of the costal arch.

The V. epigastrica cranialis (Figures 26/87, 27/87) was much larger than the preceding vein and the V. thoracica interna appeared to be the direct continuation of the former. The V. epigastrica cranialis consisted of two veins, the medial and lateral veins connected by means of anastomotic bridges. Both ran forward on either side of the corresponding artery and anastomosed while approaching the thoracic cavity. Near the entrance of the thoracic cavity, the medial vein received the V. subcutanea abdominis as a tributary vein. The V. epigastrica cranialis received the drainage from the parts of the mammary glands and prepuce (medial roots) which were supplied by the A. epigastrica cranialis. By means of these satellite vessels, it was also connected with the V. subcutanea abdominis (Figures 14/89, 26/89, 28/89). The roots of the V. epigastrica cranialis anastomosed with the roots of the V. epigastrica caudalis.

The V. subcutanea abdominis was a large tributary of the V. epigastrica cranialis, and, in general, did not accompany any artery (Figures 13/97, 26/97). It coursed cranially in the

fatty tissue of the ventral wall of the abdomen. It extended from the interfemoral space and curved slightly laterodorsally toward the infrasternal fossa (Figures 29/97, 30/97). The two Vv. subcutanei abdominis connected by anastomotic bridges (Figures 26/97", 30/97"). Laterally, each received radicles from the caudal root of the V. pudenda externa, V. circumflexa femoris medialis, V. saphena parva and the V. saphena magna (Figures 31/97', 31/97^{v'}, 34/97^{v'}). In its caudocranial course, the V. subcutanea abdominis connected the roots of the cranial tributaries of the V. pudenda externa (Figures 32/20, 33/20). In the female, on its ventromedial side, the vessel was still anastomosed with its counterpart by communicating bridges which form a network in the fatty tissue. They drained the medial and lateral aspects of the mammary gland, the fatty tissue and the skin of the region. In the male, it received a large tributary which drained a large venous pelxus. This plexus surrounded, superficially, the ventral aspect of the preputial cavity (Figure 7/19). In this plexus the radicles, which drained the ventral and lateral aspects of the preputial orifice, converged.

The V. subcutanea abdominis gradually increased in diameter, receiving a lateral vein, from the cranial aspect of the thigh, at the level of the beginning of the "knee" fold. It then continued laterally to the abdominal and thoracic mammary

glands. It collected several tributaries from the lateral aspect of the mammary glands and from the lateral wall of the abdomen (Figures 26/97IV, 35/97IV). Near the infrasternal fossa, it received a tributary (Figures 26/97V, 36/97V, 37/97V) which, after coursing deeper along the median line, became superficial and drained the medial aspect of the 2nd, 3rd and 4th mammary glands. In the male, it drained the fatty tissue, *Mm. praeputiales craniales*, and the umbilicus. This vein, in some specimens, was single and joined either the left or right *V. subcutanea abdominis*. At the level of the infrasternal fossa the latter vessel pierced the muscular wall and joined the medial vein of the *Vv. epigastrici craniales*.

The *V. pudenda externa* consisted of two veins which were connected at places by anastomotic bridges (Figures 7/15, 25/15, 39/15). The veins coursed parallel to the corresponding artery in the inguinal canal. It was observed (Figure 6), in one of ten specimens, that the right vessels were tributaries of the *Truncus pudendoepigastricus*, while those of the left side joined the *V. iliaca externa* and *V. femoralis*. In four specimens, the vessels of both sides were affluents of the *V. femoralis* and the *V. profunda femoris*. In two specimens, the right vessels showed the same disposition as the preceding vessels, while their counterparts joined the *V. femoralis*. In

one specimen, the right vessels emptied into the V. profunda femoris, whereas the left vessels discharged into the V. femoralis and the V. profunda femoris. In one specimen, the right vessels joined the V. femoralis while their counterparts terminated in the V. femoralis and V. profunda femoris. In the last specimen, the right vessel emptied in the V. femoralis and V. profunda femoris whereas the left vessels were tributaries of the Truncus pudendoepigastricus.

In the female, the cranial and caudal vessels joined the V. pudenda externa, medial to the Lnn. inguinales superficiales, (Figures 25/16, 25/21, 39/16, 39/21). The cranial root was composed of two vessels placed on each side of the lateral cranial branch of the A. pudenda externa. The venous radicles followed, generally, the course and ramifications of the satellite artery and anastomosed with the V. subcutanea abdominis and Vv. epigastrici cranialis.

The cranial root coursed deeper in the fatty tissue, lateral to the rows of the mammary glands. It received two tributaries which coursed craniodorsolaterally to the median line. They drained the lateral and medial aspects of the three mammary glands and connected the V. pudenda externa to the V. subcutanea abdominis (Figures 26/20, 32/20, 33/20). They may be considered as mammary veins, in agreement with Bickhardt (1961).

Near the Lnn. inguinales superficiales, the cranial root also received tributaries which followed the ramifications of the middle cranial and medial cranial branches of the A. pudenda externa.

The right and left caudal roots of the V. pudenda externa were formed by a common trunk (Figures 40/25, 41/25). The latter anastomosed with the V. pudenda interna in the perineal region and received a single vessel which drained the fatty tissue and the perivulvar tissues (Figure 38/82). Each caudal root coursed forward in the interfemoral space. It received, laterally, affluents which drained the subcutaneous tissue of the dorsomedial side of the thigh. By means of the affluents the vessel was anastomosed with the V. subcutanea abdominis, V. profunda femoris, V. circumflexa femoris medialis and V. saphena parva. On its medial side, it connected with its counterpart by anastomotic bridges. The caudal root, in its further course, accompanied the caudal branch of the A. pudenda externa to the inguinal region where it became a paired vessel. It received a tributary which came from the fatty tissue and from the Lnn. inguinales superficiales.

In the male, three tributaries, the lateral cranial, the medial cranial, and the caudal roots, usually joined the V. pudenda externa medial to the Lnn. inguinales superficiales (Figures 7/16, 7/18, 7/21).

The lateral cranial root was poorly developed. Its course and distribution were similar to those of the cranial root of the V. pudenda externa in the female.

The left medial cranial root and the right one were satellites of the corresponding branches of the A. pudenda externa. The distribution of these roots accompanied the ramifications of the corresponding artery. In the specimens in which the medial cranial branch of the A. pudenda externa was better developed, the vein extended from the superficial ventral aspect of the preputial cavity. It coursed parallel to the satellite artery in the septum of the preputial diverticulum. Further, it continued laterally to the preputial sheath of the penis to the inguinal region. Variable numbers of radicles, from the venous plexus of the preputial cavity (Figure 7/19), joined the medial cranial branch of the V. pudenda externa.

This venous plexus may be regarded as the ventral venous plexus of the sheath of the bovine penis (Ashdown, 1958). The plexus was laid around the preputial orifice and extended caudally between the two recurrent arteries of the sheath. At the level of the fornix, slender radicles connected the plexus with the ventral branch of the V. dorsalis penis. The medial cranial root drained the fatty tissue, the skin, the preputial tissues of the preputial cavity, the sheath of the penis and

the middle and cranial parts of the suspensory ligament of the penis, and was connected with the V. subcutanea abdominis.

The caudal root (Figures 7/21, 9/21) coursed parallel to the satellite artery, enclosed in the fatty tissue of the interfemoral space. It extended from the septum scroti to the inguinal region, crossing the medial aspect of the spermatic cord. Two veins, the lateral and medial roots, joined the caudal root of the V. pudenda externa in the septum scroti. The distribution of these roots followed the course and ramifications of the accompanying caudal branch of the A. pudenda externa. A large radicle, which drained the tissues around the insertion of the M. cremaster externus, joined the caudal root at the level of the cranial aspect of the septum scroti. Near the caudal border of the spermatic cord it received the scrotal root of the V. pudenda interna (Figure 7/25). The caudal root, in its further course, was connected with its counterpart and collected a superficial tributary which drained in the scrotal fold and anastomosed with the roots of the V. subcutanea abdominis, V. circumflexa femoris medialis and V. profunda femoris. Before reaching the inguinal region the vessel became paired and the corresponding vessels were placed on either side of the satellite artery. They received radicles which came from the Lnn. inguinales superficiales.

The V. spermatica externa (Figure 7/12) drained the M. cremaster externus in both the male and female. It coursed craniodorsally along the M. cremaster externus. The distribution of its radicles was similar to that of their satellite arteries. In the male the radicles were connected with the radicles of the caudal root of the V. pudenda externa. In its cranial third the V. spermatica externa usually became a paired vessel. It joined the V. pudenda externa. In one out of ten specimens, the vessel of the right side joined the V. circumflexa ilium profunda.

The venous drainage of the testicle, epididymis and ductus deferens was performed by the V. spermatica interna and the V. deferentialis.

The V. spermatica interna (Figure 7/5), one of the components of the spermatic cord, consisted of various vessels which extended craniodorsally to the vertex of the pampiniform plexus through the inguinal canal. The vessel coursed cranio-laterally to the seminal vesicle. In this course it was embedded in the plica vasculosa and connected the V. deferentialis by a communicating branch. The V. spermatica interna then passed medial to the ureter receiving the V. vesicalis craniales. The V. spermatica interna may join the V. iliaca communis and the V. cava caudalis or the V. circumflexa ilium

profunda. In three out of five specimens, the *V. spermatica interna* on both sides, joined the *V. cava caudalis*; in one specimen the right vessel joined the *V. iliaca communis* while the left went to the *V. cava caudalis*; and in the last specimen the left vein joined the *V. circumflexa ilium profunda* and the right one terminated in the *V. cava caudalis*. The pampiniform plexus (Figures 7/7, 17/7) was formed by numerous radicles which were derived from the testicle and the epididymis. The radicles of the testicle (*Vv. testiculares*) (Figure 7/8) ran parallel into the albuginea at the lateral and medial faces of the testicle toward its cranial border. At this point they became flexuous and joined the radicles coming from the medial face of the epididymis to form a complicated venous network arrangement, which enlaced the tortuous course of the *A. spermatica interna*.

The *V. deferentialis* drained the ductus deferens (Figure 7/36). It coursed along with the satellite artery in the inguinal canal in a craniodorsal direction to the abdominal cavity. In its course, it was connected with the satellite vein of the deferential branch of the *A. urethrogenitalis*. The *V. deferentialis*, after leaving the inguinal canal, gave off an anastomotic vein to the *V. spermatica interna*. In the abdominal cavity, it was seen accompanied by the corresponding

artery on the lateral face of the ligament of the urinary bladder. At the level of the dorsal border of the ureter it turned cranially and joined the V. vesicalis craniales (Figure 7/35). Before reaching the dorsal border of the ureter the V. deferentialis received a slender tributary which drained the tissues surrounding the A. deferentialis.

The V. utero-ovarica in the female corresponds to the V. spermatica interna in the male (Figures 25/5, 54/5, 62/5, 63/5). It drained a pampiniform plexus found near the ovary. The V. utero-ovarica coursed in the anterior border of the broad ligament of the uterus, embedded with its satellite artery. It followed the deep face of the ureter to join either the V. cava caudalis or the V. iliaca communis, or in one out of five specimens, it was noticed that the right V. utero-ovarica emptied directly into the V. iliaca communis. In one out of four specimens examined, the left vein joined the V. uterina media and the latter then drained into the V. iliaca communis. The pampiniform plexus is a triangular, vascular body embedded in the broad ligament of the uterus (Figures 25/7, 56/7, 57/7, 61/7). It faced the ovary and the vertex is continued dorsally in the V. utero-ovarica. Small radicles from the roots of the V. uterina media and satellite radicles of the branches of the A. utero-ovarica constituted the

pampiniform plexus of the ovary. The course and disposition of these radicles resembled those of the satellite arteries.

The V. uterina media (Figure 5/36) coursed parallel to the homologous artery embedded in the broad ligament of the uterus. It accompanied the deep face of the ureter close to the V. utero-ovarica to empty into the V. iliaca communis. In one out of five specimens examined, the left veins joined the V. utero-ovarica.

The roots of the V. uterina media had a conspicuous arrangement in the distal third of the broad ligament. They became plexiform and enlaced the branches of the satellite arteries. In the virgin uterus, it was possible to recognize that usually two roots, the caudal and the cranial, joined the V. uterina media (Figures 25/36', 25/36'', 62/36', 63/36''). The former coursed from the ventrocaudal third of the body of the uterus parallel to the A. uterina caudalis. Its radicles anastomosed with those which corresponded to the V. uterina caudalis and with the fellow of the opposite side along the ventral wall of the body of the uterus. It thus drained the caudal and middle thirds of the uterus. In its cranial course in the broad ligament, the caudal root received a large tributary which extended from the cranial third of the ventral face of the body of the uterus. The radicles of this branch formed

arcades on the mesometrial border of the uterine horn. Numerous rootlets (Ramuli uterini) from the wall of the uterine horn drained into these arcades.

The cranial root ran ventrally, contained within the broad ligament. Several radicles which extended from the cranial, middle and caudal aspects of the uterine horn converged to the cranial root. These radicles, like those of the caudal root, formed arcades which drained the wall of the uterine horn (distal arcades of Barone, et al. 1962). The most cranial radicles anastomosed with those of the V. utero-ovarica along the uterine tube and on the tip of the uterine horn. Between the cranial and caudal roots and the radicles of the Rami cervico-uterini (V. uterina media), anastomotic bridges could be seen.

The V. urethrogenitalis (Figure 7/40, 25/40), a large tributary of the V. iliaca interna, coursed within the retroperitoneal fatty tissue located laterally to the rectum. The vein joined the ventral wall of the V. iliaca interna at the point where the latter approached the pelvic cavity. Two roots, the cranial and caudal, joined the V. urethrogenitalis (Figures 7/41, 7/51). The distribution of the cranial and caudal roots of the V. urethrogenitalis followed, in general, the ramifications of the satellite arteries.

In the male the cranial root (Figure 7/41) arose from the lateral and ventral aspects of the seminal vesicle, (Figure 7/49), the ductus deferens (Figure 7/50), the prostate gland (Figure 7/42), and the cranial third of the urethra (Figure 7/47). Several interlobular radicles of the seminal vesicle joined it at the ventrolateral aspect (Figure 7/49). They drained the lateral and medial aspects of the glandular structure. Numerous small rootlets joined these radicles. The rootlets arose from the venous plexus which was formed on the dorso-lateral aspect of the urethra and prostate gland (Figure 7/46). The caudal root (Figure 7/51) was larger than the cranial and was assumed to be the main root of origin. The disposition of its radicles was intricate, but the distribution of the caudal roots followed the same pattern as that of the corresponding satellite arteries. A large prostatic radicle (Figure 7/52), which coursed craniocaudally drained the prostate gland to join the caudal root. This vein received several radicles from the dorsolateral aspect of the seminal vesicle. Its rootlets were connected to those of the cranial root and also to the urethral plexus.

Two larger radicles, which coursed along the lateral and medial faces of the bulbourethral gland, joined the caudal root. The lateral radicle coursed on the lateroventral aspect

of the bulbourethral gland (Figure 7/53). It drained the lateral aspect of the gland and the middle and caudal thirds of the urethra. Its rootlets anastomosed with those of the V. pudenda interna and with the Ramus obturatorius of the V. profunda femoris. The medial radicle (Figure 7/58) drained the medial side of the bulbourethral gland. It received a tributary from the M. retractor penis. Both the right and left radicles were connected by anastomotic rootlets forming a plexus between the glands.

The urethral plexus (Figures 7/46, 25/46) is formed by the radicles which drained the lateral and dorsal aspects of the cranial and middle thirds of the urethra. It was drained by the rootlets of the V. vesicalis cranialis and the cranial root of the V. urethrogenitalis. Its middle third was drained by the rootlets from the caudal branch of the V. urethrogenitalis and ventrolaterally by the rootlets of the V. obturatoria and to the Ramus obturatorius from the V. profunda femoris.

In the female, the V. urethrogenitalis, similar to that of the male, was formed by two roots, the cranial and caudal roots (Figures 25/41, 25/51). The course of the cranial root and the distribution of its radicles was similar to those of the satellite arteries (Figure 64/41). The uterine radicles drained the cervix of the uterus and anastomosed with the radicles of the

V. uterina media, forming the V. uterina caudalis (Figure 25/50'). The vesicular radicles (Figure 25/47) (V. vesicalis caudalis) drained the cranial third of the female urethra and anastomosed with those of the V. vesicalis cranialis and with the radicles of the V. ureterica. Communicating veins were seen to anastomose with the V. obturatoria, V. pudenda interna and with those of the Ramus obturatorius from the V. profunda femoris (Figure 25).

The course and distribution of the caudal root resembled those of the satellite artery (Figure 65/51). It drained the vagina and the cranial portion of the vestibule of the vulva. The Vv. perinei, satellites of the corresponding arteries, joined the V. hemorrhoidalis caudalis and were anastomosed with the rootlets of the vein which superficially drained the perivulvar tissues (Vv. caudales laterales) (Figure 25/82).

The V. pudenda interna was one of the largest tributaries of the V. iliaca interna. In the male (Figure 7/60), it was formed at the level of the dorsomedial aspect of the first bend of the sigmoid flexure of the V. dorsalis penis. From its origin the V. pudenda interna continued dorsally along the medial aspect of the M. ischiocavernosus. In this course, it received a tributary from the caudal branch of the V. pudenda

externa which drained the scrotum (Figure 7/67). Then the right and the left vessels anastomosed forming a venous plexus which extended to the ischial arch. On its caudal aspect, the plexus received a common trunk, which drained the V. profunda penis (Figure 7/62), the Vv. bulbourethrae (Figure 7/61), and the radicles from the Mm. ischiocavernosus and bulbocavernosus (Figure 7/63). The V. pudenda interna continued its course towards the pelvic cavity. After approaching it, the vein usually became a paired vessel and ran parallel to the satellite artery, lateral to the bulbourethral gland and rectum. In this course, it received, on its cranial aspect, a tributary which drained the ventrolateral aspect of the bulbourethral gland and caudal third of the urethra (Figure 7/66). The rootlets of this vein were connected with those of the V. urethrogenitalis and it received, caudally, the Rami perinei (Figure 7/64) and the radicles from the M. bulbocavernosus. The V. pudenda interna gave off a communicating tributary to the Ramus obturatorius of the V. profunda femoris (Figure 7/60'). This vessel drained the M. obturator internus and the fatty tissue of the ventral wall of the pelvic cavity and was connected with its fellow of the opposite side, under the cranial third of the pelvic part of the urethra. The V. dorsalis penis (Figure

7/68, 20/68) drained the body of the penis. It coursed on the dorsal aspect of it medial to the satellite artery. Two tributaries, the dorsal and ventral roots from the distal end of the penis, joined the V. dorsalis penis at the middle third of the penis (Figures 22/68', 22/69"). The dorsal root ran superficially along the dorsal aspect of the penis and drained the albuginea of the corpus cavernosum of the penis. Some radicles pierced the albuginea in the erectile tissue. The ventral root coursed along the ventral aspect of the corpus cavernosum urethrae. At the level of the fornix of the prepuce it was connected with branches of the V. pudenda externa. In the female, the course and distribution of the V. pudenda interna vein were similar to those of the corresponding artery (Figure 25/60). In general, it arose anastomosed in common with the deep radicles of the caudal root of the V. pudenda externa (Figures 40/25, 41/25). The V. pudenda interna ran dorsally towards the pelvic inlet. In this course, it received a tributary which drained the perivulvar veins (Figures 25/82', 38/82'). Near the ischial arch it received the V. dorsalis clitoridis (Figure 41/68). Then the V. pudenda interna divided into right and left vessels. Each usually became paired and extended to the lesser ischiatic notch. They passed laterally to the vagina and rectum within the retroperitoneal fatty

tissue. In this course they received the tributaries which corresponded to the satellite arteries. By means of them the V. pudenda interna drained the vulva, the cavernosus bodies of the clitoris and the caudal third of the urethra, and was anastomosed with the V. urethrogenitalis. A large vessel from the V. pudenda interna joined the Ramus obturatorius of the V. femoris profunda (Figure 25/60'). This vessel passed through the fatty tissue along the ventrolateral wall of the pelvic inlet. It received several radicles as tributaries which drained the fatty tissue of the region of the M. obturator internus.

The V. hemorrhoidalis caudalis (Figures 7/75, 25/75) coursed parallel to the satellite artery in the ischiorectal fossa. It may drain either into the V. pudenda interna or into the V. glutea caudalis. This variation depended on the pattern of the satellite artery. In the male, it supported the draining of the Mm. bulbocavernosus, the sphincter ani externus, the perineum, and the dorsolateral aspect of the bulbourethral gland. In the female, it drained the vestibule of the vulva, the perineum, the Mm. sphincter ani externus and the constrictor vestibuli. The rootlets of this vein joined the rootlets of the vein which drained the perivulvar tissues externally (V. caudalis lateralis).

DISCUSSION

The terminology regarding the vessels of the genital tract of the domestic animals is variable. This study confirms that the blood supply of the genital tract of the swine is derived mainly from four sources, namely the A. spermatica interna, the A. umbilicalis, the A. urethrogenitalis and the A. pudenda interna. The A. spermatica interna arises from the Aorta abdominalis while the remaining vessels are derived from the A. iliaca interna (A. hypogastrica). The accessory organs associated with the genital system, such as the mammary glands, the prepuce and the scrotum are supplied by branches of the A. thoracica interna and the A. profunda femoris.

The A. thoracica interna (internal thoracic artery) has been described as arising from the A. brachialis (A. subclavia) medial to the first rib (Montané, 1920; and Kähler, 1960). According to Kähler (1960), the vessel gives off the Rami intercostales laterally and the Rami sternales medially. He reports also that the vessel ends at the level of the 6th rib as the A. musculophrenica (musculophrenic artery) and the A. epigastrica cranialis (cranial (anterior) abdominal artery). The findings of the present study agree with this part of the description of Kähler, however, it should be mentioned that the

termination of this vessel (right and left) was extremely variable. The *A. thoracica interna*, in fact, terminated at the level of the 4th intercostal space, at the 5th rib, the 5th intercostal space, close to the attachment of the *M. diaphragm* or 1 cm after that as the parent vessel left the thoracic cavity.

It was observed that the *Rami intercostales* of the *A. thoracica interna* anastomosed with the ventral branches (*Rami ventrales*) of the *Aa. intercostales*. Those which correspond to the 4th and 5th *Rami intercostales* in this form exclusively supply the cranio-lateral aspect of the first thoracic mammary complex, while the caudomedial side of the same pair is supplied directly by the *A. thoracica interna* through its *Rami sternales*. Kähler (1960) found the same disposition regarding the pattern of these vessels, however, he reports, in agreement with Montané (1920), that the *A. thoracica externa* contributes to the first mammary complex as well.

The arterial contribution of the *A. thoracica externa* to the first mammary gland is a matter of controversy. Sisson and Grossman (1953) report that this vessel is sometimes absent. St. Clair (1958) states that perhaps the vessel supplies the thoracic mammary glands. In this study it was not possible to trace, definitively, the branches of the *A. thoracica externa*

to the first mammary gland. This vessel, in the specimens studied, was present and terminated after forming a cluster of finer branches which extended to the middle third of the pectoral muscles. There is no discrepancy as to the disposition of the A. epigastrica cranialis and its collateral branches, the lateral and the medial branches. Kähler (1960) states that the A. epigastrica cranialis terminates after anastomosing with the A. epigastrica caudalis. He also mentions that the lateral branches anastomose with the ventral branches of the Aa. intercostales as well as with the cranial branch of the A. phrenoabdominalis. In the present study anastomoses were observed: a. between the terminal branches of the A. epigastrica cranialis and those which correspond to the A. epigastrica caudalis, caudal to the umbilicus; b. between the lateral branches and the ventral branches of the Aa. intercostales in the cranial third of the hypochondriac region; c. between the lateral branches and the twigs of the cranial branch of the A. phrenoabdominalis in the ventral aspect of the hypochondriac region; d. between the A. epigastrica cranialis and the A. circumflexa ilium profunda in the ventral aspect of the flank; and, e. between the medial branches and the lateral cranial and middle cranial branches of the A. pudenda externa.

According to Kähler (1960) the blood supply of the abdominal complex of mammary glands is accomplished by means of the medial branches of the A. epigastrica cranialis and the cranial branches of the A. pudenda externa (lateral cranial, middle cranial and medial cranial branches). He states that the first two pairs of abdominal mammary glands are exclusively supplied by the medial branch of the A. epigastrica cranialis, while the last pair is supplied by the cranial branch of the A. pudenda externa. The contribution of the A. epigastrica cranialis to the prepuce has not been reported. In all cases the arterial pattern concerning the abdominal mammary glands agrees with the descriptions of Kähler (1960), but it should be emphasized that in the male the A. epigastrica cranialis, as cutaneous branches, supplies the lateral aspect of the prepuce.

The A. profunda femoris (deep femoral artery) contributes to the accessory genital organs by means of its branches, the A. spermatica externa and the Truncus pudendoepigastricus. The Truncus pudendoepigastricus supplies the mammary gland (female) or the prepuce and scrotum (male) through one of its terminal branches, the A. pudenda externa.

Individual variations in the origin of the A. pudenda externa (external pudic artery) and the A. spermatica externa

(external spermatic artery) account for many of the minor discrepancies with other authors. Ellenberger and Baum (1943), Martin (1923), Mannu (1930), and Getty (1955) agree that the *A. spermatica externa* and the *A. pudenda externa* may arise from the *A. profunda femoris* by means of the *Truncus pudendoepigastricus* (prepubic artery), or separately when the referred to trunk is absent. Ellenberger and Baum (1943), Martin (1923), and Mannu (1930) state that the *A. spermatica externa* is absent in the female. In this study it was observed, with regard to the *A. spermatica externa*, that there are four patterns as far as the origin is concerned. In fact, the vessel arose from the *A. profunda femoris* in front of, close to, or separately from the origin of the pudendoepigastric trunk, or caudal to it. (Type I), from the cranial or medial wall of the trunk; (Type II), from the *A. circumflexa ilium profunda*; (Type III), from the *A. pudenda externa* (Type IV). In all cases under investigation the *A. spermatica externa* was seen to supply the *M. cremaster externus* in both the male and female. The latter account agrees with that of Bickhardt (1961).

The *A. pudenda externa* (external pudic artery) has been described as a continuation of the pudendoepigastric trunk, or as a collateral branch of the *A. profunda femoris* when the

former is absent (Ellenberger and Baum, 1943; Martin, 1923; and Getty, 1955). Variations regarding its origin also have been reported. Ellenberger and Baum (1943) and Martin (1923) state that the vessel arose from the *A. circumflexa ilium profunda*. Although the vascular patterns of the genital tract were variable, in this study the variations reported by Ellenberger and Baum were not found. In all cases, the *A. pudenda externa* and its fellow, the *A. epigastrica caudalis*, arose as the terminal branch of the pudendoepigastric trunk. It seems that the latter account could be applicable as a general pattern of this vessel.

It was observed, in the female, that the *A. pudenda externa* ended in three cranial branches, and another branch directed caudally. In all cases the site of termination of the *A. pudenda externa* was medial to the *Lnn. inguinales superficiales* (*Lnn. supramammarii* in the female). This observation agrees with those of Kähler (1960) and Bickhardt (1961) who reported the same pattern in the male. The findings of this investigation did not correspond with the description of the male. The *A. pudenda externa*, in all male specimens, as a rule terminated in four branches, either left or right side, in which the medial cranial branch did not give rise to the recurrent arteries of the sheath of the penis.

The *A. pudenda externa*, in agreement with Kähler (1960), and Bickhardt (1961), supplied the last abdominal and inguinal mammary complexes in the female. Its caudal branch joined the *A. pudenda interna* in the perineal region. Sisson and Grossman (1953) state that in the male the *A. pudenda externa* gives off branches to the prepuce and preputial bursa but not to the penis. Kähler (1960) summarizes that the middle cranial branch supplies the prepuce. Bickhardt (1961), however, in a controversial statement, pointed out that the prepuce and the "preputial sac" are supplied by the medial cranial branch of the *A. pudenda externa*.

From the above exposition, it would appear that the arterial contribution of the *A. pudenda externa*, in supplying the prepuce, is a matter of controversy. However, in all cases dissected in this study, the medial cranial branch assumed the blood supply of the prepuce and preputial diverticulum. This is in agreement with Bickhardt (1961), but there are several features worth stressing here. First, the left and right vessels were different sizes. In three specimens the right vessels were better developed than their counterparts, while in the other two specimens, the left vessels were larger.

Secondly, both vessels were directed toward the preputial diverticulum. Near the origin of the *M. retractor penis*, the vessel, which was poorly developed, ended by means of twigs, whereas its counterpart continued forward, piercing the dorsal edge of the preputial diverticulum, to divide at an acute angle into two terminal vessels.

Thirdly, each terminal vessel gave off two principal groups of slender branches, directed cranially and ventrally. The former anastomosed with the collateral branches of the *A. epigastrica cranialis* and the latter ran along the ventral wall of the prepuce and anastomosed with the fellow of the opposite side, forming a semicircle around the preputial orifice.

Fourth, the main vessel, after giving off the above mentioned arteries, described a bend and continued along the preputial sheath to ramify and finally anastomose with the terminal branches of the *A. dorsalis penis*. Since this disposition resembles that described by Ashdown (1958) in the bovine, this artery may be considered as the recurrent artery of the sheath of the penis.

The caudal branch of the *A. pudenda externa* supplies the perineal region in the female and is anastomosed with the *A. pudenda interna*. This observation is in agreement with Getty, (1955), Kähler (1960), and Bickhardt (1961). In the male, it

supplies mainly the scrotum, and in the male is also anastomosed with collateral branches of the A. pudenda interna up to the scrotal septum (Getty, 1955).

The blood supply to the testicle and epididymis is accomplished by means of the A. spermatica interna and the A. deferentialis. In all cases the A. spermatica interna was found to be the arterial source to the testicle and the head and body of the epididymis, while the part corresponding to its tail was mainly supplied by the A. deferentialis and branches which arose from the anastomosis of the A. spermatica interna and A. deferentialis (A. accessoria testicularis) inside the inguinal canal.

Considering that the pattern of origin and disposition of the A. spermatica interna inside the abdominal cavity resembles that of the other domestic animals, the accounts of Sieber (1903) and Mannu (1930) (that the A. spermatica interna in the male pig arises from the Aorta abdominalis), and those of Chauveau (1889), Martin (1923), Ellenberger and Baum (1943), and Sisson and Grossman (1953) (that the A. spermatica interna in swine resembles that of the horse) were confirmed, while it is true that the vessels arise from the ventral wall of the parent vessel before the A. mesenterica caudalis. Moreover,

there is clear evidence that in all cases the right vessels were more cranial than the left. The same is also true in the castrated animals. However, in the noncastrate the latter vessels were larger than the right ones.

This variation in size may be in relationship to the weight of the testicle, since it has been reported that the weight of the testicles of nine animals was variable, in seven out of nine specimens, the left ones were the larger (McKenzie, et al., 1938). Likewise, it could be noted that the A. spermatica interna usually gave off the Ramus uretericus to the ureter and coursed into the plica vasculosa (peritoneal fold) in the lateral side of the seminal vesicle.

It is generally agreed that the A. spermatica interna describes a tortuous course in the inguinal canal forming an arterial cone (Montané, 1920; Beutler, 1926; and Harrison, 1949). In all cases this conspicuous disposition was observed. Slender branches were given off from the dorsolateral aspect of the arterial cone. In agreement with Beutler (1926), these branches were seen to overlap the arterial cone and extend to the medial face and head of the epididymis. It was noted that those which were placed dorsally to the arterial cone anastomosed with the terminal branches of the A. deferentialis to form the A. accessoria testicularis.

Regarding the termination of the *A. spermatica interna* in the domestic animals, including the swine, there is no complete agreement of the nomenclature. Beutler (1926) uses the term *A. testicularis* to describe the vessel which continues from the arterial cone to the testicle. Sisson and Grossman (1953) consider the vessel as the *A. spermatica interna* even up to the testicle. They state that the collateral branches of it are embedded in the tunica albuginea. According to the latter description it should be assumed that the *A. spermatica interna* is not embedded deeply in the albuginea. This is also true in the swine. In fact, the *A. spermatica interna* in the male hog, after leaving the arterial cone, passed under the epididymis toward the caudal (dorsal) pole of the gland covered by scanty fibrous connective tissue. In one specimen it gave a collateral branch directed to the lateral and medial face of the gland. This is in agreement with the observations of Beutler (1926) who describes this disposition as the arterial pattern in the swine (Figure 15b). After it reached the caudal pole, it made a bend ventrally and pierced the albuginea layer. Hill (1905) uses the term "capsular artery" for the branches of the *A. spermatica interna* which are embedded in the albuginea. Hofmann (1960) refers to these vessels as the *Aa. testiculares* in the bull. According to Hofmann (1960) the *A. spermatica*

interna ends at the point where it pierces the albuginea layer. The term Aa. testiculares was adopted in this study.

The arterial supply of the parenchyma of the testicle in the pig has been described by Hill (1905). According to him the capsular arteries (Aa. testiculares of Hofmann) give off, at a regular distance, a tortuous, rib-like vessel which penetrates the gland in a perpendicular direction to the mediastinum testes. He calls these vessels "perpendicular arteries" and adds that in a very few cases no branches are given off for these vessels. He points out that near the center of the gland the perpendicular arteries make an abrupt retro-flexion, giving off many branches which course toward the periphery of the organ. He designates these vessels as ascending branches of the perpendicular arteries. He describes various types of arterial loops which form the above mentioned arteries. Although the findings of this study agree, in part, with the descriptions of Hill (1905), the nomenclature used to describe them is that which Hofmann (1960) used to interpret the arterial pattern in the bull. The present study shows that there are, undoubtedly, a radiate disposition of the vessels which arise from the Aa. testiculares, if the testicles are considered to be ovoid in outline. The term Aa. radiatae testes, therefore, is clear and logical, as are also those

terms referred to as the Aa. centripedales and Aa. centrifugales (Figure 16).

Hill (1905) describes six types of arterial loops in the mediastinum testes formed by the Aa. radiatae testes. In this study, however, only five of Hill's types were found and in addition, other types have been recorded (Figures 18, 19, 20). It is interesting to note that the Aa. radiatae testes are anastomosed with their counterparts forming arcs (Figure 18). From these arcs Aa. centrifugales are given off (Figures 18 and 19) or sometimes showed a conspicuous disposition (Figure 20).

It is agreed that the A. deferentialis in the pig resembles that in the bovine (Chauveau, 1889; Ellenberger and Baum, 1943; Sisson and Grossman, 1953; and Dobberstein and Koch, 1958). This study showed that there are several features related to this vessel in the pig. The A. deferentialis described a twisted course around the A. umbilicalis. It gave off the Ramus uretericus and finally, after approaching the inguinal canal, divided, first into two branches, and then successively into numerous branches. Some of them anastomosed with the branches of the A. spermatica interna to form the A. accessoria testicularis. In all cases the vessel extended to the tail of the epididymis. It mainly supplied this part of the epididymis. This is in agreement with Sieber (1903) and

Tanudimadja (1963) who report that the vessel supplies the epididymis in the bull and ram respectively. The account of Magilton (1964), that in two specimens in the goat the vessel does not extend to the epididymis, was not confirmed in this study on the pig.

As it was pointed out, there are considerable differences in terminology regarding the corresponding vessel of the *A. spermatica interna* in the female hog, but because of the area supplied and the arrangement of the vessel the term *A. utero-ovarica* (Mannu, 1930; Sisson and Grossman, 1953; and Barone, et al., 1962), was adopted for the *A. spermatica interna* in this study. This vessel, in fact, supplies the ovary, the bursa ovarica, the fimbria, and the cranial and middle thirds of the uterine tube, and is anastomosed with the *A. uterina media* throughout its terminal branches. Likewise, there are divergences in regard to the disposition and terminology of the *A. utero-ovarica* and its terminal branches. However, in the following account, based on the present study, the *A. utero-ovarica*, in agreement with Lange (1959), gave off the *Ramus uretericus* (the *A. ureterica* of Sieber, 1903) directed to the ureter and finally divided in a cluster of branches. It has been previously described that one courses tortuously in a cranioventral direction to the hilus of the ovary, and was

considered as the *A. ovarica*. This term is comparable to the *Ramus ovaricus* (Sieber, 1903; Ellenberger and Baum, 1943; Dobberstein and Koch, 1958; and Mechaelov, 1963). The other branches, of the area supplied and the disposition of them, were considered by the author as *Rami tubouterini* and correspond to the *Ramus uterinus* of Sieber (1903), Ellenberger and Baum (1943), Dobberstein and Koch (1958), and Mechaelov (1963); the *A. uterina cranialis* of Sisson and Grossman (1953); the *A. tubouterina* of Barone, et al. (1962); or the *Rami uterini* of Lange (1959).

The term *Rami tubouterini* has been adopted by the author in this present study on the basis of the following. The caudal branches, which are generally impossible to trace by gross dissection because of their complicated disposition, appear to be one branch (*Ramus uterinus* of Sieber, 1903; Ellenberger and Baum, 1943; Dobberstein and Koch, 1958; the *A. uterina cranialis* of Sisson and Grossman, 1953; and the *A. tubouterina* of Barone, et al., 1962). Macerated specimens, however, showed that it consists of several branches which arose at the same point, one after the other, and split immediately, forming a complicated arterial meshwork (Figures 45, 46). According to this, and in view of the fact that some of these branches are anastomosed with the cranial branches of the *A. uterina media*,

Lange (1959) called them Rami uterini. From the above mentioned arterial meshwork several branches are directed to the ovary, bursa ovarica, the uterine tube and its parts (Fimbria, Infundibulum tubae uterinae) and it supplies the tip of the uterine horn through its anastomoses with the cranial branches of the A. uterina media. The term Rami uterini does not agree with the disposition of the caudal branches of the A. utero-ovarica, and, therefore, it has been assumed that Rami tubouterini is the more appropriate. The description suggested by Mechaelov (1963) of the A. utero-ovarica is not logical from the above standpoint.

The distribution of the arteries of the ovary in the sow has been described in detail by Andersen (1926). According to her, each terminal vessel of the ovarian artery (A. utero-ovarica) divides at the hilus of the organ into two to four branches. She states further that these vessels are difficult to trace, however, she points out that these vessels break up into many capillaries while approaching the follicles. Reynolds (1947) describes these vessels as "spiral arteries" of the ovary in the rabbit. He adds that each spiral artery forms a helix of diminishing diameter lying along the length of the ovary. In all cases the corkscrew-like vessel was found, and from this vessel other slender vessels were given off. The latter, after a tortuous course, split up into many branches

which formed an arterial wreath around the follicles (Figure 49). Andersen (1926) reports that there are two wreaths of vessels around the follicles, when the theca interna has been differentiated from the theca externa and, according to her, these two wreaths form the follicular blood supply. In this study it was only possible to distinguish those belonging to the theca externa. It was not possible to demonstrate the wreath which corresponds to the theca interna. It is assumed that this wreath is composed mainly of arterioles and venules (Andersen, 1926) and that the injection media failed to fill them.

In all cases the A. uterina media, which is homologous to the A. deferentialis in the male, was the principal arterial supply to the uterus. The A. uterina media (A. uterina of Montane', 1920; Lange, 1959; Preuss, 1959; and Barone, et al., 1962) arose from the A. umbilicalis as a visceral branch of the A. iliaca interna (A. hypogastrica). Sisson and Grossman (1953) and Barone, et al. (1962) agree that the A. uterina media does not seem to arise in a common trunk with the A. umbilicalis from the A. iliaca interna. There was considerable evidence that the vessel emerged from the cranial wall of the A. umbilicalis, 1.5 to 2.5 cm from the origin of the latter. This is further

confirmed by the findings of Sieber (1903), Dobberstein and Koch (1958), and Lange (1959). The A. uterina media was embedded in the broad ligament of the uterus and, coursed in a cranioventral direction. During its course it gave off the Ramus uretericus. Lange (1959) and Barone, et al. (1962) have confirmed this account, however, Barone, et al. (1962) uses the term A. ureterica media instead of Ramus uretericus. In this study the term Ramus uretericus was adopted, in agreement with Lange (1959).

There has been discrepancy as to the termination of the A. uterina media. According to Boye (1956) the vessel ends in two branches, the Rami cornualis. Lange (1959) reports that the parent vessel divides into three or four branches, namely, Rami uterini, whereas Barone, et al. (1962) makes no concise statement about its termination in the sow. He specifies that the vessel divides into two branches, the middle artery of the uterine horn and the caudal artery of the matrix. The latter soon divides further into two branches. He finally concludes that the A. uterina media terminates into three branches, the middle artery of the uterine horn, the caudal artery of the uterine horn and the artery of the body of the uterus. It can be seen that the nomenclature of this area is not clear and is complicated. In this study the arterial arrangement of the A.

uterina media terminated into two main vessels, in agreement with Boye (1956). These branches divided, as soon as possible, into primary branches showing two basic aspects. They coursed straight in gilts, while in the uterus of the sow they were tortuous. Grahame (1957) reported the same disposition in the pig. It was also observed that the primary branches, in return, gave off small branches to the broad ligament of the uterus. The arcades between these branches, as reported by Lange (1959) were not confirmed. The work of Barone, et al. (1962) agrees with the findings of this investigation.

As soon as the primary branches reached the mesometrial curvature of the uterine horn each divided into secondary branches. Each of them joined the adjacent ones, forming a true arcade similar to that of the A. jejunalis (artery of the small intestines). From these arcades the Ramuli uterini are given off to the uterine wall. The latter disposition concurs broadly with those findings reported by other authors (Sieber, 1903; Boye, 1956; Grahame, 1957; Lange, 1959; and Barone, et al., 1962).

It should be assumed that the disposition of the A. uterina media in the female swine conforms to the special features pertaining to the uterus. Sisson and Grossman (1953) state that the body of the uterus in the swine is short (5 cm) and that the uterine horns are extremely long and are arranged

in numerous coils resembling the small intestines. Macerated specimens showed that the A. uterina media anastomosed with the A. utero-ovarica through its cranial branches. In this way it furnished the uterine tube and the tip of the uterine horn. A similar arrangement was observed between it and the A. urethrogenitalis. These findings are confirmed also in the observations of other authors (Lange, 1959 and Barone, et al., 1962).

Apart from the descriptions of Sieber (1903) regarding the A. urethrogenitalis in the swine, most of the authors (Martin, 1923; Mannu, 1930; Sisson and Grossman, 1953; and Dobberstein and Koch, 1958) agree that the A. urethrogenitalis in the swine resembles that of the bovine. Generally speaking, there is concordance between the general pattern of the bovine and the swine.

It has been postulated that the A. urethrogenitalis in the bovine supplies the accessory genital glands, in the male, and supplies the cervix of the uterus, the vagina, and vulva and extends to the perineum, in the female. This study does not show any discrepancy, however, specific features should be emphasized. In fact, in both the male and female, the A. urethrogenitalis divided into two branches, the cranial and the caudal branches. These branches appeared to be different in size. The caudal branch was the more developed and seemed

to be the direct continuation of the parent vessel.

This has been reported by Lange (1959) who designates this branch as the A. perinealis in the female swine. Variations in size were also observed between the left and right sides. In four out of five male specimens, the left vessel was more developed than the right one and appeared as a unilateral branch which coursed between the bulbourethral glands and ended after anastomosing with the A. pudenda interna. This agrees with Getty (1955). This branch was not extended to the perineal region as its counterpart was in the female. This finding is in agreement with Preuss (1959) and besides did not give off the A. hemorrhoidalis media. In the female the left caudal branch of three out of five specimens was the more developed and extended to the perineal region. It anastomosed with the A. pudenda interna and, like its counterpart in the male, did not give off the A. hemorrhoidalis media. This finding concurs with those reported by Lange (1959). The cranial branch in the female was seen to anastomose with the A. pudenda interna. The findings reported by Lange (1959) and Barone, et al. (1962) agree with the latter statement.

It is generally agreed that the A. pudenda interna in the male supplies the penis and the structures related to it (Sieber, 1903; and Getty, 1955). The findings of this study

agree with this interpretation. However, the disposition of its collateral branches, as well as its termination, appeared to be variable. For example, the Aa. bulbi urethrae and the Aa. profundi penis can arise separately or by a common trunk from the parent vessel and, as such, an arterial pattern may not be established. It is true, however, that the A. pudenda interna joins its fellow of the opposite side to form the A. dorsalis penis. In the description of the terminal branches of the A. dorsalis penis up to the fornix of the prepuce the terminology used by Christensen (1953) has been adopted.

In the female the A. pudenda interna supports the arterial supply of the vagina, vulva, and clitoris and anastomoses with the A. pudenda externa in the perineal region, in complete agreement with the findings of Lange (1959) and Barone, et al. (1962). However, it should be emphasized that the origin of its collateral branches, as well as the termination of the A. pudenda interna, was variable. Therefore, it was not possible to establish a general pattern of its disposition. The contribution of the A. hemorrhoidalis caudalis to the blood supply of the genital tract in both sexes is by its collateral and terminal branches. In the male it gave off the A. perinei. This

finding agrees with those reported by Preuss (1959) for the male artiodactyls. In the female it supplied the muscles of the vulva.

In the course of this investigation several features regarding the disposition of the veins were noted. The venous drainage from the ventral wall of the abdominal cavity (including the mammary glands, prepuce and the scrotum), generally speaking, fall into three categories according to their topography; the cutaneous system, the subcutaneous system and the deep system. The superficial or the cutaneous system is exclusively for the skin. However, these three systems were anastomosed between each other. The relationship between the artery and the corresponding vein also was variable. In some areas the veins were not satellites of the arteries (e.g., *V. subcutanea abdominis*), whereas at places two veins accompanied each artery (e.g., *V. pudenda interna*, *V. epigastrica cranialis*), or only one vein was a satellite to each artery (e.g., *V. thoracica interna*). Having observed variations in the venous system in other areas it should be assumed that the above description cannot be considered as a general pattern.

In all cases investigated the *V. thoracica interna* consisted of a single vessel formed by the union of the *V. epi-*

gastrica cranialis and the V. musculophrenica at the level of the last costosternal articulation. The V. epigastrica cranialis was a double vessel placed on either side of the homologous artery. The medial vessel drained the V. subcutanea abdominis. This finding is contrary to that of Montané (1920) and Bickhardt (1961) who described the V. subcutanea abdominis as a tributary of the V. thoracica interna. The V. epigastrica cranialis received radicles which drained the mammary glands (2nd, 3rd and 4th pairs) being connected in this manner with the V. subcutanea abdominis. It was observed that the valves in this vein were directed to the V. thoracica interna.

The V. subcutanea abdominis was extended from the inter-femoral space toward the infrasternal fossa. Although the tributaries which drained the ventral wall of the prepuce (venous plexus) and those which ran deeper in the median line have not been distinguished by Bickhardt (1961), the distribution of the vessel followed, in general, the descriptions of Bickhardt (1961). It should be noted, however, that the valves of this vein were directed towards the thoracic cavity.

The V. pudenda externa consisted of two veins which coursed parallel to the satellite artery inside the inguinal canal. The terminations of these veins were variable. In most of the cases, one of them joined the V. femoralis while

the other joined the V. profunda femoris. In only two cases both formed the pudendoepigastric trunk, concurring with the findings of Bickhardt (1961) and Lebedewa (1960).

The V. pudenda externa was formed by two roots, the cranial and the caudal roots, in the female. In the male, three roots assumed to be the origin of the parent vessel. This is contrary to the findings of Bickhardt (1961) who described two roots as the general pattern. This assertion only can be accepted for the female.

The disposition of the cranial root of the V. pudenda externa in the female agrees with the descriptions of Bickhardt (1961) and Lebedewa (1960). However, it was seen that the valves of the cranial root, in agreement with Lebedewa (1960), were directed to the V. pudenda externa. No valves were observed in the communicating veins which were connected with the V. subcutanea abdominis and V. pudenda externa. The caudal root of the V. pudenda externa was formed by the veins which were satellites to the arteries. The deep rootlets were joined to the V. pudenda interna in the perineum in the female, and up to the scrotal septum in the male. The valves in this root were directed to the V. pudenda externa. This agrees with Lebedewa (1960). In the male the medial cranial root extended to the preputial diverticulum only as a satellite to

the arterial branch which was more developed, and it was connected with the *V. subcutanea abdominis*.

The *V. spermatica externa* followed the disposition of its satellite artery, however, it was seen that its roots were anastomosed with those of the caudal roots of the *V. pudenda externa*.

The *V. spermatica interna* and the *V. deferentialis* drained the pampiniform plexus and the epididymis, respectively. Several anastomoses were found between the *V. deferentialis* and the pampiniform plexus. The *Vv. testiculares* in the testicle did not follow the arterial pattern. It was not possible to observe the abrupt bend of the testicular veins like the arteries in the mediastinum testis. They appeared as semi-coiled vessels which followed the septa. The larger vessels (*Vv. testiculares*) were embedded in the albuginea and ran in the opposite direction to the corresponding arteries. In fact, they were directed to the cranial border of the testicle, while the arteries appeared to emerge from the caudal border. The pampiniform plexus extended up to the cranial third of the inguinal canal. Goglia (1952) described the pampiniform plexus in the bull, buffalo and ram as resembling the cavernous tissue. Histological sections were not studied in the course of this investigation. Macerated specimens showed that

the disposition of the veins which form the pampiniform plexus resembles those which constitute the cavernosus tissue of the bulbus vestibuli of the vulva. The V. deferentialis joined the V. vesicalis cranialis. The latter joined the V. spermatica interna. The termination of the V. spermatica interna was variable. In one out of five specimens, the right vessel joined the V. iliaca communis. Schwarz and Badawi (1962) also found the same variation in both the vessels in three females and in one male. They studied 21 females and 5 males for their investigation. In this investigation it was also noted that the left vessel joined the V. circumflexa ilium profunda in one of five specimens.

The V. utero-ovarica was the direct continuation of the pampiniform plexus of the ovary which drained the ovary, the ovarian bursa, the uterine tube and connected with the roots of the V. uterina media to support mainly the drainage of the uterus. Except for the variations in its termination and disposition, this vessel followed the descriptions of Lange (1959) and Barone, et al. (1962). In one of five specimens it was noted that the right vessel drained into the V. iliaca communis (Schwarz and Badawi, 1962). In other instances, the left vessel assumed this disposition. The V. uterina media was relatively less developed in relation to the accompanying artery.

It was possible to recognize two roots forming the V. uterina media in the virgin uterus. They anastomosed between them and became plexiform within the layers of the broad ligament of the uterus along the mesometrial curvature of the uterine horn. This is not in agreement with Barone, et al. (1962), who describes the roots of the V. uterina media (V. uterina) as forming a series of arches. In all cases only the venous arches close to the mesometrial border of the uterine horn were observed. These arches were formed by the radicles which drain the uterine walls. It was interesting to note that the roots forming the V. uterine media were larger than the parent vessel itself, which probably is due to the cranial root anastomosing with the root of the V. utero-ovarica. Therefore, the drainage of the uterus was mainly accomplished by way of the V. utero-ovarica. Besides there were also transverse anastomoses between the caudal root of the V. uterina media and the ventrolateral wall of the body of the uterus, as well as communications between the V. uterina media and V. urethro-genitalis. These findings have been confirmed by Lange (1959) and Barone, et al. (1962). However, the termination of the V. uterina media was variable. In one out of five specimens, the left vessel joined the V. utero-ovarica.

The V. urethrogenitalis in the male followed the same disposition as its satellite artery. It drained into the V. iliaca interna. A venous plexus was found at the beginning of the pelvic part of the urethra. This plexus was drained by the roots of the V. vesicalis cranialis, the roots of the V. urethrogenitalis and the radicles of the cranial root of the Ramus obturatorius. Anastomoses between the V. urethrogenitalis and the V. pudenda interna were observed. In the main roots the valves were directed to the V. urethrogenitalis. In the female, the disposition of the V. urethrogenitalis followed the same pattern as that of its artery. However, it was noted that the cranial root anastomosed with the V. uterina media and with the V. vesicalis cranialis through the ureteral radicles. It was also observed that some radicles of the cranial roots were anastomosed with the radicles of the Ramus obturatorius. The caudal root only drained the vagina and communicated with the V. pudenda interna. The Vv. perinei partly drained the vestibule of the vulva and the perineal region into the V. hemorrhoidalis caudalis. This is in agreement with Lange (1959), but it was found that the Vv. perinei anastomosed with the roots which drained the musculature of the vulva superficially through the dorsolateral cutaneous vein of the tail.

The V. pudenda interna was found to be variable in disposition. In some cases it was a paired vessel. In the female, it arose by a common trunk in the perineal region. This trunk anastomosed with the V. pudenda externa. The V. pudenda interna was connected with the caudal root of the Ramus obturatorius. These findings were confirmed by Lebedewa (1962). In agreement with her, the valves of the V. pudenda externa were directed to the V. iliaca interna, while those which correspond to the communicating vessel were directed to the Ramus obturatorius. It means that the venous blood of the vulva and its related structures (clitoris) may drain either into the V. iliaca interna or into the V. profunda femoris.

In the male, the V. pudenda interna is the continuation of the V. dorsalis penis up to the first bend of the sigmoid flexure. Three veins drain the penis. One of them coursed along the dorsal part of the body being embedded in the albuginea. Montané (1920) specifies this vessel as the "cavernosum vein". In this investigation this term has been omitted because it is not in accord with the anatomical disposition. The other two veins, in agreement with Montané (1920), ran ventrally at each side of the cavernosus bodies of the urethra.

As pointed out, these vessels drain in either the ventral plexus of the prepuce (V. pudenda externa) or in the V. dorsalis penis or continue in the cavernosus bodies of the urethra. This is contrary to Montané¹ (1920) who states that these vessels drain into the V. pudenda interna via the V. perinealis. The V. pudenda interna anastomosed with the V. pudenda externa upon the scrotal septum. At the level of the ischial arch the two Vv. pudendae externae anastomosed between them forming a venous plexus which drained the veins of the upper part of the penis and urethra (crus of the penis and erectile tissue of the urethra). As in the female, the V. pudenda interna in the male also anastomosed with the Ramus obturatorius.

The V. hemorrhoidalis caudalis principally drained the perineum, in agreement with Lange (1959).

SUMMARY AND CONCLUSIONS

A total of ten animals, five males and five females, were used for the investigation of the blood vessels supplying the genital tract and the accessory genital organs of the swine (*Sus scrofa domesticus*). Additional material, consisting of ten uteri from non-pregnant female pigs, was employed for the preparation of corrosion specimens.

Injection methods were followed by gross dissections which were supplemented by the study of corrosion specimens. Various techniques were employed to obtain detailed information of the vascular pattern of the genital tract in both sexes. The combination of 2% ammonium water solution and latex, in a ratio of 4:6, respectively, proved to be a satisfactory injection media for both the arterial and venous systems. Storing the specimen for a considerable time at room temperature permitted one to overcome the valvular resistance of the veins.

In general, the arterial disposition of the genital tract of the swine was mainly derived from a collateral pair of branches arising from the Aorta abdominalis, "A. spermatica interna", and from the visceral branches of the A. iliaca interna (A. hypogastrica), namely, the A. umbilicalis, the A. urethrogenitalis and the A. pudenda interna. The blood supply

to the reproductive tract of the swine was somewhat similar to that of the ruminants, although several distinguishing features were observed in this study. The arterial pattern to the mammary glands, the prepuce and the scrotum was derived from the collateral and terminal branches of the A. thoracica interna and the A. profunda femoris (deep femoral artery).

The A. thoracica interna which terminated variably, exclusively supplied the first pair of mammary glands by means of its Rami intercostales and the Rami sternales. The A. epigastrica cranialis seemed to be the direct continuation of the A. thoracica interna throughout the ventral aspect of the abdominal cavity. In its course it anastomosed with the A. epigastrica caudalis, the Aa. intercostales, the twigs from the cranial branch of the A. phrenoabdominalis, the A. circumflexa ilium profunda and the A. pudenda externa. In the female, it exclusively supplied the first two pairs of abdominal mammary glands and, together with the A. pudenda externa, supplied the last pair of abdominal mammary glands. Similarly, in the male, it supplied the prepuce. The A. profunda femoris (deep femoral artery) gave off the A. spermatica externa and the Truncus pudendoepigastricus to supply the accessory genital organs in both sexes. The A. spermatica externa supplied the M. cremaster

externus in both the male and female specimens. Variations in its origin were observed.

In the female, the A. pudenda externa, arising from the pudendoepigastric trunk, terminated by means of four branches, with three (the lateral, middle and medial cranial branches) directed cranially. They supplied the last pair of abdominal, and the inguinal mammary glands. The fourth branch was directed caudally and anastomosed with a branch of the A. pudenda interna in the perineal region.

In the male, the A. pudenda externa, as a rule, terminated in four branches on one side and three branches on the other. However, the side giving off three, on either the right side or the left side, gave rise to the recurrent arteries of the sheath of the penis. In fact, one of the two medial branches, left or right, of the A. pudenda externa formed the arterial circle of the prepuce and the recurrent arteries of the sheath of the penis.

In the male, anastomoses were observed between the A. pudenda externa and the A. pudenda interna near the sheath of the penis (recurrent arteries of the sheath of the penis and the preputial branches originating from the A. dorsalis penis) and upon the scrotal septum.

The A. spermatica interna arose from the Aorta abdominalis anterior to the A. mesenterica caudalis. The right one arose further cranial than the left, however, in the male the left vessel was better developed than the right one. The internal spermatic artery supplied the testicle and the epididymis (head and body). Various authors have applied different nomenclature to the terminal branches of the A. spermatica interna. Variations in the arterial pattern of the Aa. radiatae testes were also recorded. However, this study is in agreement with the terminology proposed by Hofmann (1961) for the bull.

Features related to the A. deferentialis in the pig were recorded. This vessel described a twist around the A. umbilicalis above the seminal vesicle. It was connected to the A. spermatica interna inside the inguinal canal, forming the A. accessoria testicularis. In the inguinal canal it branched successively and extended to the tail of the epididymis.

The A. spermatica interna in the female was represented by the A. utero-ovarica. It divided in a cluster of branches before it approached the ovary. One of them was directed to, and supplied, the ovary as the A. ovarica, while the others (Rami tubouterini) supplied the ovarian bursa, and the anterior portion of the uterine tube. In addition, it gave off a few

branches to the ovary and finally anastomosed with the A. uterina media.

The corkscrew-like vessels ("spiral arteries") were seen approaching the vascular zone of the ovary. Where these vessels approached the arterial wreaths belonging to the theca externa, a nest of flattened vessels was seen to form.

In the female pig, the disposition of the A. uterina media conformed to the special features pertaining to its uterus. It was divided into different branches which formed arcades in close proximity to the mesometrial curvature of the uterine horn. The most cranial branches anastomosed with the branches derived from the Rami tubouterini, whereas the most caudal branches anastomosed with the Rami cervicouterini of the Rami uterini (A. urethrogenitalis).

The cranial branch of the A. urethrogenitalis formed an arterial plexus along the pelvic part of the urethra, in both sexes. This plexus communicated with the terminal branches of the Ramus obturatorius. Variations in caliber between the left and right caudal branches of the A. urethrogenitalis in both the male and female have been observed. In the male, the more developed caudal branch did not extend to the perineal region. The perineal region was supplied by the A. hemorrhoidalis caudalis. In the male, the A. urethrogenitalis

mainly supplied the accessory genital glands, and its disposition resembled that of the bovine. In the female, its caudal branch extended to the perineal region and supplied the vagina, vulva and perineum.

The A. pudenda interna mainly supplied the penis and the structures related to it. The A. pudenda interna anastomosed with the A. urethrogenitalis, and the A. pudenda externa. It sometimes gave off the A. hemorrhoidalis caudalis. At the level of the fornix of the prepuce the A. dorsalis penis terminated into three branches, the preputial branch, which anastomosed with the recurrent artery of the sheath of the penis; the superficial branch, which coursed forward being embedded in the tunica albuginea of the penis; and the deep branch, which pierced the tunica albuginea of the cavernosus body of the penis and ramified in same.

The general pattern of the venous disposition in some areas followed the course of the corresponding arteries. The venous drainage of the mammary glands was accomplished through the V. thoracica interna and its tributaries and the V. pudenda externa. They followed the course of their respective satellite arteries.

The V. subcutanea abdominis was not accompanied by an artery. It drained the subcutaneous and cutaneous systems

related to the mammary glands. It was connected with the V. epigastrica cranialis. The V. pudenda externa principally drained the last two pairs of mammary glands (inguinal glands). Accordingly, the venous blood can flow either along the course of the A. pudenda externa, V. epigastrica cranialis or the V. subcutanea abdominis.

The area between the last pair of mammary glands and the perineum was drained by means of the caudal root of the V. pudenda externa and the V. subcutanea abdominis.

Variations on the termination of the V. spermatica interna (V. utero-ovarica in the female) and the V. uterina media were reported. They terminated either in the V. iliaca communis or in the V. cava caudalis. Anastomosis between these two vessels was also noticed. The V. utero-ovarica mainly drained the ovary, the uterine tube and the tip of the uterine horn. It received the roots of the V. uterina media. The V. urethrogenitalis drained the urethral venous plexus. In the male, it further drained the accessory genital glands, whereas in the female, it drained the cervix of the uterus and the vagina.

Anastomoses were observed between the V. vesicalis caudalis and cranialis and also between the V. urethrogenitalis and the roots of the Ramus obturatorius.

The V. pudenda interna drained the vagina, the clitoris and the cranial portion of the vulva in the female. It communicated with the Ramus obturatorius of the V. profunda femoris, the V. pudenda externa, and the V. urethrogenitalis. In the male, the V. dorsalis penis formed the V. pudenda interna. The latter formed a venous plexus at the level of the ischial arch and anastomosed with the Ramus obturatorius, as in the female.

The V. perinealis was not a satellite of the artery in the female. It joined the V. hemorrhoidalis caudalis. The V. perinealis drained the caudal portion of the vulva and was connected with the radicles of the V. caudalis lateralis. The penis was drained by means of three veins, one of which coursed dorsally along the penis while the other two coursed ventrally along the cavernosus tissue of the urethra. They converged together to form the V. dorsalis penis. The ventral veins communicated at the level of the fornix of the prepuce with the venous plexus which was placed on the ventral wall of the prepuce.

The ventral venous plexus of the prepuce was drained by the V. subcutanea abdominis and V. pudenda externa.

BIBLIOGRAPHY

- Andersen, D. H. 1926. Lymphatics and blood vessels of the ovary of the sow. Carnegie Institution of Washington Contributions to Embryology 88: 109-123.
- Ashdown, R. R. 1958. The arteries and veins of the sheath of the bovine penis. Anatomischer Anzeiger 105: 222-230.
- Badawi, H. 1959. Arterien und Venen der Vordergliedmasse des Schweines. Inaugural Dissertation. Tierärztliche Hochschule, Hannover.
- Barone, R. 1952. Topographie des visceres, chez le Porc et la Truie. Revue de Médecine Vétérinaire 103: 688-697.
- Barone, R. et Burel, H. 1957. Les vaisseaux sanguins du tractus genital chez la Vache. Revue de Médecine Vétérinaire 108: 382-395.
- Barone, R. et Pavaux, Cl. 1962. Les vaisseaux sanguins du tractus génital chez les femelles domestiques. Bulletin de la Société des Sciences Vétérinaires de Lyon 1: 33-52.
- Barone, R., Pavaux, Cl., et Frapart, P. 1962. Les vaisseaux sanguins de l'appareil génital chez la Truie. Société des Sciences Vétérinaires et de Médecine comparée de Lyon 3: 337-346.
- Basset, D. L., Bacon, R. O., Danforth, C. H., Gray, D. J., Greulich, W. W., Kirkman, H., and Turner, R. S. 1946. Terms of position and direction. Anatomical Record 94: 257-263.
- Batson, O. V. 1939. Latex emulsion in human vascular preparations. Science 90: 518-520.
- Beutler, O. 1926. Arteria spermatica interna in Hoden. Deutsche Tierärztliche Wochenschrift 2: 643-646.
- Bevandic, M. 1943. The function of the cranial hemorrhoidal vein in the pig. (in Yugoslavian, title translated). Veterinarski Archiv 13: 186-198.

- Bickhardt, K. 1961. Arterien und Venen der Hintergliedmasse des Schweines. Inaugural Dissertation. Tierärztliche Hochschule, Hannover.
- Boye, H. 1956. Vergleichende Untersuchungen über die arterielle Gefäßversorgung des Uterus von Wild- und Hausschweinen. Zeitschrift für Tierzüchtung und Zuchtungsbiologie 67: 259-296.
- Burruano, C. 1939. Vascolarizzazione della Tuba uterina (Rind, Hund, Katze). Monitore Zoologico Italiano 49: 215-217.
- Chauveau, A. 1889. The comparative anatomy of the domestic animals. 2nd ed. D. Appleton, New York.
- Christensen, G. C. 1953. Angiostructure of the canine penis, its role in the process of erection. Unpublished Ph.D. thesis. Library, Cornell University, Ithaca, New York.
- Dobberstein, J. and Koch, T. 1958. Lehrbuch der vergleichenden Anatomie der Haustiere. Band 2. Verlag S. Hirzel, Leipzig.
- Edwards, E. A. 1936. The orientation of venous valves in relation to body surfaces. Anatomical Record 64: 369-385.
- Ellenberger, W. und Baum, H. 1943. Handbuch der vergleichenden Anatomie der Haustiere. Springer-Verlag, Berlin.
- Faulkner, R. L. 1945. An injection study of the uterine blood vessels. American Journal of Obstetrics and Gynecology 49: 1-8.
- Foust, H. L. and Getty, R. 1954. Atlas and dissection guide for the study of the anatomy of the domestic animals. 3rd ed. The Iowa State College Press, Ames, Iowa.
- Gamble, D. L. 1939. Liquid latex as injection mass for blood vessels. Science 90: 520.
- Getty, R. 1955. Atlas for applied anatomy. Burgess Publishing Co., Minneapolis, Minnesota.

- Goglia, G. 1952. A proposito delle origine delle vene spermatiche nel toro ed in altri mammifere. *Bolletino Societa Italiana di Biologia Sperimentale* 28: 1312-1313.
- Grahame, T. and Morris, P. G. D. 1957. Comparison of the vascular supply to the virgin and post gravid uterus of the pig, ox, and sheep. *British Veterinary Journal* 113: 498-501.
- Harrison, R. G. 1949. The comparative anatomy of the blood supply of the mammalian testis. *Zoological Society of London Proceedings* 119: 325-344.
- Hill, E. C. 1905. On gross development and vascularization of the testis. *American Journal of Anatomy* 6: 439-459.
- Hill, W. C. O. 1937. The use of rubber latex in anatomical procedures. *Ceylon Journal of Science* 4: 47-151.
- Hofmann, R. 1960. Die Gefässarchitektur des Bullenhodens, zugleich ein Versuch ihrer funktionellen Deutung. *Zentralblatt für Veterinärmedizin* 7: 59-93.
- Kähler, W. 1960. Arterien der Körperwand des Schweines. Inaugural Dissertation. Tierärztliche Hochschule, Hannover.
- Lange, H. 1959. Neue Untersuchungen zur Vaskularisation des Schweineuterus. Inaugural Dissertation. Freien Universität, Berlin.
- Lebedewa, N. A. 1960. Die Klappen in den Venen der Euter bei einigen Haustieren. *Wiener Tierärztliche Monatsschrift, Festschrift Professor Schreiber* 1960: 358-365.
- Magilton, J. H. 1964. Blood supply to the genitalia and accessory genital organs of the goat. Unpublished M. S. thesis. Library, Iowa State University of Science and Technology, Ames, Iowa.
- Mannu, A. 1930. Apparechio Vascolare. In Zimmer, *et al.* *Trattato Di Anatomia Veterinaria*. Tome 2. pp. 1-392. Dottor Francesco Vallardi, Milano.

- Martin, P. 1923. Lehrbuch der Anatomie der Haustiere.
Verlag von Schickhardt und Ebner, Stuttgart.
- McKenzie, F. F., Miller, J. D. and Bauguess, L. C. 1938.
The reproductive organs and semen of the boar. Missouri
Agricultural Experimental Station Bulletin 279.
- Mechaelov, N. N. 1963. About the blood supply to the sex
organs of the sow. (in Russian, title translated).
Veterinariia 40: 61-62.
- Montané, L. et Bourdelle, E. 1920. Anatomie regionale des
animaux domestiques. Tome 3. Balliere et Fils, Paris.
- Nickel, R., Schummer, A., und Seiferle, E. 1961. Lehrbuch
der Anatomie der Haustiere. Band 2. Verlag Paul Parey,
Berlin.
- Nomina Anatomica. 1961. 2nd ed. Excerpta Medica Foundation,
New York.
- Phillips, R. V. and Andrews, F. N. 1936. The development of
the testes and scrotum of the ram, bull, and boar.
Massachusetts Agricultural Experiment Station Bulletin
331.
- Pickett, W. O. and Neumann, C. P. 1940. Winylite resin in
the preparation of corrosions of the anatomical specimens.
Anatomical Record 78: 105-111.
- Pope, G. W. 1934. Determining the age of farm animals by
their teeth. United States Department of Agriculture
Farmer's Bulletin 1721.
- Preuss, V. F. 1959. Die Arteria vaginalis der Haussäugetiere.
Berliner und Munchener Tierärztliche Wochenschrift 72:
403-406.
- Reuber, H. W. 1954. Arteriography of the cyclic estrual
changes in the internal genitalia of the cow (Bos
Taurus). Unpublished M. S. thesis. Library, Iowa State
University of Science and Technology, Ames, Iowa.

- Reuber, H. W. and Emmerson, M. A. 1959. Arteriography of the internal genitalia of the cow. American Veterinary Medical Association Journal 134: 101-109.
- Reynolds, S. R. M. 1947. Adaptation of the spiral artery in the rabbit ovary to changes in organize after stimulation by gonadotrophins; effect of ovulation and luteinization. Endocrinology 40: 381-389.
- Schreiber, J. 1960. Problems of veterinary anatomy nomenclature. British Veterinary Journal 116: 53-66.
- Schwarz, R. und Badawi, H. 1962. Unterschiede in der Einmündung der V. spermatica interna and V. circumflexa ilium profunda sowie Besonderheiten im Entste Hungsgebiet der V. cava caudalis bei den Haussäugetieren. Deutsche Tierärztliche Wochenschrift 69: 498-501.
- Sieber, H. F. 1903. Zur vergleichenden Anatomie der Arterien der Bauch und Beckenhöhle bei den Haussäugetieren. Inaugural Dissertation. Tierärztliche Hochschule, Zürich.
- Sisson, S. and Grossman, J. D. 1953. The anatomy of the domestic animals. 4th ed. Saunders, Philadelphia, Pennsylvania.
- St. Clair, L. E. 1958. Anatomy of the pig. In Dunne, W. Howard, ed. Diseases of Swine. pp. 1-35. Ames, Iowa, Iowa State College Press. 1958.
- Smith, J. R. and Henry, M. J. 1945. Demonstration of the arterial system with neoprene latex. Journal of Laboratory and Clinical Medicine 30: 462-466.
- Tanudimadja, K. 1963. The arterial supply of the digestive and reproductive tracts of the sheep. Unpublished M. S. thesis. Library, Iowa State University of Science and Technology, Ames, Iowa.

ACKNOWLEDGMENT

The author wishes to express his deep appreciation to his major professor, Dr. Robert Getty, for guidance, encouragement, constructive criticism, and understanding throughout his graduate studies and research problem. He further wishes to extend his thanks to the staff members of the Department of Anatomy and Histology, College of Veterinary Medicine, Iowa State University of Science and Technology, Ames, Iowa, for their acceptance given to him during his stay.

The author wishes to thank Dr. L. Saar, research associate, for his assistance in translation of some German publications, constructive criticism, and for his help in obtaining abattoir material. He further wishes to extend his appreciation to Dr. N. G. Ghoshal, visiting professor from the Bengal Veterinary College, Calcutta, India, and now a member of the Anatomy staff at Iowa State University of Science and Technology, for his helpful aid in editing the manuscript as well as encouragement and assistance given to him in the translation of the German literature.

He also wishes to thank Mr. D. Hillmann for the preparation of the excellent drawings and photographic work.

The author wishes to record his thanks to Miss J. Mathewson for illustrative art work and labeling of the photographic material; Mrs. M. Kotorman for the technical assistance in preparation of the histological slides; and Mrs. J. Andrew for her aid in typing the manuscript.

The author wishes to acknowledge his indebtedness to Dr. T. Ramos Saco, a former Dean of the Faculty of Veterinary Medicine, Universidad Nacional Mayor de San Marcos, Lima, Perú, and to the Rockefeller Foundation for their Fellowship which made possible his stay in the United States of America.

Thanks are extended to the Veterinary Medical Research Institute for financial support, in part, for this investigation.

The author knows the true value of his friend, Dr. Elmo de la Vega, and wishes to express his gratitude to him for his counsel and encouragement.

Last, but not least, the author wishes to thank his patient and understanding wife, Dorothy, for her encouragement given throughout the course of graduate studies.

TABLES

Table 1. Data regarding the number, sex, age and body weight of the experimental animals.

Animal no.	Breed	Sex ^a	Age in months	Weight in pounds
1	Yorkshire	F	8	180
2	"	F	8	190
3	"	F	14	260
4	"	F	10	230
5	"	F	8	150
6	"	M ^b	13	250
7	"	M ^b	12	280
8	"	M	7	150
9	Hampshire	M	8	170
10	"	M	18	350

^aM - Male; F - Female

^bM - Male castrates

Table 2. Relationship of body weight of the animal and quantity of the anesthetic solution used for intraperitoneal administration^a

Animal no.	Weight in pounds	Quantity in cc.
1	180	70
2	190	60
3	260	95
4	230	100
5	150	60
6	250	90
7	280	95
8	150	60
9	170	70
10	350	120

^aAnesthetic solution not directly related to the body weight of the individual animal.

Table 3. Site, pressure and amount of diluted latex administered for vascular injection

Animal no.	Injection mass	Site	Pressure in mm Hg.	Amount in cc.
<u>Arterial injection</u>				
1	Red latex	Left carotid artery	100	900
2	" "	" " "	"	900
3	" "	" " "	"	1200
4	" "	" " "	"	1200
5	" "	" " "	"	800
6	" "	" " "	"	1200
7	" "	" " "	"	1300
8	" "	" " "	"	900
9	" "	" " "	"	900
10	" "	" " "	"	1500
<u>Venous injection</u>				
1	Blue latex	Posterior vena cava	70	1200
2	" "	" " "	"	1000
3	" "	" " "	"	1500
4	" "	" " "	"	1000
5	" "	" " "	"	1000
6	" "	" " "	"	1200
7	" "	" " "	"	1500
8	" "	" " "	"	1000
9	" "	" " "	"	1200
10	" "	" " "	"	1000

Table 4. Variations on the termination of the A. thoracica interna

Specimen no.	Level of Termination:				Insertion of M. diaphragma	1 cm. after the A. thoracica interna leaves the thoracic cavity
	4th Intercostal space	5th rib	5th Intercostal space	6th rib		
						<u>Right side</u>
1				*		
2				*		
3	*					
4				*		
5				*		
6				*		
7			*			
8				*		
9					*	
10				*		
						<u>Left side</u>
1				*		
2				*		
3				*		
4				*		
5					*	
6						*
7			*			
8		*				
9					*	
10				*		

Table 5. Variations on the termination of the Vv. pudendae
externae

Level of Termination:


Specimen no.	Truncus pudendo- epigastricus	V. iliaca externa	V. femoralis	V. profunda femoris
<u>Right side</u>				
1			*	*
2				*
3			*	*
4	*			
5			*	*
6			*	*
7			*	
8			*	*
9			*	*
10			*	*
<u>Left side</u>				
1			*	*
2			*	*
3			*	
4		*	*	
5			*	
6			*	*
7			*	*
8			*	*
9			*	*
10	*			

130a

ILLUSTRATIONS

Figure 1. The apparatus for injecting arteries and veins

1. Tube for air inlet
2. Mercury manometer
3. Valve for air pressure control
4. Three-way valve
5. Bottle with red or blue latex
6. Ammonium hydroxide (2% solution)



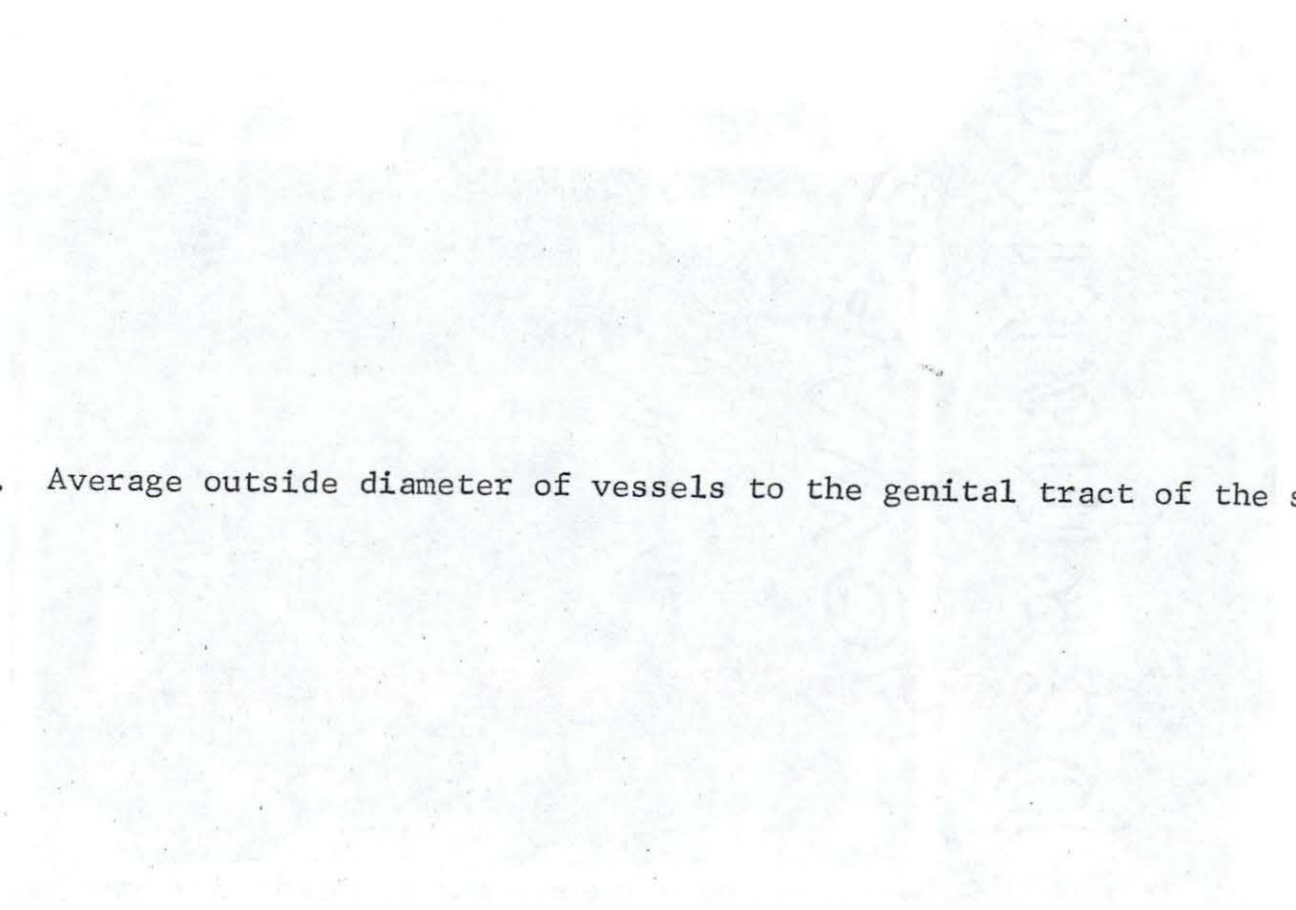


Figure 2. Average outside diameter of vessels to the genital tract of the swine.

Specimen Number	Age in Months	NAMES OF THE VESSELS																													
		A.spermatica interna (A. utero-ovarica)		A.umbilicalis		A.uterina media		A.deferenhalis		A.urethro-genitalis		A.pudenda interna		Truncus pudenda-epigastricus		A.spermatica externa		A.epigastrica caudalis		A.pudenda externa		A.thoracica interna		A.epigastrica cranialis		A.musculo-phrenica		A.hemorrhoidalis caudalis		A.profunda femoris	
		Right Side	Left Side	Right Side	Left Side	Right Side	Left Side	Right Side	Left Side	Right Side	Left Side	Right Side	Left Side	Right Side	Left Side	Right Side	Left Side	Right Side	Left Side	Right Side	Left Side	Right Side	Left Side	Right Side	Left Side	Right Side	Left Side	Right Side	Left Side	Right Side	Left Side
1	8	1.5	1.5	3.0	2.0	2.0	1.0			2.0	3.0	2.0	2.0	3.0	2.0	1.0	1.0	2.0	1.5	3.0	2.0	4.0	4.0	3.0	3.0	2.0	2.0	1.0	1.0	4.0	4.5
2	8	2.0	2.0	3.0	2.5	2.0	2.0			3.0	3.0	2.0	2.0	3.0	3.0	1.0	1.0	1.0	1.0	2.0	3.0	4.0	4.0	3.0	3.5	2.5	2.5	1.0	1.0	4.0	4.0
3	14	1.5	1.5	4.0	4.0	2.0	2.0			2.0	2.0	1.0	2.0	3.0	2.0	1.0	1.0	1.0	1.5	2.5	2.5	5.0	5.0	3.0	3.0	2.0	2.0	1.0	1.5	4.5	5.0
4	10	2.0	2.0	4.0	4.0	2.0	3.0			2.0	2.5	2.0	2.0	2.5	3.0	1.0	0.5	2.0	2.0	2.0	2.5	4.0	4.0	3.0	3.0	3.0	2.5	2.0	2.0	4.5	4.0
5	8	2.0	2.0	3.0	4.0	2.0	2.0			2.0	2.0	2.0	2.0	2.0	2.0	1.0	0.5	1.0	1.0	2.0	2.0	4.0	3.0	3.0	2.0	2.0	2.0	1.0	1.0	4.0	4.0
Average		1.8	1.8	3.4	3.3	2.0	2.0			2.2	2.5	1.8	2.0	2.7	2.4	1.0	0.8	1.4	1.4	2.3	2.4	4.2	4.0	3.0	2.9	2.3	2.2	1.2	1.3	4.2	4.3
Average for Females		1.8		3.3		2.0				2.3		1.9		2.5		0.9		1.4		2.3		4.1		2.9		2.2		1.2		4.2	
Males																															
6c	13	1.0	1.0	3.0	3.0			1.0	1.0	2.0	3.0	3.0	2.0	3.0	3.0	1.0	1.0	2.0	2.0	3.0	2.5	5.0	5.0	3.0	4.0	2.5	3.0	2.0	2.0	4.5	5.0
7c	12	1.0	1.0	3.0	2.0			1.0	1.0	3.0	3.0	3.0	2.5	3.0	3.0	1.0	1.0	2.0	2.0	3.0	3.0	5.0	5.0	3.0	3.0	3.0	3.0	2.0	2.0	4.0	4.5
8	7	1.0	1.5	2.0	2.0			1.0	1.0	2.0	2.0	2.0	2.0	2.0	2.0	1.5	0.5	1.5	1.5	2.0	2.0	5.0	4.5	3.0	3.0	2.0	2.0	1.0	1.5	4.0	4.0
9	8	2.5	3.0	3.0	3.0			2.0	1.5	3.0	2.5	2.5	2.5	3.0	3.0	1.0	1.0	2.0	2.0	2.5	2.0	5.0	4.0	3.0	3.0	2.0	2.0	1.5	1.5	4.0	4.0
10	18	2.8	3.0	3.0	3.0			2.0	1.5	3.0	3.0	3.0	3.0	3.0	3.0	2.0	2.0	2.0	2.0	3.0	3.0	5.0	5.0	4.0	4.0	3.0	3.0	2.5	2.5	5.0	5.0
Average		1.9	1.7	2.8	2.6			1.4	1.2	2.6	2.7	2.7	2.4	2.8	2.8	1.3	1.1	1.9	1.9	2.7	2.5	5.0	4.7	3.2	3.4	2.5	2.6	1.8	1.9	4.3	4.5
Average for Males		1.8		2.7				1.3		2.7		2.5		2.8		1.7		1.9		2.6		4.8		3.3		2.5		1.8		4.4	
Average for Both Sexes		1.8		3.0		2.0		1.3		2.5		2.2		2.6		1.3		1.6		2.4		4.5		3.1		2.3		1.5		4.3	

(c-castrated)

Figure 3. Arteries to the genital tract of the male pig (schematic)

- | | | |
|--|---|---|
| A. Testicle | H. Crus of the penis cut away from ischial arch | N. Inn. inguinales superficiales (lifted) |
| B. Epididymis | I. M. bulbocavernosus | O. Urinary bladder |
| C. Ductus deferens | J. M. ischiocavernosus | P. Rectum |
| D. Seminal vesicle | K. M. retractor penis | Q. M. cremaster externus |
| F. Bulbourethral gland | L. M. ischiococcygeus | R. Ureter |
| G. Penis | M. Preputial diverticulum | S. M. sphincter ani externus |
| 1. Aorta abdominis | 20. Recurrent artery (left) of 18 | 53. Anastomotic branches from 51 to 60 |
| 2. A. phrenoabdominalis | 21. Caudal branch of 15 | 54. Dorsal branches of 53 |
| 3. Aa. lumbales | 22. Superficial branch of 21 | 60. A. pudenda interna |
| 4. A. renalis (left) | 23. Deep branch of 21 | 61. Aa. bulbae urethrae |
| 5. A. spermatica interna | 25. Anastomosis of 15 with 60 | 62. Aa. profundae penis |
| 6. Ramus uretericus of 5 | 28. Ramus obturatorius of 11 | 63. Rami musculares |
| 7. Arterial cone | 31. Caudoproximal branch of 11 | 67. Branch to anastomosis with 15 |
| 8. Aa. testiculares | 33. A. iliaca interna | 74. A. glutea caudalis |
| 9. A. iliaca externa | 34. A. umbilicalis | 75. A. hemorrhoidalis caudalis |
| 10. A. circumflexa ilium profunda | 35. A. vesicalis cranialis | 76. A. perinei |
| 11. A. femoris profunda | 36. A. deferentialis | 77. Branch to bulbourethral gland |
| 12. A. spermatica externa | 37. Ramus uretericus of 36 | 78. Branch to M. ischiococcygeus |
| 13. Truncus pudendoepigastricus | 38. A. glutea cranialis | 79. A. sacralis media |
| 14. A. epigastrica caudalis | 39. A. obturatoria | 80. A. mesenterica caudalis |
| 15. A. pudenda externa | 40. A. urethrogenitalis | 81. A. hemorrhoidalis cranialis |
| 16. Lateral cranial branch of 15 | 41. Cranial branch of 40 | |
| 17. Middle cranial branch of 15 | 42. Ramus prostaticus | |
| 18. Medial cranial branch of 15 | 47. A. vesicalis caudalis | |
| 19. Arterial semicircle of the prepuce | 48. Ramus uretericus of 41 | |
| | 49. Branch to seminal vesicle | |
| | 50. Deferential branch | |
| | 51. Caudal branch of 40 | |
| | 52. Anastomotic branches from 51 to 42 | |

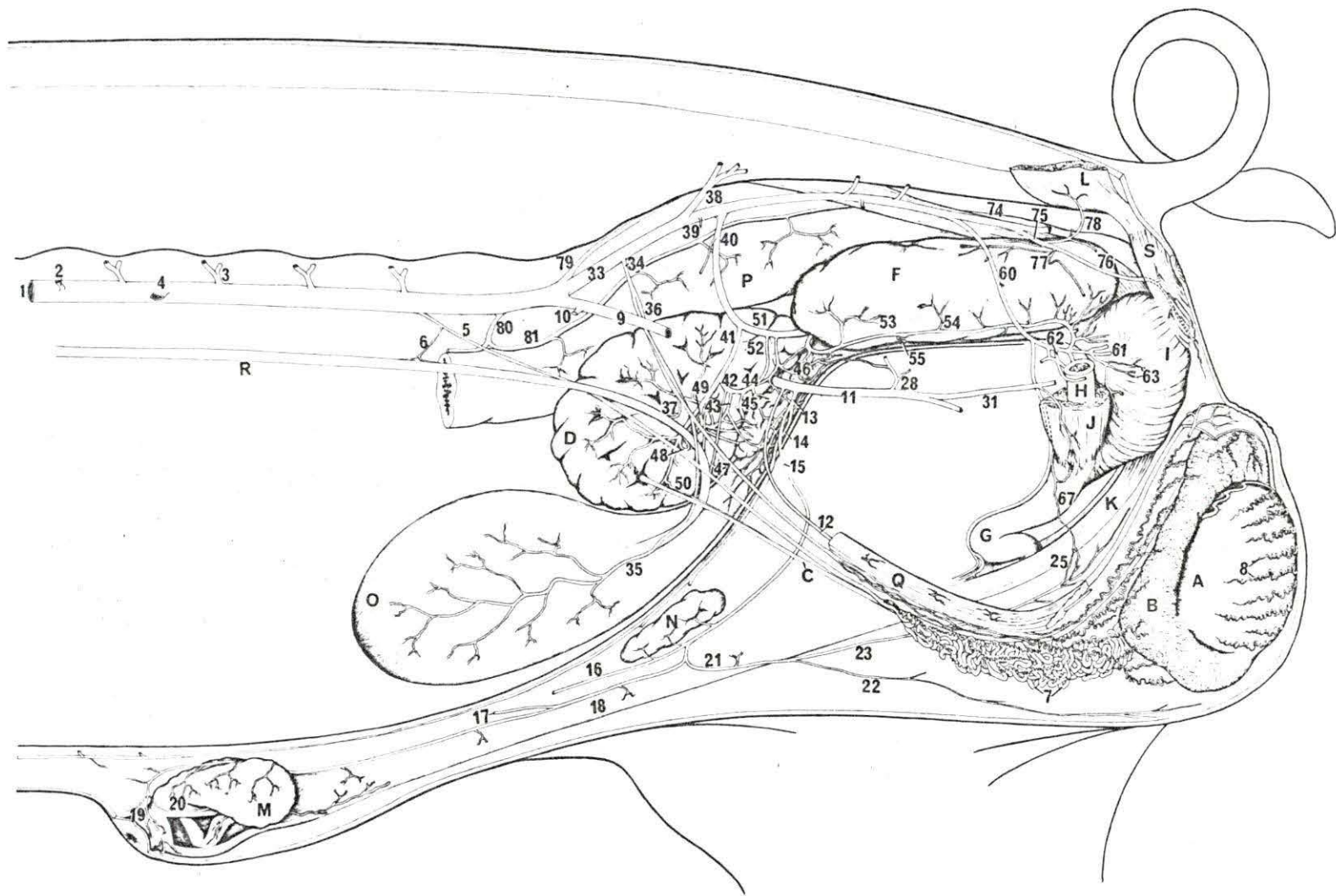


Figure 4. Arteries to the genital tract of the male pig (schematic)

- | | | |
|---|---|--|
| A. Testicle (right) (The left was removed) | G. Penis | N. Inn. inguinales superficiales (lifted) |
| D. Seminal vesicle (right) (the left was removed) | H. Crus of the penis cut away from the ischial arch | O. Urinary bladder |
| E. Prostate gland | I. M. bulbocavernosus | P. Rectum |
| F. Bulbourethral gland (right) (The left was removed) | J. M. ischiocavernosus (part of it was removed) | R. Ureter |
| | K. M. retractor penis cut away from its origin | S. M. sphincter ani externus |
| | | T. Urethra (The sheath of the penis and the preputial sac were opened) |
| 21. Caudal branch of A. pudenda externa | 33. A. iliaca interna | 53. Anastomotic branches from 51 to 60 |
| 22. Superficial branch of 21 | 38. A. glutea caudalis | 55. Ventral branches of 53 |
| 23. Deep branch of 21 | 39. A. obturatoria | 56. Medial branches of 53 |
| 24. Branch to the scrotal septum | 40. A. urethrogenitalis | 57. Anastomotic branches from 46 to 28 |
| 25. Anastomotic branch of 21 with 60 | 41. Cranial branch of 40 | 58. Terminal branches of 51 |
| 26. Medial terminal branch of 21 | 42. Ramus prostaticus | 59. Branch to the M. retractor penis |
| 27. Lateral terminal branch of 21 | 43. Arterial arch formed by 42 and 49 | 60. A. pudenda interna |
| 28. Ramus obturatorius | 44. Arterial arch formed by 42 and 51 | 64. Rami perinei |
| 29. Cranial branch of 28 | 45. Branches to the prostate gland from 43 and 44 | 65. Branch to the M. ischio-urethralis |
| 30. Caudal branch of 28 | 46. Arterial network of the urethra | 66. Anastomotic branches from 60 to 40 |
| 31. Caudoproximal branch of 11 | 47. A. vesicalis caudalis | 68. A. dorsalis penis |
| 32. A. circumflexa femoris medialis | 48. Ramus uretericus of 41 | 69. Lateral branches of 68 |
| | 49. Branch to the seminal vesicle | 70. Branch to M. retractor penis |
| | 51. Caudal branch of 40 | 71. Preputial branch of 68 |
| | 52. Anastomotic branches from 51 to 42 | 72. Superficial branch of 68 |
| | | 73. Deep branch of 68 |

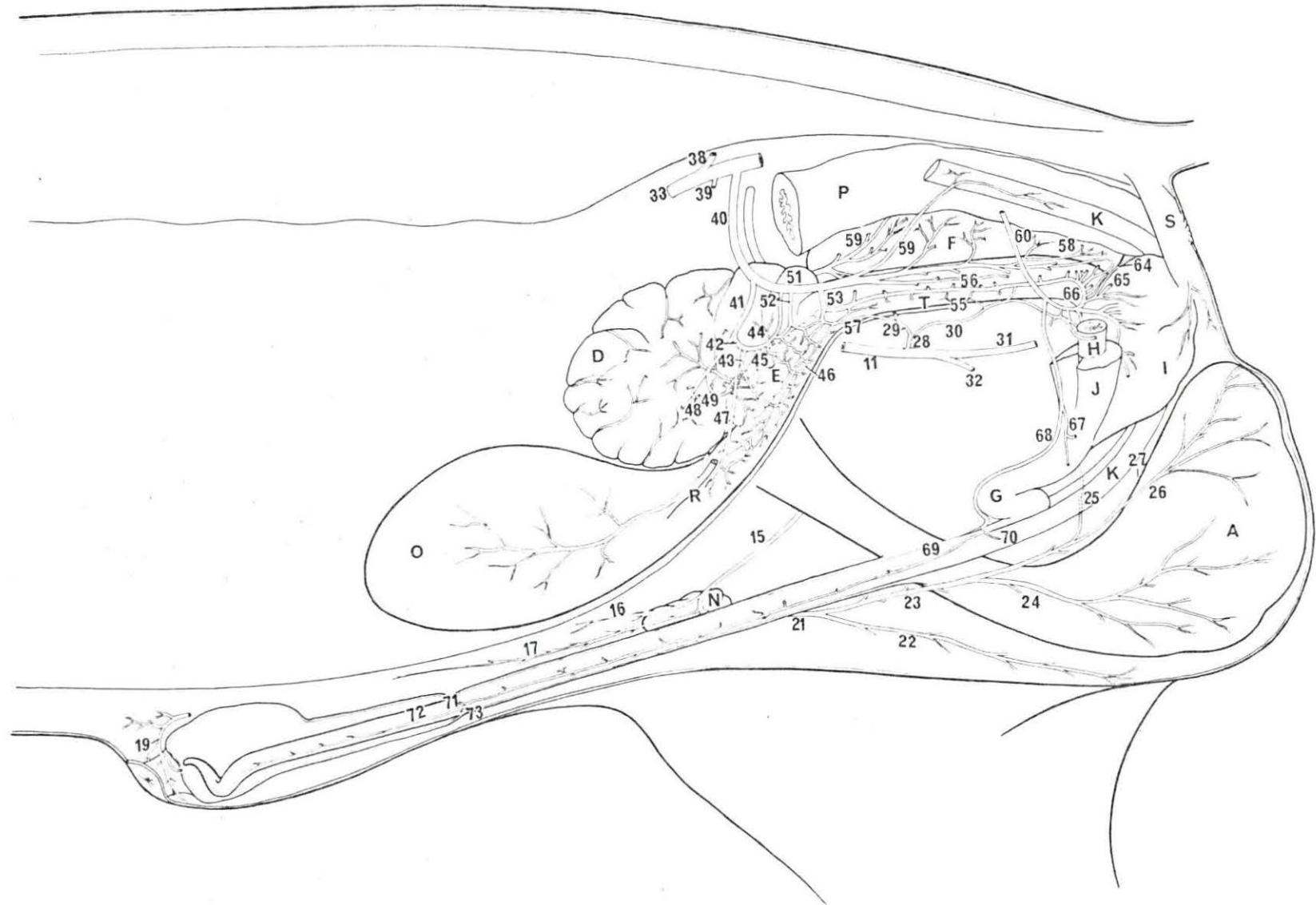


Figure 5. Terminal branching of the A. pudenda externa in the male pig (schematic)

N. Ln. inguinales superficiales

- 15. A. pudenda externa
- 16. Lateral cranial branch of 15
- 17. Middle cranial branch of 15
- 18. Medial cranial branch of 15
- 21. Caudal branch of 15

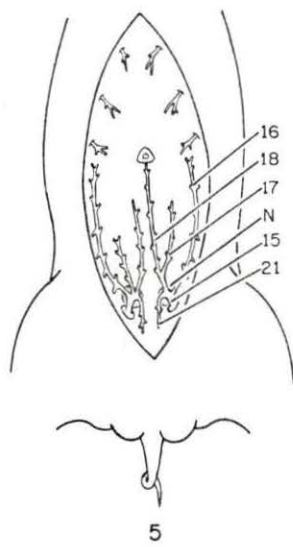
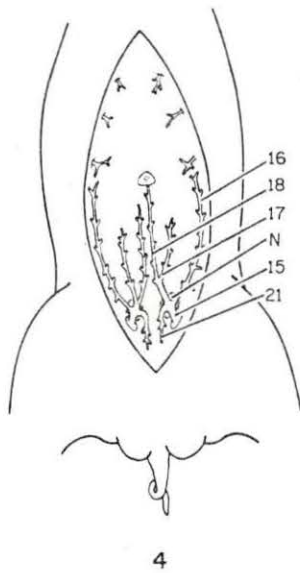
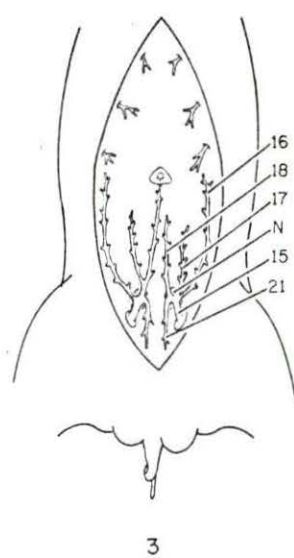
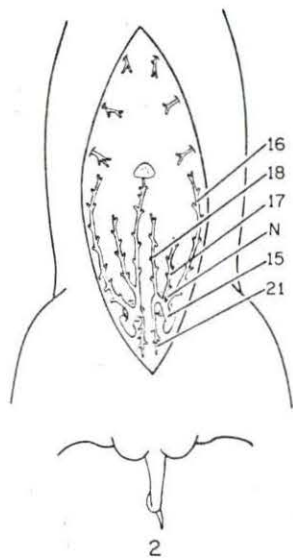
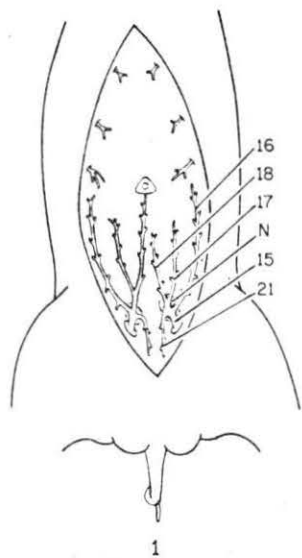
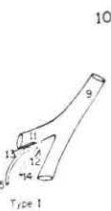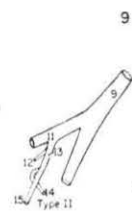
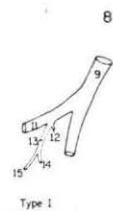
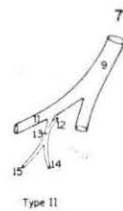
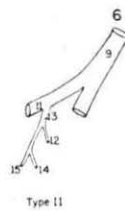
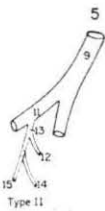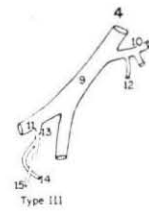
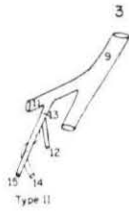


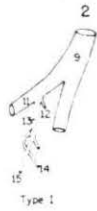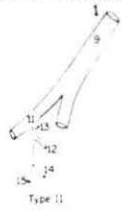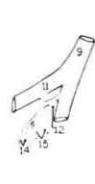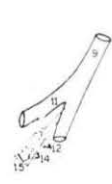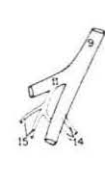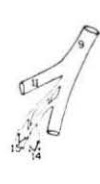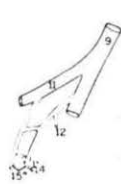
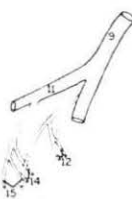
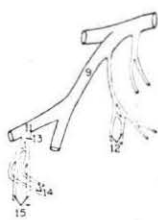
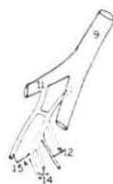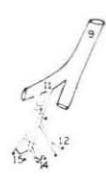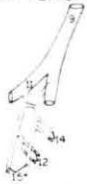Figure 6. Variations in the origin of the A. pudenda externa, A. spermatica externa and the termination of the Vv. pudendae externae (schematic)

9. A. and V. iliaca externa
11. A. and V. femoris profunda
12. A. and V. spermatica externa
13. Truncus pudendoepigastricus
14. A. and V. epigastrica caudalis
15. A. and V. pudenda externa

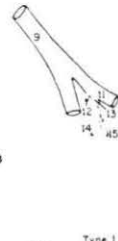
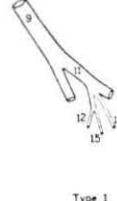
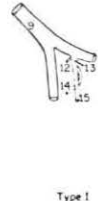
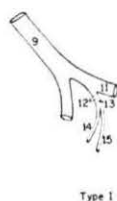
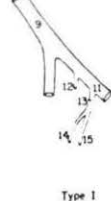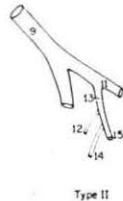
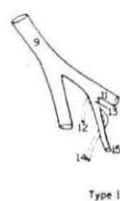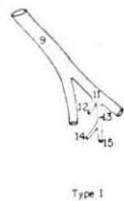
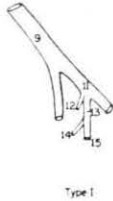
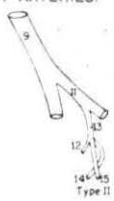
RIGHT ARTERIES:



RIGHT VEINS:



LEFT ARTERIES:



LEFT VEINS:

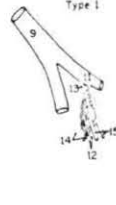
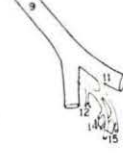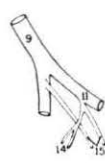
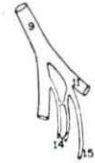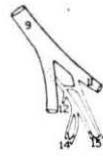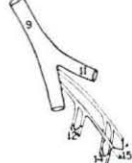
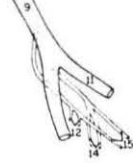
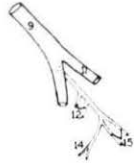
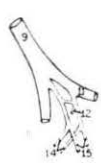


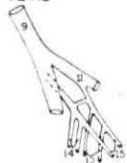Figure 7. Veins from the genital tract of the male swine (schematic)

- | | | |
|---|---|--|
| A. Testicle | H. Crus of the penis cut away from ischial arch | M. Preputial diverticulum |
| B. Epididymis | I. M. bulbocavernosus | N. Inn. inguinales superficiales (lifted) |
| C. Ductus deferens | J. M. ischiocavernosus | O. Urinary bladder |
| D. Seminal vesicle | K. M. retractor penis | P. Rectum |
| F. Bulbourethral gland | L. M. ischiococcygeus | Q. M. cremaster externus |
| G. Penis | | R. Ureter |
| 1. V. cava caudalis | 23. Deep root of 21 | 52. Prostatic radicle |
| 5. V. spermatica interna | 25. Anastomotic root of 21 to 60 | 53. Lateral radicle of 51 |
| 6. V. ureterica | 28. Ramus obturatorius | 58. Medial radicle of 51 |
| 7. Pampiniform plexus | 29. Cranial root of 28 | 60. V. pudenda interna |
| 8. Vv. testiculares | 30. Caudal root of 28 | 60'. Communicant radicle to 28 |
| 9. V. iliaca externa | 31. Caudoproximal root of 11 | 61. Vv. bulbourethrae |
| 9'. V. iliaca communis (left) | 32. V. circumflexa femoris medialis | 62. Vv. profundae penis |
| 10. V. circumflexa ilium profunda | 33. V. iliaca interna | 63. Muscular radicles |
| 11. V. femoris profunda | 34. Anastomotic root between 11 and 60 | 64. Rami perinei |
| 12. V. spermatica externa | 35. V. vesicalis cranialis | 66. Radicle from the ventrolateral part of the bulbourethral gland |
| 13. Truncus pudendoepigastricus | 36. V. deferentialis | 67. Communicant radicle to 15 |
| 14. V. epigastrica caudalis | 38. V. glutea cranialis | 68. V. dorsalis penis |
| 15. V. pudenda externa | 39. V. obturatoria | 68'. Dorsal root of 68 |
| 16. Lateral cranial root of 15 | 40. V. urethrogenitalis | 74. V. glutea caudalis |
| 18. Medial cranial root of 15 | 41. Cranial root of 40 | 75. V. hemorrhoidalis |
| 19. Venous plexus of the prepuce | 42. Prostatic radicles | 76. V. perinealis |
| 20. Communicant radicles between 15 and V. subcutanea abdominis | 46. Venous plexus of the urethra | 77. Root from the bulbourethral gland |
| 21. Caudal root of 15 | 47. Urethral radicles | 78. Root from the M. ischiococcygeus |
| 22. Superficial root of 21 | 49. Glandular radicles from the seminal vesicle | 79. V. sacralis media |
| | 50. Deferential radicles | 82. Cutaneous radicles of the Vv. caudales laterales |
| | 51. Caudal root of 40 | |

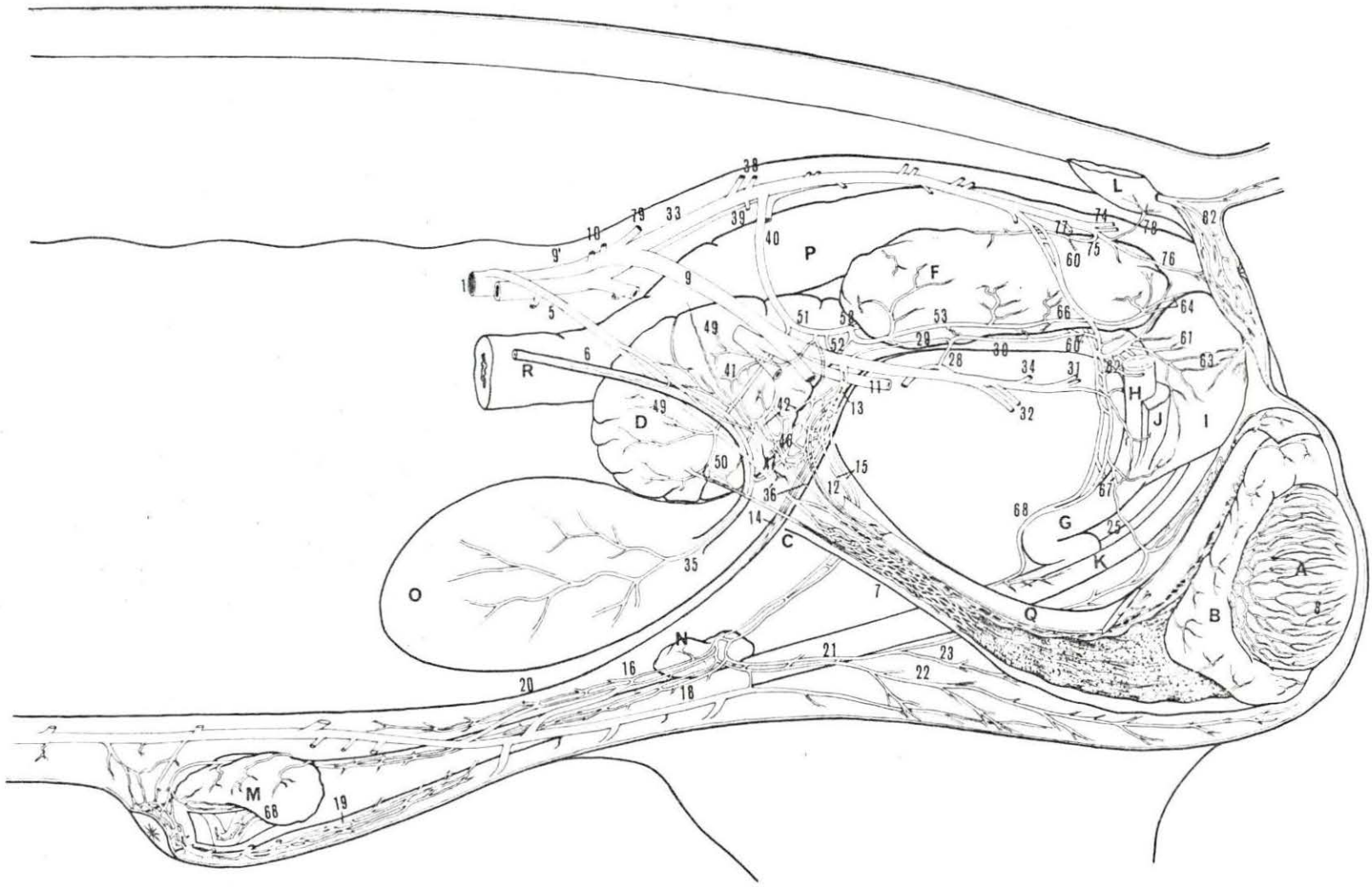


Figure 8. Variation in termination of A. thoracica interna

- A. M. transversus thoracis (exposed)
- B. M. diaphragma (cut off)

- III. Third rib
- IV. Fourth rib
- V. Fifth rib
- VI. Sixth rib

- 84. A. and V. thoracica interna
- 87. A. and V. epigastrica cranialis
- 90. A. musculophrenica

Figure 9. Ventral view of the inguinal region (superficial dissection)

- A. Testicles
- B. Lnn. inguinales superficiales
- C. Rudimentary mammary glands
- D. Prepuce

- 16. Lateral cranial branch of A. pudenda externa
- 21. Caudal branch of the A. pudenda externa
- 22. Superficial branch of 21
- 23. Deep branch of 21

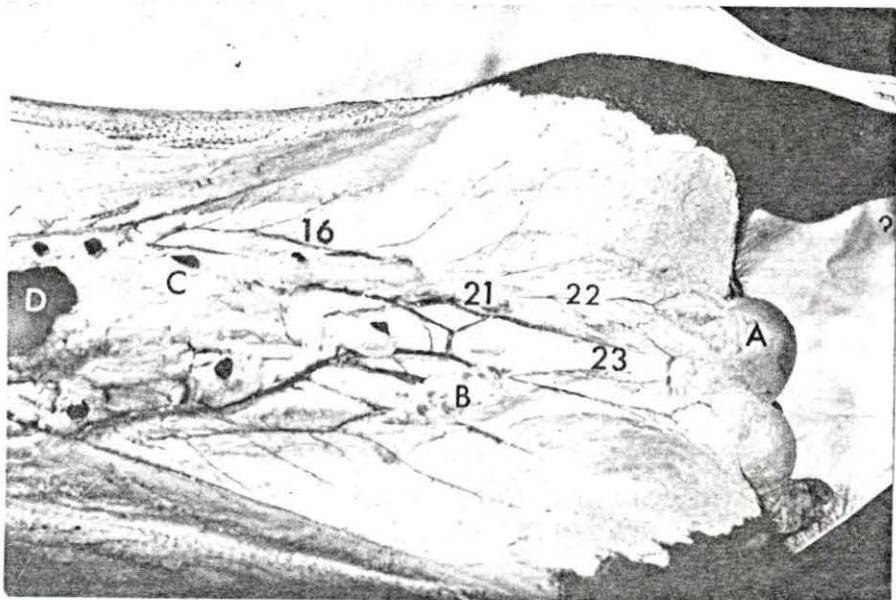
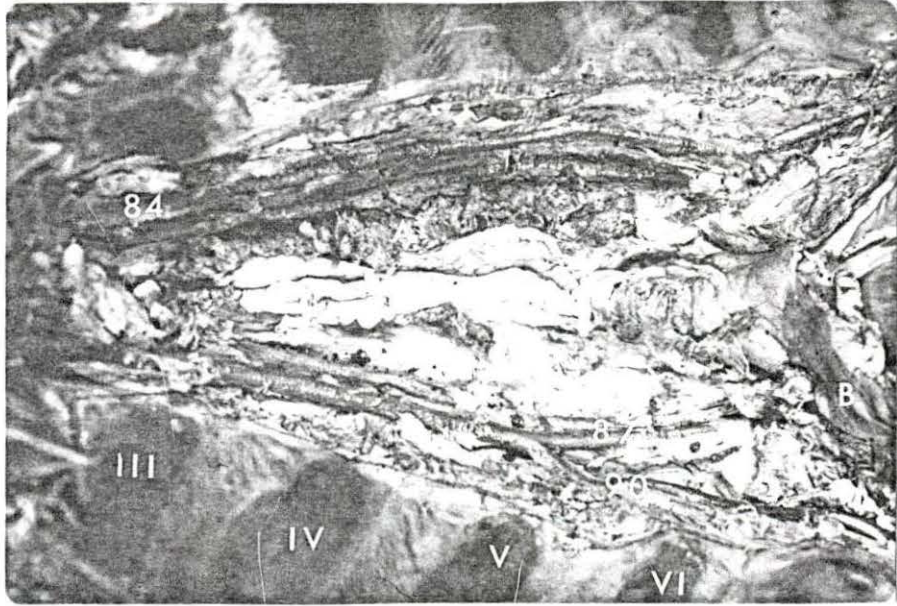


Figure 10. Termination of the medial cranial branch of the A. pudenda externa in the male pig

- A. Rudimentary mammary glands
- B. Preputial diverticulum
- 16. Lateral cranial branch of the A. pudenda externa
- 18. Medial cranial branch of A. pudenda externa
- 19. Arterial circle of the prepuce

Figure 11. Deep dissection of the preputial area in the male pig

- A. Rudimentary mammary glands
- B. Preputial diverticulum (distended)
- C. Sheath of the penis
- 16. Lateral cranial branch of the A. pudenda externa
- 17. Middle cranial branch of the A. pudenda externa
- 18. Medial cranial branch of the A. pudenda externa
- 19. Arterial circle of the prepuce
- 20. Recurrent artery of the sheath of the penis (left)

Figure 12. Deep dissection of the preputial area

- A. Rudimentary mammary glands
- B. Preputial diverticulum (distended)
- C. Sheath of the penis
- 19. Arterial circle
- 20. Recurrent artery of the sheath of the penis (left)
Anastomoses with the superficial branch of the A. dorsalis penis


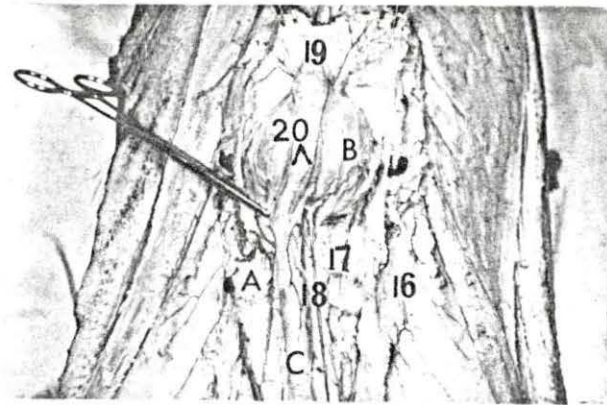
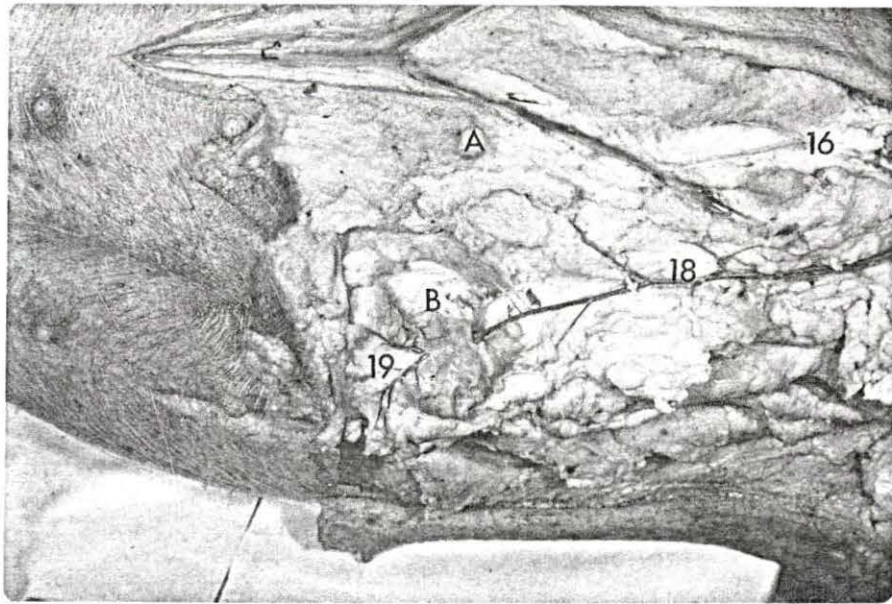


Figure 13. The venous drainage of the cranial aspect of the prepuce (superficial dissection)

- A. Rudimentary mammary glands
- B. Prepuce
- C. Knee fold

- 97. V. subcutanea abdominis
- 97^V. Root from the median line of the ventral abdominal wall

Figure 14. The venous drainage of the lateral aspect of the prepuce.

- A. Rudimentary mammary glands
- B. Prepuce

- 97. V. subcutanea abdominis
- 97^{V''}. Roots from the lateral aspect of the prepuce
- 20. Anastomosis between the V. subcutanea abdominis and V. pudenda externa (lateral cranial branch)
- 89. Preputial branches (medial) from the A. epigastrica cranialis

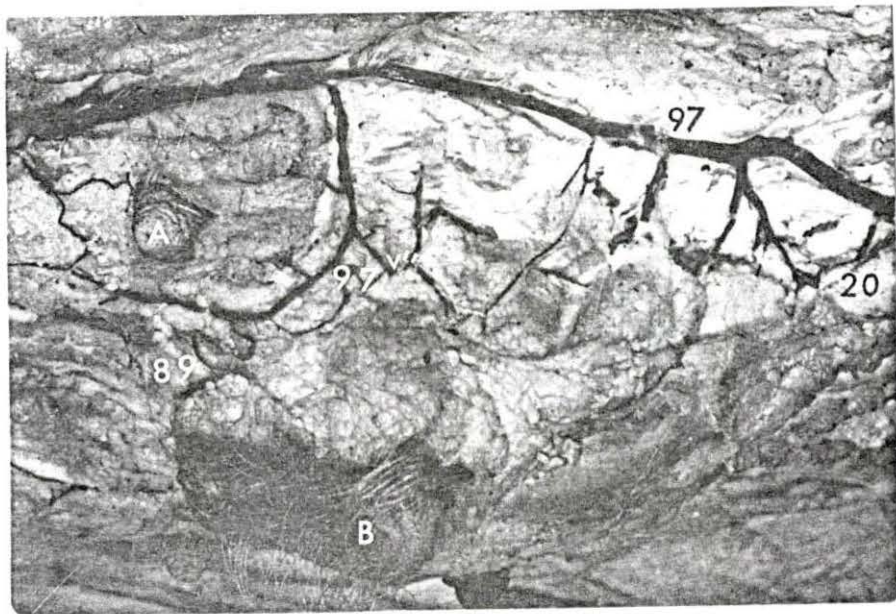
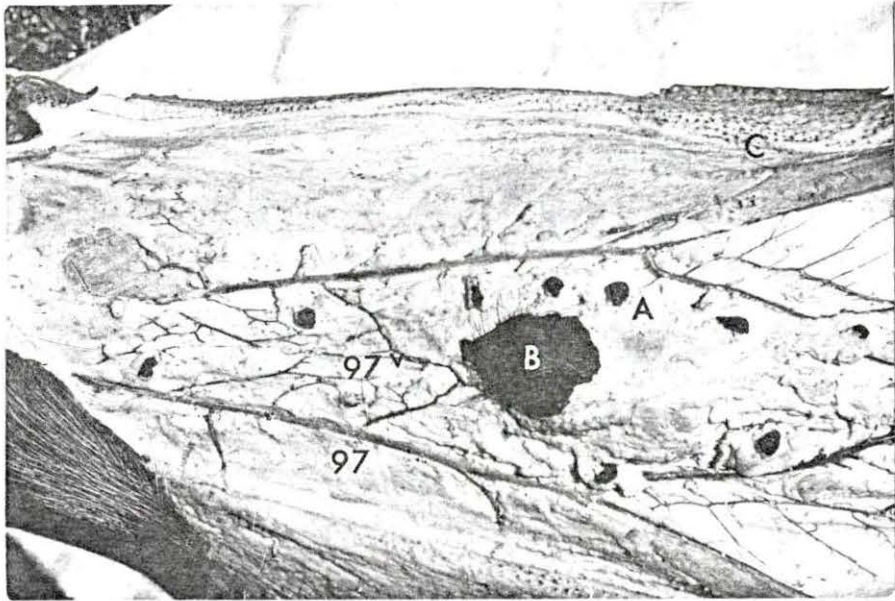


Figure 15a. Latex cast of the A. spermatica interna and A. deferentialis

- 5. A. spermatica interna
- 5'. Anastomotic branch to 36
- 7. Arterial cone (Pampiniform plexus)
- 8. Aa. testiculares
- 36. A. deferentialis

Figure 15b. Latex cast showing the variation of the A. spermatica interna at its termination

- 5. A. spermatica interna
- 5'. Anastomotic branch to 36
- 5'''. Branches to the medial and lateral side of the testicle
- 7. Arterial cone (Pampiniform plexus)
- 8. Aa. testiculares
- 36. A. deferentialis

It will be evident that the A. spermatica interna gave off a collateral branch to the medial and lateral surface of the testicle.

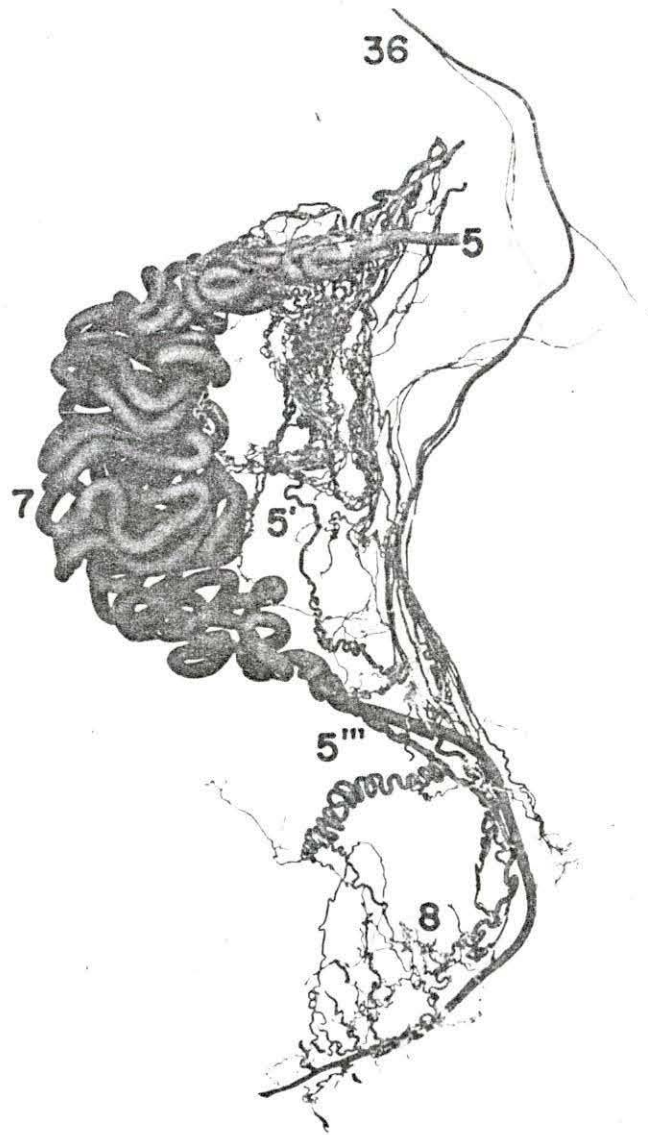
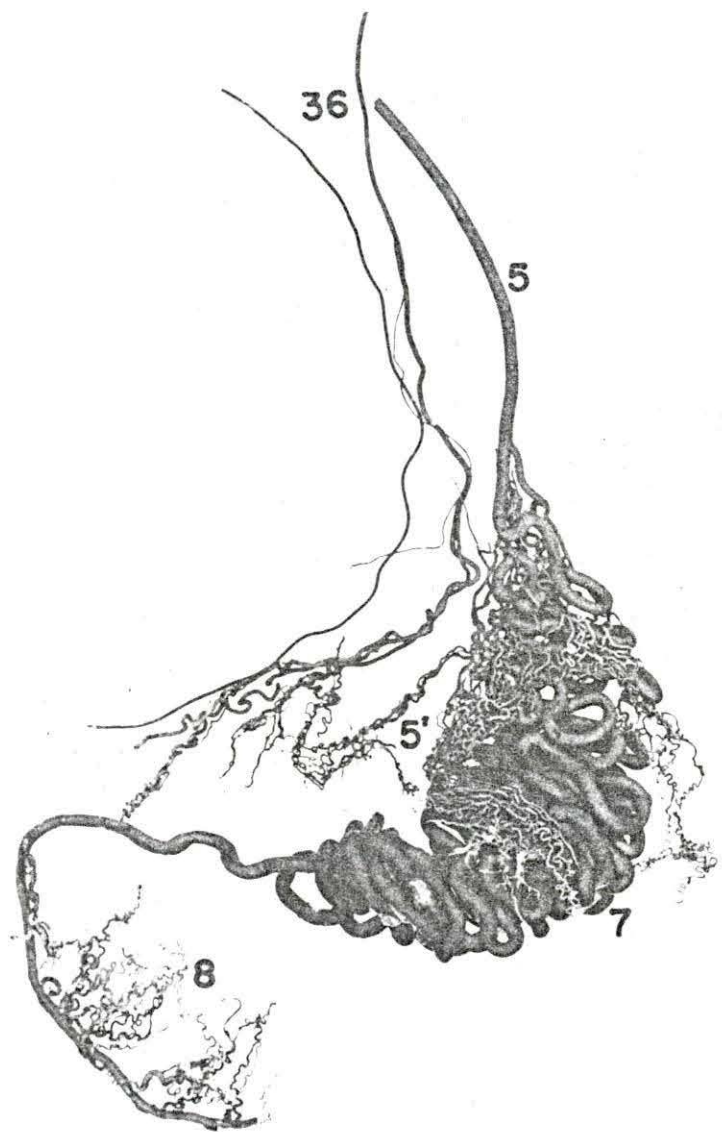


Figure 16. Latex cast from the testicle

- 5. A. spermatica interna
- 8. Aa. testiculares
- 8'. Aa. radiatae testes
- 8''. Aa. centripedales
- 8'''. Arterial arches of 8'
at the mediastinum
testes
- 8IV. Aa. centrifugales

Figure 17. Pampiniform plexus of the testicle

- 5. V. spermatica interna
forming the pampini-
form plexus
- 5'. Communicating branch
to 36
- 5''. Branches to the epi-
didymis
- 7. Pampiniform plexus

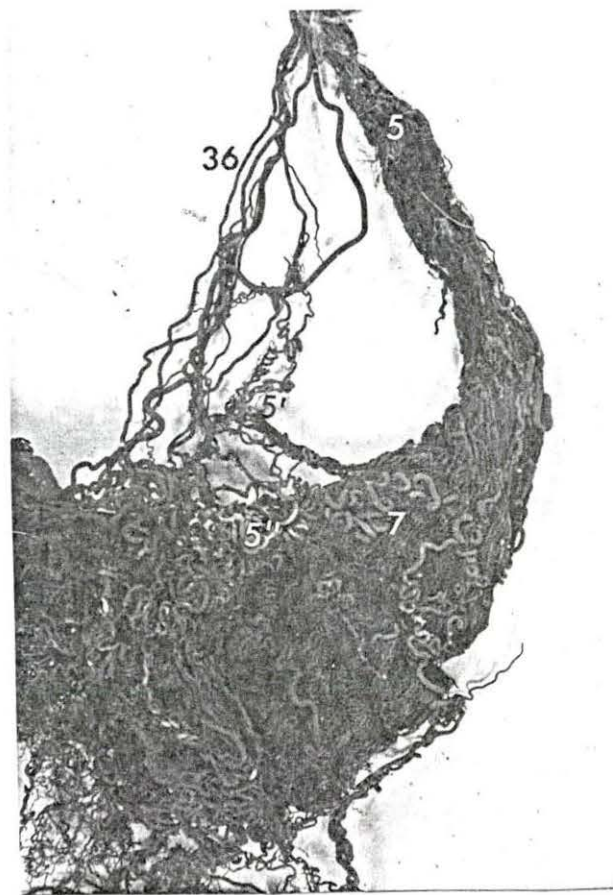
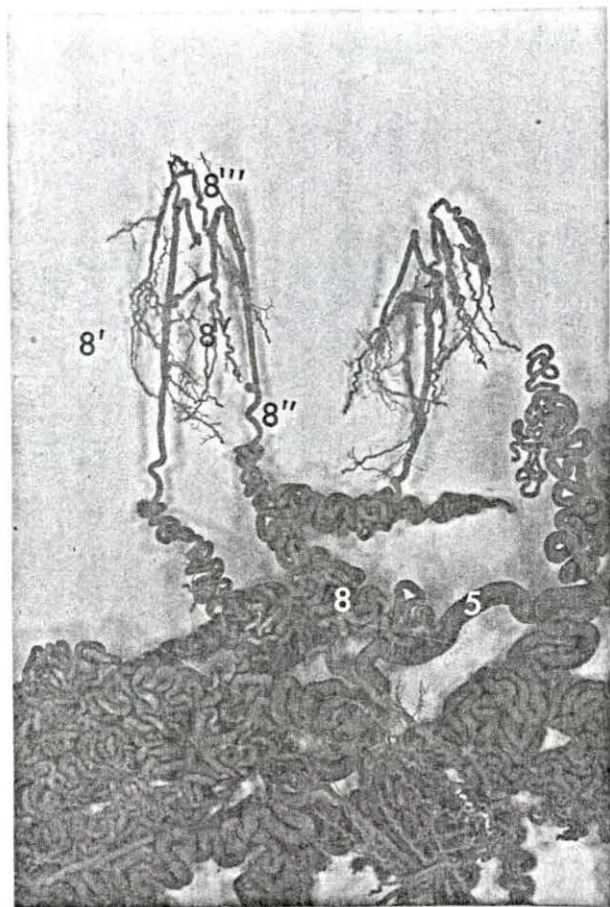


Figure 18. Cast of the Aa. radiatae testes showing the arrangements of arterial loops in the mediastinum testis

- 8. Aa. testiculares
- 8'ⁱ. Aa. centripedales
- 8'^v. Aa. centrifugales

- A. Type No. 1 One vessel made different arterial loops at different levels
- B. Type No. 2 The vessel did not give a collateral branch at the level of the arterial loop (Hill, 1905)
- C. Type No. 3 The vessel gave collateral branches at the level of the arterial loop (Hill, 1905)
- D. Type No. 4 The vessel divided into two branches, each of them described the respective loops (Hill, 1905)
- E. Type No. 5 Two Aa. radiatae testes were anastomosed forming an arch at the mediastinum testes

Figure 19.

- E. Type No. 5 Described in Figure 18
- F. Type No. 6 One of the Aa. radiatae testes gave a collateral branch before the abrupt looping is described (Hill, 1905)
- G. Type No. 7 One of the Aa. centrifugales gave a collateral branch after the abrupt looping is described (Hill, 1905)
- H. Type No. 8 Conspicuous disposition of the Aa. radiatae testes

Figure 20.

- H. Type No. 8 Noted in Figure 19
- I. Type No. 9 Five radiatae testes were anastomosed forming archs at the mediastinum testes.

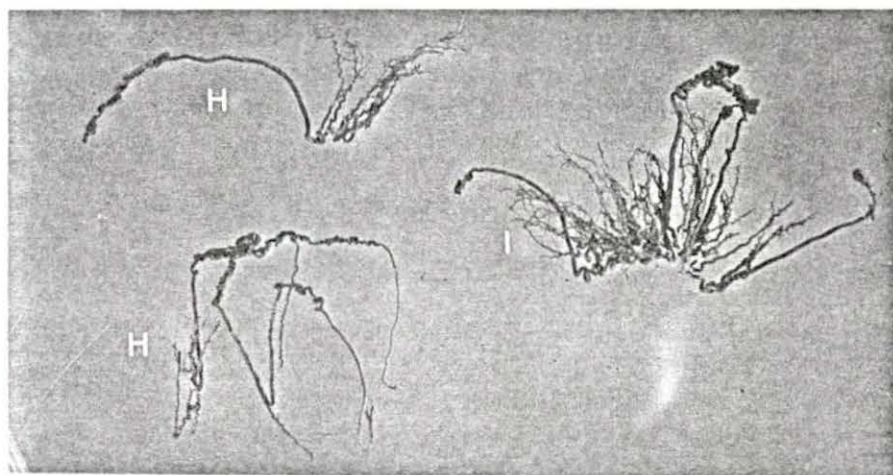
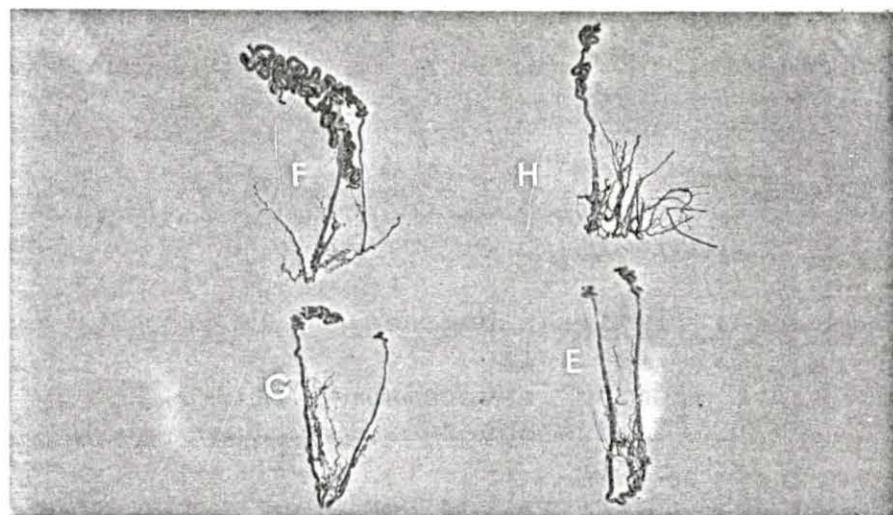
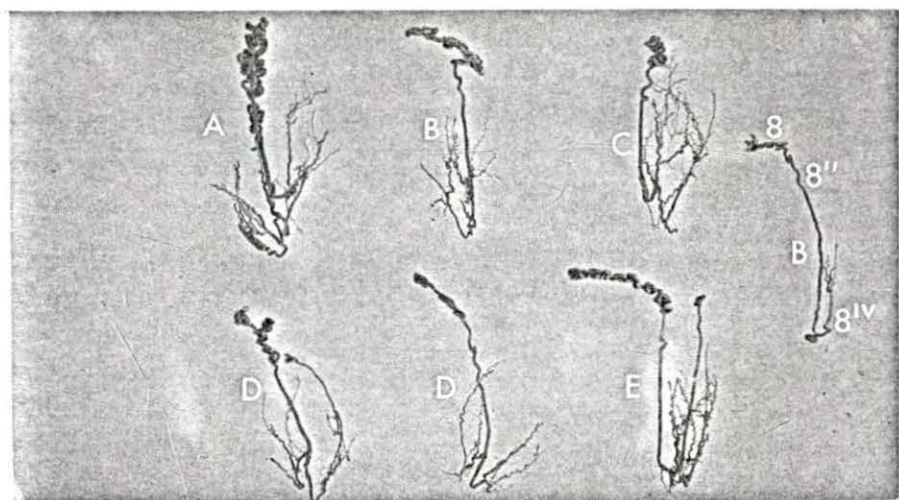


Figure 21a. Cross section of the penis (before the sigmoid flexure)

- A. Tunica albuginea
 - B. Trabeculae
 - C. Corpus cavernosum penis
 - D. Corpus cavernosum urethrae
 - E. Urethra
68. A. and V. dorsalis penis

Figure 21b. Cross section of the penis (about 2 cm after the sigmoid flexure)

- A. Tunica albuginea
 - B. Trabeculae
 - C. Corpus cavernosum penis
 - D. Corpus cavernosum urethrae
 - E. Urethra
 - F. M. retractor penis
68. V. dorsalis penis (with blue latex)
69. Terminal branches of the A. dorsalis penis (right and left)

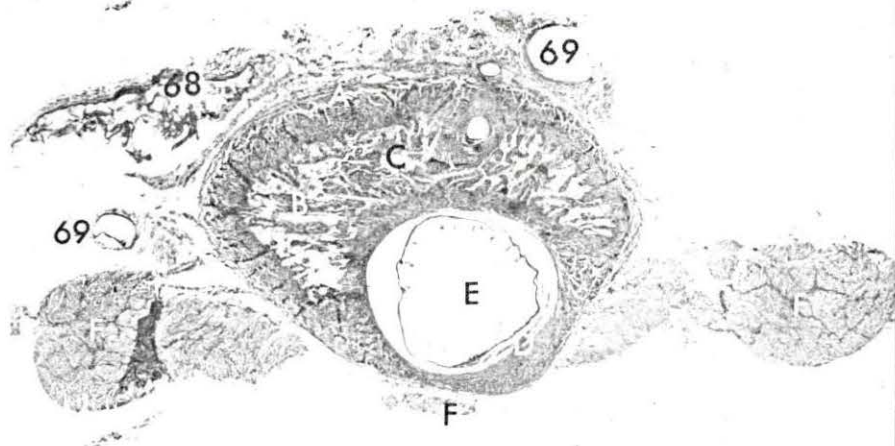
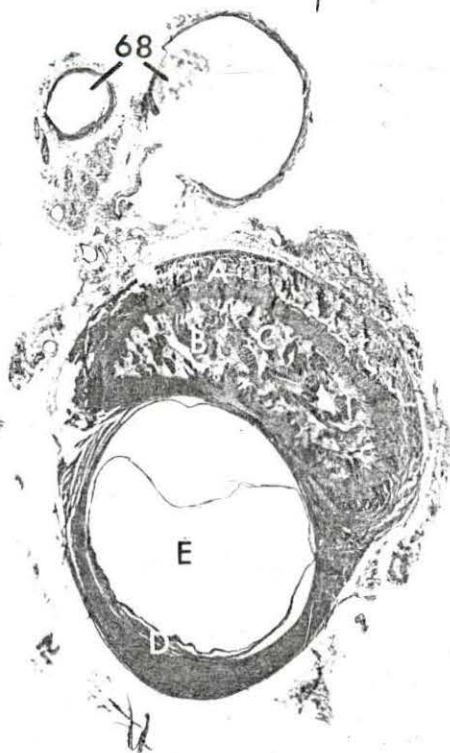


Figure 22. Cross section of penis (cranial third)

- A. Tunica albuginea
 - B. Trabeculae
 - C. Corpus cavernosum penis
 - D. Corpus cavernosum urethrae
 - E. Urethra
-
- 68'. Dorsal root of the V. dorsalis penis
 - 68'''. Ventral roots of the V. dorsalis penis
(right and left)
 - 69. Terminal branches of the A. dorsalis penis
(right and left)

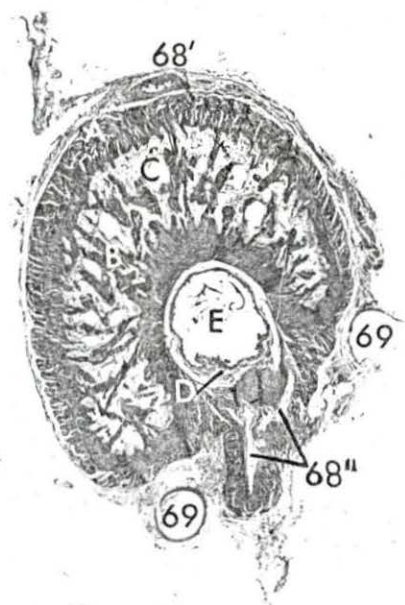


Figure 23. Arteries to the genital tract of the female pig (schematic)

- | | | |
|-----------------------------------|--|--|
| A. Ovary | H. Crus of the clitoris cut away from the ischial arch | R. Ureter |
| B. Ovarian bursa | L. M. ischiococcygeus | S. M. sphincter ani externus |
| C. Uterine tube | N. Inn. inguinales superficiales (lifted) | T. Urethra |
| D. Uterine horn | O. Bladder | U. M. constrictor vestibuli |
| E. Body of uterus | P. Rectum | V. M. constrictor vulvae |
| F. Vagina | | X. Broad ligament (cut away from its origin) |
| G. Vulva | | |
| 1. Aorta abdominis | 22. Superficial branch of 21 | 40. A. urethrogenitalis |
| 2. A. phrenoabdominalis | 23. Deep branch of 21 | 41. Cranial branch of 40 |
| 4. A. renalis (left) | 25. Anastomosis between 15 and 60 | 42. Rami vaginalis of 41 |
| 5. A. utero-ovarica | 26. Ramus obturatorius of 11 | 43. Ramus urethralis of 41 |
| 5'. Rami tubouterini | 29. Cranial branch of 28 | 47. A. vesicalis caudalis |
| 5''. Arterial plexus of 5' | 30. Caudal branch of 28 | 48. Ramus uretericus |
| 6. Ramus uretericus | 31. Caudoproximal branch of 11 | 50. Rami uterini |
| 7. Pampiniform plexus | 32. A. circumflexa femoris medialis | 50'. Rami cervicouterini |
| 8. A. ovarica | 33. A. iliaca interna | 51. Caudal branch of 40 |
| 9. A. iliaca externa | 34. A. umbilicalis | 53. Anastomotic branch from 51 to 60 |
| 10. A. circumflexa ilium profunda | 35. A. vesicalis caudalis | 60. A. pudenda interna |
| 11. A. profunda femoris | 36. A. uterina media | 61. A. urethralis |
| 12. A. spermatica interna | 36'. Main vessels of 36 | 61'. Anastomotic branch to 51 |
| 13. Truncus pudendoepigastricus | 36''. Primary branches of 36 | 62. Common trunk to 62' and 62'' |
| 14. A. epigastrica caudalis | 36'''. Secondary branches of 36 | 62'. Rami vestibularis |
| 15. A. pudenda externa | 36'V. Branches to the broad ligament of the uterus | 62''. A. profunda clitoridis |
| 16. Lateral cranial branch of 15 | 36V. Anastomotic branch to 5' | 63. A. bulbivestibuli |
| 17. Middle cranial branch of 15 | 36V'. Anastomotic branch to 50' | 68. A. dorsalis clitoridis |
| 18. Medial cranial branch of 15 | 36V''. Ramuli uterini | 74. A. glutea caudalis |
| 21. Caudal branch of 15 | 37. Ramus uretericus of 36 | 75. A. hemorrhoidalis caudalis |
| | 38. A. glutea cranialis | 76. Ramus muscularis |
| | 39. A. obturatoria | 78. Branch to the M. ischiococcygeus |
| | | 79. A. sacralis media |
| | | 80. A. mesenterica caudalis |
| | | 81. A. hemorrhoidalis cranialis |

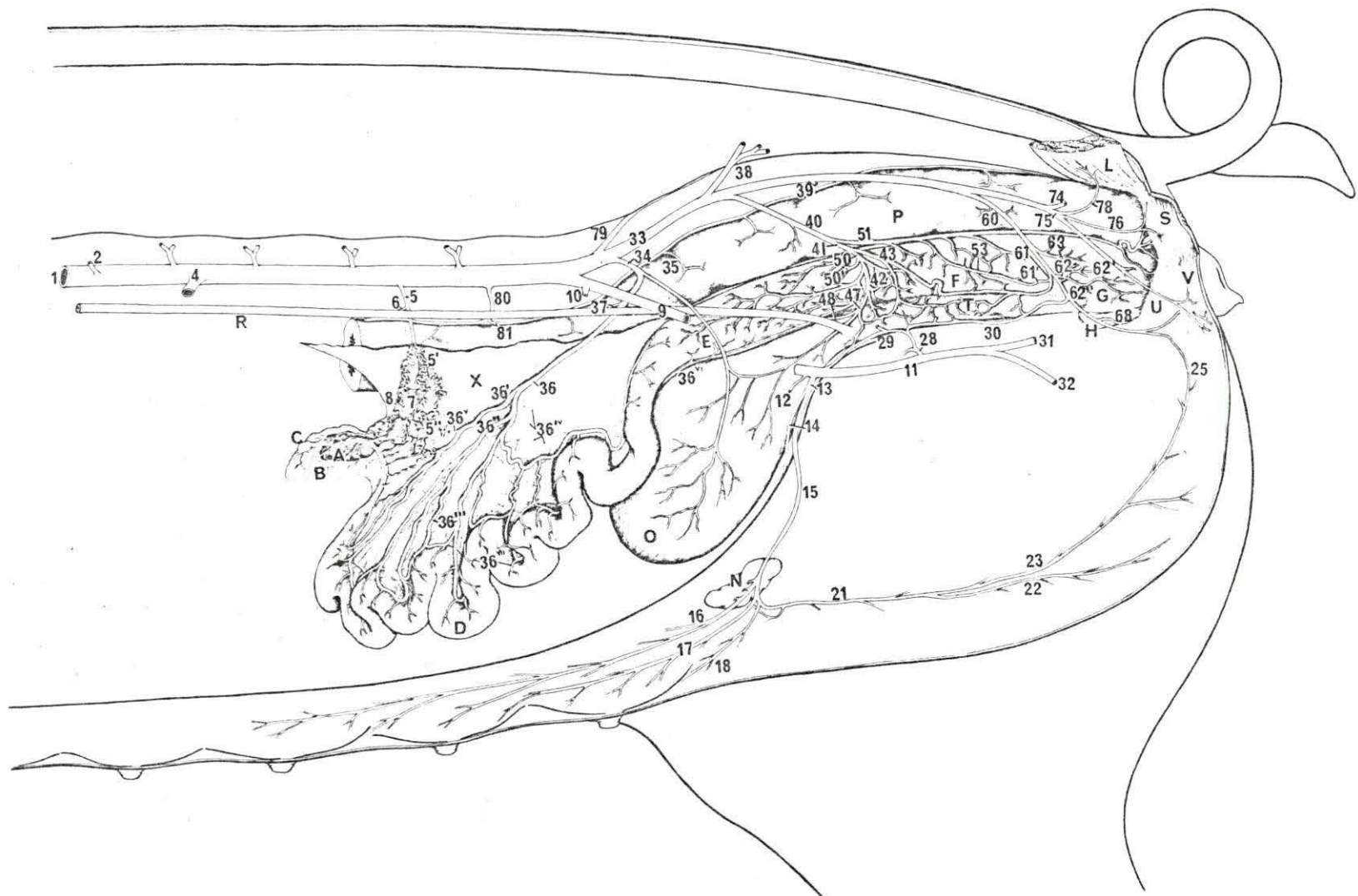


Figure 24. Arteries to the ventral wall of the trunk in the female pig (schematic)

- C.c. Cariniform cartilage
N. Lnn. inguinales superficiales (lifted)
I-XIV. Ribs
- | | | | |
|-------------------|-------------------------------|-------------------|--|
| 1. | Aorta abdominis | 79. | A. sacralis media |
| 2. | A. phrenoabdominalis | 80. | A. mesenterica caudalis |
| 2 ¹ . | Cranial branch of 2 | 81. | A. hemorrhoidalis cranialis |
| 2 ¹¹ . | Caudal branch of 2 | 83. | A. brachialis (A. subclavia) |
| 4. | A. renalis (left) | 83 ¹ . | Truncus omocervicalis |
| 5. | A. spermatica interna | 84. | A. and V. thoracica interna |
| 9. | A. iliaca externa | 85. | Rami intercostales of 84 |
| 10. | A. circumflexa ilium profunda | 86. | Cutaneous branches of Rami sternales of 84 |
| 11. | A. profunda femoris | 87. | A. epigastrica cranialis |
| 12. | A. spermatica externa | 88. | Lateral branches of 87 |
| 13. | Truncus pudendoepigastricus | 89. | Medial branches of 87 |
| 14. | A. epigastrica caudalis | 90. | A. musculophrenica |
| 15. | A. pudenda externa | 91. | A. thoracica externa |
| 16. | Lateral cranial branch of 15 | 92. | A. transversa scapulae |
| 17. | Middle cranial branch of 15 | 93. | Rami ventrales of Aa. intercostales |
| 18. | Medial cranial branch of 15 | 94. | V. cava cranialis |
| 21. | Caudal branch of 15 | 94 ¹ . | Truncus costocervicalis |
| 22. | Superficial branch of 21 | 95. | V. jugularis |
| 23. | Deep branch of 21 | 96. | V. axillaris proximalis |
| 33. | A. iliaca interna | 96 ¹ . | V. axillaris distalis |

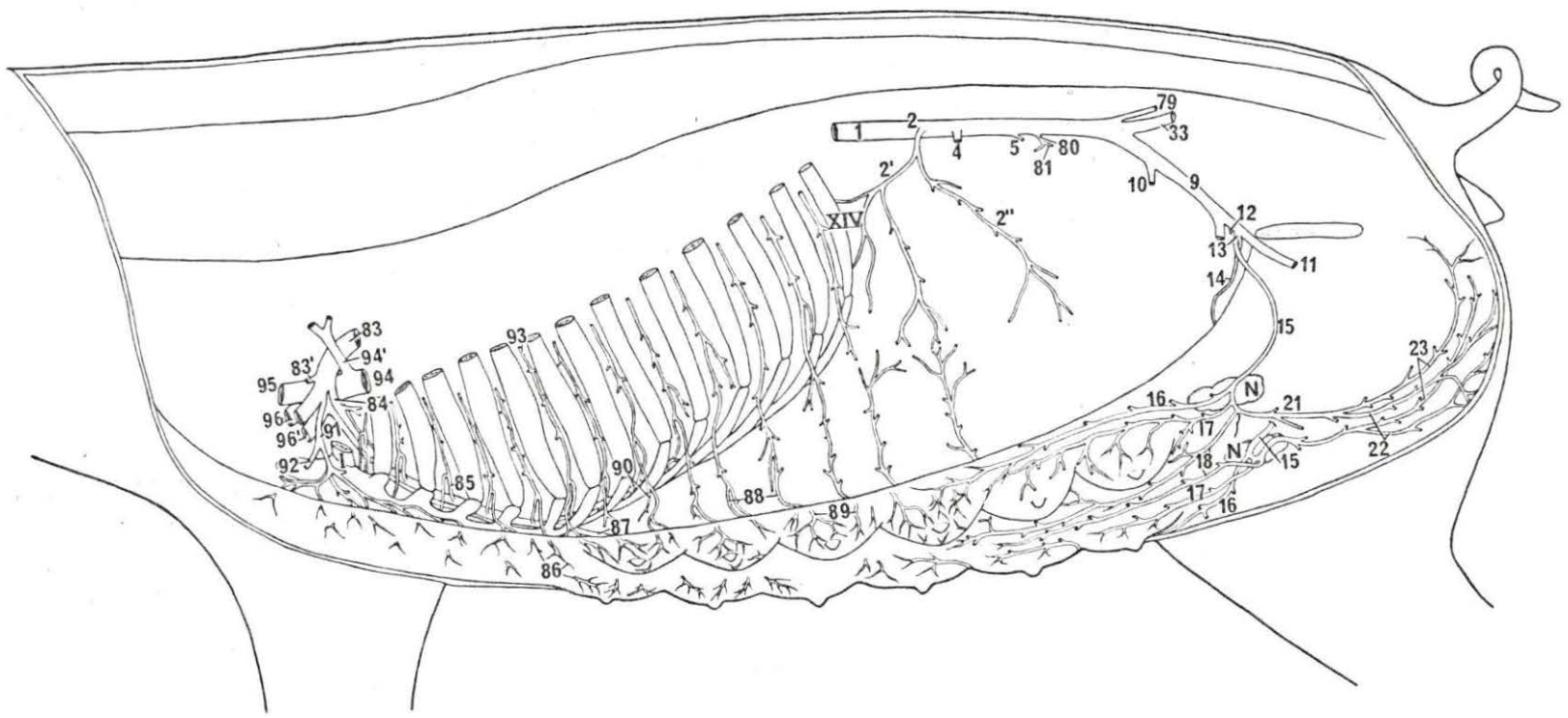


Figure 25. Veins from the genital tract of the female pig (schematic)

- | | | |
|---|--|--|
| A. Ovary | H. Crus of the clitoris cut away from the ischial arch | R. Ureter |
| B. Ovarian bursa | L. M. ischiococcygeus | S. M. sphincter ani externus |
| C. Uterine tube | N. Inn. inguinales superficiales (lifted) | T. Urethra |
| D. Uterine horn | O. Urinary bladder | U. M. constrictor vestibuli |
| E. Body of uterus | P. Rectum | V. M. constrictor vulvae |
| F. Vagina | | X. Broad ligament (cut away from its origin) |
| G. Vulva | | |
| 1. V. cava caudalis | 22. Superficial radicle of 21 | 40. V. urethrogenitalis |
| 5. V. utero-ovarica | 23. Deep radicle of 21 | 41. Cranial root of 40 |
| 5 ¹ . Rami tubouterini | 25. Anastomosis between 15 and 60 | 42. Rami vaginalis |
| 5 ¹¹ . Venous plexus of 5 ¹ | 28. Ramus obturatorius | 43. Rami urethralis |
| 6. Ramus uretericus | 29. Cranial root of 28 | 47. V. vesicalis caudalis |
| 7. Pampiniform plexus | 30. Caudal root of 28 | 46. Urethral (venous) plexus |
| 8. Vv. ovarici | 31. Caudoproximal branch of 11 | 50. Rami uterini |
| 9. V. iliaca externa | 32. V. circumflexa femoris medialis | 50 ¹ . Rami cervicouterini |
| 9 ¹ . V. iliaca communis | 34. Communicant vein between 11 and 60 | 51. Caudal root of 40 |
| 10. V. circumflexa ilium profunda | 35. V. vesicalis cranialis | 53. Vaginal radicles of 51 |
| 11. V. profunda femoris | 36. V. uterina media | 60. V. pudenda interna |
| 12. V. spermatica externa | 36 ¹ . Cranial root of 36 | 60 ¹ . Communicant radicle to 28 |
| 13. Truncus pudendoepigastricus | 36 ¹¹ . Caudal root of 36 | 61. V. urethralis |
| 14. V. epigastrica cranialis | 36 ^v . Anastomotic radicles to 5 | 62 ¹ . Rami vestibularis |
| 15. V. pudenda externa | 36 ^{v1} . Anastomotic radicles to 40 | 62 ¹¹ . V. profunda clitoridis |
| 16. Cranial root of 15 | 36 ^{v11} . Ramuli uterini | 68. V. dorsalis clitoridis |
| 20. Communicant radicles between 15 and V. subcutanea abdominis | 38. V. glutea cranialis | 74. V. glutea caudalis |
| 21. Caudal root of 15 | 39. V. obturatoria | 75. V. hemorrhoidalis caudalis |
| | | 76. V. perinealis |
| | | 78. Root from the M. ischiococcygeus |
| | | 82. Cutaneous radicles of the Vv. caudales laterales |
| | | 97. V. subcutanea abdominis |

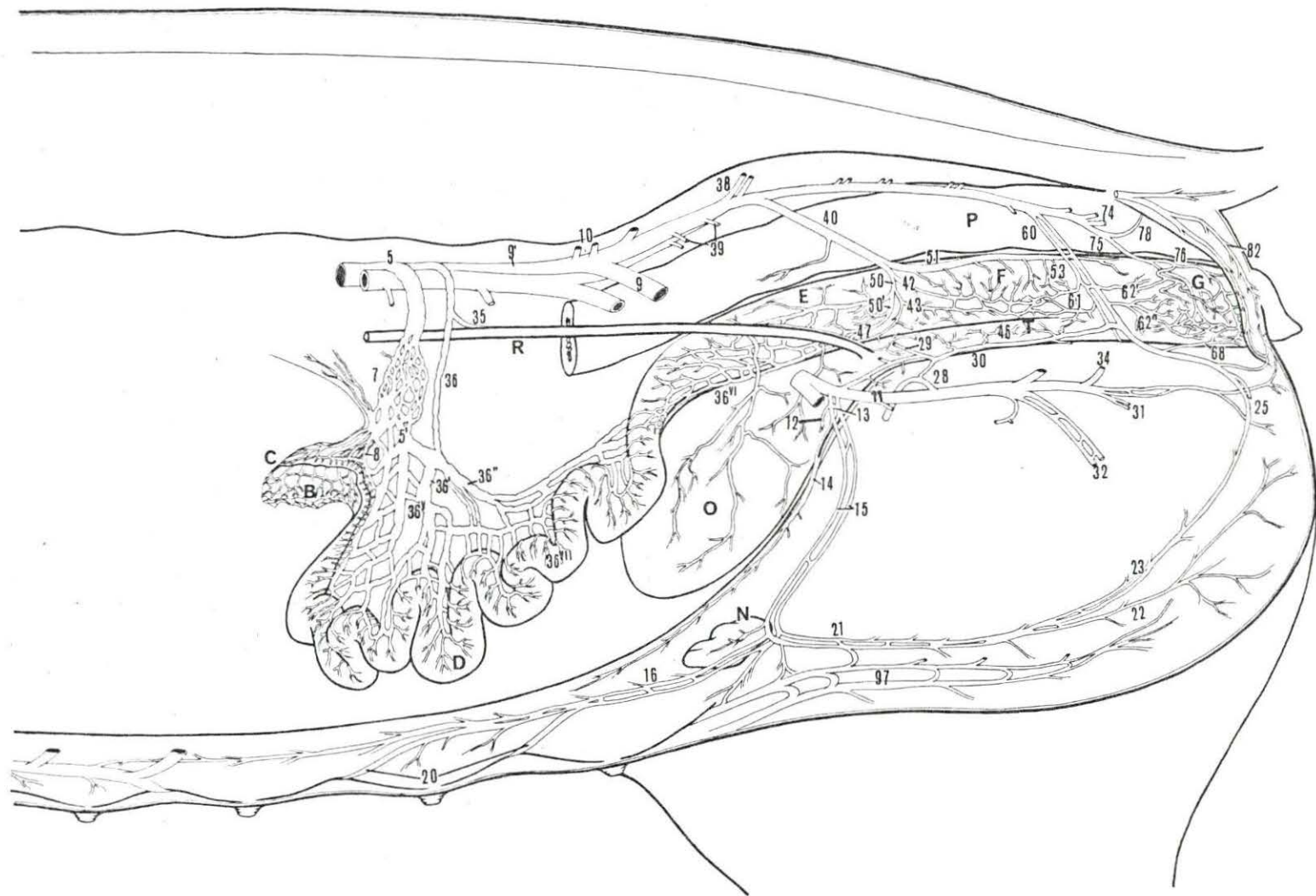


Figure 26. Veins from the ventral aspect of the trunk in the female pig (schematic)

The right side has been dissected superficially. The cranial portion of the left side was exposed after removing the M. rectus abdominis while the caudal portion was deeply dissected and the mammary glands were removed.

- A. Mammary gland
 - B. Xiphoid process (sternum)
 - C. M. rectus abdominis (cut)
 - N. Lnn. inguinales superficiales (reflected)
-
- 15. V. pudenda externa
 - 16. Cranial root of 15
 - 20. Communicant radicles from 97
 - 21. Caudal root from 15
 - 22. Superficial radicle of 21
 - 23. Deep radicle of 21
 - 25. Anastomosis from 15 to the V. pudenda interna
 - 87. V. epigastrica cranialis
 - 88. Lateral roots of 87
 - 89. Medial roots of 87
 - 97. V. subcutanea abdominis
 - 97ⁱ. Anastomotic radicles from 97 to the V. circumflexa femoris medialis and V. saphena parva
 - 97ⁱⁱ. Communicant bridges between 97 of both sides
 - 97ⁱⁱⁱ. Root from the knee fold
 - 97^v. Roots from the lateral wall of the trunk
 - 97^v. Root from the median plane of the ventral aspect of the trunk
 - 97^vⁱ. Anastomotic radicles to the V. saphena magna

Figure 27. Disposition of the A. and V. epigastrica cranialis and M. rectus abdominis (in part)

- A. M. cutaneus trunci together with subcutaneous tissue and skin (exposed)
 - B. Deep face of the M. rectus abdominis
 - C. Costal arch
-
- 87. A. and V. epigastrica cranialis
 - 88. Lateral branch and lateral root of 87
 - 89. Medial branch and medial root of 87

Figure 28. Anastomosis between the V. epigastrica cranialis and V. subcutanea abdominis

- 89. Medial root of V. epigastrica cranialis (cutaneous radicle)
- 97. V. subcutanea abdominis
- 97'''. Communicant bridges between 97 of both sides
- 97'''. Root from the knee fold
- 97'V. Root from the lateral wall of the trunk

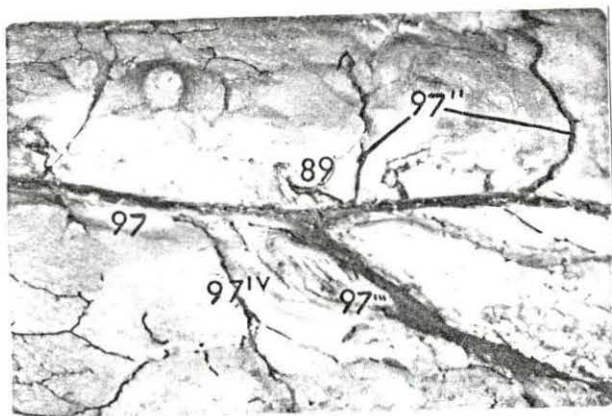
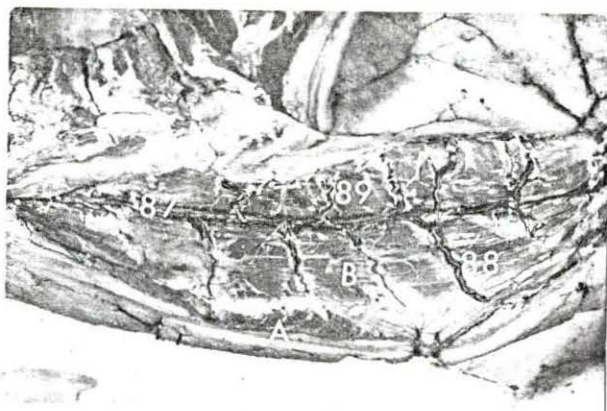


Figure 29. Disposition of the V. subcutanea abdominis in the female pig (cranial portion)

- A. Mammary gland
- B. Infrasternal fossa

- 97. V. subcutanea abdominis
- 97'''. Communicant bridges between 97 of both sides
- 97'''. Root from the knee fold
- 97'v. Root from the lateral wall of the trunk

Figure 30. Disposition of the V. subcutanea abdominis in the female pig (caudal portion)

- A. Mammary gland
- B. Lnn. inguinales superficiales

- 97. V. subcutanea abdominis
- 97'''. Communicant bridges between 97 of both sides
- 97'''. Root from the knee fold

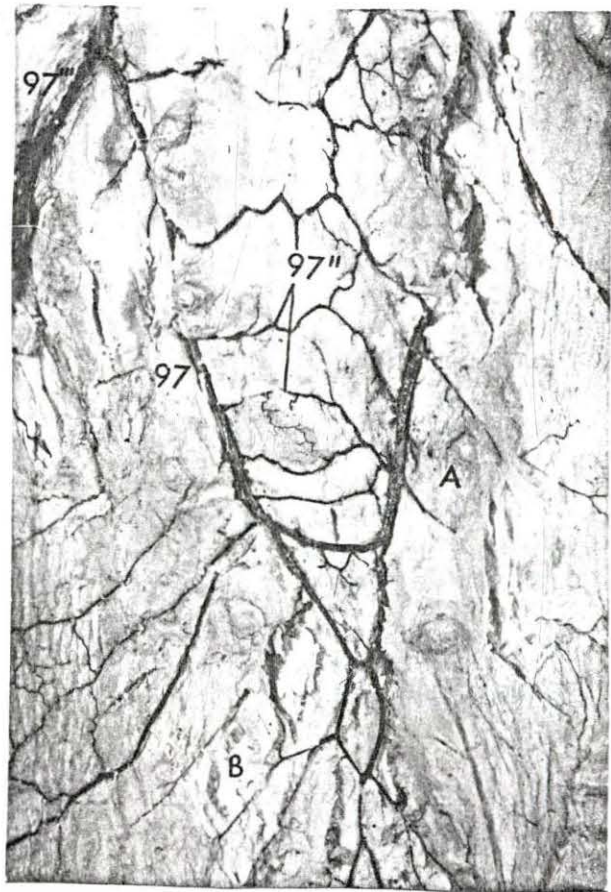
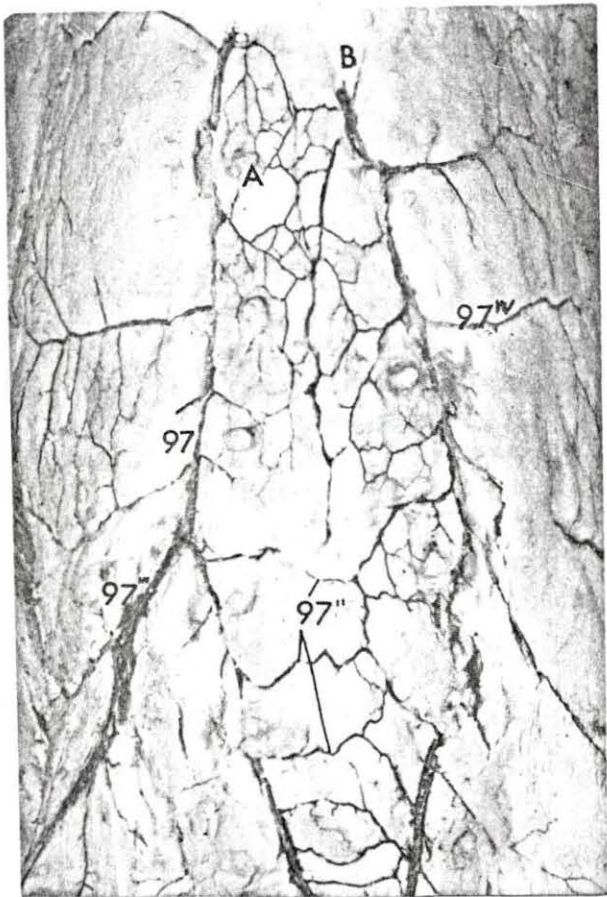


Figure 31. Superficial dissection of the medial side of the thigh showing the anastomotic radicles of the V. saphena magna and parva with the V. subcutanea abdominis

- A. Mammary gland
 - B. Stifle joint (medial)
 - C. Knee fold
- 97'. Cutaneous anastomosis between the radicles of the V. subcutanea abdominis and V. saphena parva and V. circumflexa femoris medialis
- 97^v'. Cutaneous anastomosis between the radicles of the V. subcutanea abdominis and V. saphena magna.
98. V. saphena parva
99. V. saphena magna

Figure 32. Deep dissection of the inguinal region showing the anastomosis between the V. pudenda externa (cranial root) with the V. subcutanea abdominis

- A. Mammary gland
 - B. Lnn. inguinales superficiales
16. Cranial root of the V. pudenda externa
20. Communicant radicles between 97 and 16
97. V. subcutanea abdominis
- 97'''. Root from the knee fold

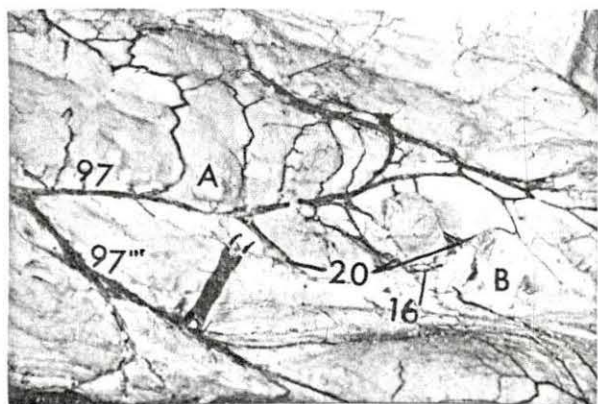
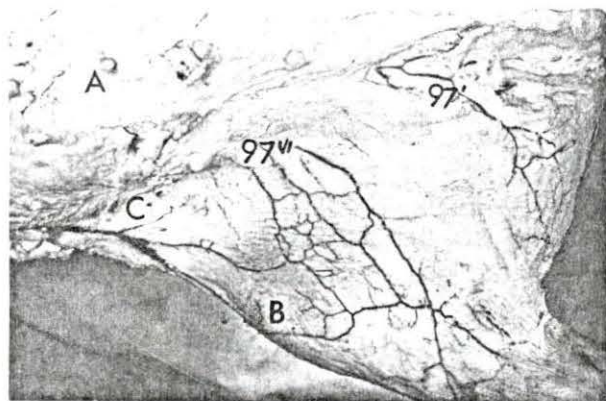
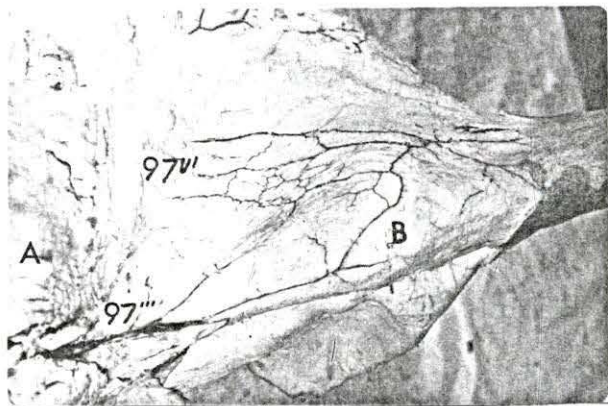
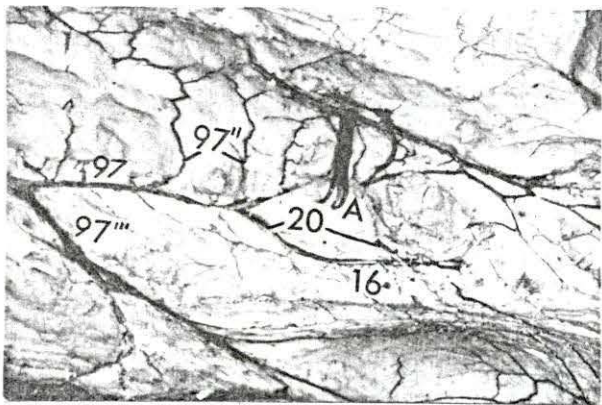


Figure 33. Deep dissection of the inguinal region after reflecting the first inguinal mammary gland

- A. Mammary gland (reflected)
- 16. Cranial root of the V. pudenda externa
- 20. Communicant radicles between 97 and 16
- 97. V. subcutanea abdominis
- 97^{''}. Communicant bridges between 97 of both sides
- 97^{'''}. Root from the knee fold

Figure 34. Anastomosis between the roots of the V. subcutanea abdominis and V. saphena magna

- A. Mammary gland (inguinal)
- B. Stifle joint
- 97^{'''}. Root from the knee fold
- 97^{v'}. Anastomotic radicles from the V. saphena magna



174b

Figure 35. The V. subcutanea abdominis showing its roots from the lateral wall of the trunk

- A. Mammary gland
- B. Skin (reflected)
- C. Knee fold

97'v. Roots from the lateral wall of the trunk

Figure 36. Dissection of the infraesternal fossa exposing the termination of the medial root of the V. subcutanea abdominis

- A. Mammary gland
- B. Infraesternal fossa

97. V. subcutanea abdominis

97v. Root from the median plane of the ventral wall of the trunk

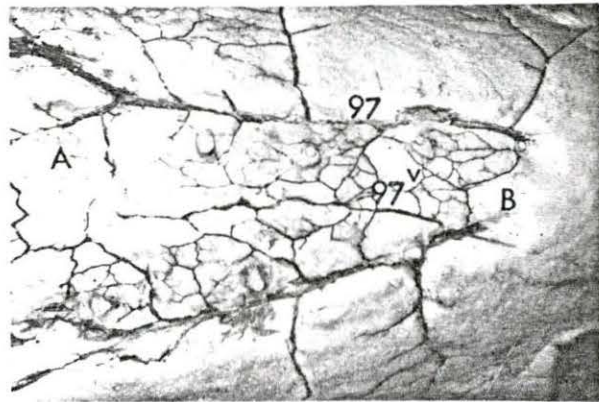
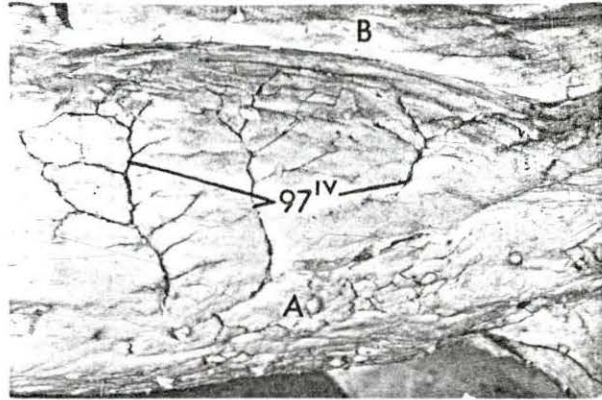


Figure 37. Origin of the medial root of the V. subcutanea abdominis at the level of the knee fold

- A. Mammary gland
- B. Median line
- C. Knee fold

- 97. V. subcutanea abdominis
- 97^v. Root from the median line of the ventral wall of the abdomen

Figure 38. Superficial dissection of the perineal region of the female pig

- A. Tail
- B. Vulva
- C. Anus

- 25. Anastomosis between the V. pudenda externa and the V. pudenda interna
- 82. Cutaneous roots of the V. caudalis lateralis
- 82'. It can be seen that a single vessel from the perivulvar tissues joins the anastomosis (25) between the V. pudenda externa and V. pudenda interna. This vessel is also connected with the cutaneous radicles of the V. caudalis lateralis.

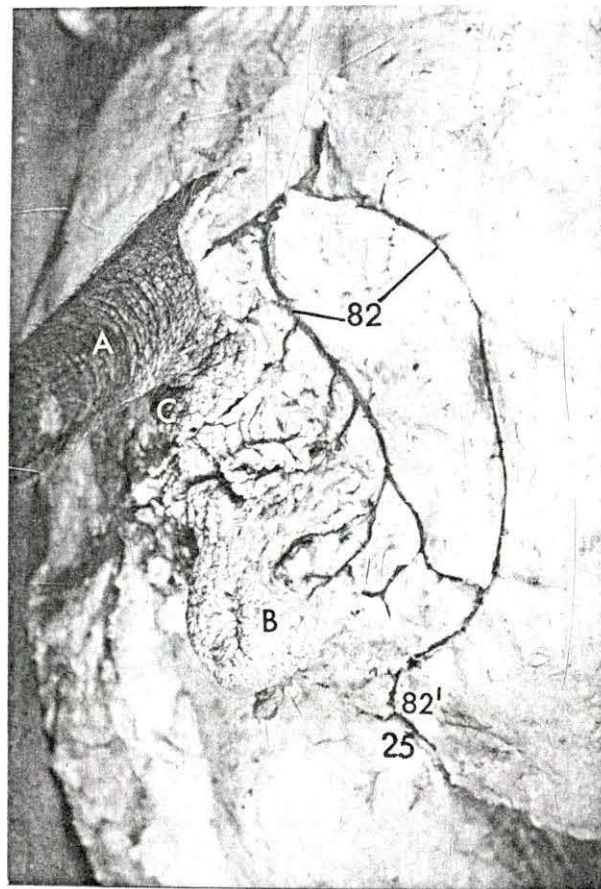
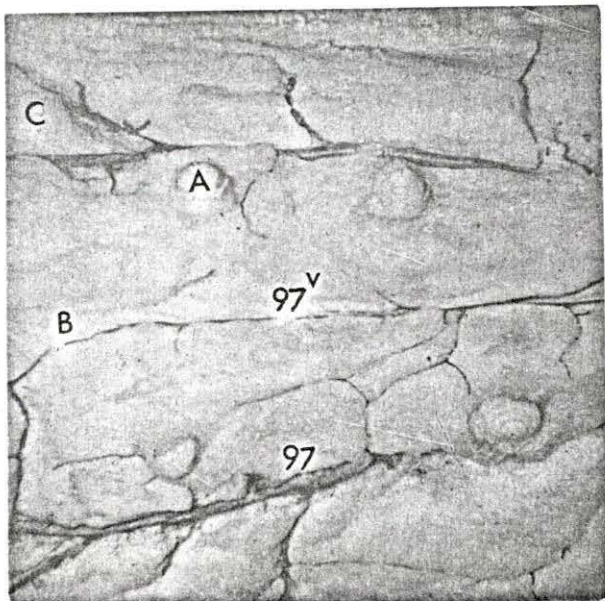


Figure 39. Termination of the A. and V. pudenda externa in the female pig

- A. Mammary gland
 - B. Uterine horn
 - C. Symphysis pelvis (cut)
 - D. Lnn. inguinales superficiales
-
- 9. A. and V. iliaca externa
 - 15. A. and V. pudenda externa at the external inguinal ring
 - 16. Lateral cranial branch and cranial root of 15
 - 17. Middle cranial branch of 15
 - 18. Medial cranial branch of 15
 - 21. Caudal branch and caudal root of 15
 - 22. Superficial branch and superficial radicle of 21
 - 23. Deep branch and deep radicle of 21
 - 25. Anastomotic trunk between 15 and 60
 - 60. A. and V. pudenda interna

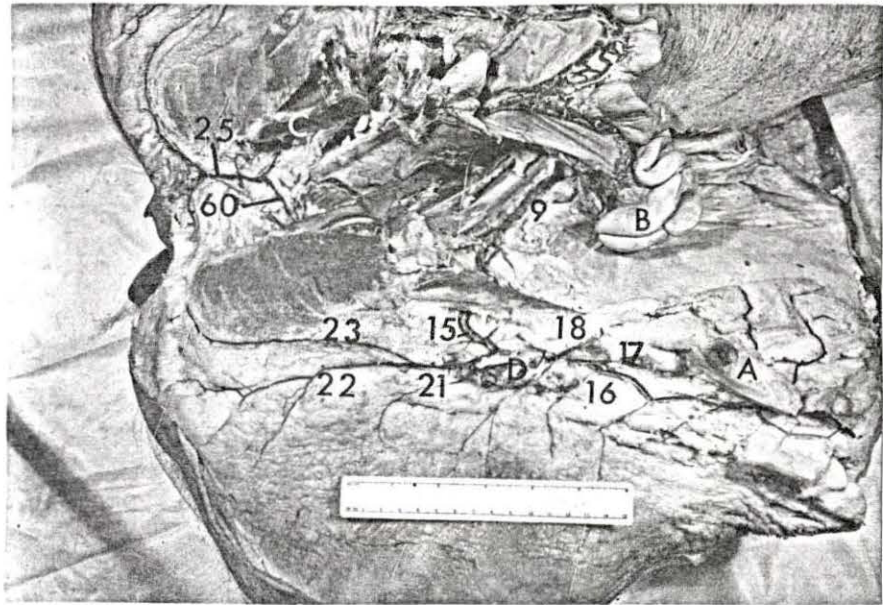


Figure 40. Deep dissection of the perineum in the female pig

C. Symphysis pelvis (cut)

- 15. A. and V. pudenda externa at the external inguinal ring
- 22. Superficial branch and superficial radicle of the caudal branch and caudal root of the A. and V. pudenda externa
- 23. Deep branch and deep radicle of the caudal branch and caudal root of the A. and V. pudenda externa
- 25. Anastomotic trunk between 15 and 60
- 60. A. and V. pudenda interna

Figure 41. Deep dissection of the perineum in the female pig (close-up view)

C. Symphysis pelvis (cut)

- 25. Anastomotic trunk between A. and V. pudenda externa and 60
- 60. A. and V. pudenda interna
- 68. V. dorsalis clitoridis

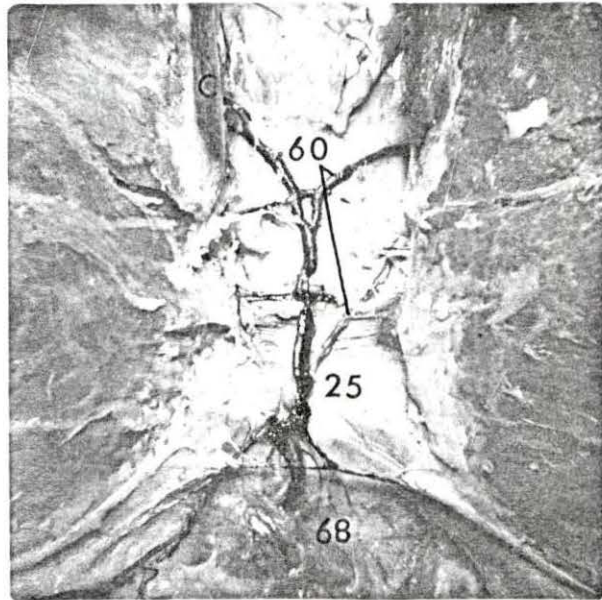
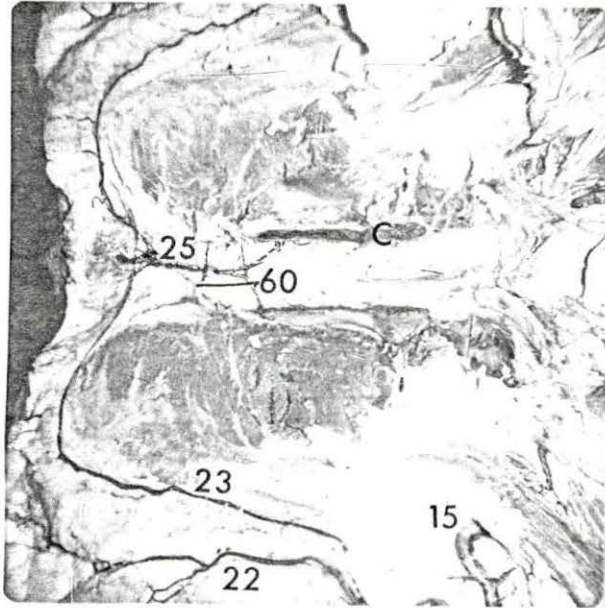


Figure 42. Latex cast of the arteries of the genital tract of the female pig

- A. Ovary
- B. Uterine horn
- C. Vagina
- D. Vulva

- 5. A. utero-ovarica
- 8. A. ovarica
- 36. A. uterina media
- 36'' . Primary branches of 36
- 40. A. urethrogenitalis
- 41. Cranial branch of 40
- 51. Caudal branch of 40 (A. perinealis of Preuss, 1959)
- 60. A. pudenda interna

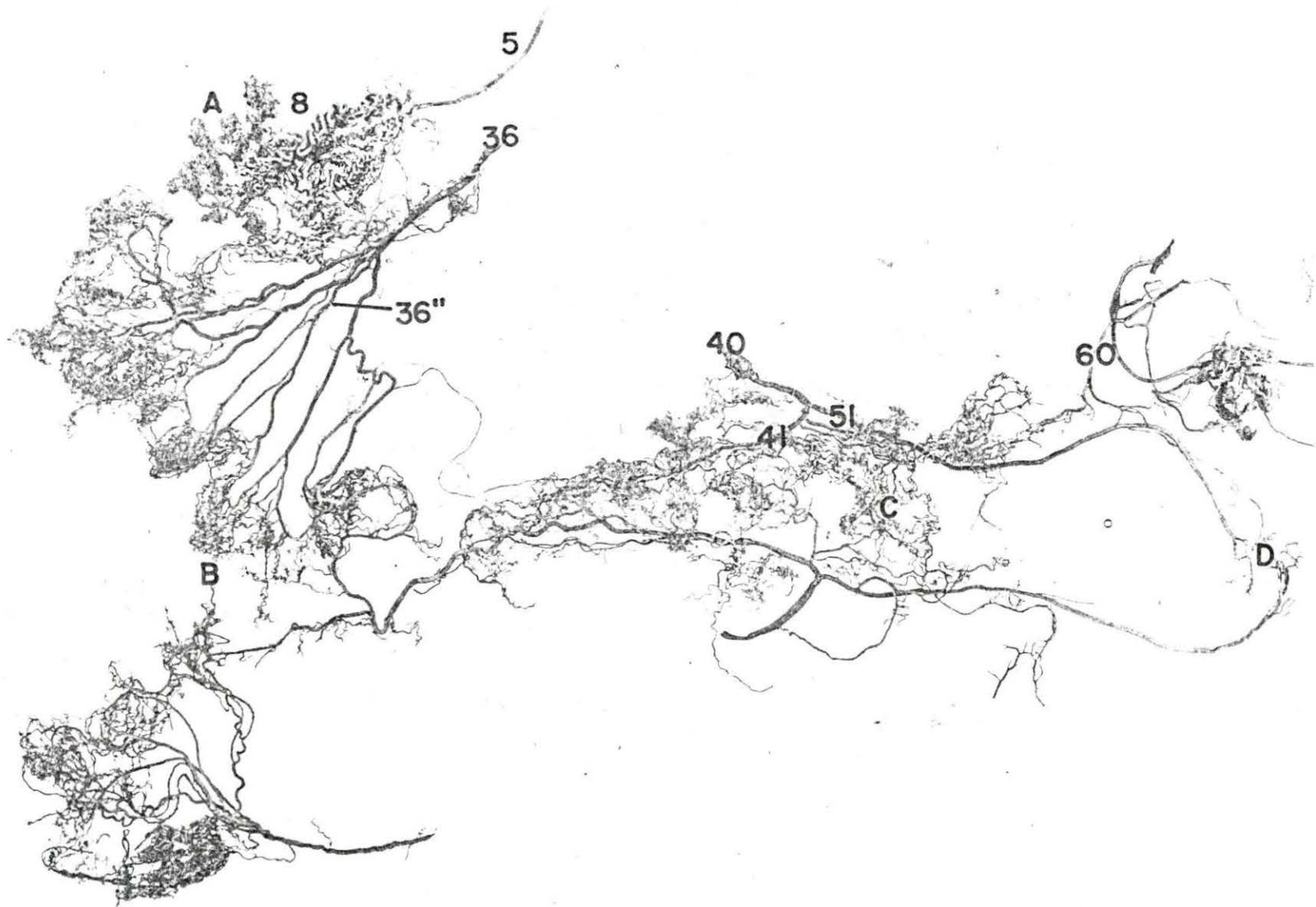


Figure 43. Dissection of the medial side of the mesometrium showing the arterial meshwork of the caudal branch of the A. utero-ovarica (the arteries were injected with yellow latex)

- A. Ovarian bursa
- B. Ovary
- C. Lnn. uterini
- D. Uterine horn
- E. Ligament proper of the ovary

- 5. A. utero-ovarica
- 5'. Caudal branch (Rami tubouterini) of 5
- 5''. Arterial plexus of 5'
- 8. A. ovarica
- 36. A. uterina media
- 36V. Anastomosis between 36 and 5

Figure 44. Dissection of the medial side of the mesometrium showing the blood supply of the uterine tube (the arteries were injected with yellow latex)

- A. Ovarian bursa
- B. Ovary
- C. Uterine tube
- D. Uterine horn
- E. Ligament proper of the ovary

- 5''. Arterial plexus of 5'
- 36. A. uterina media
- 36V. Anastomosis between 36 and A. utero-ovarica

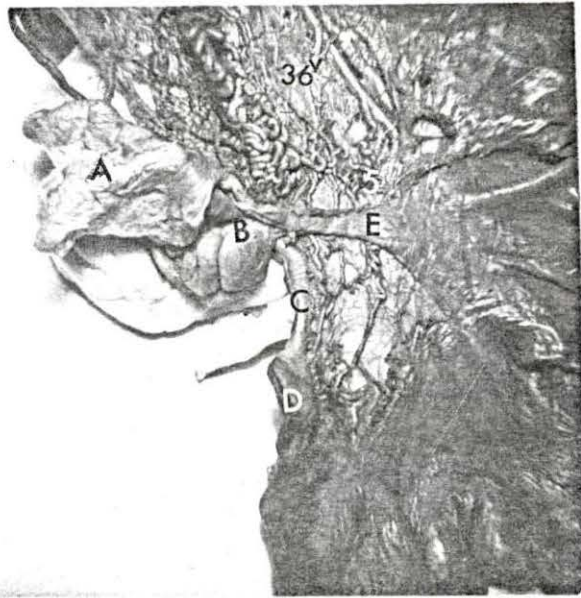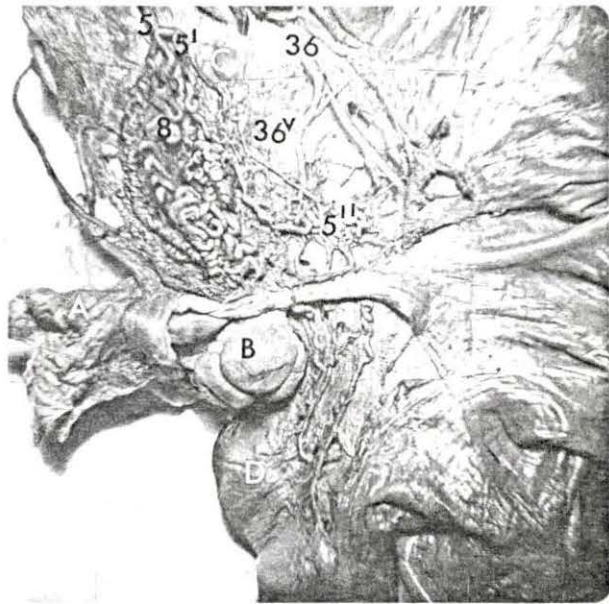


Figure 45. Latex cast of the A. utero-ovarica

- A. Extent of the follicle
 - 5. A. utero-ovarica
 - 5'. Caudal branch (Rami tubouterini) of 5
 - 5''. Arterial plexus of 5'
 - 8. A. ovarica
 - 8'. Spiral artery of 8
 - 36. A. uterina media

Figure 46. The termination of the A. utero-ovarica (close-up view)

- B. Tag used for separating the coils of 8
 - 5. A. utero-ovarica
 - 5'. Caudal branches (Rami tubouterini) of 5
 - 8. A. ovarica

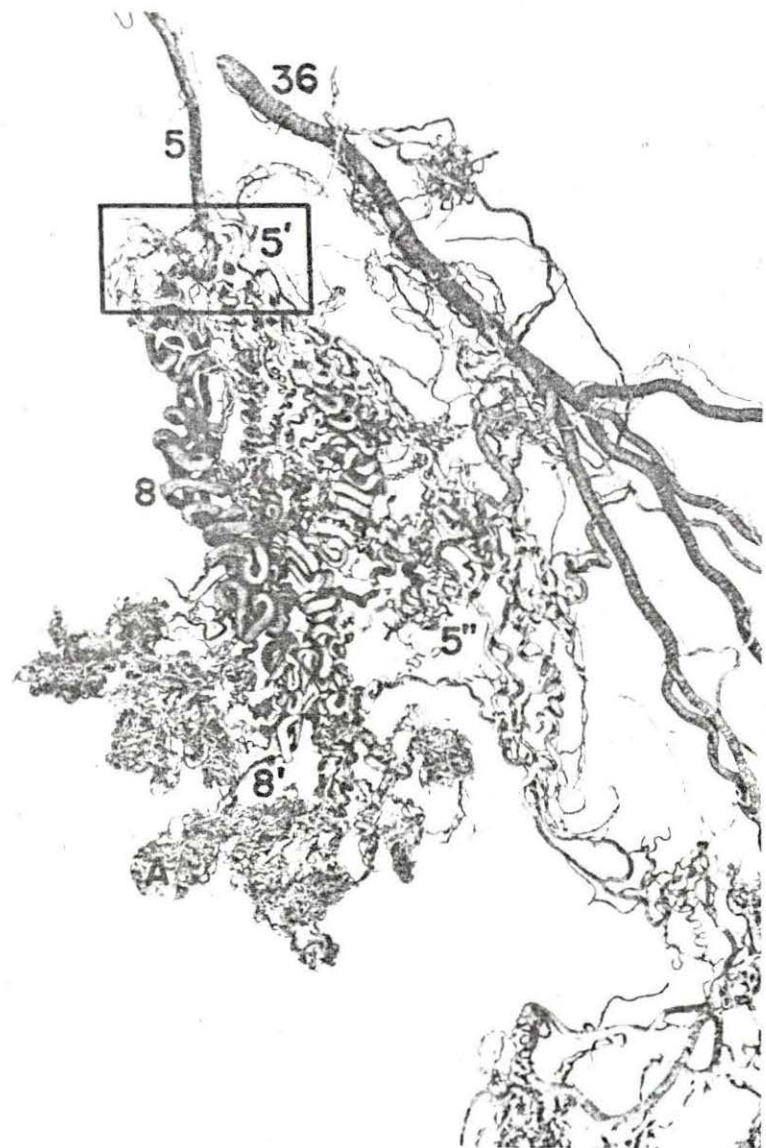


Figure 47. Latex cast of one spiral artery of the ovary (lateral view)

- 8'. Spiral artery of the ovary
- 8''. Branches of 8' forming the follicular wreaths

Figure 49. Latex and Vinyl cast of the spiral artery and vein of the ovary (the vein was injected with vinyl)

- A. Extent of the follicle
- 8'. Spiral artery of the ovary
- 8''. Branches of 8' forming a follicular artery wreath

Figure 48. Latex cast of one spiral artery of the ovary (medial view)

- 8'. Spiral artery of the ovary
- 8''. Branches of 8' forming the follicular arterial wreaths

Figure 50. Latex and vinyl cast especially showing the spiral vein of the ovary

- A. Extent of the follicle
- 8'. Spiral vein of the ovary
- 8''. Radicle of 8' forming a follicular venous wreath (It is observed that the veins had a flattened appearance)


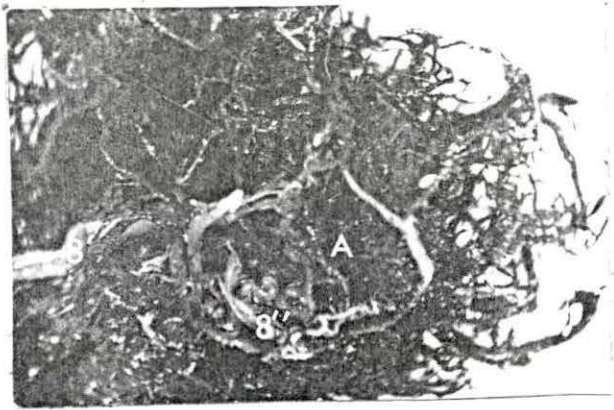
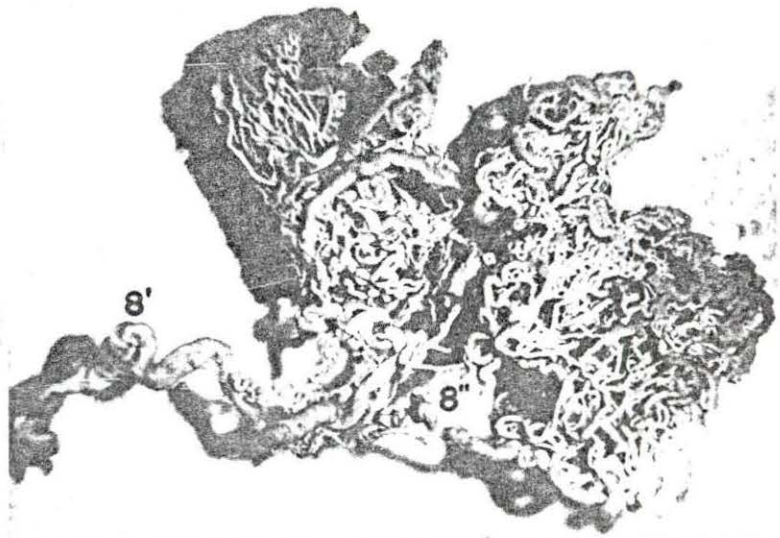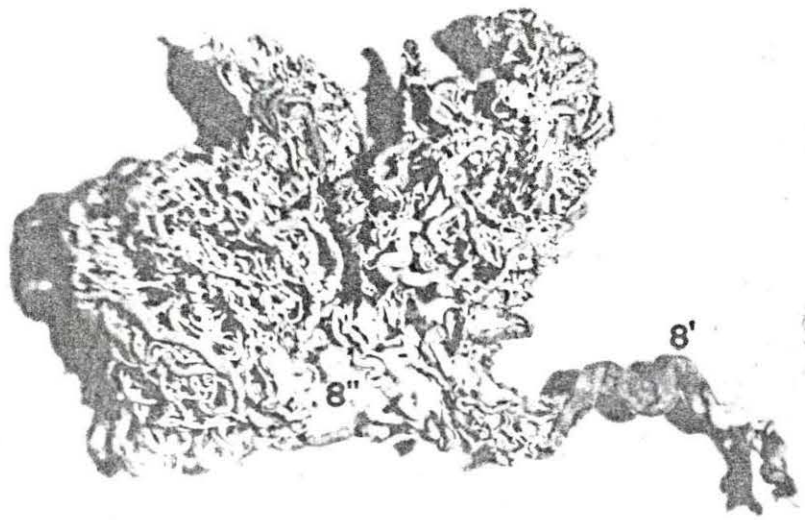


Figure 51. Blood supply of the ovarian bursa showing the disposition of the vessels (cranial view)

- A. Ovary (partly exposed)
- B. Ovarian bursa
- C. Uterine tube

Figure 52. Blood supply of the ovarian bursa showing the vascular arrangement (medial view)

- A. Uterine tube
- B. Ovarian bursa
- C. Hilus of the ovary

Figure 53. Transparent view of the ovarian bursa and fimbria showing the vascular disposition

From Figures 51, 52, and 53, it is evident that each arterial trunk is accompanied by a pair of satellite veins, one on each side.

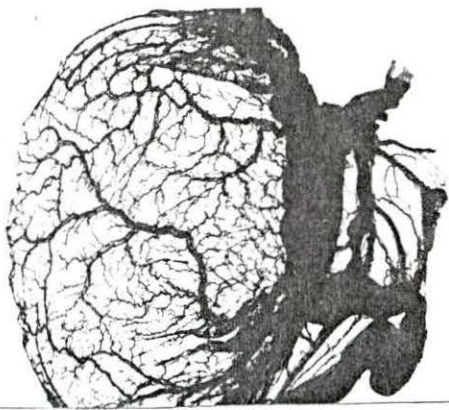
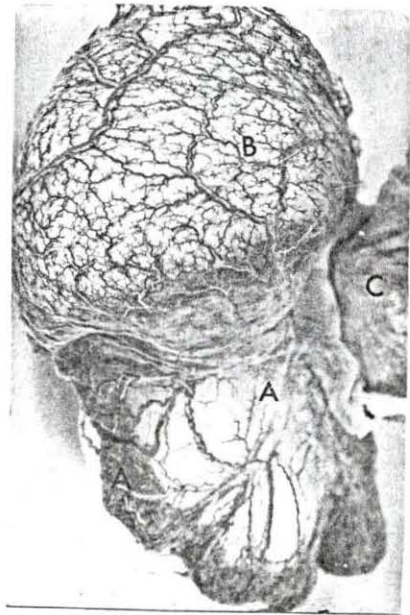
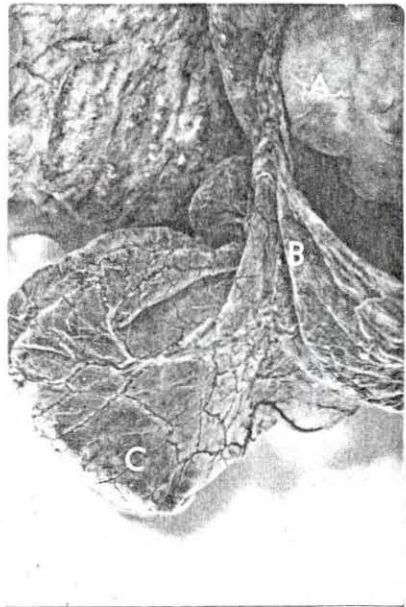


Figure 54. Venous drainage of the ovarian bursa, fimbria and the tip of the uterine horn

- A. Ovarian bursa
- B. Uterine tube
- C. Uterine horn (tip)

5. V. utero-ovarica
(The venous archades on the mesometrium and mesosalpinx are visible.)

Figure 55. Roots of the V. utero-ovarica forming the archades along the uterine tube (close-up view)

- A. Uterine tube
- 5. V. utero-ovarica

Figure 56. Latex cast of the ovary and uterine tube showing the pampiniform plexus and the arterial plexus of the caudal branch of the A. utero-ovarica (lateral view)

- A. Ovary
- B. Ovarian bursa
- C. Uterine tube
- D. Uterine horn

5''. Arterial plexus of the caudal branch of A. utero-ovarica
7. Pampiniform plexus of the ovary
36. A. uterina media

Figure 57. Medial view of Figure 56

- A. Ovary
- B. Ovarian bursa
- C. Uterine horn

5''. Arterial plexus of the caudal branch of A. utero-ovarica
7. Pampiniform plexus of the ovary
36. A. uterina media

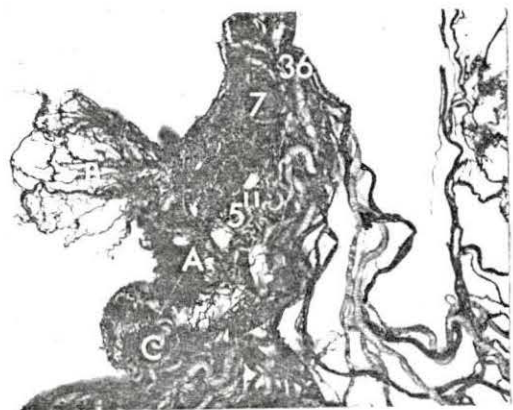
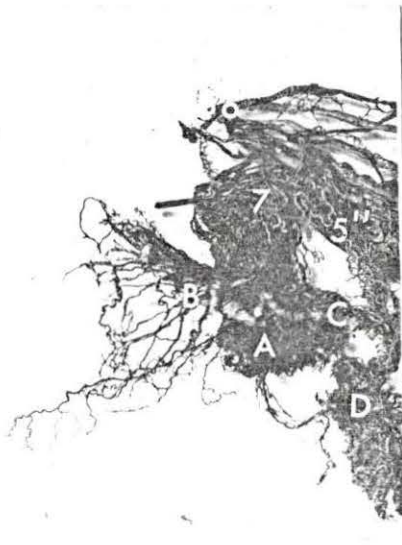
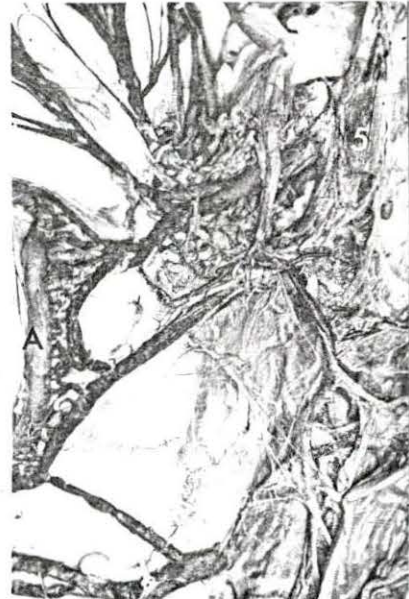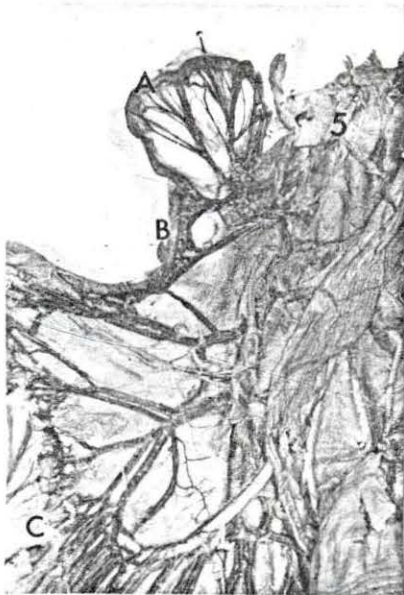Figure 58. Latex cast of the A. uterina media

- 5. A. utero-ovarica
- 8. A. ovarica
- 36. A. uterina media
- 36'. Main branches of 36
- 36''. Primary branches of 36
- 36'''. Secondary branches of 36
- 36'v. Communicant branches between 36'' and the broad ligament
- 36v. Communicant branches to the Rami tubouterini
- 36v'. Communicant branches to the caudal branch of A. urethrogenitalis
- 36v''. Ramuli uterini

Figure 59. Disposition of the A. uterina media in the broad ligament (lateral view)

- A. Ovary
- B. Uterine tube
- C. Uterine horn

- 36. A. uterina media (cut)
- 36'. Main branches of 36
- 36''. Primary branches of 36
- 36'''. Secondary branches of 36
- 36'v. Branches to the broad ligament
- 36v. Communicant branches to Rami tubouterini
- 36v''. Ramuli uterini

Figure 60. Latex cast of the blood vessels of the uterus and uterine horn (lateral view)

- 36. A. uterina media
- 36'^{''}. Primary branches of 36
- 36^{v'}. Communicant branches from 36 to 40
- 40. A. urethrogenitalis
- 41. Cranial branch of 40
- 50. Rami uterini
- 50'. Rami cervico-uterini
- 51. Caudal branch of 40 (A. perinealis)

Figure 61. Latex cast of the blood vessels of the uterus and uterine horn (medial view)

- A. Ovary
- B. Ovarian bursa
- C. Uterine horn
- D. Uterus (body)

- 7. Pampiniform plexus of the ovary
- 36. A. and V. uterina media

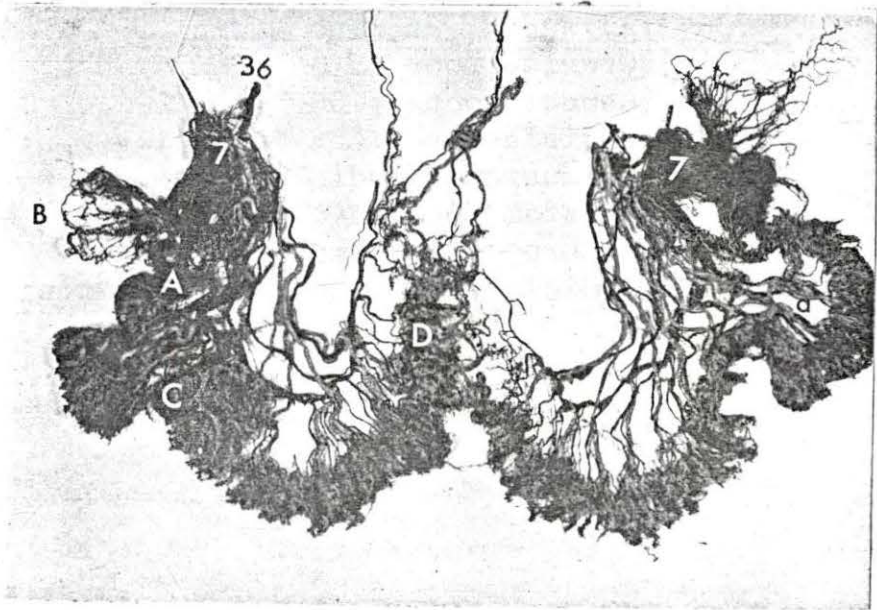
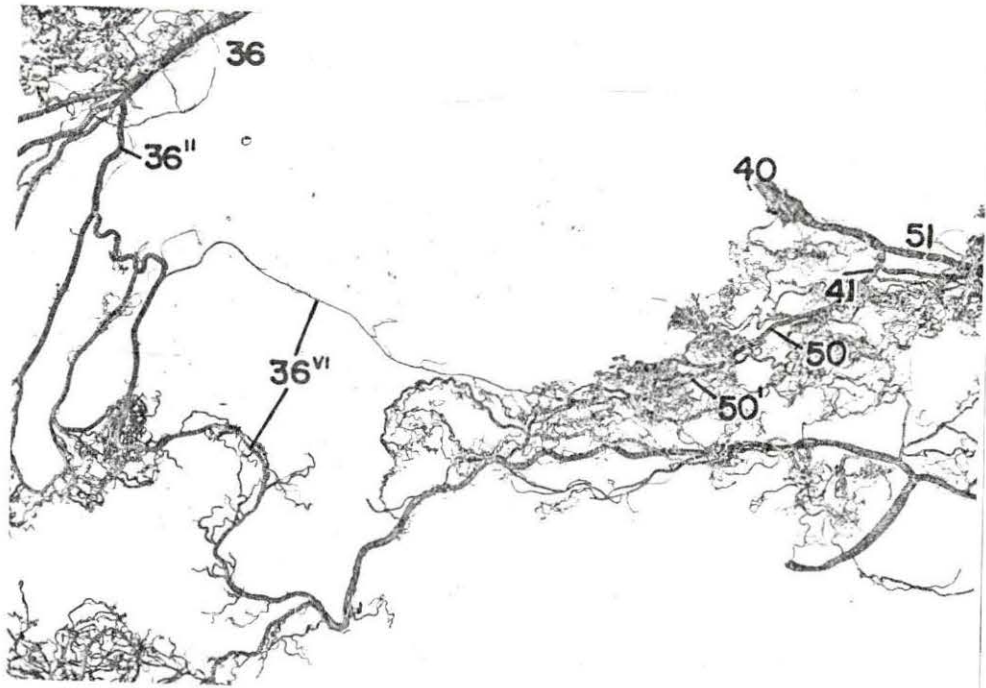


Figure 62. Disposition of the V. utero-ovarica and V. uterina media

- A. Lnn. uterini
- B. Ovary

- 5. V. utero-ovarica
- 36. A. and V. uterina media
- 36'. Cranial root of 36
- 36''. Caudal root of 36
- 36'v. Radicles from the broad ligament
- 36^{v'}. Anastomotic radicles from 36 to V. urethrogenitalis
- 36^{v''}. Radicles from the Ramuli uterini

Figure 63. Disposition of the V. utero-ovarica and V. uterina media showing anastomotic bridges between them along the ventral surface of the uterus

- A. Lnn. uterini

- 5. V. utero-ovarica
- 36. A. and V. uterina media
- 36'. Cranial root of 36
- 36''. Caudal root of 36
- 36'v. Radicles from the broad ligament
- 36v. Communicant radicles between 36 and 5
- 36^{v'}. Anastomotic radicles from 36 to V. urethrogenitalis
- 36^{v''}. Radicles from the Ramuli uterini

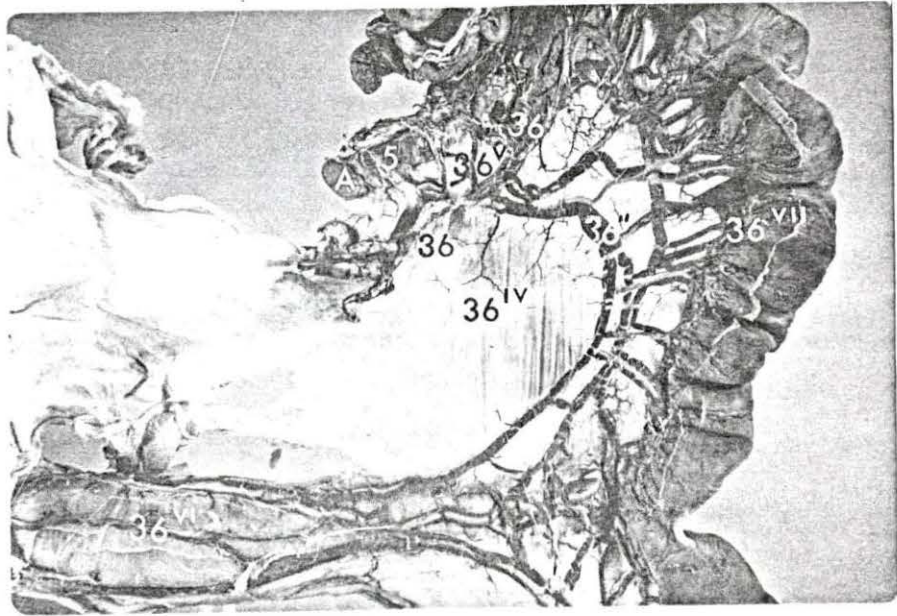
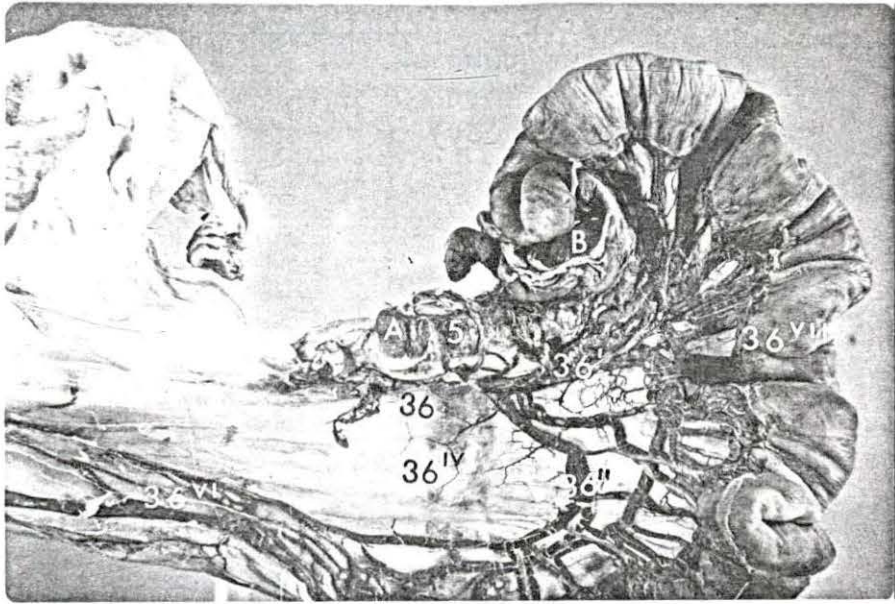


Figure 64. Disposition of the V. urethrogenitalis in the female pig.

- A. Ovary and ovarian bursa
- B. Uterine tube
- C. Uterine horn
- D. Uterus (body)
- E. Vagina
- F. Vulva
- G. Rectum
- H. Urinary bladder
- I. Ureter

- 40. V. urethrogenitalis
- 41. Cranial root of 40
- 51. Caudal root of 40

Figure 65. Disposition of the V. urethrogenitalis in the female pig (close-up view)

- E. Vagina
 - F. Vulva
 - G. Rectum
 - H. Urinary bladder
 - I. Ureter
-
- 40. V. urethrogenitalis
 - 41. Cranial root of 40
 - 42. Rami vaginalis
 - 43. Ramus urethralis
 - 51. Caudal root of 40

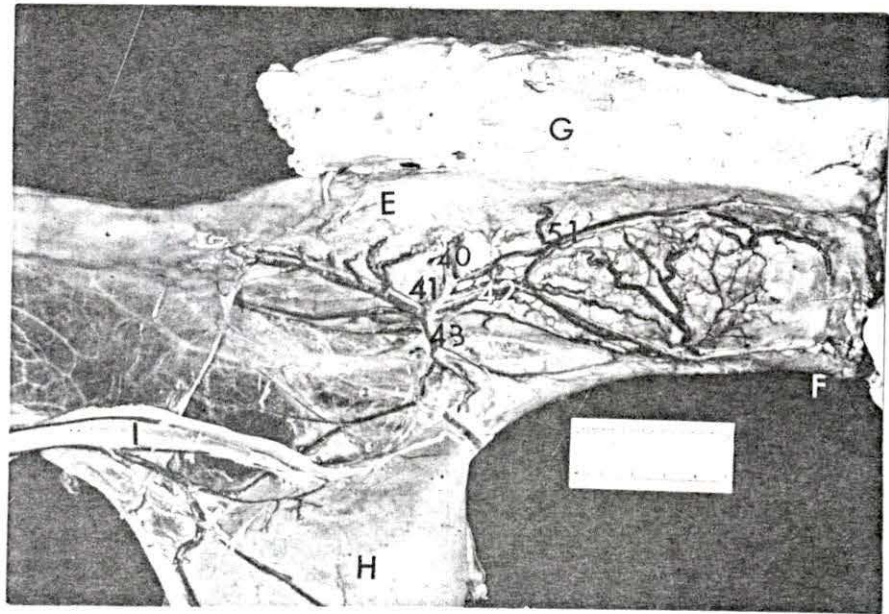
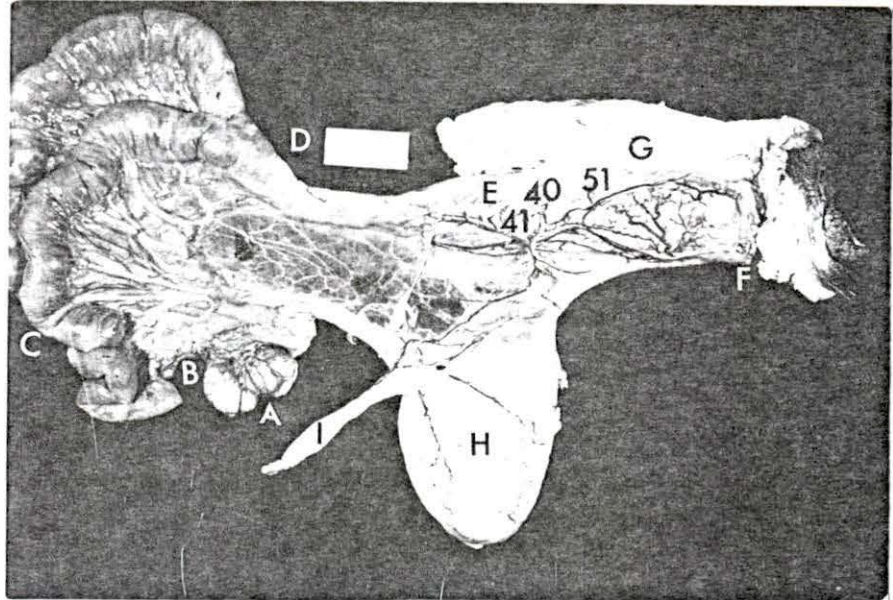


Figure 66. Latex cast of the vessels of caudal portion of the vagina and the erectile tissue of the vestibule of the vulva (medial view)

- A. Vagina
 - B. Vulva
 - C. Arterial circle of 51
 - D. Vestibular bulb
-
- 40. A. urethrogenitalis
 - 41. Cranial branch of 40
 - 51. Caudal branch of 40
 - 60. A. pudenda interna

Figure 68. Latex cast of the vessels of the erectile tissue of the vestibule of the vulva (medial view)

- B. Vulva
 - C. Arterial circle of 51
 - D. Vestibular bulb
-
- 51. Caudal branch of A. urethrogenitalis
 - 60. A. pudenda interna

Figure 67. Latex cast of the vessels of the caudal portion of the vagina and the erectile tissue of the vestibule of the vulva (lateral close-up view)

- A. Vagina
 - B. Vulva
-
- 51. Caudal branch of A. urethrogenitalis
 - 53. Anastomotic branch from 51 to 60
 - 60. A. pudenda interna
 - 61. Anastomotic branch from 51 to A. urethralis of 60

Figure 69. Latex cast showing the arterial circle of the caudal branch of the A. urethrogenitalis (medial close-up view)

- B. Vulva
 - C. Arterial circle of 51
 - D. Vestibular bulb
-
- 51. Caudal branch of A. urethrogenitalis
 - 60. A. pudenda interna

