RADIOGRAPHIC DEMONSTRATION OF INDUCED PERIARTICULAR AND ARTICULAR ARTHRITIS IN THE STRESSED SKELETALLY IMMATURE HORSE (EQUUS CABALLUS)

by

Horst Paul Neubauer

A Thesis Submitted to the
Graduate Faculty in Partial Fulfillment of
The Requirements for the Degree of
MASTER OF SCIENCE

Major Subject: Veterinary Radiology

Iowa State University
Ames, Iowa

1968

TABLE OF CONTENTS

INTRODUCTION

Man's resurgent interest in the horse is evident as the pleasure breeds steadily increase in numbers from one year to another. There is, however, no population explosion of the equine species. The increase in leisure time has caused us to transfer the horse from the economically important draft animal into a pleasure and companion animal. Due to this fact, man is now in closer contact with the horse than ever before. In riding, racing, driving, and in trail rides more attention is being paid to the safety of locomotion in the horse. This contact has an indirect but close relationship to man's own health and well being. Persons who enjoy horses, regardless of the degree of experience they have had with equitation, are not going to trust themselves to ride or drive a known lame horse. The danger that the horse might stumble, fall and injure the rider or driver is obvious. It is evident, then, that the shift in importance from draft to pleasure purposes has increased the demands of owners on the breeders, handlers, judges and veterinarians. The greatest demand is that a horse not only be sound but safe.

In judging the individual horse, more attention is being paid today to the perfect conformation of the extremities. Their function in support and locomotion of the body is important both to the individual performance of the animal and the safety of the owner. The fact that the extremities bear the body weight as well as supply the propulsive force for locomotion explains why these body parts are exposed to multiple stresses and injuries. Due to the direct influence of variations in tension, pressure, and stress effects upon the bony skeleton and upon the tendon-ligament apparatus, the lower leg regions are more affected. The treatment of lamenesses, therefore, constitutes a large portion of equine practice.

Diagnosis and accurate prognosis of diseases and malformations of the limb are very important both to the practitioner and the owner, because the accuracy of the diagnosis marks the sharp line between usefulness and uselessness of the horse. This places a great burden on the veterinarian. It would be inexcusable to use treatments to make a horse sound if these treatments in any way jeopardized the safety of the animal for riding or driving.

As science advances, new ways and means of treating unsoundnesses become available. Just which modern scientific method and device to use in order to correct a lameness must be determined. Even more important than treatment is the discovery of ways and means of preventing the occurrence of lameness in the first place.

Ever since the beginning of the 20th century, radiography has been used as a diagnostic aid, not only in human medicine, but also in veterinary medicine. In many cases the radiological examination of the lame horse is not only important to insure a proper diagnosis but it also allows an immediate prognosis. Some types of lameness are caused by a structural change and, therefore, are more in the nature of a mechanical disorder. Gross anatomical alterations of the bony skeleton may require a considerable period of time before a mechanical hindrance to normal function becomes evident. The earlier a disease process of this chronic nature can be recognized, the better is the chance for successful treatment.

The objective of this investigation was to determine the effect of uneven foot axes, such as are caused by improperly trimmed feet and/or faulty shoeing on the genesis of articular and periarticular ringbone in the skeletally immature horse. The fact that the horse must not only support the weight of its own body but also the weight of its rider was considered. The possibility that direct and sudden stress upon the collateral ligaments might cause a forcible separation of the periosteum from the bone with subsequent new bone production beneath, known as exostoses or osteophytes, appeared to warrant investigation.

In the review of the literature on ringbone, it will be shown that investigators not only agree, but accept the fact that poor conformation and stress are etiologically responsible for ringbone, a pathological entity which is rather common in the equine species.

Clinical experience has revealed that the occurrence of periarticular ringbone is relatively rare in Shetland ponies as compared to other breeds. If one should be successful in creating any periarticular new bone formation in Shetland ponies by artificially creating abnormal stress and poor conformation, it could then be assumed that these factors were etiologically responsible in breeds predisposed to this disease. The growing horse seems to be especially predisposed to these alterations and for this reason recommendations have been made by veterinarians over the years to avoid racing Thoroughbreds as well as Standardbreds under two years of age. Vickers (40) makes an appeal for judgment and reasoning concerning the racing of young Thoroughbreds.

REVIEW OF LITERATURE

Diseases of the joints have always been of great importance in veterinary surgery. The diagnosis as well as the treatment have been discussed to a great extent in the professional literature.

Terminology

Articular and periarticular arthritis in the pastern region are of special interest to the surgeon and pathologist because of their clinical and economical importance. But over and above this, investigators have found that changes of the normal bone and joint structure, mainly in older horses, are rather common, and that clinical signs are not necessarily connected with the pathological findings (Fehlow, 13; Ullrich, 39). As early as 1751, Gibson (15) mentioned a hard swelling on the lower part of the pastern, which he called "ringbone."

Later textbooks of veterinary surgery do not seem to agree on the term "ringbone." While in the German literature (Nieberle and Cohrs, 25; Silbersiepe and Berge, 32), three sites of ringbone are recognized, Frank (14), Dollar (9) and other American and Irish authors accepted only two, namely, the ringbone of the coronary joint and of the coffin joint (high and low ringbone). Arthritis and periarthritis ossificans of the fetlock joint are referred to as osselets.

J. V. Lacroix (21) applied the term ringbone to all exostoses involving the first and second phalanges, regardless of their size, extent or location. Lesions in which the exostoses occur at the level of one of the interphalangeal joints are called true ringbone. Those lesions which occur quite clear of these joints are called false ringbone.

Another classification divides ringbone into articular and periarticular types.

The authors of Equine Medicine and Surgery (Bone, Catcott, Gabel, Johnson and Riley, 6) spoke of ringbone whenever the articular surfaces of one or more joints below the fetlock were diseased or eroded. Arthritis of any of these joints usually is attended sooner or later by the development of osteophytes surrounding the edges of the articular surfaces.

Generally, it is accepted that the term "ringbone" applies whenever new bone growth occurs on the first, second or third phalanges. This excessive bone production is the result of periosteal new bone formation and often leads to an osteoarthritis or even ankylosis of the pastern or coffin joints (Adams, 1).

Pathogenesis

According to Nieberle and Cohrs (25), ringbone is a chronic deforming arthritis or periarthritis of the phalangeal joints of ungulates, especially the horse. After destruction of the joint cartilage ossifying granulation tissue can connect both surfaces of the joints (ankylosis vera). As a consequence, the subchondral bone becomes atrophic.

Periarticular ringbone is more frequent than the articular form. It is a direct consequence of a chronic inflammation of the band apparatus and of the periosteum (periosteal new bone formation). Whenever traumatized, periosteum may react with a chronic proliferating inflammation. This results in new bone growth, which in reality is granulation tissue composed of bone instead of the usual fibrous tissue. Such proliferations are usually strictly localized and are called exostoses or osteophytes (Smith and Jones, 34).

There seems to be a considerable controversy as to the seat of the primary change in this affliction. Some researchers (Joest, 19) sought the origin in the destruction of the joint cartilage with resulting scars, while Bayer and Froehner (3) spoke of a proliferation of the periosteum. Thomson and Krook (35) made a study of the vertebral osteophytes in breeding bulls and concluded the primary etiology was to be found in some stress to the periosteum.

Other authors recognized the stress effect upon the collateral ligaments. Bueche (7) described the ligamentous insertions on the pastern joint as showing a peculiar structure, namely a zone of osteoid cells fusing bone and ligament. According to Bueche, the number of these osteoid cells increases considerably under pathological conditions, and these cells penetrate into the ligaments themselves. Upon continued stress they adopt the character of bone cells and cause ossification of the collateral ligaments. Udriski (38) was the first to describe the pathological anatomy of ringbone (1900). He found that in nearly all cases the periosteum was thickened, the consistency was firm and the color darker. He claimed that all the lesions began, in each and every case, within the bone tissue itself. In the case of periarticular ringbone, the subperiosteal bone tissue is the seat of the initial pathological alterations. In articular arthritis, the Haversian canals widen to become the so-called Howship's lacunae. If osteitis progresses in the direction of the periosteum, a periarticular ossification process will follow (centrifugal or eccentric ringbone). Goldberg (16) agreed with other researchers that periarticular coronary ringbone begins by proliferation of the osteoid cells at the point of insertion of ligaments. According to him, bone rarefaction occurred after marked inflammatory changes took place in these ligaments.

As a rule, old cases of ringbone are a combination of the articular with the periarticular form (Bayer and Froehner, 3).

Radiological Review

Until the discovery of x-rays in 1895 (Bleich, 5), the diagnosis of periarticular and articular arthritis was based upon clinical findings alone. Hammer (18) gave a historical review of diagnosis and therapy of ringbone.

By the time a diagnosis based upon the appearance of lameness can be made, the pathologic-histological process has already found chronic manifestation. Ullrich (39) proved this by examining 40 horses destined for slaughter. None of them showed any degree of lameness. Out of the 40 horses examined, 35 had pathological alterations which could be demonstrated radiologically and clinically.

One year after the discovery of x-rays, Eberlein and Pfeifer (11) published a paper concerning the usefulness of roentgen rays in veterinary medicine. Theirs was the first radiographic demonstration of ringbone in the living animal. Since wooden cassettes did not work satisfactorily, the film was fastened around the pastern with the aid of a rubber band. Instead of a Hittorf tube, they used the improved Rubenkorff type of tube. One year later (1898) Eberlein (10) used cassettes with intensifying screens and a "cryptoskop", the use of which allowed him to cut the exposure time for ringbone from 65 minutes to 25 seconds. Troester (37) in 1896 radiographed a three-month-old equine fetus with a Hittorf tube. Reinemann (27) described arthritis and periarthritis, which he found with the help of x-rays. Since those pioneer days of veterinary radiology, many works have been published. Wittmann (41) wrote that veterinary medicine gained an invaluable diagnostic aid following the discovery of x-rays. He listed arthritis deformans as a pathological alteration that could be diagnosed radiographically.

Ullrich (39) established the value of radiological examination of the equine phalanges, in arriving at a diagnosis and emphasized its importance in giving an accurate prognosis of ringbone. Fehlow (13) studied the distal part of the front legs of older riding horses. He stated that many radiographs revealed structural changes on the bony skeleton where clinical signs were absent. Even though no lameness was apparent, he considered these radiological findings important as being proof of predisposing factors of ailments appearing later in life.

Wittmann (42) pointed out the important sites of lamenesses of the foreleg of the horse. He emphasized joint and bone diseases. He found that the roentgenogram was invaluable in the diagnosis of lamenesses resulting from bone and joint disturbances.

Berge (4) suggested the use of all diagnostic means in order to avoid wrong diagnoses and subsequent improper treatments. He used nerve blocks and diagnostic intra-articular injections in combination with radiography. Zschokke (43) put more emphasis on clinical diagnosis, including nerve blocks and intra-articular injections. According to his statement, x-rays were not too commonly used. Since then x-ray apparatus has been greatly improved and has become standard equipment in veterinary clinics and the larger veterinary practices. In the College of Veterinary Medicine, Iowa State University, nearly all of the lamenesses caused by ringbone may be confirmed by radiography, according to Lundvall (22).

Recently, more and more investigators are using the systematic approach based upon the concept of veterinary radiological anatomy. Pommer (26) studied the normal scapulo-humoral joint of the horse and dog, and Alksnis (2) wrote about the radiographic anatomy of normal joints in horses, dogs and cats.

Schebitz and Engelhardt (29) described the equine carpus from the standpoint of radiological anatomy. These authors presented a very lucid description of the carpal joint and stated that the radiological anatomy must be the foundation on which the diagnosis of pathological alterations by radiography must be based.

Kuepfer (20) used x-rays to study the embryonal development of equidae and to determine the age at which the centers of ossification appeared. Feti and embryos from 160 mares and 300 female donkeys of more uniform origin were sent from the Union of South Africa to Switzerland for radiological study. His work contains an atlas of all his findings, along with a statistical survey. More research has been done on the embryologic-morphological development since then. Smith (33) dealt with the radiological observations in young greyhounds. Schmidt (31) demonstrated radiologically the epiphyses and apophyses of the extremities of the colt and Schlotthauer (30) attempted to determine the time of closure of the lower femoral and the upper tibial epiphyses in the dog. Tohara (36) studied the ossification of leg bones in the horse.

The above-mentioned radiological studies of epiphyseal closure in the equine species were made on different horses of different ages. The review of literature failed to show that any researcher followed one horse through its postnatal development prior to Myers' (23) investigation. Myers provided, in his thesis, a complete and uniform series of radiographs of two related horses. In his work a chronological closure of the epiphyses is given and he used a systematic approach in establishing the urgently needed roentgen anatomy. Schaller (28) underlined the postulate expressed by most researchers in veterinary radiology. He emphasized the importance of the knowledge of anatomy for the x-ray diagnosis and claimed that the anatomist in turn could and should profit from the radiograph.

MATERIALS AND METHODS

Experimental Animals

Six purebred Shetland ponies with known ancestry (Tables 1-3, Figures 1-2) were used in this study of experimental ringbone production. Four animals, namely two male and two female ponies, were purchased from Dr. Kelly, Goldfield, Iowa, comprising group 1; and two female ponies were purchased from S. W. Sheia, Story City, Iowa, to comprise group 2.

Group 1

The first group was transported by truck to Ames, Iowa, on November 23, 1964. For the first three days any handling of the animals was kept at a minimum in order to allow for a smoother adaptation to the new environment. After this short period of rest, a complete physical examination was given and the results were recorded. The animals were housed and fed under the same conditions provided for the hospitalized equine patients at Iowa State University Veterinary Clinic and based upon the suggestions of the USDA (24). Body temperature, pulse frequency and respiration rate were measured daily, beginning December 1964, and record was kept in graphic illustrations. No abnormal values were noted. An anthelmintic (Equizole)[1] was administered twice

---

[1] Merck Chemical Division, Merck and Company, Inc., Rahway, New Jersey.

Table 1. Pedigree of research animals - group 1

1.	Filly Ann Foaled 4-28-63	Mr. Moto Reg. No. 51340 Born: 6-12-56
		Beauty Not registered but purebred Born: 6-12-56
2.	Filly Betty Foaled 5-14-63	Mr. Moto Reg. No. 51340 Born: 6-12-56
		Tabbie Not registered but purebred Born: 7-10-57
3.	Colt Cecil Foaled 10-23-63	Mr. Moto Reg. No. 51340 Born: 6-12-56
		Royal Pearl Reg. No. 26978 Born: 5-10-49
4.	Colt Dan Foaled 9-5-63	Mr. Moto Reg. No. 51340 Born: 6-12-56
		Princess Silver Lexie Reg. No. 52342 Born: 5-27-57

Table 2. Pedigree of research animals - group 2

Filly Hillswicke's Midge Foaled 5-2-63	Hillswicke's Silver Flash	Hillswicke's Oracle	Silver Crescent II
			Bonnie Bride
		Larigo's Snow Fleet	Romeo's White Cloud
			Snow Fleet
	Midge	Jolly Crescent	Silver Crescent II
			Bonnie Bride
		Malta	Silver Neveda
			Sierra Vista
Filly Hillswicke's Rose Foaled 4-4-63	Hillswicke's Silver Flash	Hillswicke's Silver Flash	Silver Crescent II
			Bonnie Bride
		Larigo Snow Fleet	Romeo's White Cloud
			Snow Fleet
	Sylvan-Lane Lady Pattie	Ponyland's Gallent Lad	Duke of Evergreen
			Checkers BB
		Brook's Mystic Dark Lady	Francine Larigo Topper
			Lady LeTresor

Table 3. Survey of Sheia's pony herd* in regard to the individual ages

Name	Sex	Age	Date of birth
Silver Daisy Mae	F	24	6.20.1940
Crescent Blondy	F	22	5.3.1942
Jolly Blondie	F	21	6.5.1943
Milady Queen	F	18	8.26.1946
Francine Larigo's Topper	M	14	6.4.1950
Miladys Supreme Doll	F	12	4.21.1952
Brooks Mystic Dark Lady	F	9	5.26.1955
Sylvan-Lane Lady Topper	F	6	3.17.1958
Hillswicke's Silver Flash	F	6	5.10.1958
Nightcaps Nightingale	F	6	7.11.1958
Sheia's Dark Temple Brooks	F	5	4.17.1959
Sheia's Midnight Showboat "N"	F	5	5.29.1959
Brooks Larigo Queenie "S"	F	4	6.7.1960
Chancellors Francine	F	4	8.13.1960
Peters Miss Fresno Two	F	3½	4.20.1961
Sylvans Jolly Blondie	F	3½	5.3.1961
Maxie's Black Lady	F	3½	5.11.1961
Beauty's Black Molly	F	3½	5.15.1961
Silver Sophia Mae	F	3½	7.6.1961
Hillswicks Blue Nightengale	F	2½	4.1.1962
Hillswicks Royal Jewell	M	2½	5.16.1962
Hillswick Tanforan	M	2½	5.18.1962
Hillswicks Brigette	F	2½	7.11.1962
Hillswicks Francine Larigo	F	1½	3.10.1963
Hillswick's Midge	F	1½	5.2.1963
Hillswick's Marcello	F	1½	5.9.1963
Hillswick's Daisy Mae	F	1½	5.17.1963

*The names listed above are spelled exactly as they appeared on the owners registration certificates. In the text, the incorrectly spelled names have been corrected.

A. Ann

B. Betty

C. Cecil

D. Dan

E. Midge

F. Rose

G. Ponies exercising on the "Equine Exerciser"

Figure 1. Experimental animals

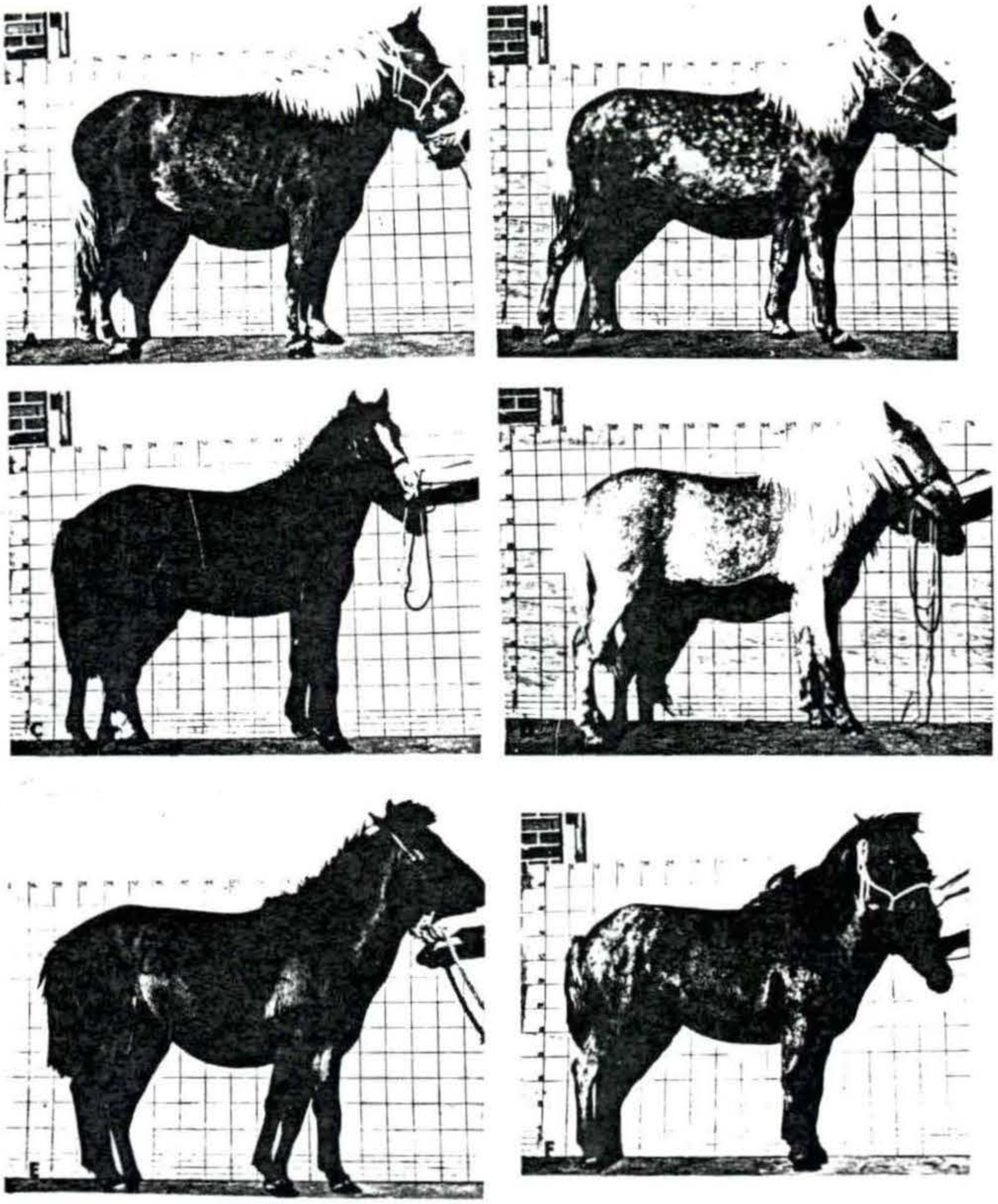
A
C
E
F



A. Mr. Moto; male

B. Beauty; female
Dam of Ann

C. Tabby; female
Dam of Betty

D. Royal Pearl; female
Dam of Cecil

E. Princess Silver
Lexie; female
Dam of Dan

Figure 2. Sire and dams of research ponies - group 1

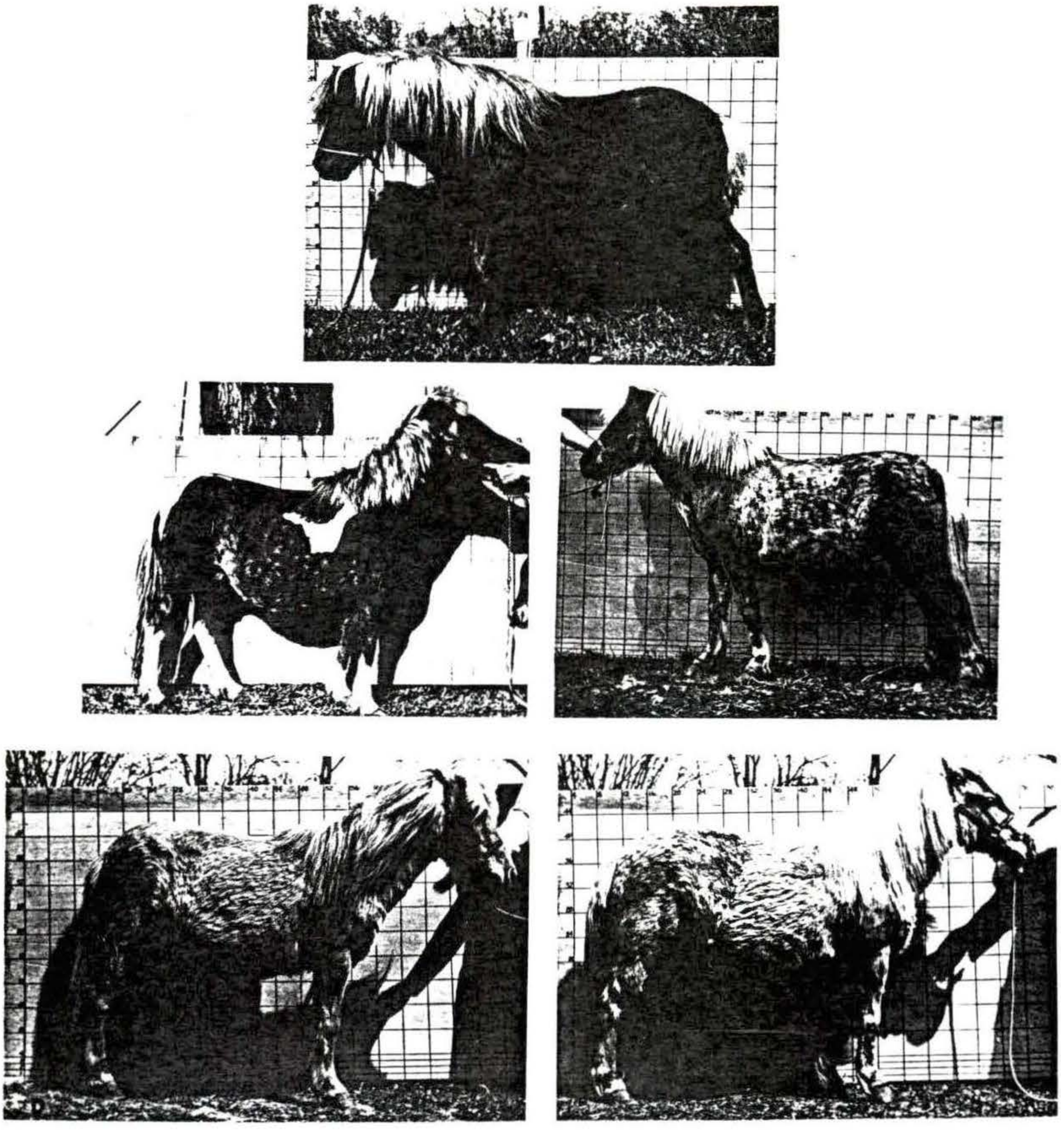
D

during the period of the experiments in order to minimize internal parasitism.

In order to eliminate the possibility of any hereditary skeletal weaknesses in the lower leg region, it was deemed necessary to radiograph the front feet of both dam and sire. Photographs of the research animals and their immediate ancestors were also taken (Figures 1 and 2).

Twenty-six days after the arrival, all four animals were radiographed for a radiological study of the existing skeletal anatomy of the front foot regions. Latero-medial and antero-posterior radiographs were taken and together with the radiographs of the second series (2R1 - 2R4) they constituted the medium of comparison for the following experiments.

On January 3, 1965, the construction of an "Equine Exerciser" (Figure 1g) was finished. The diameter of this custom built exercising wheel was 24 feet. The following day the ponies were exercised for one hour, with a change of direction after approximately 30 minutes. This procedure was used from then on through the entire length of the experiment, namely until May 18, 1965. Within this hour of actual work, the animals were forced to walk, trot or run. The time for the individual modes of locomotion was determined with the help of a stop watch. A detailed record was kept. Weather and ground conditions had a direct influence upon the mode and speed of the exercise because, on some occasions, the mud cover upon the exercise track did not allow for a fast speed but only for walking.

After two weeks of preliminary exercises, a farrier was hired to give the ponies a nearly perfect hoof trim and to shoe the front feet. While one of the front hooves was shod with a normal pony shoe, the opposite foot received a shoe on which one branch was elevated to 1 cm by welding a metal bar to it. Ponies number 1 and 3 were furnished with elevated shoes on the left front hoof. Ponies number 2 and 4 were shod with elevated shoes on the right front hoof. During the first phase of the daily exercises the lateral branches of the horse shoes of ponies number 1 and 3 and the medial branches of the horse shoes of ponies number 2 and 4 were elevated. This was done in order to imitate the every-day occurrence of poor hoof trim with consequent compulsory stress upon the collateral ligament of the now elevated side. After 63 days, the farrier exchanged the shoes in a manner that the opposite branch was elevated. The normally shod control hoof was trimmed to a rather good hoof axis and shod again with a normal pony shoe. Again the hind feet were just trimmed, but not shod.

During the exercises it was observed that the elevated hoofs of several ponies slid over the front border of the shoe, which was due to the forward slope and to the fact that only two to four No. 4 horse shoe nails fastened the shoe to the hoof. Corrections were made to replace the dislocated shoes to their normal position.

Beginning March 10, pony number 1 was equipped with a specially constructed surcingle, and the animal was required to carry 25 pounds of lead weight during exercise. The lead rectangles, which weighed circa one pound each, were evenly distributed on both sides and packed into four leather pockets. Ponies 3 and 4 shared another surcingle, so that they only carried the extra weight on alternate days.

At regular intervals, radiographs were made of both the elevated and the normally shod front feet. The radiographs were evaluated regularly and the interpretations recorded. At the conclusion of the experiments, the corresponding radiographs from each series were read in sequence and the gradual changes compared to the pre-experimental radiograph (1R1 - 1R4). This method allowed the study of structural changes of the bony skeleton over a period of six months.

On May 18, the final series of radiographs were taken. The animals were euthanized the following day and routine necropsies were performed by the Department of Veterinary Pathology, Iowa State University.

Group 2

The two female ponies constituting group 2 arrived at Iowa State University on March 16, 1965. After several days of rest, a complete physical examination was made, including hematological and parasitological studies. At this point, the first set of radiographs was made in order to establish the pre-experimental radiographic anatomy.

Housing, feeding and care was similar to those of the first group. The following day both animals were exercised with group 1 in order to acclimatize them to the "Exerciser." Both readily accepted their tasks, and they were shod three days after arrival. Before the animals were purchased, all ponies owned by Sheia were radiographed on the farm for radiologic study.

Both animals received an elevated shoe on the right hoof while the left one was shod with a normal pony shoe. In these animals the medial branch of the horse shoe was raised during the entire length of the experiment. Trimming of walls, heels and soles was executed before shoeing in order to establish a sound hoof axis. Both ponies were exercised together with group 1. On April 3, 1965, an intra-articular injection of autogenous blood into the right front proximal interphalangeal joint of pony number 6 was attempted. The blood had been collected from the vena jugularis. In order to trace the deposited blood, it was thoroughly mixed with

1 cc of an emulsion of bismuth subnitrate and saline solution. In order to keep tissue-irritating granules out of the joint capsule and guarantee free passage through an 18-gauge hypodermic needle, the bismuth subnitrate emulsion was filtered through sterilized gauze and autoclaved prior to adding the blood.

The right front foot was clipped, washed and the injection site disinfected. An 18-gauge, 1 1/2 inch hypodermic needle was inserted through the skin into the joint and a radiograph (Figure 17) was taken. Some synovial fluid was withdrawn before the mixture of autogenous blood and contrast medium was injected. Immediate lameness was exhibited by the animal, but after several minutes of exercise, it "warmed out" of the lameness.

Pony 5 was prepared as pony 6 and 1 cc of bismuth subnitrate emulsion was injected into the region of the collateral ligament insertions of the right front pastern. An attempt was made to deposit the bismuth subnitrate emulsion as close to the periosteum as possible and not to penetrate the joint capsule. After the injections, radiographs were taken.

Radiographic Technique

For the description of different radiographic views the nomenclature recommended by Emmerson (12) and Habel _et_ al. (17) was used. Antero-posterior (A.P.) and latero-medial (L.M.) radiographs were taken of both front feet in intervals of approximately 2 weeks. While for group 1 eleven series were accumulated, only seven series were made for group 2. During radiography, the feet were resting on a 2-inch thick block and the cassette (10" x 12") was set on the floor and kept as close as possible to the extremity by an assistant. In taking latero-medial radiographs, the cassettes were held perpendicular to the floor. In the antero-posterior view, it was attempted to keep the cassettes parallel to the axis of the pastern or at an angle of 42° - 55° with the floor, depending on the individual animal. The marker was placed laterally in A.P.-views and anteriorly in L.M.-views. The experimental animals number, sequence of radiographs, side of the animal, and date were put on the x-ray marker for positive identification. Opposite to the marker an aluminum densitometer was placed to determine the density of individual body parts in mm/AL. It was attempted to radiograph the lower leg region from the upper two-thirds of the metacarpus to the sole. In all the above cases, the ponies were standing with all four feet squarely under them. The radiographic techniques used during the experiments are the same as described by Carlson (8).

In a daily log book, all information concerning the animals and the experiments were recorded. Three days and ten days after the blood-bismuth subnitrate injections both animals were examined and a differential blood count was . made. Latero-medial and antero-posterior radiographs were taken. From there on the periodical radiographs were made simultaneously with the ones of group 1. The exercises were terminated on May 18, 1965.

A Picker Meteor X-Ray Machine[1] Style F10 was used to take the radiographs. The setting of the machine varied according to the thickness of the pastern in the individual ponies. With 10 ma and 74 KvP as constant factors, only film target distance (FTD) and exposure time were used as variables. At a distance of 36 inches, the exposure time was calculated as follows:

$$\frac{\text{thickness of pastern}}{\text{in inches minus one}} = \frac{\text{the tenth of seconds}}{\text{of exposure}}$$

Par speed cassettes and Kodak Medical X-Ray Film, Blue Brand[2] were usually used.

---

[1] Picker X-Ray Corporation, White Plaines, New York.

[2] Eastman Kodak Company, Rochester, New York.

OBSERVATIONS AND DISCUSSION

Survey of Existing Bone Pathology (Front Feet) Within the Herd of Origin

For the purpose of eliminating any hereditary weakness of the rather young research ponies, especially in regard to bone quality and new bone formation, the entire herd of origin of group 2 was made a part of this study. The radiological examination of the lower front feet revealed the following findings:

Pony No. 1

Hillswick's Silver Flash, female, born 5-10-1958

Radiological findings:
Proximal sesamoiditis and osteochondrosis of both pastern joints. There was a slight tendency toward laminitis. The animal was soft ankled. Improper hoof care caused this abnormal angulation. The hoof walls showed growth rings.

Pony No. 2

Sylvan's Jolly Blondy, female, born 5-3-1961

Radiological findings:
Slight osteochondrosis of left pastern joint. Abnormal digital angulation was causing abnormal hoof wear.

Pony No. 3

Sheia's Dark Temple Brooks, female, born 4-17-1959

Radiological findings:
Chronic laminitis, slight proximal sesamoiditis. Mild osteochondrosis of pastern joints, poor angulation.

Pony No. 4

Hillswick's Royal Jewell, female, born 5-16-1962

Radiological findings:
Mild osteochondrosis of both pastern joints. There was a periarticular lipping of the fetlock joints noticeable. The digital angulation was good.

Pony No. 5

Nightcaps Nightingale, female, born 7-11-1958

Radiological findings:
Mild chronic laminitis and proximal sesamoiditis. Osteochondrosis of both pastern joints. Annular rings could be observed on the left front foot. There was a mild abnormal angulation of the digits.

Pony No. 6

Hillswick's Daisy Mae, female, born 5-17-1963

Radiological findings:
Osteochondrosis of pastern joints. Left front foot showed abnormal angulation, right front foot had normal ankle. The right front showed the lateral splint bone to be turned outward at the distal end.

Pony No. 7

Hillswick's Midge, female, born 1954

Radiological findings:
Both tuberosities for the insertion of the collateral ligaments on the proximal end of the first phalanx were enlarged. There was a proximal sesamoiditis in the right front foot. Tendovaginitis and serous arthritis of fetlock. The first phalanx showed some lipping. Mild osteochondrosis of both pastern joints, possible light case of inactive ringbone in left front foot.

Pony No. 8

Maxies Black Lady, female, born 5-11-1967

Radiological findings:
Slight serous arthritis and proximal sesamoiditis. Osteochondrosis of both pastern joints.

Pony No. 9

Milady Queen, female, born 8-26-1946

Radiological findings:
Left front foot showed poor angulation due to improper hoof care. Osteochondrosis of both pastern joints. The pull of the collateral ligaments caused a distinct enlargement of the tuberosities of the first phalanx. The fetlock joint showed some indication of lipping. Ankylosing carpitis in both knees. Proximal sesamoiditis and tendinitis in both extremities.

Pony No. 10

Silver Daisy Mae, female, born 6-20-1940

Radiological findings:
Definite sidebones and periarticular ringbone. Mild proximal sesamoiditis. Osteochondrosis of both pastern joints. Beginning pyramidal disease.

Pony No. 11

Peter's Miss Fresno Two, female, born 4-20-1961

Radiological findings:
Some osteochondrosis of the right pastern with possibly a very early periarticular ringbone.

Pony No. 12

Hillswick's Midge III, female, born 5-2-1963

Radiological findings:
Osteochondrosis of pastern joints. Mild tendency toward tendinitis.

Pony No. 13

Hillswick's Tanforan, male, born 5-18-1961

Radiological findings:
Slight osteochondrosis of right pastern joint.

Pony No. 14

Brook's Dark Lady, female, born 5-26-1955

Radiological findings:
Proximal sesamoiditis, mild tendinitis. Osteochondrosis of pastern joints. Beginning sidebones.

Pony No. 15

Crescent Blondy, female, born 6-5-1943

Radiological findings:
Right front foot showed chronic laminitis. The splint bones tended to diverge or point posteriorly at their distal ends. Proximal sesamoiditis, tendinitis, serous arthritis with lipping and pulled tuberosities of first phalanx in fetlock region. Indication of inactive periarticular ringbone. Osteochondrosis of pastern joints.

Pony No. 16

Silver Sophia Mae, female, born 7-6-1967

Radiological findings:
Beginning proximal sesamoiditis, serous arthritis, mild tendovaginitis of fetlock region. Osteochondrosis of both pasterns as well as bilateral periarticular ringbone. Sidebones noticeable on both feet.

Pony No. 17

Francine Larigo's Topper, male, born 6-4-1950

Radiological findings:
Remarkably clean legs for 15-year-old animal. Slight tendency toward sesamoiditis and periarticular ringbone. Beginning pyramidal disease of left front foot. No osteochondrosis. Feet needed to be trimmed (stones were noticeable in the frog).

Pony No. 18

Sheia's Midnight Showboat "N", female, born 5-29-1959

Radiological findings:
Slight laminitis in both front feet. Osteochondrosis in both pastern joints. Indication of beginning periarticular ringbone. Proximal sesamoiditis. Beginning sidebones. Annular rings on hoof wall were distinctly visible.

Pony No. 19

My Ladies Supreme Doll, female, born 4-27-1952

Radiological findings:
Slight laminitis, indication of pyramidal disease. Osteochondrosis of both pastern joints, periarticular ringbone. The right navicular bone seemed to be compressed.

Pony No. 20

Beauty Black Molly, female, born 5-15-1961

Radiological findings:
Osteochondrosis of both pastern joints. Suggestion of an early periarticular ringbone.

Pony No. 21

Hillswick's Brigette, female, born 7-11-1962

Radiological findings:
Osteochondrosis of both pastern joints. Tendency toward lipping in both fetlocks.

Pony No. 22

Hillswick's Blue Nightingale, female, born 4-1-1962

Radiological findings:
Osteochondrosis of both pastern joints, otherwise clean.

Pony No. 23

Hillswick's Francine Larigo, female, born 3-10-1963

Radiological findings:
Osteochondrosis of both pastern joints, right leg showed slight degree of sesamoiditis.

In evaluating the radiological findings concerning the herd of origin (group 2), it becomes evident that some degree of pathology was present in nearly all extremities of the ponies examined. The most common lesions were osteochondroses of one or more joints of the foot. Twenty out of twenty-two animals showed these lesions. It was noticed that the pastern joint was the most commonly affected site. Furthermore, fourteen cases of proximal sesamoiditis and six cases of laminitis could be diagnosed. Pyramidal disease (3 times), periarticular lipping of the fetlock joint (3 times), and serous arthritis (3 times) showed up on the roentgenograms. In regard to new bone production, there was a surprising amount of activity to be observed. While only four cases of sidebones were found, nine animals showed some degree of periarticular arthritis. The spectrum of pathological alterations ranged from a slight enlargement of the tuberosities, serving as insertion sites for the collateral ligaments, to one case of distinct ringbone formation. The remaining cases showed merely a touch of new bone formation. Several animals showed a slight degree of osteolysis beneath the periosteum. The common site for these alterations was the distal end of the first phalanx. Only one animal, which was nineteen years of age, showed true ankylosing carpitis. This process was advanced to such a degree that clinical lameness could be observed.

In summarizing the findings, it must be stated that a high percentage of the animals did show evidence of new bone production. However, none of the ponies so affected were less than four years of age. This leads to the conclusion that the research animals were not prone to naturally occurring ringbone, because of their young age.

Interpretation of Radiological Findings

In order to achieve an objective evaluation of structural changes of the lower front legs which took place during the course of the experiment, the radiological anatomy of these regions at the time of purchase had to be established. This initial radiological study was meant to be the basis for the comparison of the subsequently induced alterations, which appeared in chronological order. For this purpose the first group of research animals was radiographed three times. Only one set of initial radiographs was taken of the ponies comprising group 2. The first three series of radiographs taken of group 1 are, therefore, nearly identical. The variations in exposure time and in positioning of the foot during the radiographic process account for the small deviations.

Pony No. 1 (Ann)

Pre-experimental radiographic anatomy (1 R 1) Both front legs showed a rather good bone quality. There was a slight osteodystrophy of the fetlock joints. In the left leg an additional slight indication of arthritis of the coffin joint, especially in the region of the extensor process, could be noticed. The abnormally straight pastern of the left extremity was suggestive of flexor tendon contraction. The density within the soft tissue area indicated also tendinitis.

Experimental radiographic anatomy (4Rl - 11Rl) During the experimental phase of this study numerous changes within the anatomy of the lower left leg took place. The change of hoof axis was reflected in both the pastern and the coffin joint. On the radiograph taken on February 20th, it was noticed that the medial wall of the hoof was sloping inward. At that time, the joint space on the elevated side was considerably narrower than on the other. The lateral hoof wall showed a distinct concavity, which became more pronounced on March 9th. At that time, a shifting of the shoe could be observed. There was some thickening of the medial epicondyle of the first phalanx indicating that stress was being placed upon the medial collateral ligament of the pastern joint. The radiograph taken on April 20th showed even more evidence of stress on the medial collateral ligament. There was some new bone production, but it was not pronounced. On the last two radiographs of this series, the medial wall seemed to have become less concave and appeared more linear. The lateral wall, which was elevated by the shoeing on March 16th, now showed signs of concavity. The degree of narrowing of the pastern and the coffin joints on the elevated side was not as pronounced after changing the shoe due to the greater ability of the pony to compensate for the change. The last radiograph taken on May 18, 1965, showed the new bone formation on the medial epicondyle of the first phalanx to be more pronounced than on any previous radiograph.

From early in the course of the experiment, a definite contraction of the heels of both front feet was observed.

Pony No. 2 (Betty)

Pre-experimental radiographic anatomy (1 R 2) This animal showed good bone quality, and the foot axis was fair when the experiment was initiated. Throughout the study the second phalanges on the AP radiographs appeared rather short, due to the fact that the lateral axis of the digit was exaggerated. There was a partial contraction of the deep flexor tendon, and a slight osteochondrosis of both the pastern and the coffin joints.

Experimental radiographic anatomy (4R2 - 11R2) As in the radiographs of pony number 1, the change in the foot axis caused by the elevated bar was evident. Beginning in April, a reparative enlargement of the lateral tuberosities became noticeable. Because of the mild nature of the abnormal pull on the collateral ligaments, only a very mild inflammatory reaction took place on the epicondyles. On the last radiograph exaggerated horn growth could be observed which was attributed to a mild inflammatory involvement of the coronary band.

Pony No. 3 (Cecil)

Pre-experimental radiographic anatomy Cecil showed good bone quality, and the foot axis was fair. There was evidence of a mild sesamoiditis, as well as osteochondrosis of the left pastern joint.

Experimental radiographic anatomy (4R3 - 11R3) On a radiograph dated February 20, the joint spaces of the pastern and coffin joints were wider on the medial aspect than on the lateral or elevated side. A tendovaginitis began to appear. Beginning on April 20th, a slight osteolysis on the epicondyles of the first phalanx could be observed. There was no evidence of new bone production.

Pony No. 4 (Dan)

Pre-experimental radiographic anatomy (1 R 4) This animal showed an abnormally straight pastern which gave the extremities a "mule-footed" appearance. The walls were quite straight. Here, too, the joint space on the elevated side was remarkably narrowed. The heels showed some contraction, and a slight degree of tendinitis could be observed.

Experimental radiographic anatomy (3R4 - 11R4) During the course of the experiment, a proximal sesamoiditis was developing. Beginning on March 23rd, both the medial and the lateral hoof walls became contracted. Toward the end of the experiment, a definite enlargement of the epicondyles of the first phalanx became apparent. Some degree of osteolysis, especially under the periostium of the medial epicondyle of the first phalanx could be noticed.

Pony No. 5 (Midge) (1 D 1)

Pre-experimental radiographic anatomy The conformation of the extremities seemed to be fairly good. The AP radiograph revealed a slight osteochondrosis of the fetlock joint. In the LM view no pathological changes could be found. The angulation was poor, but improved after shoeing.

Experimental radiographic anatomy (2D1 - 7D1) The deposits of injected autogenous blood mixed with bismuth subnitrate was evident on all radiographs taken after April 3rd. The volume of the media in the soft tissue structures appeared somewhat diminished on April 20th, but then persisted in about the same amount throughout the remainder of the experiment. The injection did not seem to cause a periostitis. Aside from the evidence of contracted heels no pathological alterations were diagnosed.

Pony No. 6 (Rose)

Pre-experimental radiographic anatomy (1 D 2) The hoof and foot anatomy appeared to be quite normal.

Experimental radiographic anatomy On all these radiographs the deposit of blood and radiopaque material could be followed up to May 18th. The amount of the deposit was progressively diminishing with time. Even though injected intra-articularly, there were no signs of arthritis or osteochondrosis noticeable. This pony showed a tremendous ability to compensate for the elevated shoe.

The radiological examination of the opposite, normally shoed extremity revealed that the joint spaces of the coffin and pastern joints reflected a change from the normal position (Table 4). This was evidence that the pony not only compensated for the elevated branch in the involved foot, but that the opposite leg helped to adjust to the existing condition. By shifting the body weight, the stress was transferred to the opposite extremity. The compensated stress was, however, not as pronounced on the opposite leg as it was upon the extremity which was elevated by the faulty shoeing.

Table 4. Average width of joint space (pastern joint)(in millimeters)

		Elevated foot		Normal shoed foot	
		Lateral	Medial	Lateral	Medial
Ann	1)	1.58*	3.82	1.75	2.00
	2)	2.08	1.58*	2.00	2.00
Betty	1)	1.25*	1.92	1.17	2.50
	2)	2.44	1.00*	1.25	1.87
Cecil	1)	1.00*	2.76	2.00	1.66
	2)	2.77	1.47*	1.62	2.06
Dan	1)	1.66*	2.42	1.50	2.58
	2)	2.87	1.37*	1.30	2.46
Midge		1.00*	2.00	1.80	2.00
Rose		1.42	1.08*	1.00	1.35

*Hoof side elevated at the time of measurement.

SUMMARY AND CONCLUSIONS

This study was concerned with the duplication of natural, every-day occurring stresses upon the extremities of the horse. The purpose of this study was to determine the effects of stress on the production of a specific type of arthritis, popularly called "ringbone," under controlled and closely observed conditions. Alterations appearing as a consequence of improper hoof trimming and faulty shoeing in combination with excessive exercises and weight bearing were studied by means of regular, systematic radiological examinations.

1. The experimental animals constituted a selected group of purebred Shetland ponies with known genetic background. In order to insure an unbiased course of the investigation the ponies were housed and fed under optimal conditions.

2. The horse shoeing was performed by a professional farrier and specially constructed shoes were used. A custom-built equine exerciser served as a suitable apparatus for controlled "exercising" of the ponies.

3. The weights of lead which were carried in specially made surcingles were meant to duplicate the actual weight of a rider. It was calculated that 25 pounds of metal was adequate to represent 10 to 12 percent of the animals bodyweight and that this additional load would imitate as closely as

possible an existing stress affecting a horse while being ridden.

4. The intra-articular and periarticular injections of autogenous blood were meant to duplicate hemorrhages, which occur under certain management conditions, e.g. after a fall, stumble or even a severe joint sprain. It was visualized that severe sprains and contusions could cause rupture of capillaries within the vicinity of the periostium and ligamentous insertions as well as in the joint capsule. Autogenous blood could easily provoke a local hyperemia with subsequent cellular infiltration and periosteal proliferation. Subsequent osteoblast and osteoclast activity could result in exuberant bone growth commonly referred to as "exostoses" or "osteophytes." The injection of foreign material was supposed to have the same effect upon the joint surfaces as contaminating substances entering the articular space through penetrating wounds.

5. During the course of the experimental work a total of 238 radiographs were made and studied. This total includes all the radiographs taken of the research animals at periodic intervals as well as the radiographs taken of all the animals in one of the herds of origin in order to determine the occurrence of various skeletally induced lamenesses under natural field conditions.

6. It was found that during the relatively short period

of time in which stress was induced in this study no ringbone could be produced. However, three out of the six experimental animals showed evidence of bone pathology which indicated a tendency or susceptibility toward ringbone which probably would have become clinically evident at a later time. The observed lesions ranged from mere enlargement of the epicondyles of the first phalanx to new bone production in one case.

7. It was theorized that superficial periarticular hemorrhage, which can occur on the race track, does not cause enough irritation to stimulate the development of pronounced periosteal new bone formation and frank ringbone.

8. There was considerable evidence that the primary lesions preceeding periarticular ringbone are not to be found in the joint cartilage as described by Joest (19) but in the epicondyles and tuberosities to which the collateral ligaments are attached (Bueche, 7).

9. The difficulties, experienced in producing periarticular arthritis in the research Shetland ponies tends to substantiate the postulate of Ullrich (39) that heavier breeds are more predisposed to this pathological condition than the lighter breeds.

10. The reason for the inability to produce frank ringbone may be explained by the short time period of induced stress and by the apparent ability of the Shetland

pony to compensate for abnormal hoof growth or faulty shoeing. The entire investigation leads to the hypothesis that the Shetland pony, down through the ages, has developed a resistance toward collateral ligament injury and the subsequent bone reaction that leads to ringbone formation.

LITERATURE CITED

1. Adams, O. R. Lameness in horses. Lea and Febiger, Philadelphia, Pa. 1962.

2. Alksnis, A. Roentgen-anatomische Studien ueber normale Gelenke beim Pferd, Hund und bei der Katze, Latvijas Universitates Raksti Vet. med. 2, Riga. 1938.

3. Bayer, J. and Froehner, E. Handbuch der tieraerztlichen Chirurgie und Geburtshilfe. 2nd ed. Vol. 1. W. Braumueller, Wien and Leipzig. 1906.

4. Berge, E. Betrachtungen zur Lahmheitsdiagnose. Monatshefte fuer Veterinaermedizin 5: 309. 1950.

5. Bleich, A. R. The story of x-rays, from Roentgen to isotopes. Dover Publications, Inc., New York, N.Y. 1960.

6. Bone, J. F., Catcott, E. J., Gabel, A. A., Johnson, L. E. and Riley, W. F. Equine medicine and surgery. 1st ed. Am. Vet. Publ., Wheaton, Ill. 1963.

7. Bueche, K. Ueber die Histologie and Pathologie der periartikulaeren Krongelenkschale beim Pferd. Inaug. Diss. Hannover. 1913.

8. Carlson, W. D. Veterinary radiology. 2nd ed. Lea and Febiger, Philadelphia, Pa. 1967.

9. Dollar, J. A. W. Regional veterinary surgery and operative technique. The J. F. Hartz Co., Toronto, Canada. 1912.

10. Eberlein, R. Weiteres ueber die Verwertbarkeit der Roentgenstrahlen beim Pferd. Monatshefte fuer praktische Tierheilkunde 9: 433-447. 1898.

11. Eberlein, R. and Pfeifer, W. Untersuchungen ueber die Verwertbarkeit der Roentgenschen Strahlen in der Tierheilkunde. Monatshefte fuer Tierheilkunde 8: 385-420. 1897.

12. Emmerson, M. A. Radiographic nomenclature. Private communication. Dept. of Clinical Sciences, Iowa State University, Ames, Iowa. 1965.

13. Fehlow, K. Roentgenologische Untersuchungen an den distalen Abschnitten der Vorderextremitaeten aelterer Reitpferde. Inaug. Diss. Berlin West. 1956.

14. Frank, E. R. Veterinary surgery. 7th ed. Burgess Publishing Co., Minneapolis, Minn. 1964.

15. Gibson, W. A new treatise on the diseases of horses. Printed for A. Millar, London, England. 1751.

16. Goldberg, S. A. The structural changes that occur in certain non-specific inflammations of joints. The Cornell Veterinarian 6: 57-73. 1916.

17. Habel, R. E., Barett, R. B., Diesem, C. D., Roenigk, W. J. Nomenclature for radiologic anatomy. Journ. of the American Veterinary Medical Association 142, No. 1: 38-41. 1963

18. Hammer, F. Geschichte des Wesens und der Therapie der Schale. Inaug. Diss. Leipzig. 1913.

19. Joest, E. Spezielle pathologische Anatomie der Haussaeugetiere. R. Schoetz, Berlin, Germany. 1919.

20. Kuepfer, M. Beitraege zum Modus der Ossifikationsvorgaenge in der Anlage des Extremitaetenskelettes bei den Equiden-Der Verknoecherungsprozess in der Pferde- und Eselgliedmasse auf Grund roentgenologischer Untersuchungen. Denkschrift der Schweizerischen Naturforschenden Gesellschaft, Mémoires de la Société Helvétique des Sciences Naturelles 67, No. 67: 1-352. Gebrueder Fretz A. G., Zuerich, Switzerland. 1931.

21. Lacroix, J. V. Lameness of the horse. American Journ. of Vet. Med., Chicago, Ill. 1916.

22. Lundvall, R. L. Epiphysitis of the phalanges. Private communication. Department of Vet. Clinical Sciences, Iowa State University, Ames, Iowa. 1965.

23. Myers, V. S. The age and manner of closure of various epiphyses and centers of ossification in the front limb of the domestic horse (Equus caballus). Dept. of Vet. Clinical Sciences, Iowa State University, Ames, Iowa. 1963.

24. National Academy of Sciences, National Research Counsel. Nutrient Requirements of Domestic Animals, No. 6, Nutrient Requirement of Horses. Revised Edition, Publication 912, Author, Washington D.C. 1961.

25. Nieberle, K. and Cohrs P. Lehrbuch der speziellen pathologischen Anatomie der Haustiere 3. Ed. Gustav Fischer, Jena. 1949.

26. Pommer, A. Das Schultergelenk des Pferdes und Hundes im Roentgenbild. Wiener Tieraerztliche Monatsschrift 15: 768-775. 1928.

27. Reinemann, Oberrossarzt. Roentgenstrahlen zur Feststellung des Sitzes von Lahmheiten beim Pferd. Zeitschrift fuer Veterinaerkunde 12: 174. 1900.

28. Schaller, O. Die Bedeutung der Roentgenanatomie in der Veterinaermedizin. Wiener Tieraerztliche Monatsschrift 50: 145. 1963.

29. Schebitz, H. und Engelhardt, F. Zur Roentgenuntersuchung des Karpalgelenkes vom Pferd. Tieraerzliche Umschau 18: 416-418. 1963.

30. Schlotthauer, C. F. and Jones, P. M. The time of closure of the lower femoral epiphyses and upper tibial epiphyses in the dog as determined by roentgenogram. American Journal of Veterinary Research 13: 90. 1952.

31. Schmidt, G. Epiphysen und Apophysen in der roentgenologischen Darstellung in den Vorder- und Hinterextremitaeten der Fohlen. Inaug. Diss. Hannover. 1960.

32. Silbersiepe, E. and Berge, E. Lehrbuch der speziellen Chirurgie. fuer Tieraerzte und Studierende. 13th ed. Verlag Ferdinand Enke, Stuttgart, Germany. 1958.

33. Smith, R. N. Radiological observations on the limbs of young greyhounds. The Journal of Small Animal Practice 1, No. 2: 84-90. 1960.

34. Smith, H. A. and Jones, T. C. Veterinary Pathology. 2nd ed. Lea and Febiger, Philadelphia, Pa. 1961.

35. Thomson, R. G. and Krook, L. A study of vertebral body osteophytes in bulls. Report of the New York State Veterinary College, Legislative Document No. 88: 44-45. 1966.

36. Tohara, S. Radiographical studies on the ossification of leg-bones of horses. Japanese Journal of Veterinary Science 12, No. 1: 1-12. 1950. Original available but not translated; English summary used.

37. Troester, C. Photographie mit X-Strahlen. Zeitschrift fuer Vet. Kunde 8: 274. 1896.

38. Udriski, C. Die pathologische Anatomie der Krongelenkschale des Pferdes. Monatsheft fuer praktische Thierheilkunde 11: 337. 1900.

39. Ullrich, H. Roentgenologische Untersuchungen an den Zehenknochen der Vordergliedmaben von Schlachtpferden im Hinblick auf die Prognose der periartikulaeren Schale und der Hufknorpelverknoecherung. Inaug. Diss. Hannover. 1934.

40. Vickers, R. J. A plea for sanity in thoroughbred racing. Whittet and Shepperson, Richmond, Va. 1962.

41. Wittmann, F. Chirurgische Diagnostik des Pferdes. Verlag Ferdinand Enke, Stuttgart, Germany. 1931.

42. Wittmann, F. Die wichtigsten Lahmheitspunkte an der Vordergliedmasse des Pferdes infolge von Knochen- und Gelenkserkrankungen. Zeitschrift fuer Vet. Kunde 50, No. 6: 241-274. 1938.

43. Zschokke, F. Zur Diagnostik der Lahmheiten am Fuss des Pferdes. Zeitschrift fuer Vet. Kunde 48: 475-481. 1936.

ACKNOWLEDGMENTS

The author wishes to thank all the members of the Veterinary Medical Staff of Iowa State University who helped in many ways with this project.

Special gratitude and appreciation are extended to Dr. M. A. Emmerson, whose counsel, advice, and guidance were invaluable throughout the entire course of this study and to Dr. W. M. Wass for his excellent cooperation and helpful assistance. Their encouragement, especially in the last phase of the project, contributed much toward its completion.

Dr. B. H. Skold and Dr. J. H. Greve are thanked for their assistance in preparing the final thesis form.

The author is indebted to Dr. J. P. Wylie, a graduate of Iowa State University who assisted with the experimental study during his undergraduate senior year.

The fine photography performed by Dr. D. J. Hillmann was greatly appreciated.

Last, but not least, the author would like to thank his former practice partners, Dr. P. W. Kopf and Dr. R. F. Marshall, Wapello Veterinary Clinic, Wapello, Iowa, for their understanding and encouragement while absent from the practice.

This investigation was supported by funds from the Patricia Wiman-Hewitt Equine Research Fund and from the Veterinary Medical Research Institute, Iowa State University.

APPENDIX

Figure 3. <u>Ann</u> (1 R 1) Radiograph of left front foot taken prior to beginning of experiment

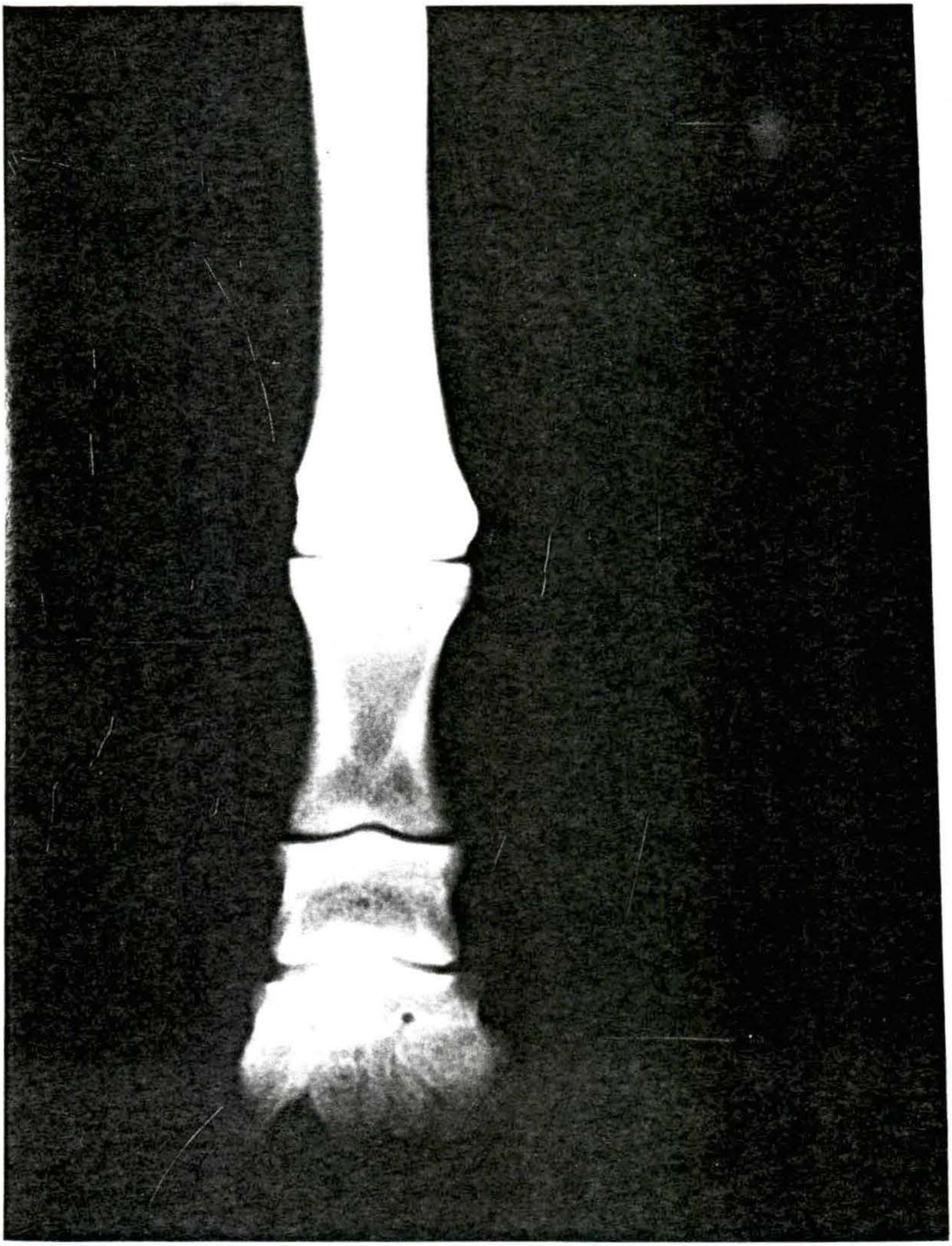

Figure 4. <u>Ann</u> (6 R 1) Radiograph of left front foot taken on 56th day of experiment. Pronounced concavity of the lateral hoof wall. Thickening of the medial epicondyle of first phalanx.

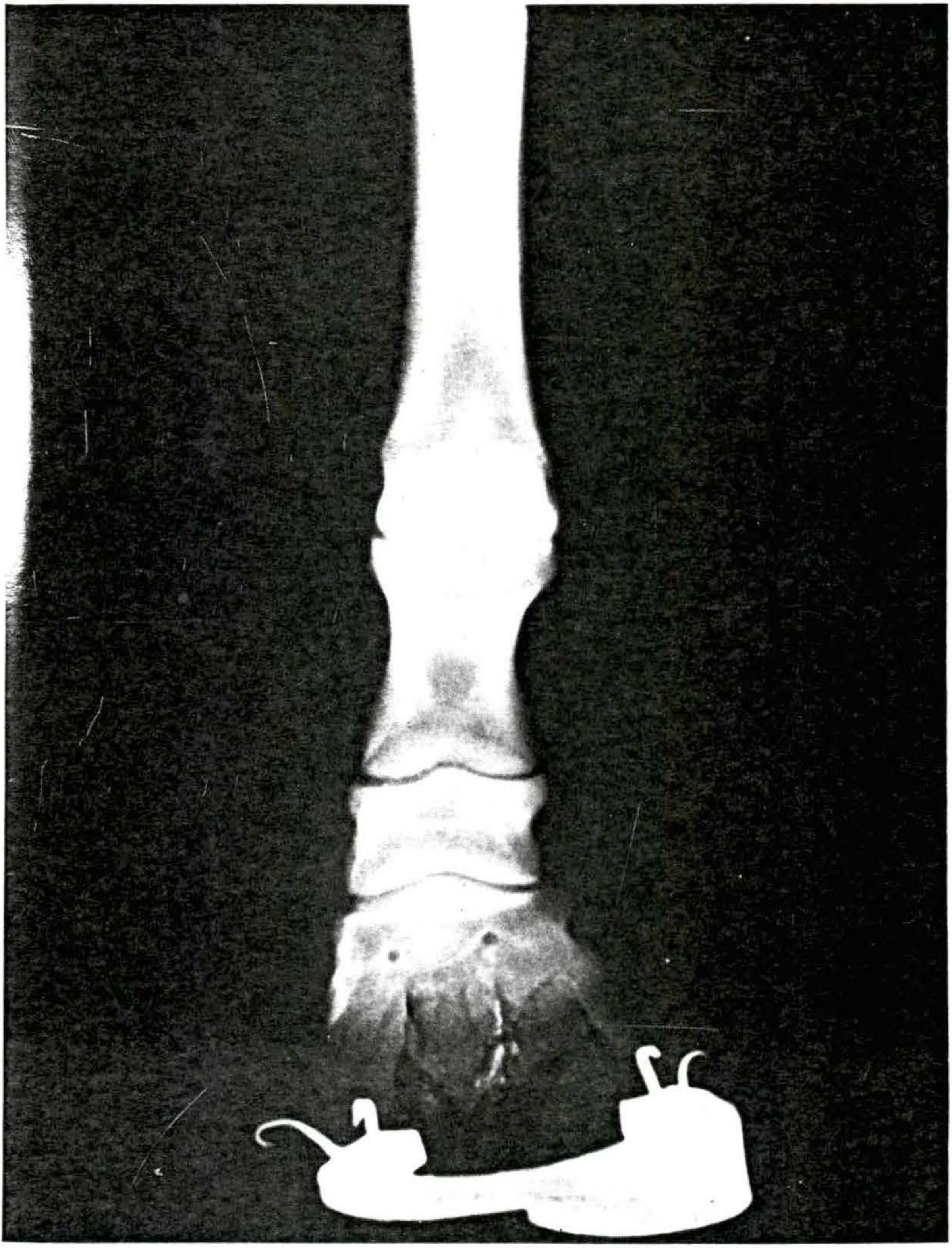

Figure 5. *Ann* (11 R 1) Radiograph of left front foot taken on 126th day of experiment. Beginning new bone formation on the tuberosities of the epicondyles of first phalanx.

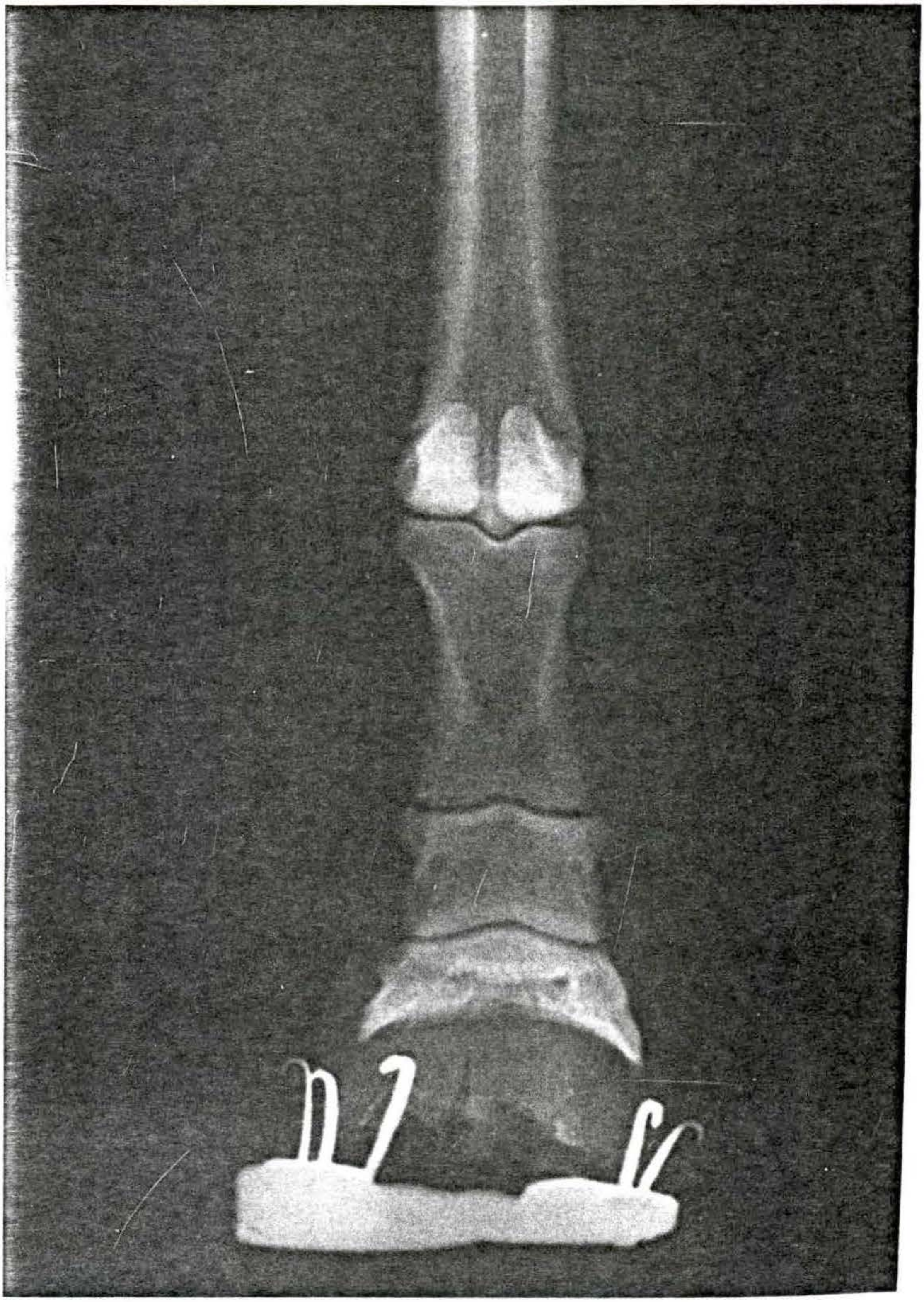

Figure 6. Betty (1 R 2) Radiograph of right front foot prior to beginning of experiment. Second phalanx appears short due to abnormal lateral foot axis.

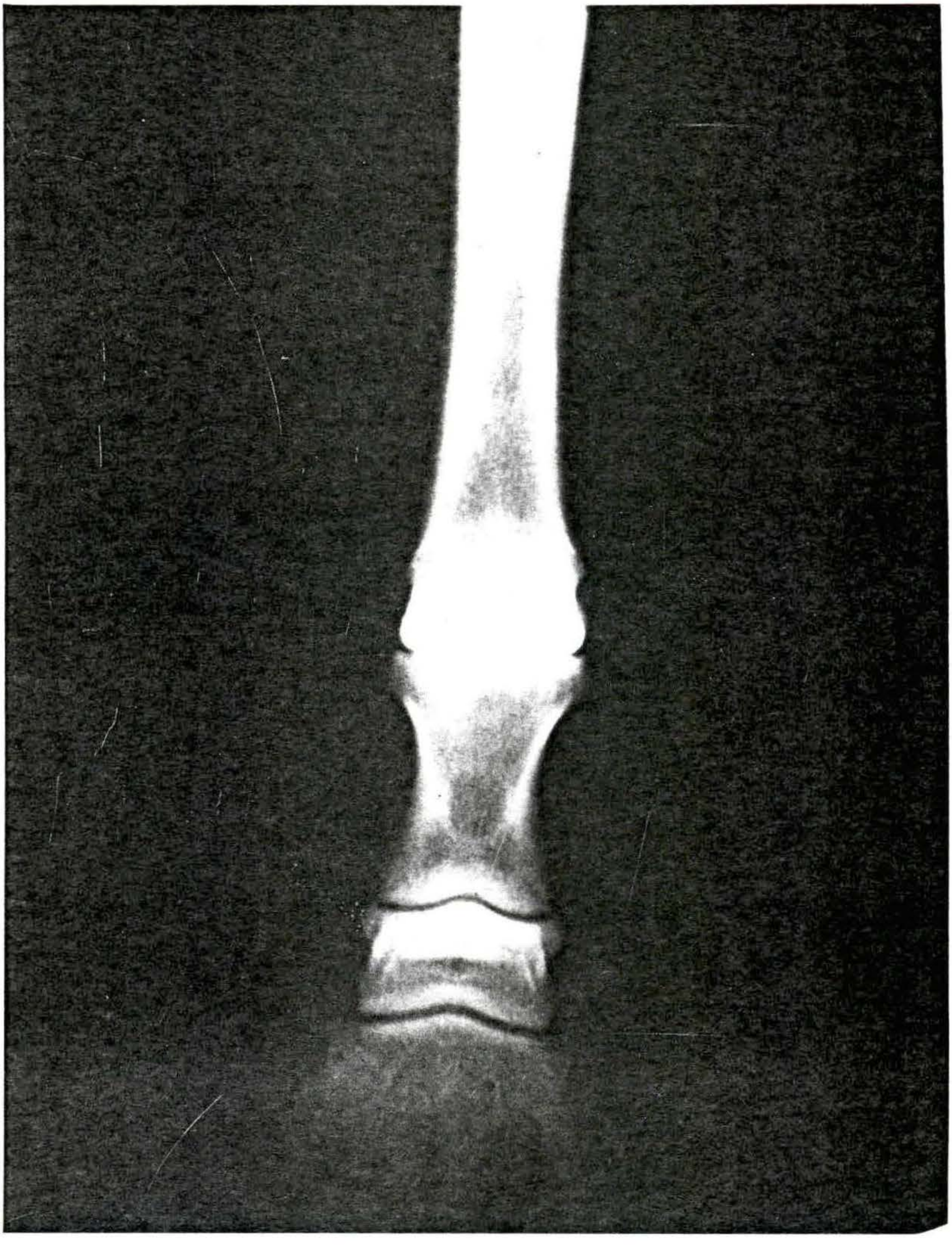

Figure 7. <u>Betty</u> (1 R 2) Radiograph of right front foot, latero-medial view, taken prior to beginning of experiment. This radiograph reveals abnormal alignment of the phalanges (broken foot axis).

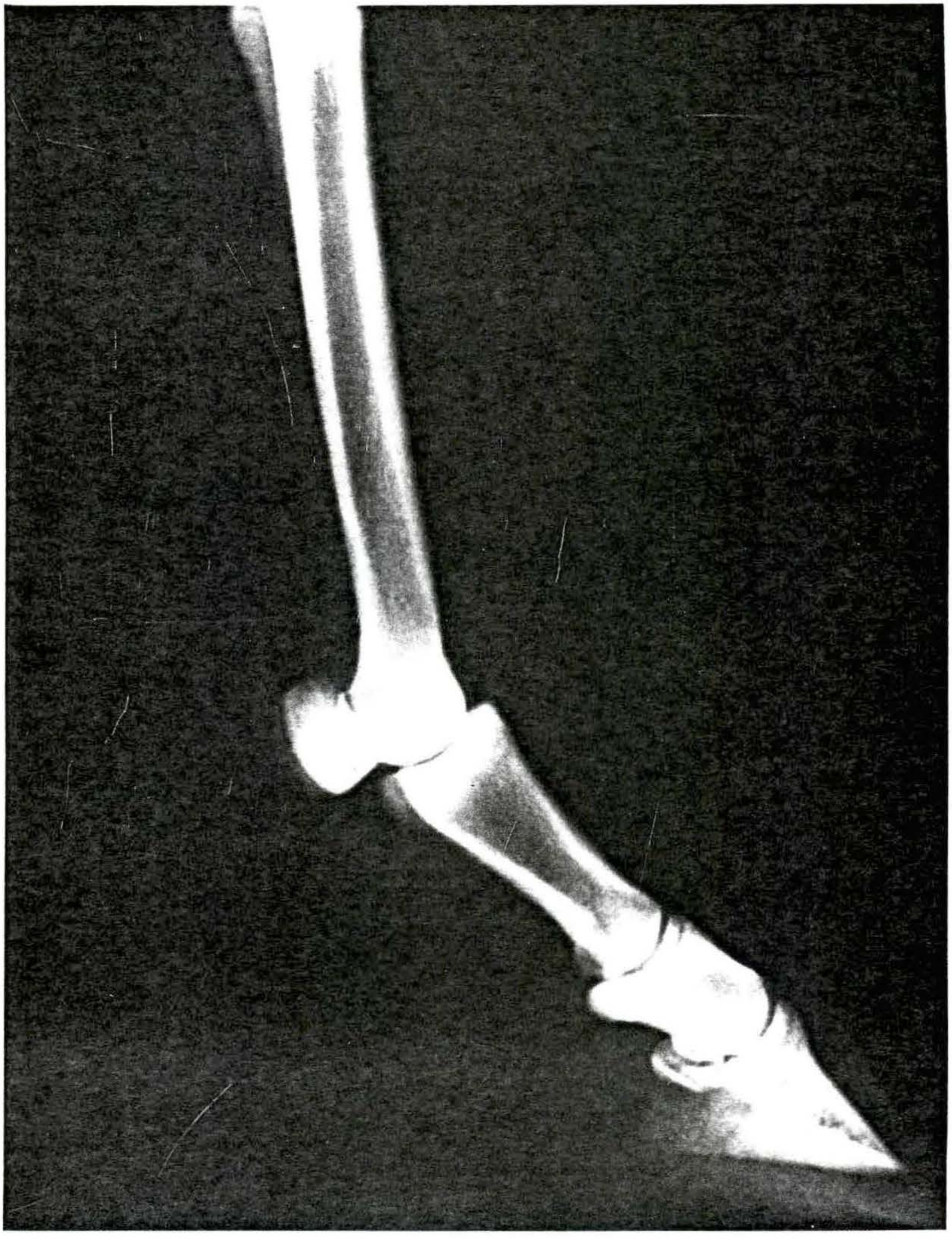

Figure 8. <u>Betty</u> (6 R 2) Radiograph of right front foot taken on the 56th day of experiment. No pathological alterations are evident.

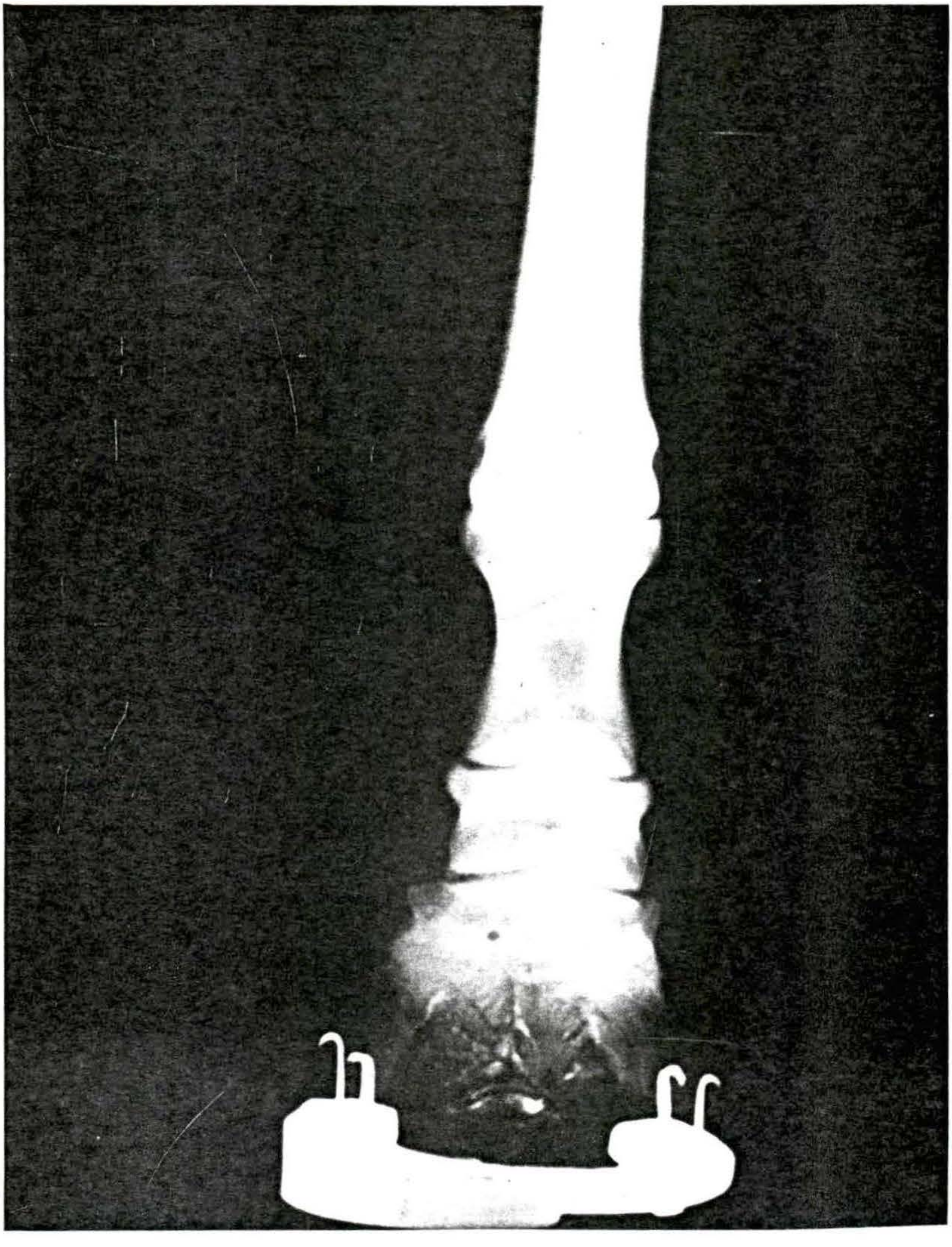

Figure 9. *Betty* (11 R 2) Radiograph of right front leg taken on 126th day of experiment. No new bone formation. Exaggerated horn growth and shifting of shoe are shown.

Figure 10. Cecil (1 R 3) Radiograph of left front foot taken prior to beginning of experiment

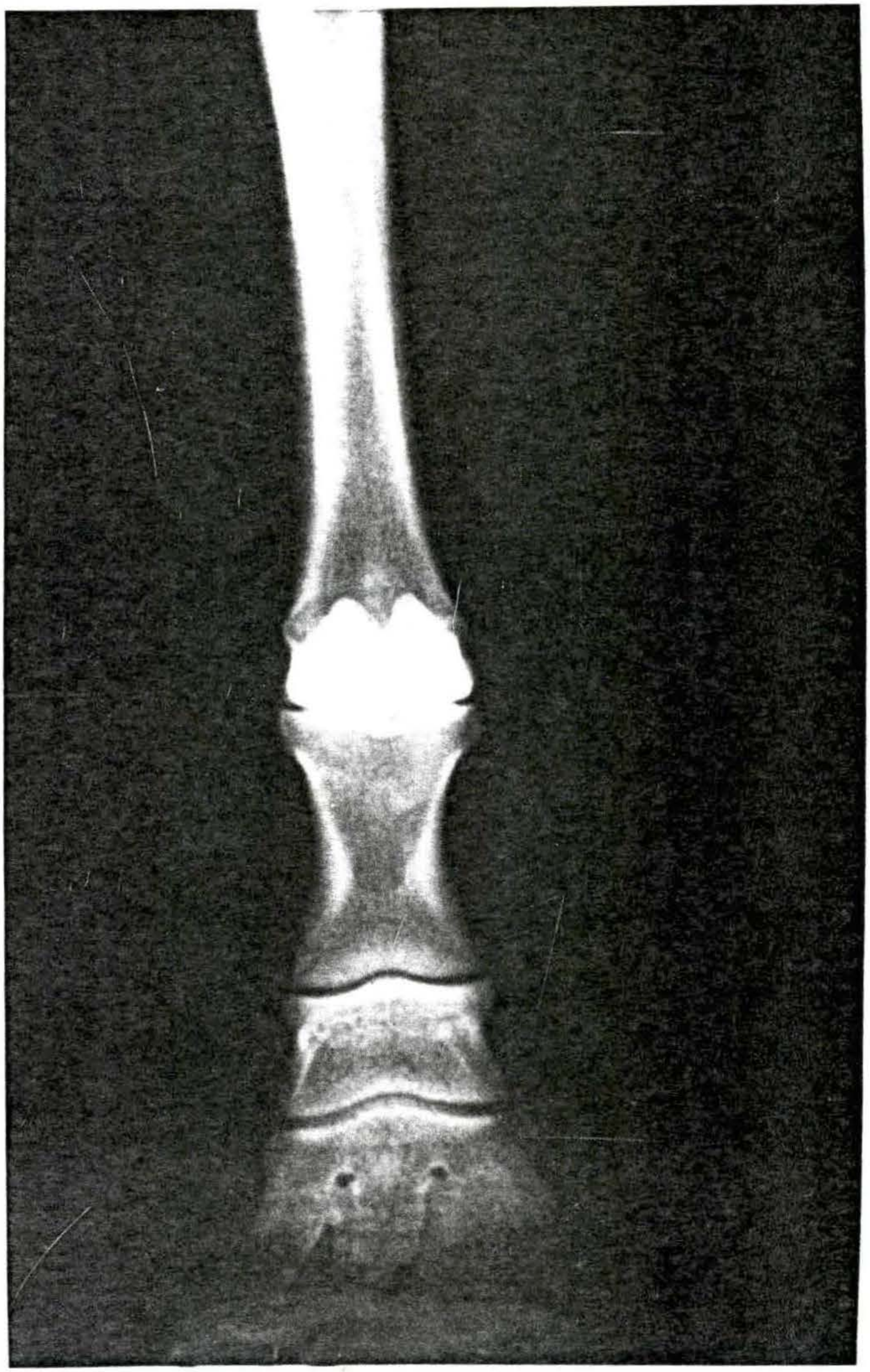

Figure 11. Cecil (6 R 3) Radiograph of left front foot taken on 56th day of experiment. Distinct difference in lateral and medial width of joint spaces.

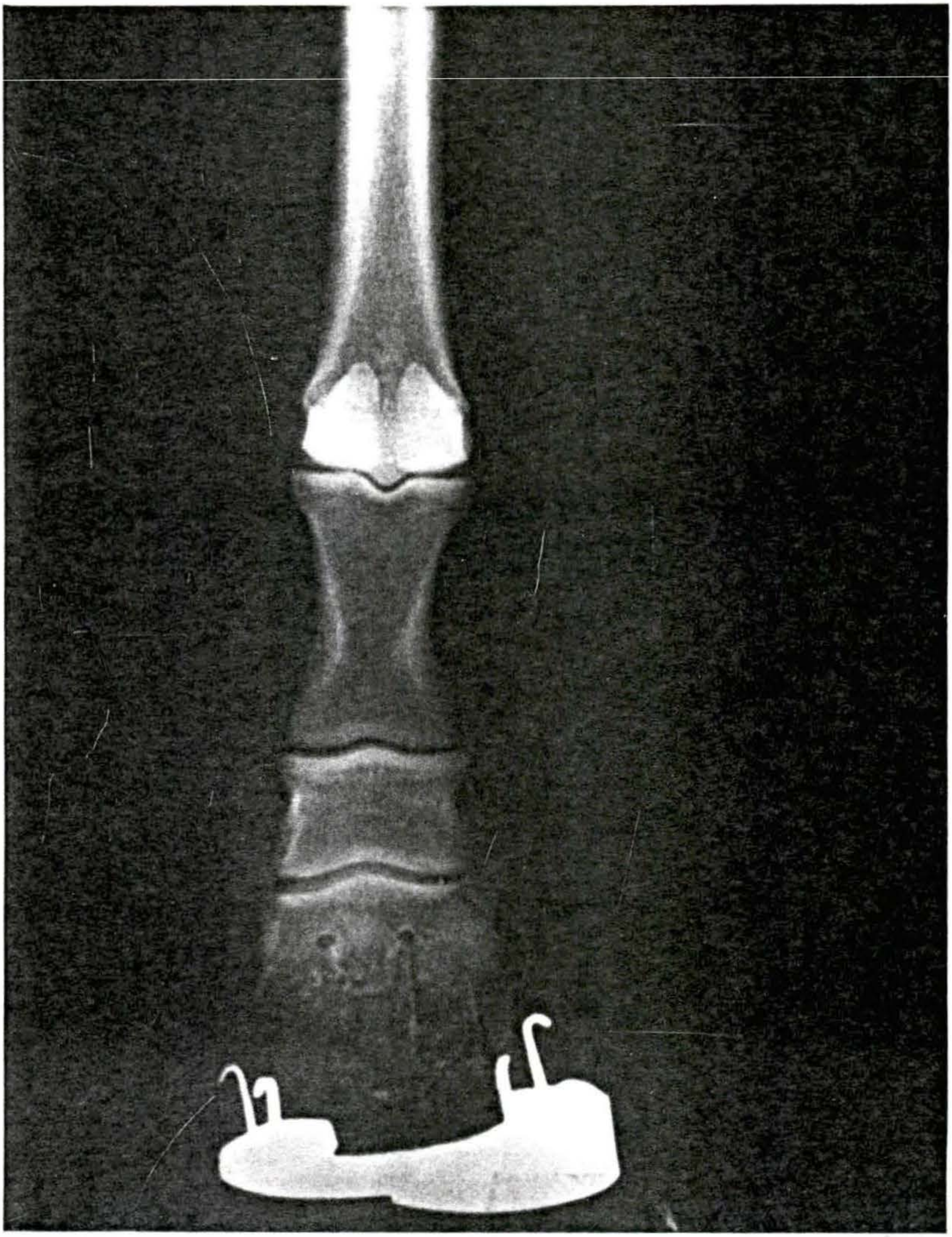

Figure 12. Cecil (11 R 3) Radiograph of left front foot taken on 126th day of experiment. Slight osteolysis in distal end of first phalanx.

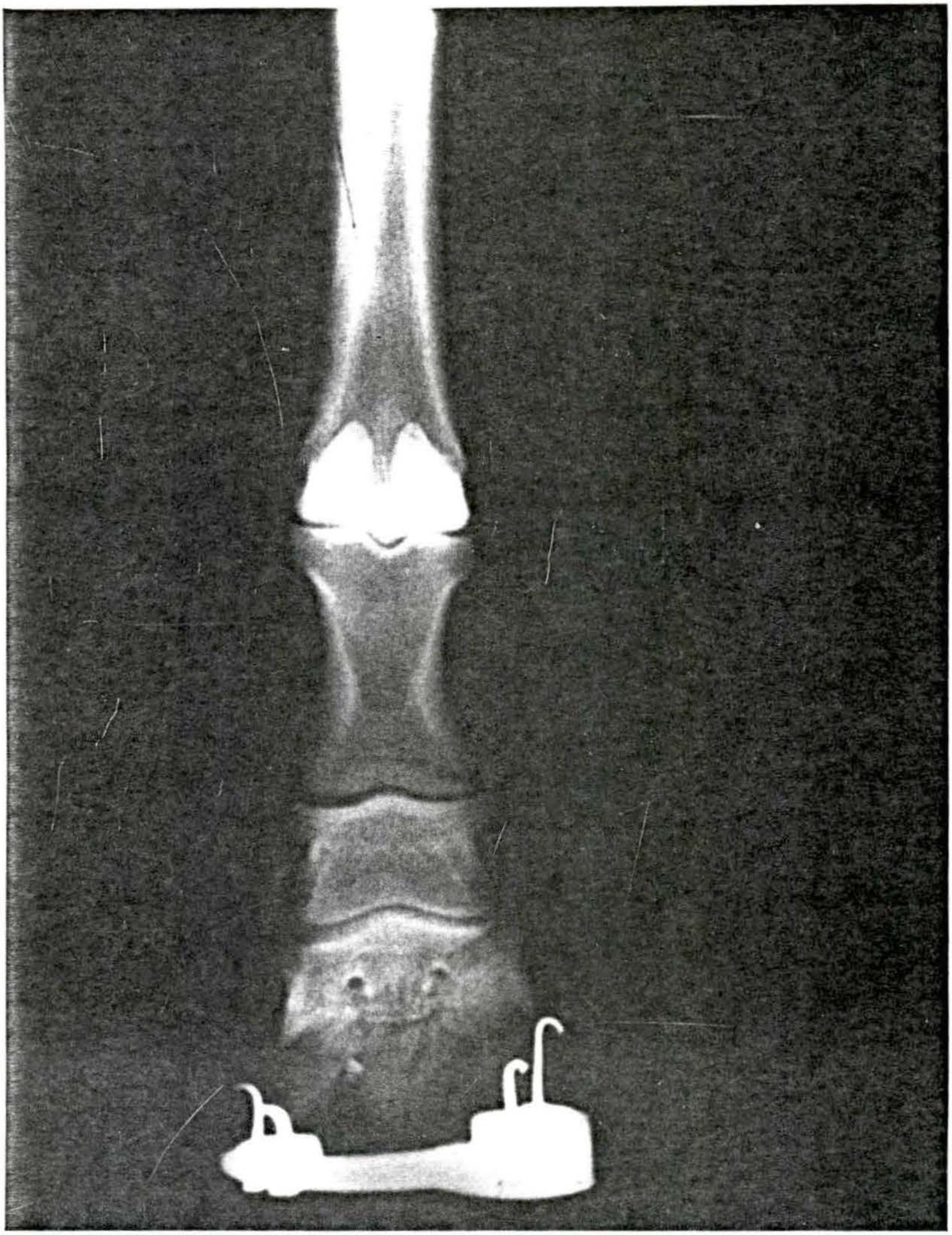

Figure 13. Dan (1 R 4) Radiograph of right front foot taken prior to beginning of experiment. Abnormally straight pastern (mulefoot).

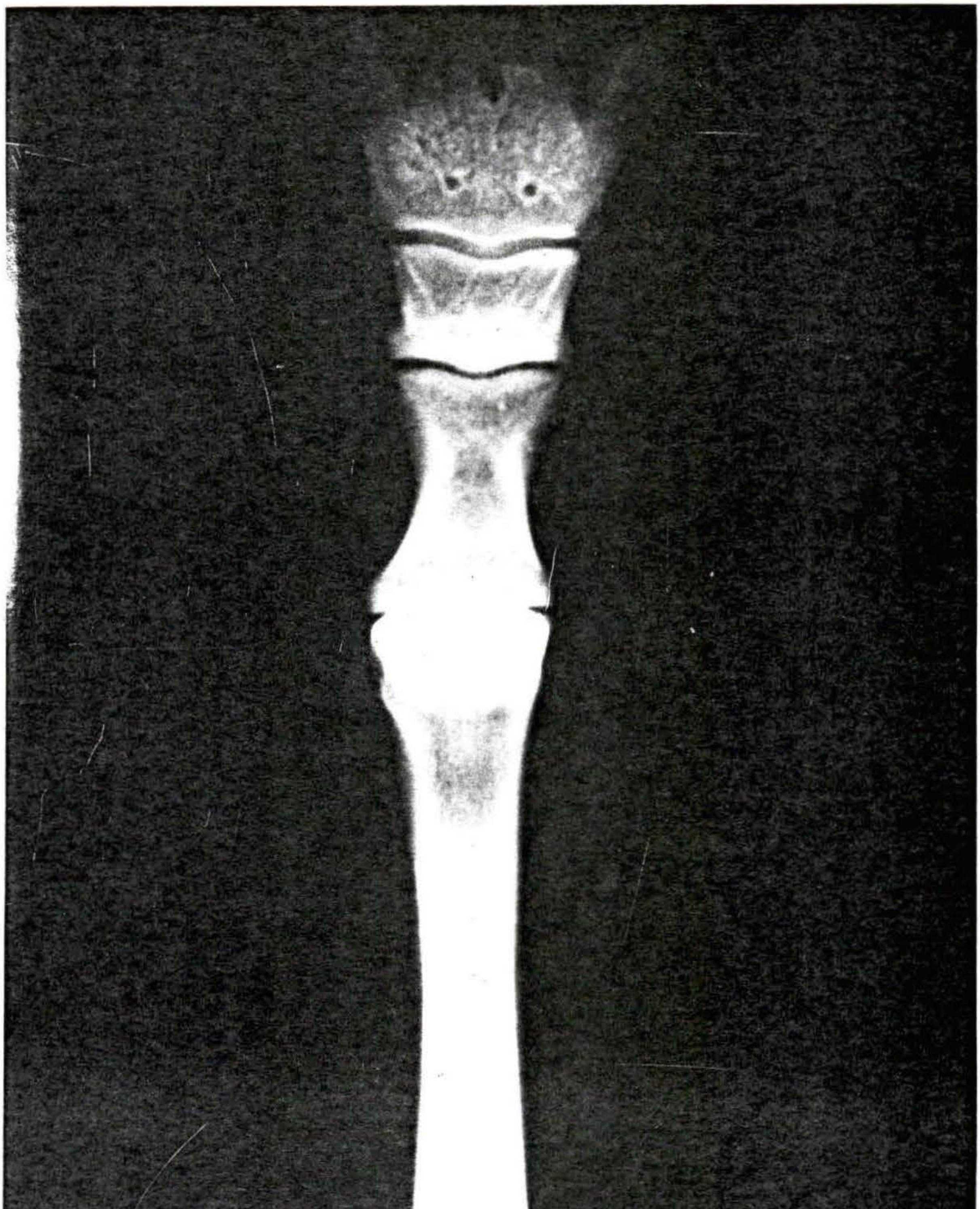

Figure 14. Dan (6 R 4) Radiograph of right front foot taken on 56th day of experiment. Both lateral and medial hoof wall became concaved.

Figure 15. Dan (11 R 4) Radiograph of right front leg taken on 126th day of experiment. Definite enlargement of the tuberosities of the distal proximity of the first phalanx. Beneath the periosteum of the medial epicondyle of the first phalanx slight degree of osteolysis.

Figure 16. *Rose* (1 D 2) Radiograph of right front foot taken prior to beginning of experiment

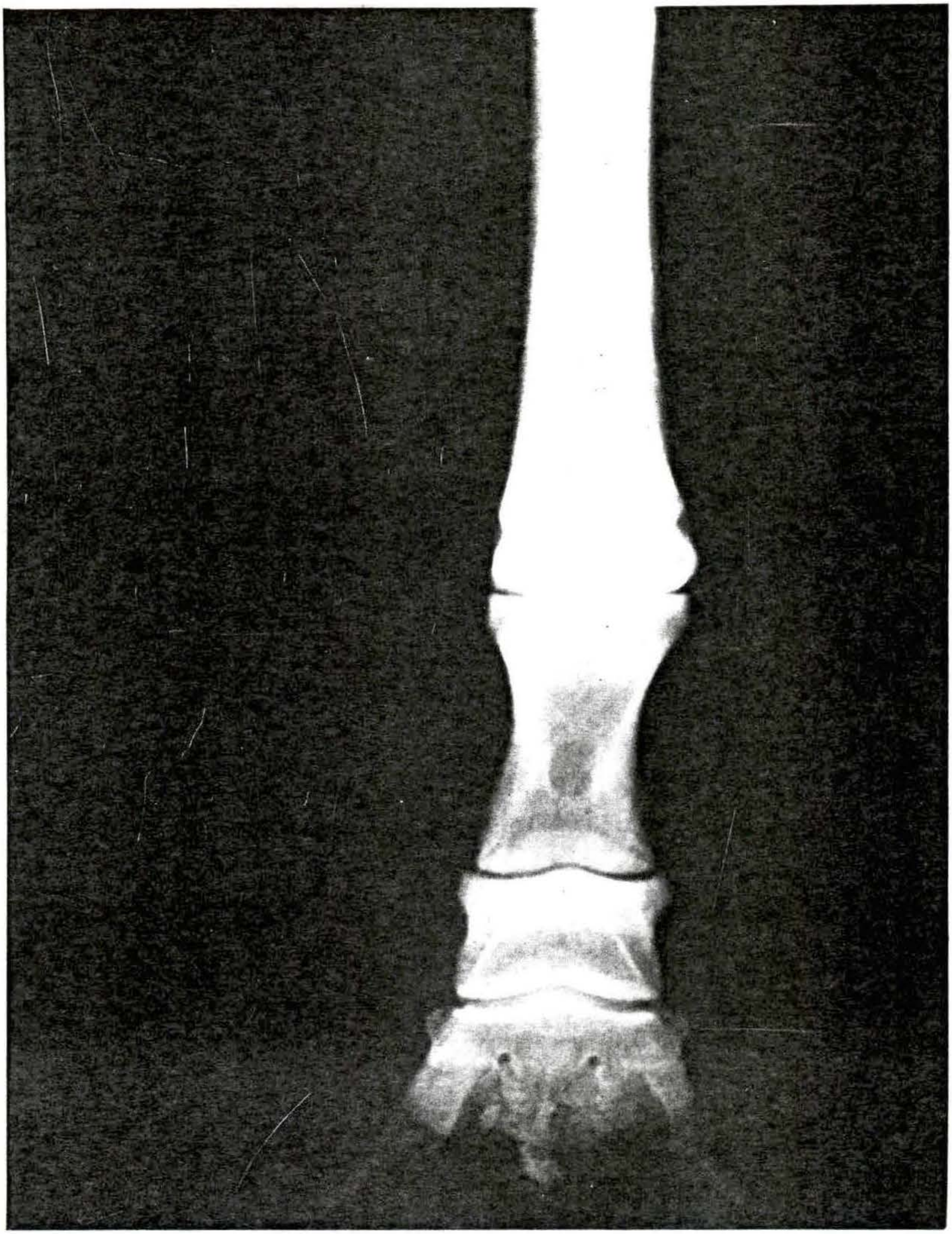

Figure 17. Rose (3 D 2) Radiograph of right front foot taken during intra-articular injection of mixture of autogenous blood and radiopaque material (Bismuth subnitrate).

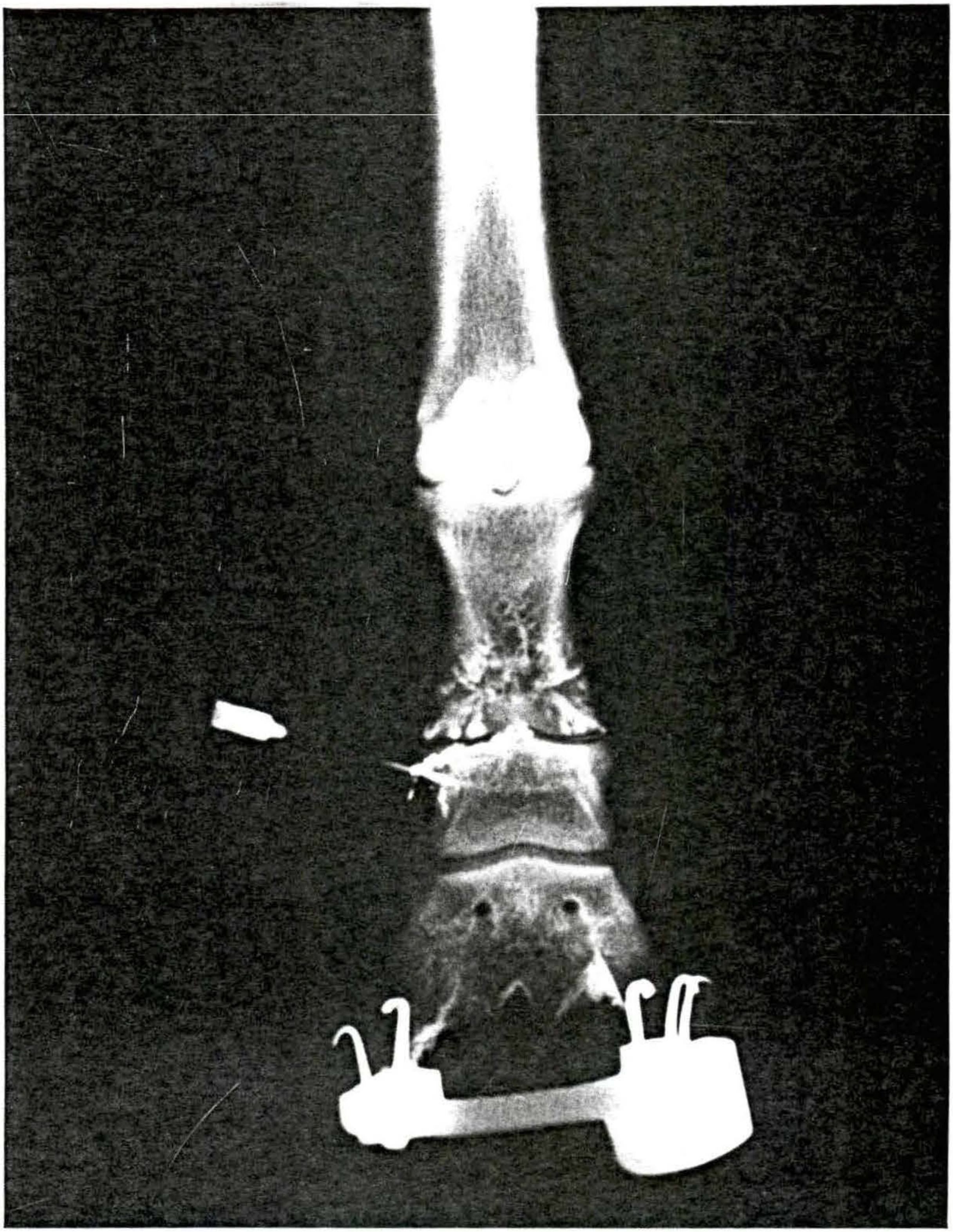

Figure 18. Rose (3 D 2) Latero-medial radiograph of right front foot after intra-articular injection of autogenous blood mixed with bismuth subnitrate. Note even distribution in joint space.

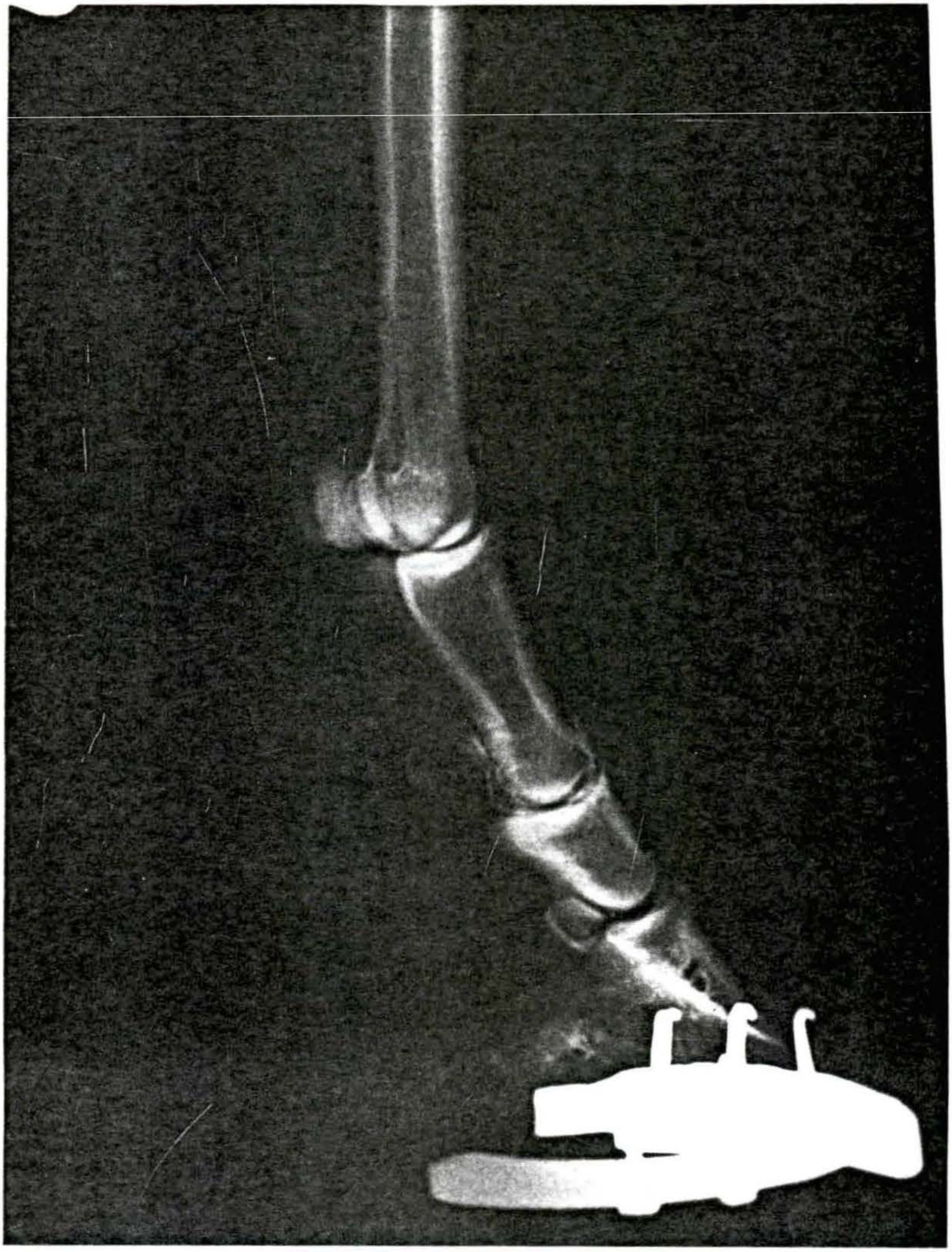

Figure 19. <u>Rose</u> (7 D 2) Final radiograph of right front foot taken on 46th day after joint injection. Diminished amount of injected mixture of blood and bismuth subnitrate still visible. No sign of arthritis or new bone formation. Note ability of pony to conpensate for elevated bar.