The cranial cruciate ligament in the bovine: Its tensile strength and surgical repair using a patellar ligament graft

by

Edwin William Moss

A Thesis Submitted to the
Graduate Faculty in Partial Fulfillment of the
Requirements for the Degree of
MASTER OF SCIENCE

Department: Veterinary Clinical Sciences
Major: Veterinary Clinical Science
(Veterinary Surgery)

Iowa State University
Ames, Iowa

1980

TABLE OF CONTENTS

GENERAL INTRODUCTION

The search for an adequate replacement procedure and material for ruptured cranial cruciate ligament has attracted the attention of medical and veterinary surgeons for most of this century. The first surgical treatment in man, using a replacement graft, was reported by Hey Groves (1917, 1920). In this procedure, fascia was harvested from the lateral thigh region and passed through drill holes in the lateral condyle of the femur, and the medial condyle of the tibia to replace the ruptured cranial cruciate ligament.

Paatsama (1952), reported on ligament injuries in the canine stifle joint, describing a modification of Hey-Groves' fascia lata technique for cranial cruciate rupture in the dog. This technique remained the classic procedure in dogs, and the primary basis for comparison until imbrication and plication techniques were introduced some fourteen years later by Childers (1966).

Since these initial reports, numerous materials and surgical techniques have been tried and compared to the original fascia lata procedure. The success or failure of these attempts were evaluated solely on the subjective measurements of clinical response and post-mortem changes in the joint. It was not until the tensile strength of a patellar ligament replacement graft was reported on by Ryan and Drompp (1966), that this objective measure was included in the criteria of evaluation. However, the tensile strength of the normal cranial cruciate ligament in the dog was not determined until 1969 in a report by Gupta et al. Following this, Alm et al., (1974a), published a detailed report on the tensile strength of the cranial ligament in the dog, and included the effects of rotational forces.

In recent years, attention has been focused on reducing the surgical trauma created by the multiple drill holes used in the fascia lata procedures, and avoiding the functional disturbances created by the imbrication techniques. To this end, Jones (1963), reported on the use of a patellar ligament graft for replacement of cranial cruciate ligament in man. This technique was adapted to dogs by Dueland and Strande, both in 1966. Later it was modified by Arnoczky et al., (1979), who passed the graft completely through the joint to avoid drill holes, and termed it the "over-the-top" procedure.

Despite the significant incidence of cranial cruciate ligament rupture in cattle, only limited information is available on surgical repair of this condition in the bovine. A successful repair of cranial cruciate ligament rupture in a bull was reported by Hofmeyr (1968). Hamilton and Adams reported on a comparison study between various synthetic and natural prosthesis used for cranial cruciate ligament replacement in cattle in 1971. The authors of both reports used Paatsama's surgical technique.

The purpose of this investigation was twofold. First, the tensile strength requirements of cranial cruciate replacement was determined by measuring the ultimate tensile load required to rupture the cranial cruciate ligament in the normal bovine. Secondly, the feasibility of adapting the patellar ligament graft procedure to the bovine was studied. In addition, a comparison was made between placing the graft in a bone tunnel in the lateral femoral condyle, to passing it through the joint in the "over-the-top" procedure. The success of the procedures was determined by clinical response, tensile strength measurements and pathological changes.

This thesis consists of a general introduction, a literature reivew, two separate manuscripts, a general conclusion, general references, acknowledgements, and an appendix of additional results not contained in the manuscripts. The M.S. Candidate, Edwin William Moss, is the senior author, and principal investigator for each of the manuscripts. He also performed all of the experimental procedures which are reported on in the manuscripts, with only limited help from the co-authors.

LITERATURE REVIEW

The clinical signs and diagnosis of cranial cruciate ligament rupture was first described in humans by Stark (1850), while Carlin (1926) was the first to report on the condition in the canine. Carlen described two clinical cases in which it was possible to displace the tibia cranially in relation to the femur. He termed this displacement the "anterior drawer movement." When the two cases were examined at post mortem, they were found to have ruptured cranial cruciate ligaments.

The first treatments described for cranial cruciate ligament rupture in dogs were splinting and casting the affected leg. This was done to stabilize the stifle joint, in hopes that the rest would allow the ligament to heal sufficiently to restore adequate function. Schroeder and Schnelle (1941), reported on the physical examination, radiographic anatomy and diagnosis of stifle joint injuries in the canine. In this report they advocated the use of the Schroeder-Thomas splint as treatment for cranial cruciate ligament rupture. The splint was applied for 3-6 weeks with moderate traction and semi-flexion of the stifle. The results of this treatment were not reported. Schroeder and Schnelle, in the same article, reported the use of point-firing for treatment of an avulsion fracture associated with detachment of the caudal cruciate ligament in the dog. Knecht (1976), in an excellent review article, reported that firing had been used successfully by others as treatment for ruptured cranial cruciate ligament repair in the dog. It is interesting to speculate on what effects firing would have on the periarticular tissues of the stifle joint, and to compare these effects to what is accomplished by the plicating and imbricating technique introduced by Childers (1966).

Hey Groves (1917, 1920) described a surgical technique for repair of cranial cruciate ligament rupture in man. In this technique, fascia lata was used to replace the ruptured cruciate ligament. Using a modification of the Hey-Groves technique, Paatsama (1952) was the first to introduce surgical repair of cranial cruciate ligament rupture in the canine. In this procedure, a strip of fascia lata was dissected free from the lateral surface of the thigh, cranial to the border of the gluteobiceps muscle. The dissection was continued distally to the level of the lateral condyle of the femur. The strip of fascia, which was left attached at its distal end, was then stored under the skin until the joint was prepared. A lateral para-patellar incision was made through the joint capsule, and the patella luxated medially. Tunnels were then drilled in the lateral femoral condyle and the proximal tibia to approximate the insertions and direction of the normal cranial cruciate ligament. The fascia graft was then twisted slightly, and the free end pulled through the femoral and tibial tunnels.

Sufficient traction was applied to the graft to eliminate "the drawer movement," following which it was sutured to the deep fascia of the tibia. The leg was then stabilized with a Schroeder-Thomas splint for 15 days. Nine experimental cases were reported on in dogs with 8 of the 9 making a complete recovery during the 161 day observation period. Paatsama's technique became the classical procedure for repair of cranial cruciate ligament rupture in the dog, and the primary basis for comparison of new techniques over the ensuing years.

Many modifications of Paatsama's technique have been investigated and reported. Singleton (1957), freed the fascia strip at both ends and fixed it in the bone tunnels with orthopedic screws at the proximal and distal ends of the tunnels. Paatsama (1963) developed a modification to his original technique by dissecting the fascial strip to the level of the tibial tuberosity and thereby creating a near-circle of fascia when the free end was directed through the bone tunnels. It was felt the modification would add stability to the joint.

Gibbens (1957) adapted the use of skin instead of fascia in Paatsama's technique, in an effort to add strength to the graft. Chastain (1959) reported on the use of a skin graft for repair of simultaneous rupture of the cranial cruciate and medial collateral ligaments in the dog. He felt the procedure was sufficiently successful to warrant continued use.

Leighton (1961) reported on the use of whole skin in place of fascia in Paatsama's technique and was able to follow up on 77 of the 130 cases he tried. Sixty-four of the 77 were considered satisfactory, 11 fair and 2 failures. However, the author questioned whether the results were due to the replacement of the ligament or to inflamation and thickening of the joint capsule.

Vaughan and Bowden (1964) published the results of 30 cases using skin in place of fascia with Paatsama's technique. Many of the cases were of the heavier breeds. The results were considered excellent based on clinical response and range of joint movement. This study removed much of the concern among veterinary surgeons about skin grafts causing septic arthritis.

In the search for simpler and faster procedures, veterinary surgeons experimented with synthetic prostheses in place of fascia or skin. Johnson (1960) reported on the use of number 4 braided nylon while Emery and Rostrup in the same year reported on the use of 8 mm tubes of teflon, both in dogs. Numerous other reports, using various synthetics followed. Butler, (1964) reported on the use of teflon mesh in both dogs and cats. He emphasized the importance of aseptic technique, but considered the results superior to other synthetics. Supramid threads were studied by Zahm (1966) in 40 cases over a 3 year period. Four of the 40 cases developed infection. Cameron _et al_. (1968) reported on the use of braided teflon in four clinical and 5 experimental animals. In the 5 experimental animals, all were clinically sound during the observation period of up to 8 months. However, when the joints were examined at post-mortem, the teflon had broken in each case. In two of the cases, the ligament had regrown.

Singleton (1963) modified Paatsama's technique slightly, and used terylene, which was braided in four strands. He drilled converging tunnels in the lateral condyle of the femur and the medial condyle of the tibia. Two braids of terylene were placed in the joint, and a single braid threaded out through each tunnel in the femur and tibia. The free ends were then tied over the bone wedge in a simple suture knot. The author felt this procedure provided more strength and stability than the classical technique. In 1969, Singleton compared the above procedure to the use of terylene secured with buttons, and to nylon. The reported success rate was 95% for terylene alone, 57% for terylene secured with buttons and 35.5% for nylon.

The major concern with synthetic materials has been that joint movement would cause fatigue and failure of the material. Gupta and Brinker (1969) reported that nylon coated with silicon rubber failed in 7 dogs, 2 to 4 months after replacement surgery.

Vaughan (1963) did a comparison study between fascia, skin and nylon using 3 dogs in each group. Three months after the operation, all three skin grafts were intact, but 2 of the fascia and 2 of the nylon grafts had failed.

Imbricating and plicating techniques have been studied as a means of simplifying surgical correction of cranial cruciate rupture. The technique was originally reported by Childers in 1966, and modified by Pearson in 1969. In 1970 McCurnin carried out a comprehensive clinical and pathological evaluation of ruptured cranial cruciate ligament repair in the dog, comparing the imbrication technique to Paatsama's fascia technique. The imbrication technique consisted of opening the joint with a lateral para-patellar approach, removing a section of the cranial cruciate and closing the joint capsule with small Lembert sutures. Following this, the first layer of 10 to 15 Lembert sutures was placed on the lateral side of the joint and drawn taut with the leg held in extension. A second layer of 4 to 6 Lembert sutures was then placed over the first layer and tied down as tightly as possible. Finally, a third layer of 4-6 Lembert sutures was placed on the medial side of the joint.

Of the 52 stifles operated on, 14 had some degree of lameness at the time of euthanasia, 7 in each group. However, 10 of the 26 fascia replacements were partly or completely severed with only 4 of these 10 showing signs of lameness.

The author felt the modified Lembert technique provided advantages over the Paatsama technique, and supported its use.

This study was followed by reports on the Lembert imbrication technique by Pearson _et_ _al_. (1971), Pearson alone in 1971 and McCurnin _et_ _al_. (1971).

In 1972, Pond and Campbell compared conservative treatment to surgical repair for ruptured cranial cruciate ligament in the dog. They concluded surgical repair was required in working dogs and large breeds only, while forced rest would often provide adequate response in small dogs.

Throughout these early reports on cranical cruciate ligament repair, the criteria for measuring success was based on clinical response and; occasionally, post-mortem examination. Authors in the later years felt a need for more critical methods of evaluating procedures, especially in relation to long term results, biomechanical function and high stress performance.

To gain information on long term results, Vaughn and Scott (1966) conducted a study on the fate of skin grafts using Paatsama's technique in 6 goats. The grafts were examined histologically at 14, 30, 91, 182 and 365 days. The results indicated the grafts went through an early phase of necrosis, followed by vascularization, then infiltration by young collagen fibers, organization of this new collagen, and finally maturation. From approximately 182 days on, the skin grafts began to take the appearance of a ligament. At 365 days, the grafts were only about one half their original thickness, but were composed of ligament-like tissue.

Alm (1973) reported on the survival of patellar tendons used as a replacement graft in human patients which were evaluated during re-arthrotomy. In all cases, the graft was vascularized and viable. Another study on 13 human patients was reported by Alm _et al_. (1974a) with similar results.

The vascular supply to the cranial cruciate ligament of the dog, has been investigated by Paatsama (1952), Alm and Strömberg (1974), and Marshall _et al_. (1979). The conclusions of these studies were that the cranial cruciate ligament receives the majority of its vascular supply from the synovial tissues surrounding it, and from the infrapatellar fat pad. There is a degree of anastomosis with the vascular network of the femur at the femoral attachment, however very little anastomosis was apparent at the tibial attachment. The intrinsic vascularity of the ligament appeared to be diminished in its middle section.

Realizing that an autogenous graft must become vascularized to survive, attention was turned to using ligaments, tendons and fibrocartilage as possible replacement grafts. O'Donoghue (1963) stated that the knee joint resisted invasion by any tissue not covered by synovial membrane with the exception of fibrocartilage. This report was followed with a study by O'Donoghue _et al_. (1966) on suturing the two ends of the ruptured cranial cruciate ligament. The results indicated the ligament would heal only if the two ends were apposed shortly after rupture, and excess traction was not placed on the sutures. If left untreated for two weeks, the ends of the ligament contracted and could not be sutured together. When "properly" sutured, the cranial cruciate ligament healed within two weeks, but the strength was below normal.

Tillberg (1977) reported favorable results in man using either the lateral or medial meniscus of the joint being operated on as a replacement graft. The meniscus was trimmed to the shape and length desired, and secured with synthetic sutures through converging tunnels in the femur and tibia.

Hohn and Miller (1967) investigated the use of the long digital extensor tendon for correction of cranial cruciate ligament rupture in the dog. A reported disadvantage was the occasional absence of the femoral attachment of the tendon, making the procedure impossible to complete.

The use of the patellar ligament as a substitution graft for ruptured cranial cruciate ligament in man was described by Jones (1963), and adapted to dogs by Dueland (1966) and Strande (1966). In this procedure, a portion of the patellar ligament connected to a wedge of superficial patellar bone with its fascial covering, plus a strip of the quadriceps tendon, was used for the replacement graft. The graft, with its tibial tuberosity attachment intact, was placed in the joint and directed out through a tunnel in the lateral condyle of the femur, then secured by suturing it to the periosteum.

Chiroff (1975) reported on the fate of the transplanted patellar ligament in repair of ruptured cranial cruciate ligament in the dog. The results were encouraging, the grafts became vascularized and gradually increased in size and strength. According to Cheroff the grafts went through the phases of necrosis and shrinking, followed by vascularization, repopulation with fibroblasts and finally, organization of the newly formed collagen. This pattern is similar to that reported by Vaughan and Scott (1966) and Rudy (1974).

In 1977 Arnoczky and Marshall reported on the anatomy and function of the cruciate ligaments in the canine stifle joint. The same year, Arnoczky _et al_. studied the biomechanical function of the canine stifle. This study compared the function of the normal joint to controls where the cranial cruciate ligament had been surgically removed. In addition, the imbricating techniques and intra-articular techniques for cranial cruciate repair were compared to the normals and controls. They identified the instant center of motion in the stifle joint and concluded that the imbricating techniques altered normal function.

Arnoczky _et al_. (1979) introduced a modification of the patellar ligament procedure for ruptured cranial cruciate ligament repair, and termed it the "over-the-top" procedure. This modification placed the patellar ligament-tendon graft completely through the intercondylar fossa, and up over the caudal aspect of the lateral condyle of the femur. The graft was drawn taut with the stifle in semi-flexion, and sutured to the periosteum on the surface of the lateral femoral epicondyle. The results of 5 experimental cases were reported as excellent, with the graft increasing to 3 times its original diameter in 12 to 16 weeks. The results of 28 clinical cases were classified as 61% excellent; 32% good, 7% fair and no failures. The authors concluded the procedure did not alter the biomechanical joint function, was simple to perform, and was not subject to error such as misjudging the placement of a bone tunnel.

It is interesting to note that a considerable volume of research had been published on repair of cranial cruciate ligament rupture in the dog before the first reports appeared on what the tensile strength requirements of a replacement prosthesis were. Gupta _et_ _al_. (1969) stated that the tensile strength of the cranial cruciate ligament in the dog averaged about 4 times the animal's body weight. This initial report was followed by more detailed studies by Gupta _et_ _al_. (1971), and Alm _et_ _al_. (1974b), where the tensile strength of the normal canine cranial cruciate ligament was related to cross-sectional area, rotational forces and elongation. The conclusions of these studies indicated the tensile strength of the normal cranial cruciate ligament was 3 to 4 times the animal's body weight, and that rotation of the ligament reduced the load required to rupture it. Only one report could be found on measuring the tensile strength of a cranial cruciate ligament replacement graft. This study was conducted by Ryan and Drompp (1966) using a patellar ligament replacement procedure in one stifle joint in each of 15 dogs. The dogs were sacrificed at varying intervals from 2 to 25 weeks, and the tensile strength of the replacement graft was measured in each animal. Results were obtained on 14 of the 15 dogs and varied from 4 lbs. to 79 lbs. Attempts to measure the tensile strength of the normal cranial cruciate ligament failed because the test device could achieve a maximum load of 181 lbs., which was insufficient to rupture the normal cranial cruciate ligament in the animals tested.

Of interest, are two recent articles on the use of pure carbon fibers for ligament and tendon replacement. Jenkins et al. (1977), reported successful results in tendon replacement experiments in sheep. Then in 1978, Jenkins reported on the use of carbon fibers for replacement of the cranial cruciate ligament in sheep. The results were encouraging with all animals walking normally within one month. The sheep were sacrificed at varying intervals up to 8 months, and the prosthesis examined. In all cases, the carbon fibers were surrounded by ligament-like tissue and synovial membranes. The author suggests the carbon fibers act as a scaffold for new ligament tissue to grow on.

Despite the significant incidence of cranial cruciate ligament rupture in the bovine, no reports on attempted repair could be found until Hofmeyr published the results of a clinical case in 1968. This case concerned a valuable four year old Jersey sire that was observed to have injured his stifle during a breeding accident. The author examined the bull 3 weeks later and could observe the anterior drawer movement in the injured stifle when the animal was forced to walk. The Paatsama technique was used for surgical repair. The bull was put back into breeding service 7 months after the operation, and was still being used when last observed 18 months later. The author noted the bull did not flex the joint as much as the opposite normal when he walked, and some muscle atrophy persisted.

Following this report, Hamilton (1970) did a comparison study between fascia, skin, teflon and dacron alone, and in various combinations on 15 cattle. Paatsama's technique of surgical repair was used in all animals. The author evaluated the results on the basis of clinical response over a 5 to 14 month period and on post-mortem examination. He concluded that a full thickness strip of skin provided the best results. Hamilton and Adams reported the results of this study in 1971.

Wouters et al. (1976) reported on the use of radiographic examination for diagnosis of cranial cruciate ligament rupture in 19 cows. He concluded that radiography was a useful technique in confirming cranial cruciate rupture in cattle.

PART I: THE TENSILE STRENGTH OF THE CRANIAL CRUCIATE LIGAMENT OF THE BOVINE

Summary The ultimate tensile load of the cranial cruciate ligament of the normal adult bovine was measured on a tensile measuring instrument.

The ultimate tensile load was related to the animal's live body weight and to the cross-sectional surface area of the cranial cruciate ligament. The mean, range, variance, and standard deviation for each relationship was calculated and presented.

Four treatments were employed which were based on angle of the joint and time after sacrifice that the test was made. Repeatability was determined by using paired joints from the same animals.

The results indicated a high degree of correlation between the tensile load of the cranial cruciate ligament and the animal's live body weight and the cross-sectional area of the ligament. There were no significant differences between the four treatments used and the repeatability was high for the tensile load, the tensile load per unit body weight and the tensile load per unit cross-sectional area.

Introduction The search for an adequate replacement procedure and material for ruptured cranial cruciate ligaments has attracted the attention of medical and veterinary medical surgeons for most of this century (Hey Groves, 1917, 1920; Paatsama, 1952; Vaughan, 1963). Numerous materials and procedures have been tried with varying degrees of success, but to date only limited information has been available on the tensile strength requirements of a replacement prosthesis (Ryan and Drompp, 1966). The strength of the normal cruciate in the canine has been investigated, however, no references for similar work could be found for the bovine (Gupta et al., 1969; Gupta et al., 1971; Alm et al., 1974b). The significant incidence of cranial cruciate damage in valuable breeding bulls and mature cows has led to advances in surgical repair of this condition in cattle (Hofmeyr, 1968; Hamilton, 1970). The need for adequate tensile strength in a replacement prosthesis in this species is especially important for two reasons: first, the anatomy of the bovine leg reduces the effectiveness of ancillary external support devices and secondly, the nature of the bovine is to attempt to stand on the injured leg as soon as it awakens from anesthesia, which puts considerable stress on the prosthesis right after surgery.

This study was undertaken to provide information on the ultimate tensile load (UTL) requirements for cruciate replacement in the bovine and relate those requirements to measurable parameters such as live body weight and cross-sectional area of the ligament.

Materials and methods Tests were performed on stifle joints from normal, mature cows and bulls only. The joints were obtained from a local abattoir and from the Iowa State University Meats Laboratory. All the animals were slaughtered from one to eighteen days prior to collection for testing. The animals had been slaughtered and the carcasses handled and cooled in the standard packing plant procedure. The rear quarters had been boned out and the joints collected the day of or the day prior to testing.

Preparation of the joints consisted of separating the femur and the tibia at the mid-diaphysis with a band saw. The collateral ligaments, patella, medial, middle and lateral patellar ligaments, and the joint capsule were then carefully dissected away from their femoral and tibial attachments. The medial and lateral menisci and their ligaments and the caudal cruciate ligament were removed, leaving the cranial cruciate ligament as the only attachment between the femur and tibia.

Following the dissection, a one-half inch hole was drilled in the shaft of the femur and the tibia using an electric drill press and a steel bit at 450 rpm. These holes were positioned on the caudal borders approximately five centimeters proximal to the upper tip of the trochlea in the femur and an equal distance distal to the proximal epiphysis of the tibia (Fig. 1). Care was taken in placement of these holes to maintain the normal alignment of the femur and tibia (Fig. 2). The holes held steel pins which were used to secure the stifle joint in the U-clamps which were attached to the cross-heads of the tensile measuring instrument[1] (Fig. 3). Shim plates were

---

[1] Instron Testing Machine, model F/C 3209, Instron Corporation, 2500 Washington Street, Canton, Mass. 02021.

Fig. 1. Stifle joint of an adult bovine in position in the cross-heads of the tensometer unit. A shim plate is placed between the shaft of the tibia and the U-clamp to maintain the angle

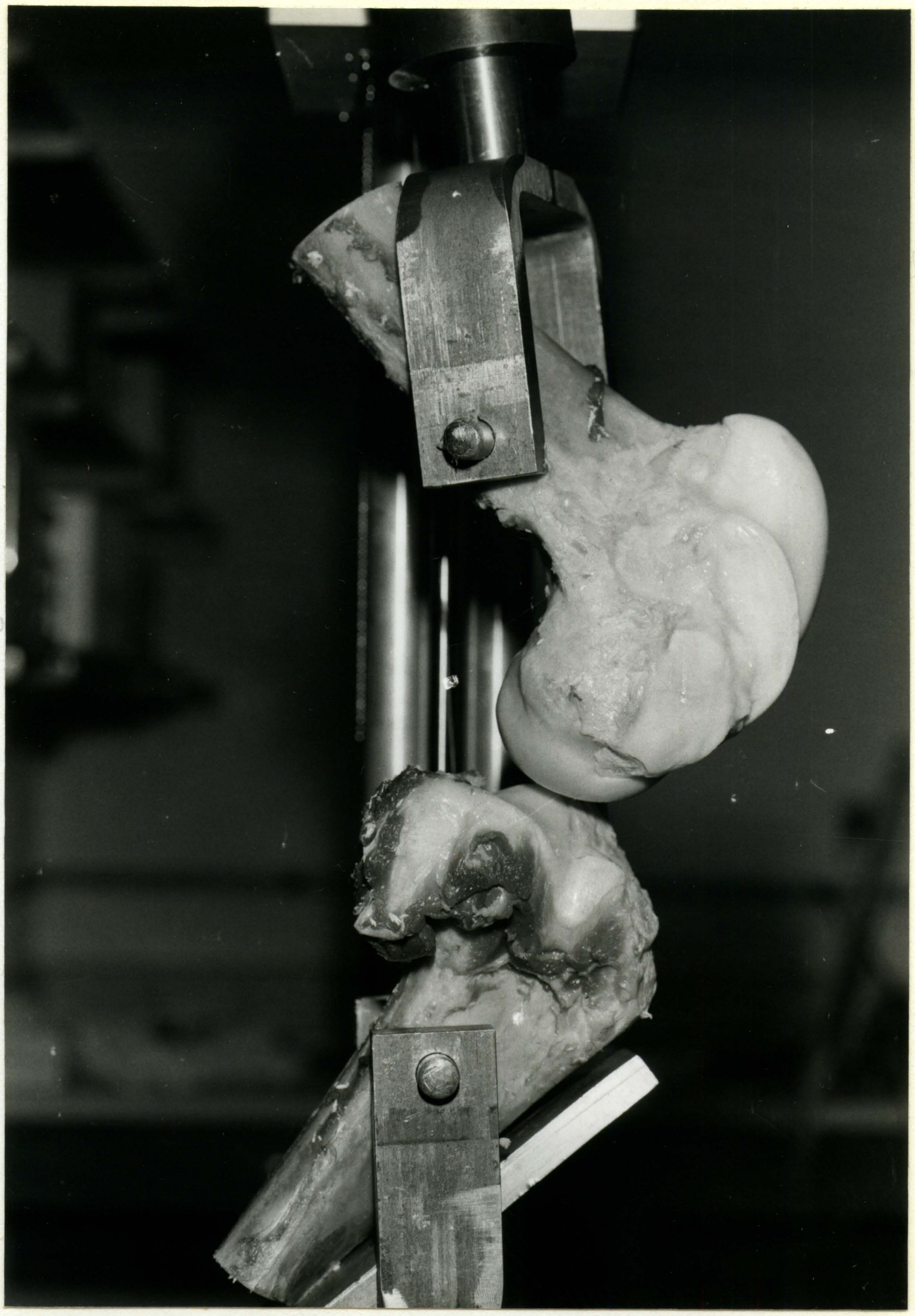

Fig. 2. Cranial view of the stifle joint in position for test showing the joint in near normal alignment with slight tension on the cranial cruciate ligament

Fig. 3. The tensometer measuring unit and recorder with joint in position for test


INSTRON
UP
STOP
DOWN
TRAVERSE
CYCLE CONTROL
Load Cell Amplifier

placed between the U-clamp and the bone to maintain the approximate same angle of the joint in each test (Fig. 1).

The ligaments were tested in tension at a crosshead velocity of 2 inches per minute. The resulting measured load was recorded on an X-Y recorder sweep[1] (Fig. 3). The UTL was determined by measuring the maximum deflection of the sweep in centimeters and translating this to kilograms of load on the scale of 1 cm = 90.5 kg (Fig. 4).

The cross-sectional area (CSA) of the ligament was estimated by assuming an elliptical shape and measuring the maximum and minimum diameters near the center (Fig. 5). Thus, the cross-sectional area equals π x d (max) x d (min) divided by 4.

The ultimate tensile strength (UTS) of the ligament can thus be determined by the equation UTS = UTL/CSA for each ligament.

The live body weight (BW) of the animal was estimated by doubling the warm carcass weight.

All tests were performed in air and at room temperature.

A test was considered satisfactory only if the cruciate ligament itself separated. Tests in which the ligament separated from its bony attachment or in which the epiphyseal plate failed or the cortical bone around the drill hole failed

---

[1] X-Y Recorder, Model 7045A, Hewlett-Packard, 1501 Page Mill Road, Palo Alto, CA 94304.

Fig. 4. Typical recording of successful tests on the left and right cranial cruciate ligaments from one animal

The ultimate tensile load of the ligament is determined by the centimeters of deflection and converted to kilograms of load by the ratio of 1 cm = 90.5 kg.

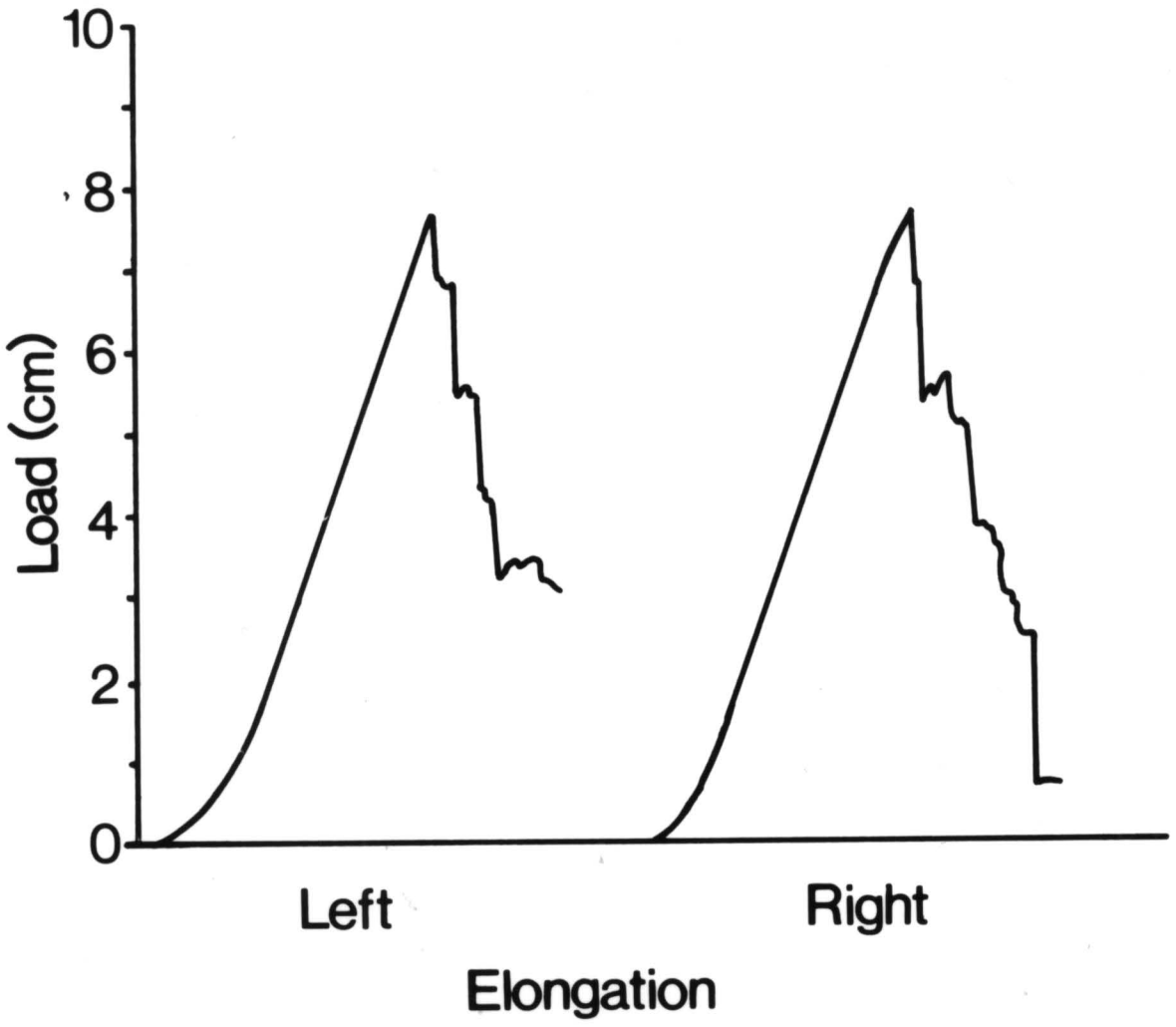
10
8
6
4
2
0
Load (cm)
Left
Right
Elongation

Fig. 5. Measuring the diameter of the cranial cruciate ligament with a Vernier caliper

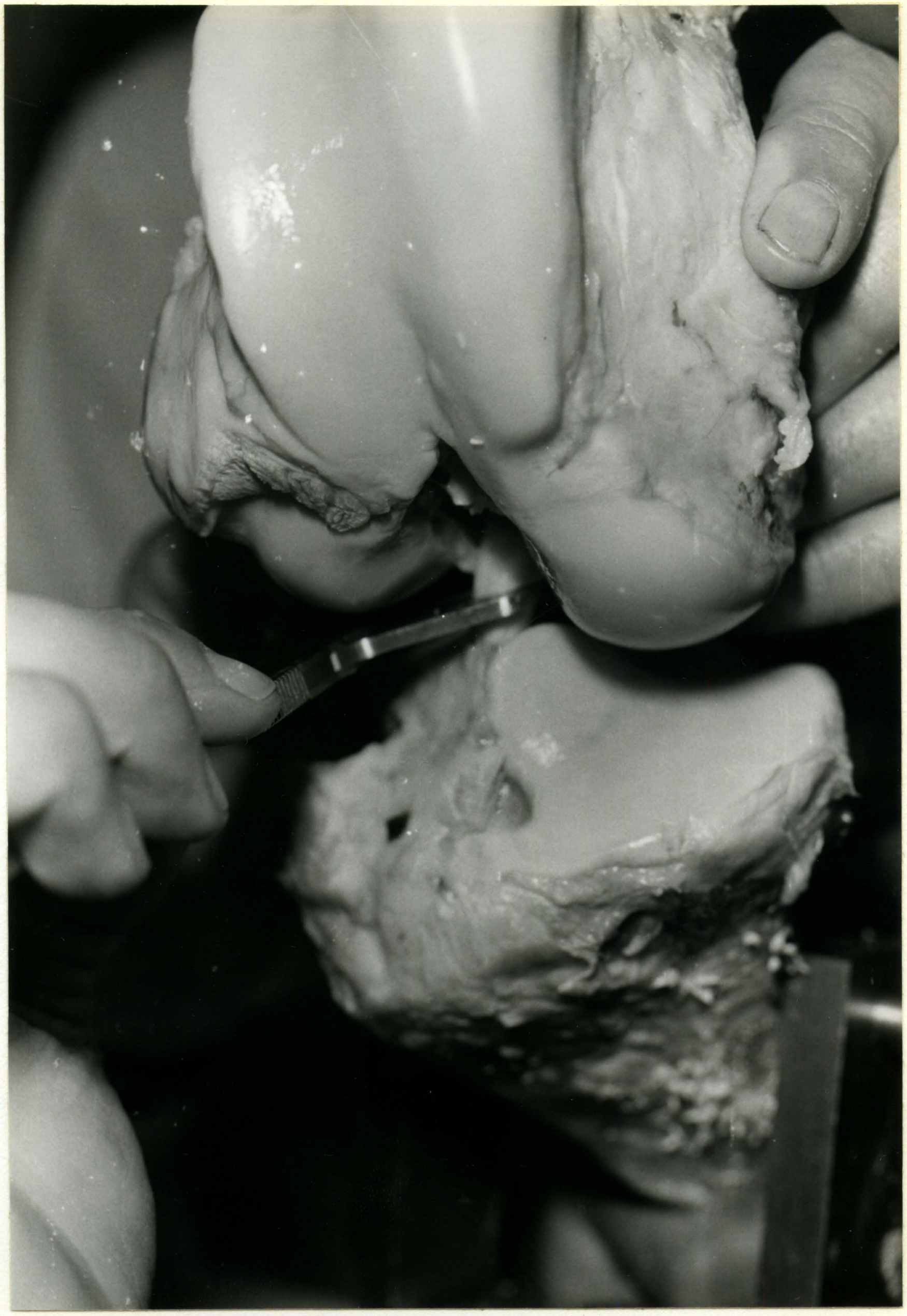

were considered inaccurate and were not included in the data.

Two configurations of joint angle were employed in the experiment. The first configuration was in full extension with the long axis of the femur and the tibia at 180° to each other. The second configuration was in partial flexion with the femur and tibia at approximately 125° (Fig. 1).

The left and right stifle joints were collected from 10 animals and these 20 joints were used to test the repeatability of the procedure. (The term "repeatability" in this paper is used in the sense of a measure of accuracy or precision.)

Results Thirty-four stifle joints produced satisfactory test results. Of these, 7 were tested in extension (180°) and 27 in partial flexion (125°).

The UTL was determined by the maximum kilograms of load observed before rupture for each cranial cruciate ligament. The UTL was then compared to the unit CSA and the unit BW, and the UTS was compared to the unit BW. The results of these tests and comparisons including the range, means, variances, and standard deviations are given in Table 1 for extension and Table 2 for partial flexion.

Four treatments were applied in the study as follows:

Treatment 1) joints tested in extension

Treatment 2) joints tested in partial flexion and tested 2 days or less after sacrifice of the animal

Table 1. Joints in extension

Test number	UTL(kg)	CSA(cm^2)	UTL/CSA(kg/cm^2)	BW(kg)	UTL/BW(kg/kg)	UTS/BW(cm^{-2})
3	1047.6	1.176	890.8	517.7	2.204	1.721
5	615.4	1.125	547.0	419.1	1.468	1.305
6	606.4	1.105	551.3	474.1	1.279	1.163
7	660.6	0.865	763.7	431.8	1.530	1.769
8	543.0	0.985	551.3	447.7	1.213	1.231
9	633.5	0.814	778.2	381.8	1.659	2.038
10	687.8	0.802	859.5	411.8	1.670	2.087
Range	543.0-1647.6	0.802-1.176	547.0-890.8	381.8-517.7	1.213-2.204	1.163-2.087
Mean	684.9	0.982	705.9	440.6	1.575	1.616
Variance	27653.4	0.025	248.9	1990.6	0.107	0.147
Standard Deviation	166.3	0.157	152.5	44.6	0.328	0.384

Table 2. Joints in partial flexion

Test number	UTL(kg)	CSA(cm^2)	UTL/CSA(kg/cm^2)	BW(kg)	UTL/BW(kg/kg)	UTS/BW(cm^{-2})
2	1104.2	1.570	703.4	681.8	1.620	1.032
11	660.6	0.916	721.2	445.5	1.483	1.619
12	615.4	0.718	857.1	445.5	1.381	1.924
13	642.5	0.950	676.3	445.5	1.444	1.518
14	678.7	0.913	743.4	445.5	1.523	1.669
15	823.5	0.971	848.1	381.8	2.160	2.221
18	606.3	0.818	741.2	488.2	1.240	1.518
19	552.1	0.685	806.0	488.2	1.130	1.651
20	778.3	0.924	842.3	480.9	1.620	1.752
21	778.3	0.924	842.3	480.9	1.620	1.752
22	714.9	0.793	901.5	465.5	1.536	1.937
23	696.8	0.833	836.5	465.5	1.497	1.797
24	669.7	0.897	746.6	520.9	1.286	1.433
25	678.6	0.982	691.0	520.9	1.303	1.327
26	371.1	0.784	473.3	390.9	0.949	1.211
27	488.7	0.838	583.2	454.5	1.075	1.283

28	452.5	0.911	496.7	454.5	0.996	1.093
29	642.6	0.934	688.0	490.9	1.309	1.402
30	515.9	0.804	641.7	438.2	1.177	1.464
31	534.0	0.701	761.8	438.2	1.218	1.738
32	470.6	0.794	592.7	420.0	1.120	1.411
33	479.7	0.733	654.4	420.0	1.142	1.558
35	633.5	0.846	748.8	490.9	1.290	1.525
37	687.8	0.882	779.8	447.3	1.538	1.743
38	696.9	0.780	893.5	369.1	1.889	2.421
39	696.9	0.821	848.1	369.1	1.889	2.298
41	588.3	0.680	865.2	406.4	1.448	2.129
Range	371.1-1104.2	0.680-1.570	473.3-901.5	369.1-681.8	0.949-2.160	1.032-2.421
Mean	639.2	0.867	740.2	457.3	1.403	1.645
Variance	20494.6	0.028	13217.2	3705.8	0.081	0.122
Standard Deviance	143.2	0.166	115.0	60.9	0.285	0.349

Treatment 3) joints tested in partial flexion and tested 5 to 18 days after sacrifice

Treatment 4) joints tested in partial flexion and tested between 2 and 5 days after sacrifice

The means and mean square error for the 4 treatments are displayed in Table 3. An analysis of variance was used to perform "t" tests between Treatment 2 and Treatment 3 and between Treatment 1 and Treatments 2, 3 and 4 combined. The tests indicated that differences between the treatments were not statistically significant.

A second analysis was used to compare the differences between the 2 joints from one animal to the differences between animals. These comparisons were made to test the repeatability of the experiment and to determine the ability to characterize the animal by testing only 1 joint. The data are given in Table 4. The repeatability was very high for UTL (0.96) and for UTL/BW (0.97), it was lower for UTL/CSA (0.76) and for UTS/BW (0.85), but still quite high for most biological measures. The lower repeatability values for UTL/CSA and UTS/BW can be attributed to the relatively lower repeatability for the CSA.

<u>Discussion</u> The cattle industry has made significant advances in genetic improvement in this century. Through the use of artificial insemination and, more recently, embryo transfer, the importance and value of genetically superior

Table 3. The mean values for the experimental treatments

Treatment no.	UTL(kg)	UTL/CSA(kg/cm^2)	UTL/BW(kg/kg)	No. joints
1	685	706	1.58	7
2	682	801	1.50	8
3	654	737	1.42	14
4	528	650	1.21	5
Mean square error	20655	13747	0.076	

Table 4. Paired joints versus animal differences

Animal #	UTL(kg)	CSA(cm^2)	Average UTL (kg)	Average CSA (cm^2)	UTL/CSA(kg/cm^2)	UTL/BW(kg/kg)	UTS/BW(cm^{-2})
1	(L) 660.6	0.916	638	0.817	789	1.43	1.77
	(R) 615.4	0.718					
2	(L) 642.5	0.950	661	0.932	710	1.48	1.59
	(R) 678.7	0.913					
3	(L) 606.3	0.818	579	0.752	774	1.19	1.59
	(R) 552.1	0.685					
4	(L) 778.3	0.924	778	0.924	842	1.62	1.75
	(R) 778.3	0.924					
5	(L) 714.9	0.793	706	0.813	869	1.52	1.87
	(R) 696.8	0.833					
6	(L) 669.7	0.987	674	0.940	719	1.29	1.38
	(R) 678.6	0.982					
7	(L) 488.7	0.838	471	0.875	540	1.04	1.19
	(R) 452.5	0.911					
8	(L) 515.9	0.804	525	0.753	702	1.20	1.60
	(R) 534.0	0.701					
9	(L) 470.6	0.794	475	0.764	624	1.13	1.49
	(R) 479.7	0.733					
10	(L) 696.9	0.780	697	0.801	871	1.89	2.36
	(R) 696.9	0.821					
	Repeatability		0.96	0.43	0.76	0.97	0.85

individuals has increased dramatically. To condemn valuable animals to slaughter because of breeding incapability and pain from a ruptured cranial cruciate, as has been suggested, represents an enormous direct economical loss to the owner, and an unassessable loss of genetic potential (Wouters et al., 1976). It may be argued that cranial cruciate rupture reflects a genetic weakness and these animals should not be saved for breeding purposes. This allegation may be valid but in cattle the high potential for accidental injury must be given serious consideration. The economics of this condition in cattle has stimulated continued investigation for a satisfactory cruciate replacement procedure (Hofmeyr, 1968; Hamilton, 1970).

The purpose of this study was to provide information that could be used when selecting a replacement prosthesis for cattle. The UTL of the normal cranial cruciate ligament was measured and correlated with the cross-sectional area of the ligament and the live body weight. The cross-sectional area was used because it could be measured with reasonable accuracy and would provide some indication of the physical size limits of a potential replacement prosthesis. Live body weight was chosen as a measurable parameter of a potential patient to be used as a guide when selecting a replacement prosthesis. The results of this study indicate the UTL of the prosthesis should exceed the animal's live body weight by approximately 1½ times. From this figure, one can then calculate the approximate physical size limits of the prosthesis if it is to pass through the intercondylar space and occupy the area where cranial cruciate ligament is normally located. For example, if the animal weighs 600 kg, the UTL of the prosthesis should be 600 x 1.5 = 900 kg, then the cross-sectional area should not exceed 900/740 = 1.2 cm^2. (The 740 value is the mean UTL/CSA from Table 2.)

The statistical analysis of the effect of postmortem aging on the UTL of the cruciate (Table 3) has no clinical significance but was included because it may be useful in future surgical investigations of cruciate repair. The high cost of large animal experimentation makes slaughter for salvage a desirable feature. Aging the carcass provides improved meat quality, but this means hanging the carcass in a cooler for 7 to 10 days by the hocks, which cannot be done with the stifle joints removed. In this study, the results of the "t" tests comparing treatment 2 to treatment 3 indicate there was no significant change in the tensile strength of the cranial cruciate ligament up to 18 days after slaughter. This suggests that experiments designed to compare different surgical techniques or prosthetic materials could include normal slaughter for salvage in their cost accounting.

Analysis of paired joints (Table 4) was undertaken for 2 purposes. First, it provided a means of testing the repeatability of the experimental procedure. If the assumption is made that the left and right cruciate ligaments in the animal have identical tensile strengths, then comparing the test results of left versus right is a measure of accuracy. The results of the analysis support this assumption.

Secondly, the high degree of repeatability indicates there is no need to measure both joints to characterize the animal. Thus an experimental procedure on one stifle can be compared to the opposite normal stifle to evaluate the effectiveness of the procedure.

The 2 configurations of joint angle in the tests were necessitated by the high percentage of test failures in the fully extended position. These failures were related to the placement of the pin holes, resulting in the cortical bone around the drill hole breaking, or in some cases the epiphyseal plate of the tibia separating. Observation of bulls during normal mating and measurement of the angle of the stifle joint in various postures suggested use of the partially flexed position. This configuration allowed better placement of the drill holes and resulted in fewer test failures. In both configurations, the full cross-section of the cruciate ligament appeared to be brought under tension simultaneously during the test. Analysis of the data confirmed that differences between extension and flexion groups were not statistically significant.

The effect of torsion coupled with a high velocity application of load, which is probably what occurs in traumatic injury, was not investigated but could be expected to reduce the UTL of the cranial cruciate ligament. However, the other attachments between the femur and tibia, such as skin, fascia, muscles, tendons and ligaments, which tend to support cruciate ligament function, if left in place would increase the UTL measurement.

Conclusion The cranial cruciate ligament in the bovine has considerable tensile strength when direct tension is applied. The load required to rupture the cranial cruciate ligament under the test conditions employed in this experiment is likely many times greater than that encountered in normal use in the animal and indicates the ligament possesses considerable reserve to withstand trauma.

The results of this experiment indicate a prosthesis must possess a very high UTS to be considered adequate in replacement procedures for cranial cruciate rupture in the bovine.

PART II: CRANIAL CRUCIATE REPAIR IN THE BOVINE USING A PATELLAR LIGAMENT GRAFT

Summary The cranial cruciate ligament was surgically removed from the right stifle joint in 10 heavy steers and two bulls, following which the cruciate ligament was replaced with a tendon-ligament graft harvested from the tendon of the gluteo-biceps muscle plus a portion of the lateral patellar ligament. Two surgical techniques were compared using 6 animals in each group.

Clinical response was observed over a 4 to 5 month period and the animals were then euthanatized and both stifle joints from each animal recovered. The tensile strength of the grafts and the normal cranial cruciate ligaments in the opposite stifle were measured. Gross and histopathological examinations were performed on each animal.

Both surgical techniques proved to be simple to perform and caused minimal inflammatory response. The clinical response was considered excellent in 9 of 12 animals and the graft remained healthy and viable in 11 of 12 animals. However, the tensile strength of the graft was less than the cranial cruciate ligament in the opposite normal stifle in all animals tested.

Introduction The history of cranial cruciate ligament repair in veterinary medicine dates from the adaptation of a classical human operative technique to dogs (Paatsama, 1952; Hey Groves, 1920). Since these initial reports, the diagnosis, clinical signs, and treatment of cruciate rupture in dogs has received considerable attention in veterinary literature (Knecht, 1976; McCurnin, 1970; Rudy, 1974; Vaughan, 1963; Vaughan and Bowden, 1964; Pond & Campbell, 1972).

In recent years, investigators have reported very successful results using an autogenous graft consisting of fascia harvested from the upper cranial thigh, the fascia covering the patella and a ridge of patellar bone, plus the medial portion of the patellar ligament (Alm, 1973; Alm *et al.*, 1974a; Arnoczky *et al.*, 1979; Dueland, 1966; Jones, 1963; Strande, 1966; Chiroff, 1975). This graft, which is left attached to the tibial tuberosity by its natural insertion, is then placed in the joint and either secured in a hole drilled in the lateral condyle or, more recently, passed through the intercondylar space and pulled up over the caudal aspect of the lateral epicondyle. This latter technique, termed the "over-the top" procedure, provides several advantages over techniques requiring bone tunnels. These advantages are: less alteration to the biomechanical function of the joint, less surgical time and less trauma to joint tissues (Arnoczky *et al.*, 1977; Arnoczky and Marshall, 1977).

Despite the significant incidence of cruciate injury in cattle, only limited information is available on surgical repair in this species (Hamilton, 1970; Hofmeyr, 1968).

This investigation was carried out to determine the feasibility of adapting the autogenous patellar ligament graft procedure to cranial cruciate replacement in the bovine. In addition, a comparison was made between placing the graft in a bone tunnel in the lateral condyle of the femur to the "over-the-top" procedure. The criteria for comparing the success of these procedures included clinical response, tensile strength measurement, and gross and histopathological evaluations.

Materials and methods Ten steers and two bulls of Hereford or Holstein breeding, ranging in ages from eighteen to thirty-six months, and in weight from 368 kg to 493 kg were selected for the experiment. All animals were healthy and physically sound prior to purchase. The animals were housed in a dry lot and fed a balanced ration of hay and concentrate.

Anesthesia Prior to surgery, each patient was deprived of feed and water for 24 hours, then anesthesia was induced with rapid intravenous infusion of 5% guaiafenesin[1] and 0.2% thiamylal sodium[2] in normal sterile saline. The average dose rate of 2 ml/kg was required for endotracheal intubation. Induction was carried out with the patient standing but secured to the surgical table.

Anesthesia was maintained with halothane.[3] Ventilation was controlled by intermittent positive pressure ventilation

---

[1] Glyceryl quaiaculate, gecolate, Summit Hill Labs, Summit, New Jersey.

[2] Surital - Parke-Davis and Co., Detroit, Michigan.

[3] Fluothane - Ayerst Labs Inc., New York, N.Y.

using an integrated anesthetic machine ventilator.[1]

Surgical procedure The animals were positioned in left lateral recumbency with the right rear leg suspended so the leg was horizontal to the body. The entire lateral aspect of the thigh from the greater trochanter to the hock was clipped, as was the cranial aspect of the stifle, the flank, and the medial side of the leg. The area was routinely prepared for aseptic surgery then draped with three large linen drapes positioned to produce a triangular exposure for surgery.

The skin incision started at a point approximately 15 cm distal and 5 cm cranial to the major trochanter of the femur and extended to the tip of the tibial tuberosity (Fig. 6).

Subcutaneous tissue was separated with scissors to expose the junction between the gluteobiceps muscle caudally and the vastus lateralis muscle cranially. The thick fascial attachment between these two muscles was severed with scissors from the level of the lateral patellar ligament to the proximal extent of the skin incision. The cranial border of the gluteobiceps muscle was then reflected caudally to expose the strong tendon of the gluteobiceps on the muscle's medial face. This tendon was then incised longitudinally, 1 cm from its lateral border, from the proximal exposure to its insertion on the lateral patellar ligament. A second incision paralleling the

---

[1] Model 100 - Innovative Engineering Inc., Cathedral City, California.

Fig. 6. Location of the skin incision in relation to anatomical structures of the right rear leg

(A) patella; (B) tibial tuberosity; (C) greater trochanter

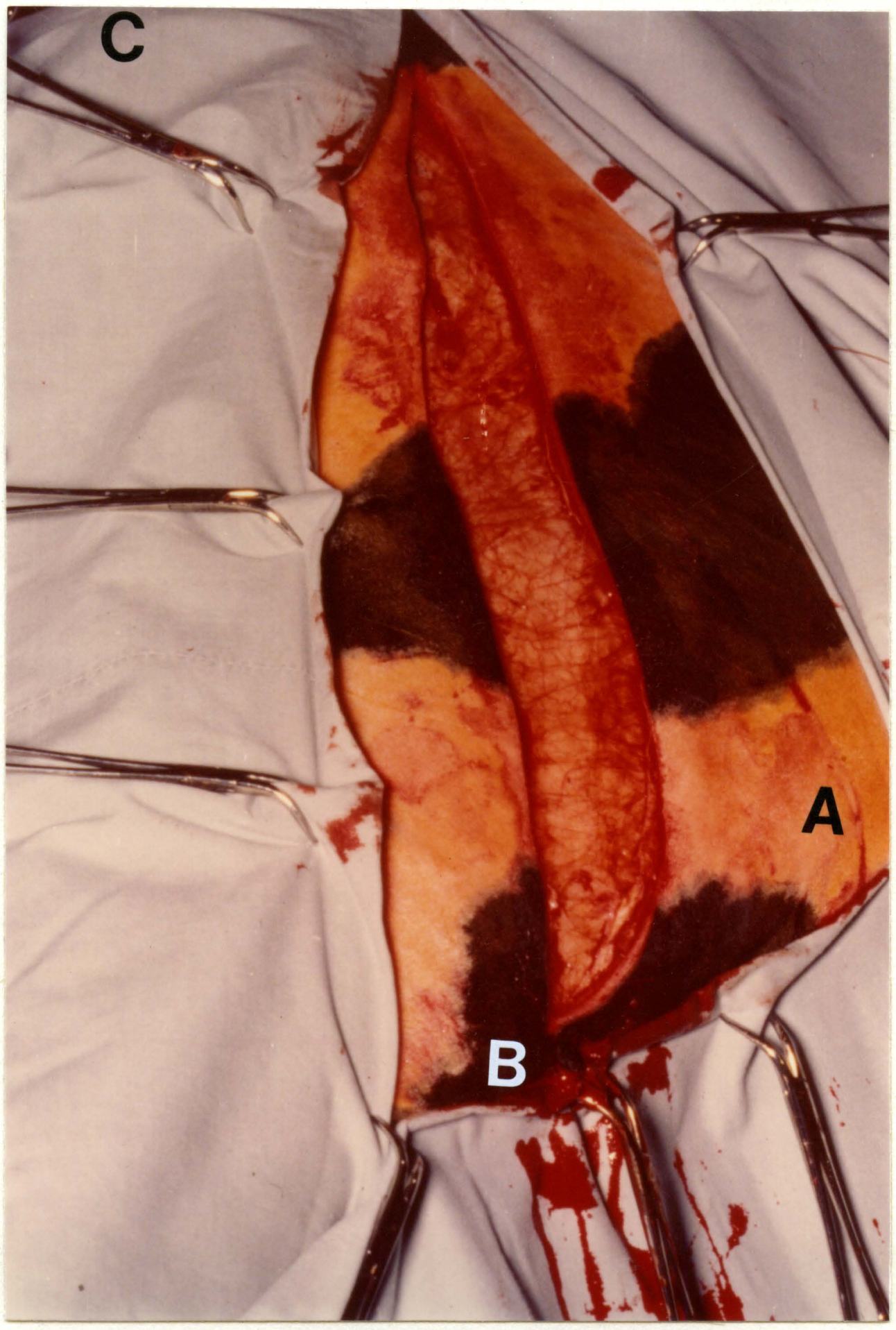
C
A
B

above was made in the tendon to provide a tendon strip approximately 2.5 cm wide. This strip of tendon was then dissected free from the underlying muscle attachments (Fig. 7).

At the point of the insertion of the gluteobiceps tendon to the lateral patellar ligament the graft was extended by splitting the lateral patellar ligament, attempting to maintain the same or slightly more tissue volume than the proximal tendon portion. Thus, a 40 cm long tendon-ligament graft, which inserted on the tibial tuberosity, was created (Fig. 8).

The graft was then wrapped in gauze, moistened with normal sterile saline and set aside. The defect created in the gluteobiceps tendon was closed with number one chromic catgut using a simple continuous pattern.

The stifle joint was exposed by incising the lateral patellar ligament midway between the patella and the insertion of the gluteobiceps tendon, exposing the underlying bursa. The joint capsule was incised over the lateral epicondyle, and the incision extended with scissors to its proximal and distal extent. The joint was placed in full extension, and the patella luxated medially, then flexed to maintain the patellar luxation and to allow exposure of the cranial cruciate ligament. While exposing the cranial cruciate ligament for removal, care was taken to minimize disturbance of the blood supply to the intercondylar attachments of the joint capsule and the infrapatellar fat pad. The cruciate ligament was removed by

Fig. 7. Harvesting the tendon-ligament graft

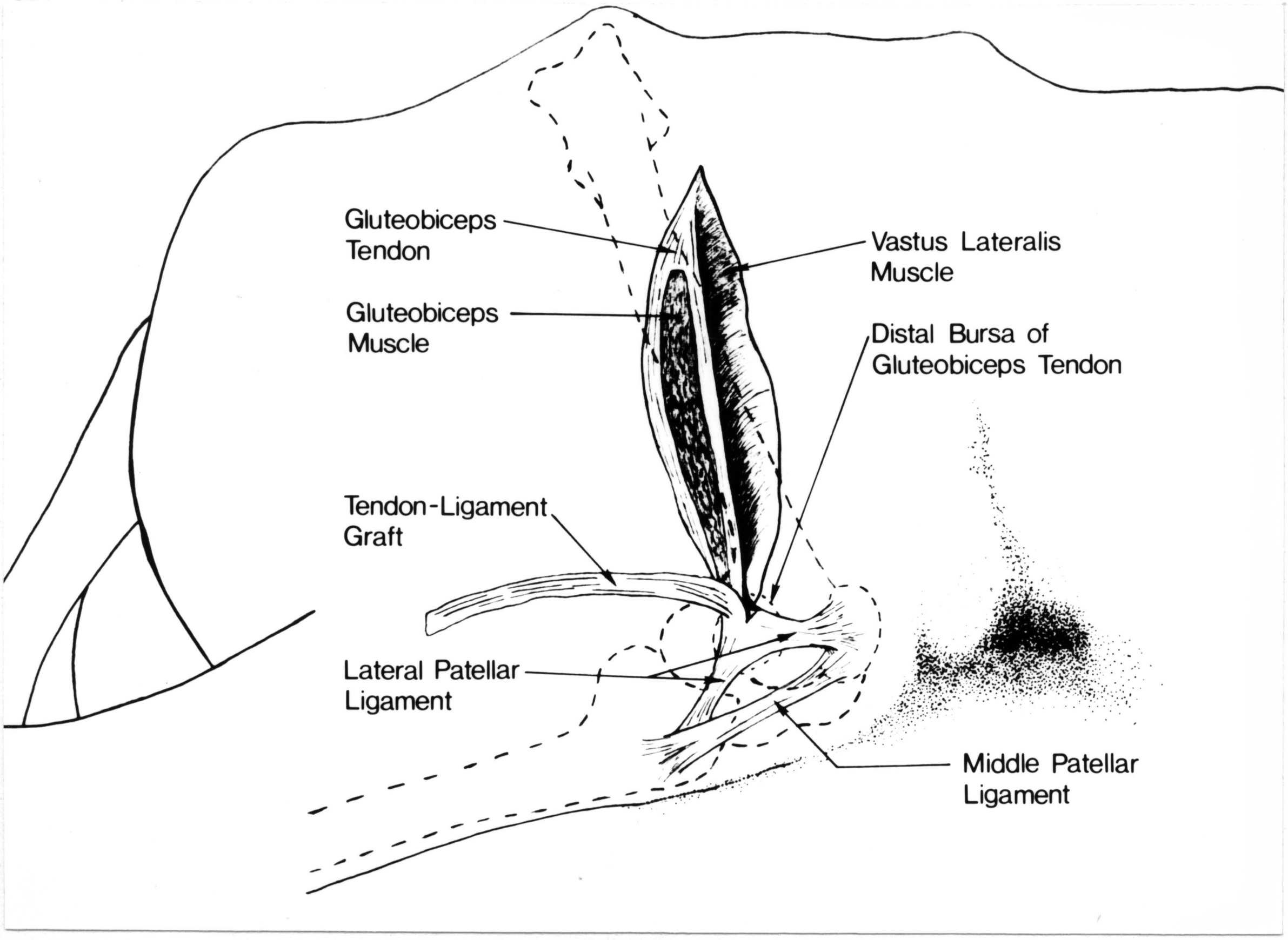
Gluteobiceps Tendon
Gluteobiceps Muscle
Vastus Lateralis Muscle
Distal Bursa of Gluteobiceps Tendon
Tendon-Ligament Graft
Lateral Patellar Ligament
Middle Patellar Ligament

Fig. 8. The graft with its insertion on the tibial tuberosity and the relationship to the remaining lateral patellar ligament

(a) lateral patellar ligament; (b) tendon of the gluteobiceps muscle; (c) tendon-ligament graft; (d) patella

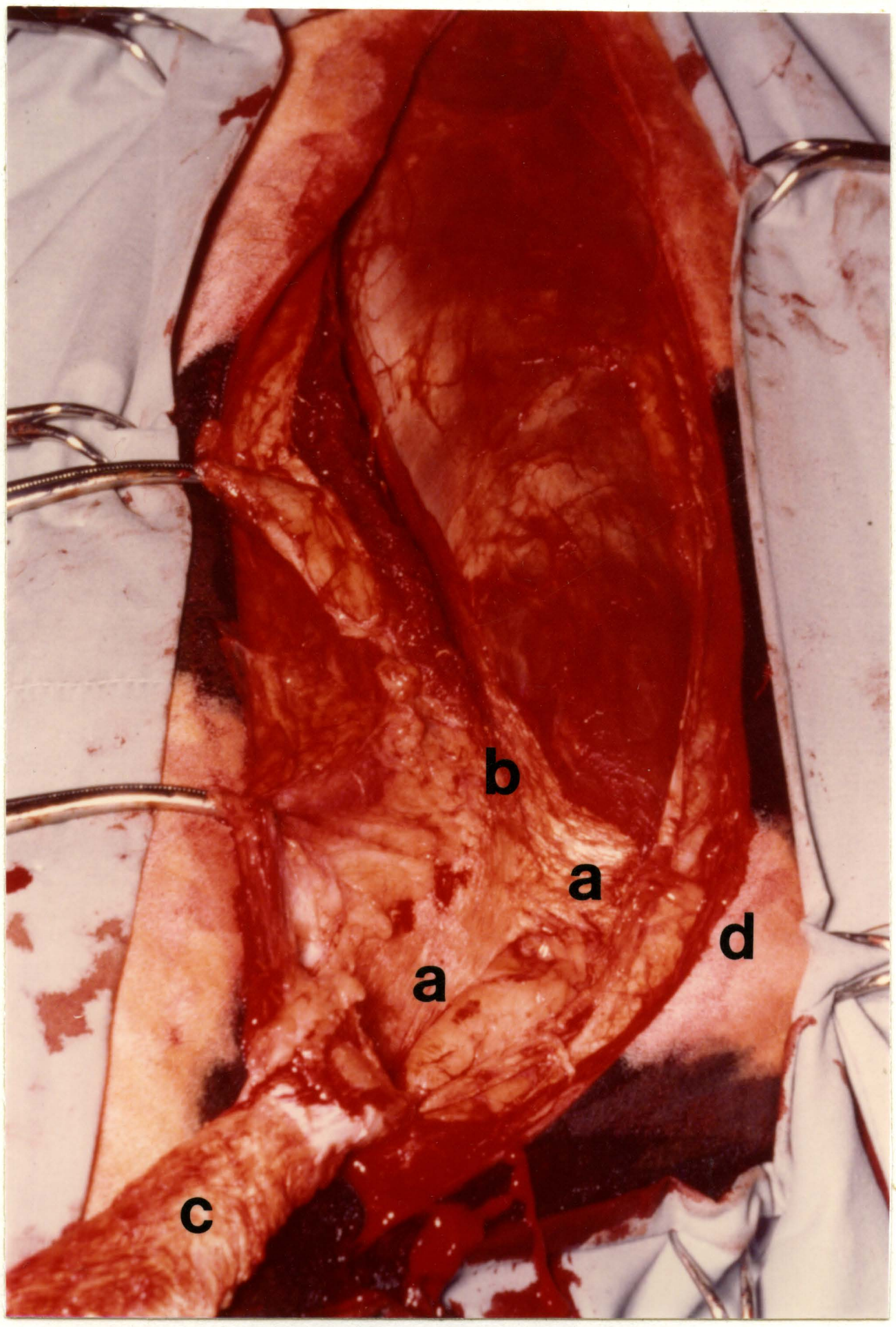
b
a
d
a
c

first isolating it with a curved hemostat, then incising it as close to its femoral attachment as possible, and dissecting the distal portion from its insertion on the tibia.

On six animals, the graft was directed through the infrapatellar fat pad and then pulled through the intercondylar space and around the caudal aspect of the lateral condyle This was accomplished by creating a tunnel in the soft tissue caudal to the lateral condyle and introducing an 18 gauge stainless steel wire down through the tunnel and out through the joint. The proximal end of the graft was then sutured to the wire and the graft guided through the joint by applying traction to the wire (Fig. 9).

In the remaining animals a 12 mm (½") hole was drilled in the lateral condyle with a stainless steel bit and a surgical air drill.[1] The bit, protected by a drill guide manufactured from 12 mm (½") steel pipe, was positioned as deep in the intercondylar space as possible, and directed dorso-laterally to enable the drill hole to emerge on the caudal border of the lateral epicondyle. The hole and the joint were then flushed with normal sterile saline several times to remove bone filings. The graft was introduced into the intercondylar space and through the hole in a manner similar to the one described above (Fig. 10).

---

[1] Model P-300 - 3M Co., Surgical Products Division, St. Paul, Minnesota.

Fig. 9. The position of the graft in the "over-the-top" procedure

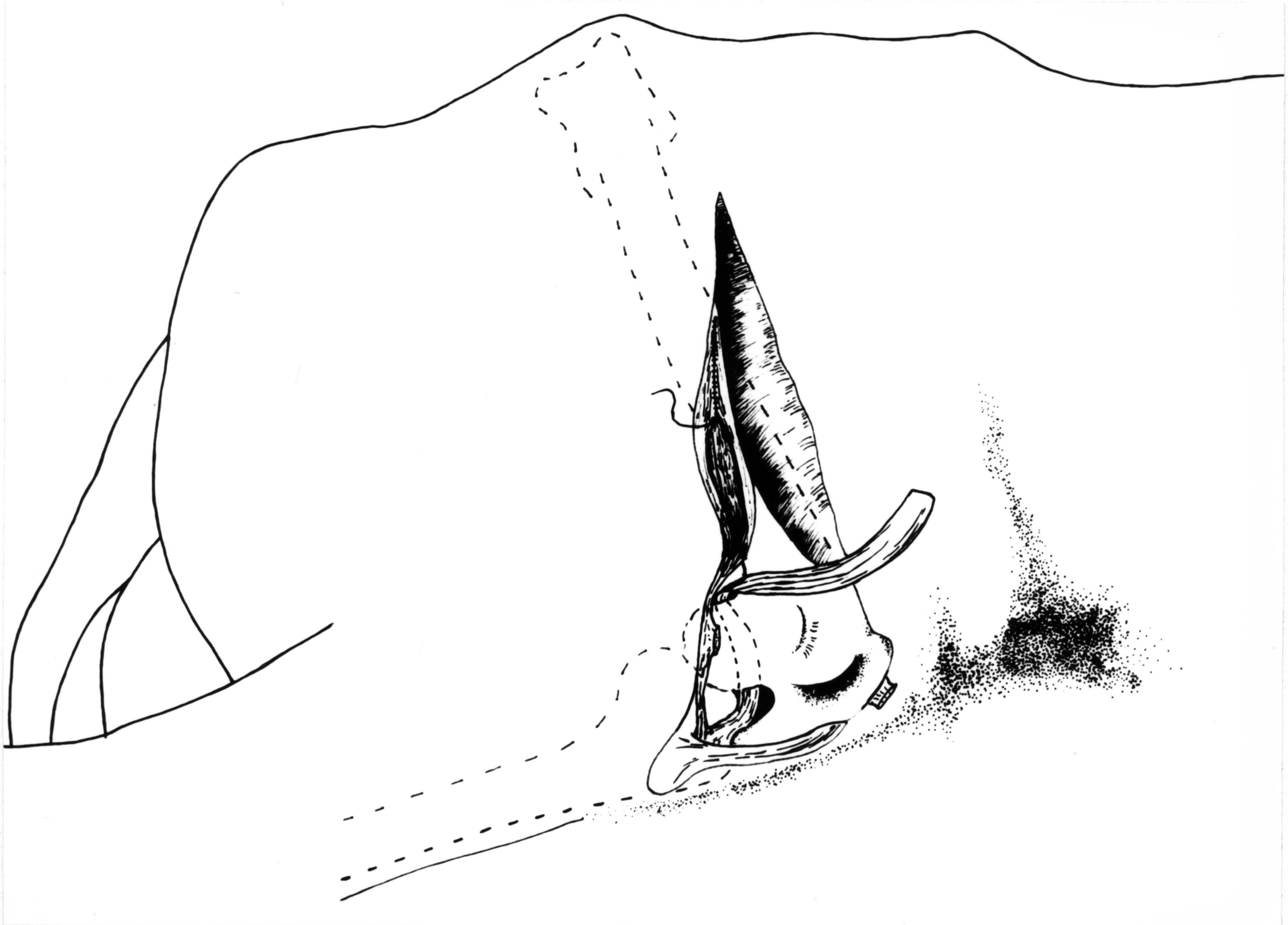

Fig. 10. The position of the graft in the bone tunnel procedure. The bone tunnel is located in the lateral condyle of the femur

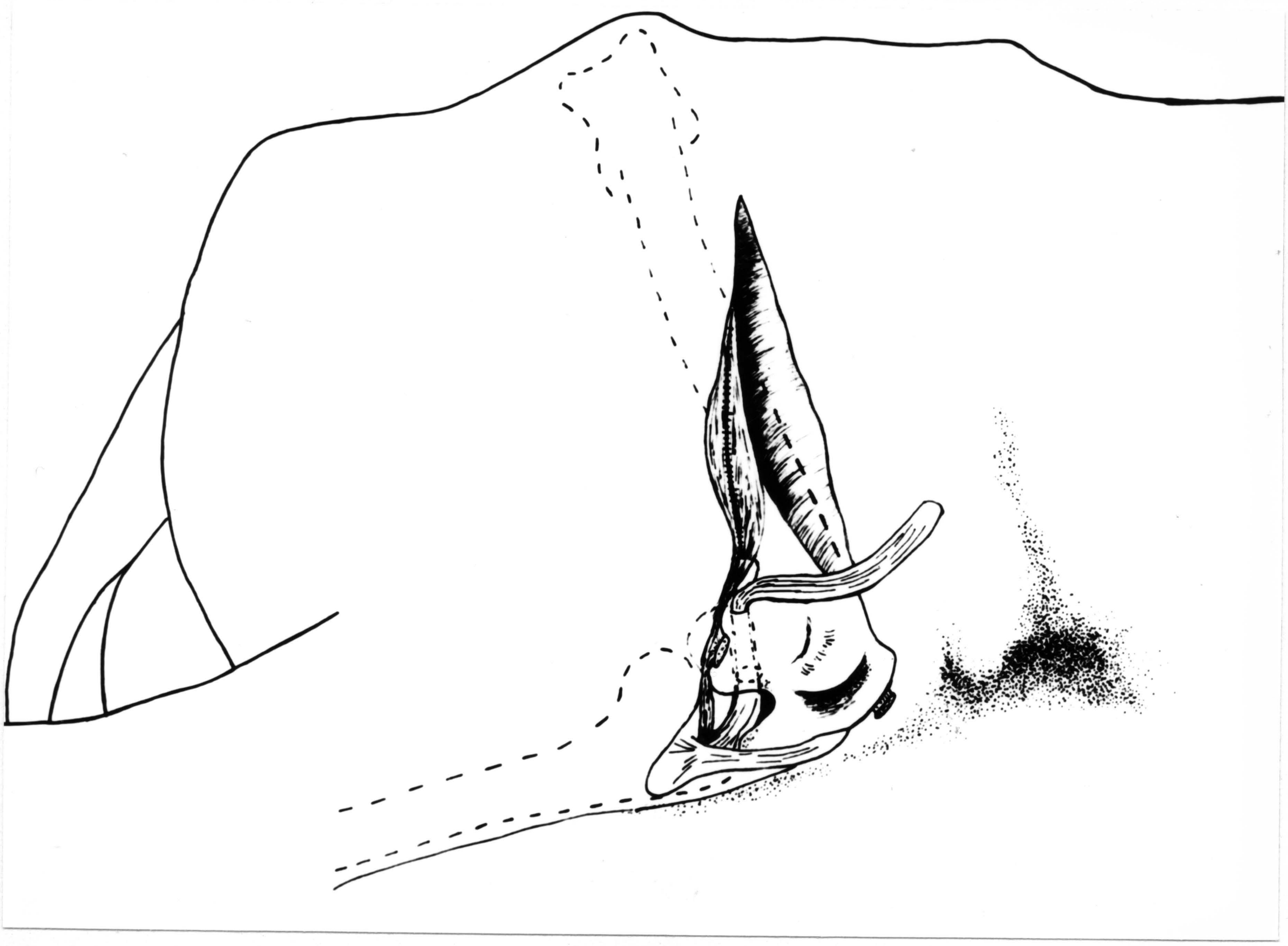

The graft was secured to the femur in the following manner in both groups. The joint was placed in partial extension to relocate the patella. A periosteal groove was created in the dorsal surface of the lateral epicondyle, and the graft placed in this groove. The groove was located as close as possible to the base of the lateral trochlea to avoid interfering with the bursa of the gluteobiceps tendon. A 50.8 mm (2") four hole small utility bone plate[1] was placed over the graft (located in the periosteal groove) and secured with two bone screws,[2] one on either side of the graft. With the stifle joint in slight flexion, sufficient traction was applied to the graft to remove cranial drawer movement. The bone screws were then tightened and the graft folded back over the plate and sutured to itself with heat sterilized 0.6 mm nonabsorbable suture.[3] Three simple interrupted sutures were placed on each margin.

The same procedure was used to close the arthrotomy incision in all animals. The joint capsule was sutured with #0 catgut in a simple continuous pattern. The previously

---

[1] Richards Manufacturing Co., 1450 Brooks Rd., Memphis, Tennessee.

[2] Hi Torque self tapping cone screw (4.5 mm diameter x 38.1 mm length). Richards Manufacturing Co., 1450 Brooks Rd., Memphis, Tennessee.

[3] Vetafil - S. Jackson Inc., Washington, D.C.

incised lateral patellar ligament was reapposed with two everting and one inverting mattress sutures using heat sterilized nonabsorbable material.[1] The mattress sutures were placed so they did not enter the underlying bursa. The fascial layer and the subcutaneous tissue were each closed with #1 catgut using a simple continuous pattern. The skin was closed with heat sterilized nonabsorbable material[1] in a continuous lock stitch pattern.

The animals were recovered from anesthesia in the surgery suite and then placed in box stalls where they were kept for 4-7 days prior to being returned to the dry lot. Post surgical treatment consisted of daily intramuscular injections of procaine penicillin[2] at the rate of 20,000 I.U. per kg of body weight per day for 4 days.

Each animal was identified at the time of purchase with a numbered eartag.[3] The animals with the yellow tags were used for the "over-the-top" procedure and are designated in the tables and text as Y followed by the identification number. The green tags identify the animals with the bone tunnel procedure and are designated by G and a number.

Post-operative clinical response was evaluated according to a subjective estimate of an animal's ability to bear weight

---

[1] Vetafil - S. Jackson Inc., Washington, D.C.

[2] Penicillin G Procaine, Med-Tech Inc., Edwood, Kansas.

[3] Allflex, Allflex Tag Co., Ltd., Santa Monica, California.

on the affected limb. These estimates were recorded as a percentage of normal. Evaluations were made at 6 to 16 day intervals throughout the observation period. An evaluation consisted of isolating each animal and observing it at a walk and a run 3 to 4 times. The animal was considered 100% sound when no lameness or abnormal gait could be detected. During this period the feed intake was increased in preparation for slaughter.

When market weight was reached, the animals were taken to a local packing plant and slaughtered in the usual manner. Both stifle joints from each animal were recovered and prepared for tensile strength testing. The tensile strength test consisted of measuring the ultimate tensile load (UTL) required to rupture the graft or the normal cranial cruciate ligament in each stifle joint. The technique and the equipment used for tensile strength testing followed that described in Part I of this thesis.

After testing for tensile strength, the lateral femoral condyles were sectioned with a bone saw and fixed in 10% buffered formalin. These specimens were then trimmed and oriented to depict the graft lying either in the bone canal or in the periosteal groove on the epicondyle. The tissues were then routinely prepared for examination by light microscopy.

Results The clinical response to surgery was considered excellent in 9 animals, fair in 2 animals and a failure in one animal. The data on animal identification, purchase weight and evaluation of clinical response are presented in Table 5. There were unusual circumstances involved with the three animals not showing an excellent response.

Animal Y-22, an aggressive young Holstein bull, escaped from his stall 2 days after surgery and fell on the operated leg. A large seroma developed under the incision but partially subsided over the following month. However, following an episode of fighting, the joint swelling returned and was accompanied by acute lameness of the affected leg. The fluid filled swelling was drained. The exudate, which was similar to joint fluid, produced no bacterial growth on culture. One week later, sepsis developed and the animal was euthanatized On post mortem, the lateral patellar ligament and the joint capsule were found to be ruptured. The graft, however, was intact, surrounded with joint capsule tissue and appeared to be vascularized.

In Y-21, the periosteal groove was misplaced too far laterally on the epicondyle, and the bone plate protruded into the bursa of the gluteobiceps tendon. This error was noticed when suturing the lateral patellar ligament. The animal was more acutely lame following surgery, and remained lame longer than the others. When examined at slaughter, the joint

Table 5. Clinical response to surgery

Animal	Purchase wt. (Kg)	Operation date	Percent of normal weight bearing on following observation dates								Overall response
			5/25	5/31	6/5	6/13	6/25	7/11	7/25	8/8	
Y-7 Holstein (S)	398	5/15	40%	60%	90%	95%	100%	100%	100%	100%	Excel
Y-20 Hereford (S)	388	5/17	50%	60%	80%	90%	90%	100%	100%	100%	Excel
Y-21 Hereford (S)	368	5/18	50%	40%	10%	25%	70%	90%	100%	100%	Fair
Y-22 Holstein (B)	431	5/22	50%	40%	60%	80%	20%	Euthanized			Poor
G-8 Hereford (B)	484	5/23	--	40%	65%	75%	85%	100%	100%	100%	Excel
G-9 Hereford (B)	386	5/24	--	40%	60%	90%	90%	100%	100%	100%	Excel
G-10 Holstein (S)	493	5/30	--	--	40%	70%	80%	90%	100%	100%	Excel
G-11 Hereford (S)	395	5/31	--	--	40%	80%	80%	100%	100%	100%	Excel
Y-23 Hereford (S)	386	6/5	--	--	--	75%	90%	95%	100%	100%	Excel
G-12 Holstein (S)	404	6/6	--	--	--	40%	80%	90%	100%	100%	Excel
Y-24 Holstein (S)	436	6/7	--	--	--	60%	60%	60%	85%	100%	Fair
G-13 Hereford	398	6/11	--	--	--	--	90%	100%	100%	100%	Excel

[a]Y prefix indicates the "over-the-top" procedure; G prefix indicates the bone tunnel procedure; S = steer; B = bull.

exhibited advance degenerative changes of the articular and periarticular structures of the femur.

Animal Y-24 fell on the operated leg during anesthetic recovery, and subsequently developed a large seroma under the incision. The seroma persisted and required drainage. The exudate resembled serum and produced no bacterial growth on culture. The animal made good progress following drainage and the joint appeared normal at slaughter.

Tensile strength results were obtained on the replacement grafts in 11 animals. One animal, Y-22, was euthanatized early in the observation period and was not tested. The tensile strength of the cranial cruciate ligament in the opposite normal stifle was tested in each animal to be used as a control. Only 2 of the 11 controls provided results, in the remaining 9, either the cortical bone of the tibia or the epiphysis of the femur failed prior to rupture of the cranial cruciate ligament. In the controls that did not provide results, the UTL for the cranial cruciate ligament was estimated by multiplying the live body weight by 1.5, as determined in Part I of this thesis.

The UTL required to rupture the replacement grafts ranged from 115 kg to 470 kg, with a mean of 213 kg. The UTL for the controls ranged from 675 kg to 942 kg with a mean of 794 kg. When the UTL of the replacement graft was calculated as a percentage of the UTL for the control in each animal, the range was from 14.9% to 52.9%, with a mean of 26.8%. These data are summarized and presented in Table 6.

Table 6. Ultimate tensile load results

Animal[a]	Slaughter wt. (Kg)	Postoperative period (days)	UTL control (Kg)	UTL replacement graft (Kg)	Replacement graft/control (%)
Y-7	548	141	822[b]	225	27.4
Y-20	513	139	735	125	17.0
Y-21	450	161	675[b]	115	17.0
G-8	628	138	942[b]	470	49.9
G-9	513	132	769[b]	115	15.0
G-10	535	131	802[b]	210	26.2
G-11	536	125	804[b]	120	14.9
Y-23	510	143	765[b]	175	22.9
G-12	517	142	775[b]	410	52.9
Y-24	550	118	825[b]	195	23.6
G-13	531	137	820	185	22.6
Mean	531	137	794	213	26.8
Range	---	---	675-942	115-470	14.9-52.9
Variance	---	---	4086.8	14316.4	174.2
Std. Dev.	---	---	63.9	119.7	13.2

[a] Y prefix indicates the "over-the-top" procedure; G prefix indicates the bone tunnel procedure.

[b] Estimated UTL (see results). The high rate of test failures in the controls is related to the epiphysis still being open in animals under 2½ years of age.

The means of the tensile strength results for each surgical procedure were calculated and compared. The replacement graft percentage of control was 30.8% for the bone tunnel procedure and 21.9% for the "over-the-top" procedure (Table 7). Statistical anslysis of the results determined that the differences in the means for the two procedures were not significant. However, the "over-the-top" procedure required less surgical time and equipment than the bone tunnel procedure and eliminated the concern for proper placement of the bone tunnel.

The post-mortem examination of the stifle joints in the 11 animals sent to slaughter included careful inspection of the joint capsule, the menisci, and all ligaments for gross signs of damage. In 10 of the 11 animals, no gross changes in the menisci, ligaments or articular surfaces were observed. The joint capsule in all animals was moderately thickened along the incision line. The surface of the lateral epicondyle where the graft was secured was covered with dense fibrous tissue in all operated stifles (Fig. 11).

One animal, Y-21, was found to have advanced diffuse degenerative arthritis and extensive bone lysis of the periarticular areas. The joint fluid in this animal was cloudy and contained fibrinous clots, however, aerobic and anaerobic bacterial cultures were negative.

Grossly the replacement grafts appeared healthy and slightly reduced in size. One exception was animal G-13 in which the graft was markedly reduced in size. The infrapatella

Table 7. Means of the two surgical procedures

Procedure	Control (Kg)	UTL of replacement graft (Kg)	Replacement graft/ control (%)
Bone Tunnel (G Series)	819	252	30.8
"Over-the-top" (Y Series)	764	167	21.9

fat pad and the intercondylar joint capsule were adhered to the graft and appeared to be providing vascularity. In all 11 animals there was evidence of early regenerative growth of the cranial cruciate ligament (Fig. 12).

There was increased joint mobility when compared to the opposite normal joint in three animals (G-11, Y-23, and Y-24). This was not, however, related to abnormal clinical findings.

The histopathological findings were characterized by the appearance of viable tendon tissue in the bone tunnels and on the surface of the epicondyles. The tendons were intimately associated with the surrounding and underlying bone with a small amount of fibroplasia extending into the ajacent Haversion canals and marrow cavities. There was no evidence of bone necrosis (Fig. 13).

Discussion There are anatomical differences between the canine and bovine stifle joints (Fig. 14). The significant

Fig. 11. Example of the necropsy findings in the operated joint (left) and the normal joint (right 139 days following surgery

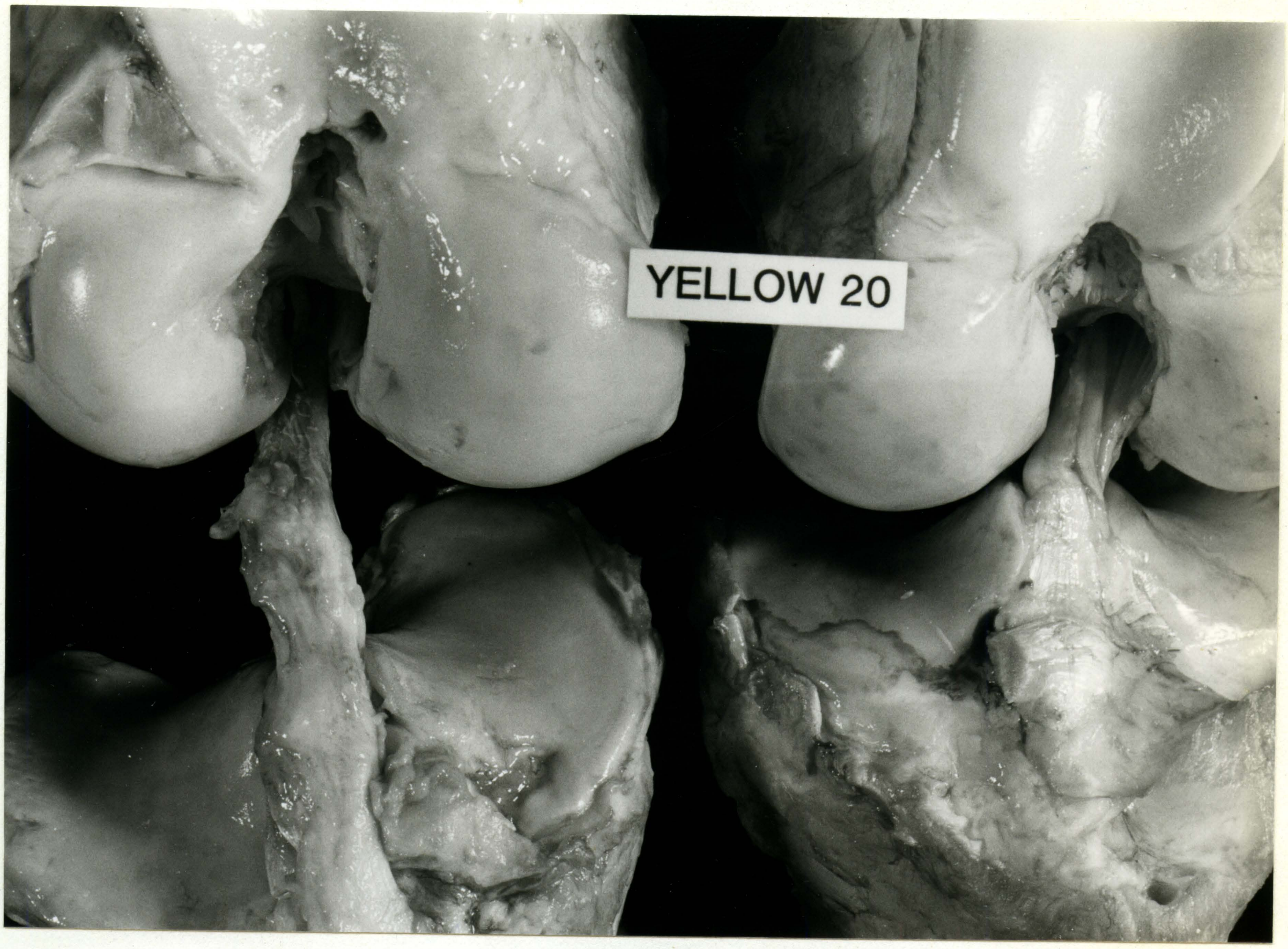
YELLOW 20

Fig. 12. Lateral view of replacement graft 132 days following surgery


GREEN 9

Fig. 13. Histological appearance of the ligament-bone interface in the drill hole (left) and on the surface of the epicondyle (right) x 2.5, (Hematoxylin and Eosin stain)

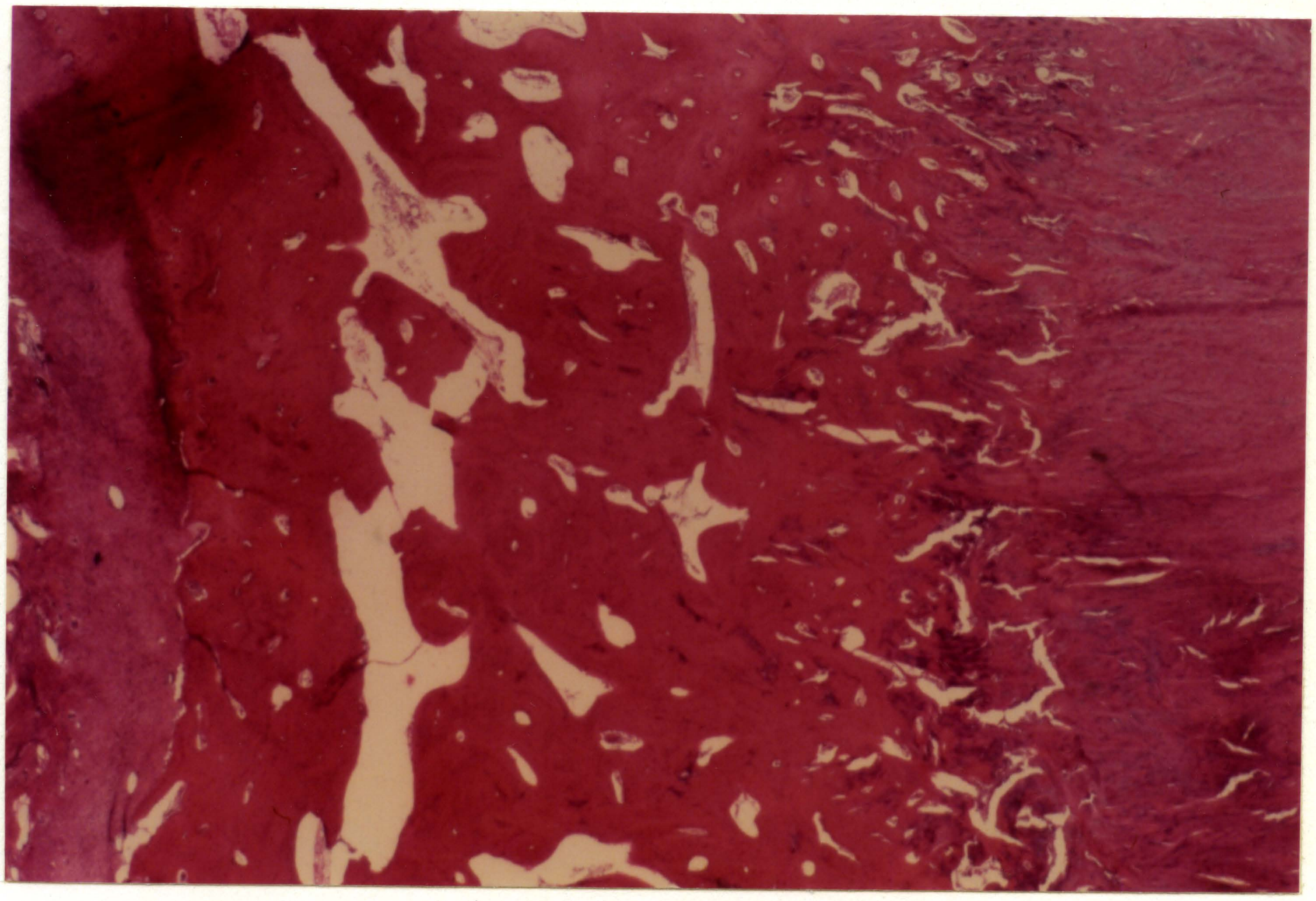

Fig. 14. Anatomy of the patellar ligaments in the bovine

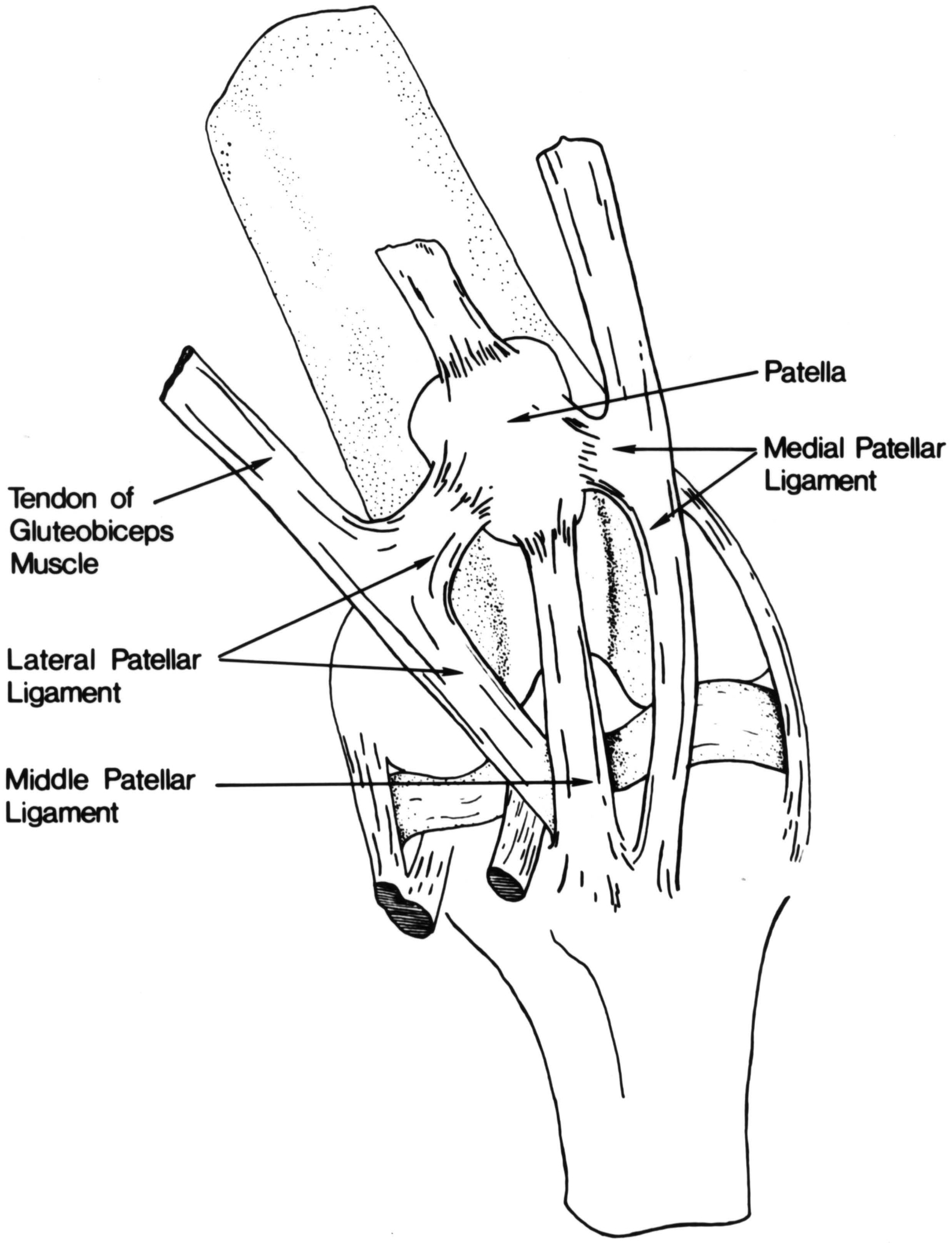
Patella
Medial Patellar Ligament
Tendon of Gluteobiceps Muscle
Lateral Patellar Ligament
Middle Patellar Ligament

differences are the bovine has three patellar ligaments and a relative deficiency of fascial tissue proximal to the patella. In two clinical cases of cranial cruciate ligament rupture in the bovine the authors attempted to prepare a patellar ligament graft in the same manner as that described for the dog (Arnoczky *et al*., 1979). Our experience was that the fascial portion of the graft was not strong enough.

Further dissections of bovine specimens suggested the use of the gluteobiceps tendon in combination with a portion of the lateral patellar ligament as a replacement graft. This graft was readily accessible and comparable in size to the cranial cruciate ligament in the bovine. The graft's tibial insertion is caudal to the middle patellar ligament which provides for excellent alignment when the graft is placed in the joint. In this study, the graft closely followed the anatomical location of the cranial cruciate ligament over the surface of the tibia.

In the bovine a lateral parapatellar approach with medial luxation of the patella, as reported in a previous study, provides excellent exposure of the surgical area (Hamilton, 1970). Since the medial trochlear ridge is more prominent than the lateral in the bovine, medial patellar luxation is not a post surgical concern.

In this study the tensile strength measurements did not correlate well with the appearance of the graft and the clinical response of the animals. Only one report on the tensile strength of cranial cruciate ligament replacement could be found in the literature (Ryan and Drompp, 1966). This study was performed on dogs. The authors did not report abnormal clinical responses but the tensile strengths of the grafts were far less than that reported for normal cranial cruciate ligaments in the dog (Alm et al., 1974b; Gupta and Brinker, 1969; Gupta et al., 1971). The results of our study and the studies performed on dogs supports the logical conclusion that the cranial cruciate ligament possesses considerable reserve strength over and above what is required for normal ambulation. However, the tensile strength results of this study lend doubt as to the capability of these animals to perform as breeding bulls at 4 to 5 months following repair.

Autogenous grafts in the joint environment progresses through the phases of necrosis and shrinking for the first two weeks followed by vascularization of the graft and progressive invasion by normal appearing fibroblasts (Rudy, 1974; Alm, 1973; Chiroff, 1975; Vaughan and Scott, 1966; Marshall et al., 1979). The new fibrous tissue then begins to organize in a linear manner. Invasion and organization progresses for the next 8-12 months and the graft begins to increase in size, eventually exceeding its original size. Organization of the invading fibrous tissue and maturation of the collagen fibers are required to increase tensile strength of the graft. These changes occur slowly and it is unlikely that the graft will reach its maximum tensile strength in less than a year. The purpose of our study was to evaluate a surgical procedure and determine the fate of the replacement graft in the short-term. Our results indicate that a long-term study should be considered.

Recent reports on the use of carbon fibers for ligament replacement suggest that carbon induces the formation of fibrous tissue by providing a matrix for proliferation (Jenkins et al., 1977; Jenkins, 1978). Multiple carbon fibers also possess ultra-high tensile strength. Based on our tensile strength results, carbon fibers might be used in conjunction with an autogenous graft to increase tissue proliferation and tensile strength thus providing support for the graft in the early convalescent period.

Conclusions In this study on male adult bovine animals our results indicate that cranial cruciate ligament replacement, using an autogenous ligament-tendon graft, can be performed without significant difficulty. These results, while indicating that excellent clinical responses can be expected in the short term, suggest that more studies are desirable in order to determine how strong the graft ultimately will become if a longer postoperative period is allowed.

The results were not conclusive in comparing the different placements of the graft. However, it is the author's opinion that the "over-the-top" procedure is simpler to perform and will likely provide more consistent results than the bone tunnel procedure.

GENERAL CONCLUSIONS

In the author's experience the highest incidence of cranial cruciate ligament rupture in the bovine occurs in mature breeding bulls, although the condition has been seen in heifers and cows. Many of these cases occur in genetically superior, valuable breeding stock and to condemn these animals to slaughter represents an enormous economic loss. It is likely that cranial cruciate ligament tears occur as a result of hyper-extension of the stifle joint as suggested by Rudy (1965), Strande (1967) and Arnoczky (1977). This would account for the higher incidence in breeding bulls where the weight is borne primarily by the hind legs, and the stifles are fully extended during the thrust motion of the breeding act.

The breeding bull, like the working dog, is of little value unless he can function, and when deciding on surgical repair of cruciate ruptures, this fact must be considered. The difference between the stresses placed on the cranial cruciate ligament in normal ambulation and heavy work, must be significant. The significance of this difference is demonstrated in this study, and in that done by Ryan and Drompp (1966) where the tensile strength of the replacement graft was far less than the tensile strength of the normal cruciate ligament. In this study, 11 of 12 animals showed no clinical lameness when observed in normal ambulation 7 to 9 weeks after surgery.

In Part I of this investigation the tensile strength of the cranial cruciate ligament was measured in the bovine, and the results subjected to statistical analysis. The ultimate tensile load required to rupture the cranial cruciate ligament in the adult bovine was approximately 1½ times the animal's live body weight. The study established that there was no difference between the left and right stifle joints of the same animal. In addition, it showed the effects of post-mortem aging on cranial cruciate ligament strength to be negligible between 2 and 18 days when the animals were killed and the carcasses cooled in the usual packing plant procedure.

The second part of the study evaluated the feasibility of adapting the patellar ligament procedure to the bovine, and compared the "over-the-top" procedure to securing the grafts in the lateral femoral condyle.

The results indicate that with the modification of using parts of the gluteobiceps tendon and lateral patellar ligament as the graft, the procedure can be performed in the bovine with relative ease. In this experiment, 9 of the 12 cases showed an excellent response with no lameness apparent after the 9th post-surgical week. A fair response was achieved in 2 of the 3 remaining cases, and one was considered a failure.

In the post-mortem evaluation, 10 of the 12 animals had little or no observable pathological changes in the joint structures. The pathological changes present in 2 animals could be attributed to avoidable errors.

The comparison of the two surgical techniques employed in the study were not conclusive. However, the "over-the-top" procedure required less time and could be performed without sophisticated surgical equipment.

The tensile strength measurements demonstrated that the replacement graft averaged only about 25% of the tensile strength of the normal cranial cruciate ligament in the opposite stifle. This was considerably less than expected in view of the clinical response. It is the author's opinion that most of these grafts would have failed if they had been exposed to the stress involved in normal breeding at this stage of recovery.

The results of these experiments provide information on tensile strength requirements for replacement of the ruptured cranial cruciate ligament in the bovine. They also demonstrate that surgical correction of the ruptured cranial cruciate can be accomplished with relative ease using an autogenous tendon-ligament graft in this species. However, the results of the tensile strength measurements pose some questions that need to be investigated before the procedure can be termed successful, such as:

1. How long a recumbance period is required for the replacement graft to achieve its ultimate tensile strength, and will that tensile strength be sufficient?

2. How accurate are the criteria of clinical response and post-mortem change when evaluating a surgical procedure for repair of cruciate rupture? The results of this study suggests the tensile strength of the replacement graft should be included in the criteria for working animals.
3. What effect will the addition of carbon fibers to the graft employed in this experiment have on promoting additional fibroplasia and increasing tensile strength?

BIBLIOGRAPHY

Alm, A. 1973. Survival of part of the patellar tendon transposed for reconstruction of the anterior cruciate ligament. Acta Chirurgica Scandinavica 139:443-447.

Alm, A. and B. Strömberg. 1974. Vascular anatomy of the patellar and cruciate ligaments. Acta Chirurgica Scandinavica Supplement 445:25-35.

Alm, A., J. Gillquist and B. Strömberg. 1974a. The medial third of the patellar ligament in reconstruction of the anterior cruciate ligament. Acta Chirurgica Scandinavica Supplement 445:5-14.

Alm, A., H. Ekström and B. Strömberg. 1974b. Tensile strength of the anterior cruciate ligament in the dog. Acta Chirurgica Scandinavica supplement 445:5-23.

Arnoczky, S. P. and J. L. Marshall. 1977. The cruciata ligaments of the canine stifle: An anatomical and functional analysis. American Journal of Veterinary Research 38:1807-1814.

Arnoczky, S. P., P. A. Torzilli and J. L. Marshall. 1977. Biomechanical evaluation of anterior cruciate ligament repair in the dog: An analysis of the instant center of motion. Journal of the American Animal Hospital Association 13:553-558.

Arnoczky, S. P., G. B. Tarvin, J. L. Marshall and B. Saltzman. 1979. The over-the-top procedure: A technique for anterior cruciate ligament substitution in the dog. Journal of the American Animal Hospital Association 15: 283-290.

Butler, H. C. 1964. Teflon as a prosthetic ligament in repair of ruptured anterior cruciate ligaments. American Journal of Veterinary Research 25:55-59.

Cameron, T. P., C. Sevy, D. Carren, L. Cooper and D. McKnown. 1968. An aid in the repair of the anterior cruciate ligament. Small Animal Clinician 63:337-340.

Carlin, I. 1926. Ruptur des ligamentum cruciatum anterius in Kneigelenk beim Hund. Arch. Wessench. prakt. Turhalk, 54:420-423.

Chastain, J. N. 1959. Surgical technique using skin for repair of simultaneously ruptured anterior cruciate and medial collateral ligaments of the canine femorotibial articulation. M.S. Thesis, Texas A&M University, Texas.

Childers, H. E. 1966. New methods for cruciate ligament repair II. Repair by suture technique. Modern Veterinary Practice 47:59-60.

Chiroff, R. T. 1975. Experimental replacement of the anterior cruciate ligament. Journal of Bone and Joint Surgery 57A: 1124-1127.

Dueland, R. 1966. A recent technique for reconstruction of the anterior cruciate ligament. Animal Hospital 2:1-5.

Emery, M. A. and O. Rostrup. 1960. Repair of the anterior cruciate ligament with 8 mm tube teflon in dogs. Canadian Journal of Surgery 4:11-14.

Gibbens, R. 1957. Patellectomy and a variation of Paatsama's operation on the anterior cruciate ligament of a dog. Journal of the American Veterinary Medical Association 131:557-558.

Gupta, B. N. and W. O. Brinker. 1969. Anterior ligament prothesis in the dog. Journal of the American Veterinary Medical Association 154:1057.

Gupta, B. N., W. O. Brinker and K. N. Subramanian. 1969. Breaking strength of cruciate ligaments in the dog. Journal of the American Veterinary Medical Association 155:1586-1588.

Gupta, B. N., K. N. Subramanian, W. O. Brinker and A. N. Gupta. 1971. Tensile strength of canine crenial cruciate ligaments. American Journal Veterinary Research 32:183-189.

Hamilton, G. F. 1970. Anterior cruciate ligament repair in the bovine stifle joint by replacement methods. Ph.D. Thesis. Colorado State University, Boulder, Colorado.

Hamilton, G. F. and O. R. Adams. 1971. Anterior cruciate ligament repair in cattle. Journal of the American Veterinary Medical Association 158:178-183.

Hey Groves, E. W. 1917. Operation for repair of the crucial ligaments. Lancet 1:674-675.

Hey Groves, E. W. 1920. The crucial ligaments of the knee joint: Their function, rupture and the operative treatment of the same. British Surgery 7:505-515.

Hofmeyr, C. F. C. 1968. Reconstruction of the ruptured anterior cruciate ligament in the stifle of a bull. The Veterinarian 5:89-92.

Hohn, R. B. and J. M. Miller. 1967. Surgical correction of rupture of the anterior cruciate ligament in the dog. Journal of the American Veterinary Medical Association 150:1133-1141.

Jenkins, D. H. R., I. W. Forster, B. McKebbin and Z. A. Ralis. 1977. Induction of tendon and ligament formation by carbon implants. Journal of Bone and Joint Surgery 59-B: 53-57.

Jenkins, D. H. R. 1978. The repair of cruciate ligaments with flexible carbon fiber. Journal of Bone and Joint Surgery 60-B:520-522.

Johnson, F. L. 1960. Use of braided nylon as a prosthetic anterior ligament of the dog. Journal of the American Veterinary Medical Association 137:646-647.

Jones, K. G. 1963. Reconstruction of the anterior cruciate ligament. A technique using the central third of the patellar ligament. Journal of Bone and Joint Surgery 45-A:925-932.

Knecht, C. D. 1976. Surgical techniques for cruciate ligament rupture. Journal of the American Animal Hospital Association 12:717-726.

Leighton, R. L. 1961. Repair of ruptured cruciate ligament with whole thickness skin. Small Animal Clinician 1:246-259.

Marshall, J. L., S. P. Arnoczky, R. M. Rubin and T. L. Wickiewicz. 1979. Microvasculature of the cruciate ligaments. The Physician and Sports Medicine 7:87-91.

McCurnin, D. M. 1970. Clinical and pathological evaluation of ruptured anterior cruciate ligament repair in the canine species. M.S. Thesis. Iowa State University, Ames, Iowa.

McCurnin, D. M., P. T. Pearson and W. M. Wass. 1971. Clinical and pathological evaluation of ruptured anterior cruciate ligament repair in the dog. American Journal of Veterinary Research 32:1517-1524.

O'Donoghue, D. H. 1963. A method for replacement of the anterior cruciate ligament of the knee. Journal of Bone and Joint Surgery 45-A:905-924.

O'Donoghue, D. H., C. A. Rockwood, G. R. Frank, S. C. Jack and R. Kenyon. 1966. Repair of the anterior cruciate ligament in dogs. Journal of Bone and Joint Surgery 48-A:503-519.

Paatsama, S. 1952. Ligament injuries in the canine stifle joint. Helsinki, Finland, Kauppakiryapaino, O.Y.

Paatsama, S. 1963. Ein weiterer Beitrag zu den Kniegelenksoperatonen beim Hund. XVII World Veterinary Congress Proceedings 17:997-999.

Pearson, P. T. 1969. The canine stifle joint. American Animal Hospital Association Proceedings 1969:379-404.

Pearson, P. T. 1971. Ligamentous and meniscal injuries of the stifle joint. Veterinary Clinics of North America 1:439-501.

Pearson, P. T., D. M. McCurnin, J. D. Carter and J. D. Hoskins. 1971. Lembert suture technique to surgically correct ruptured cruciate ligaments. Journal of the American Animal Hospital Association 7:1-13.

Pond, M. J. and J. R. Campbell. 1972. The canine stifle joint. Rupture of the anterior cruciate ligament - An assessment of conservative and surgical treatment. Journal of Small Animal Practice 13:1-10.

Rudy, R. L. 1965. Stifle joint. In Canine Surgery. 1st Archibald Ed., American Veterinary Publications, Inc., Santa Barbara, Calif.

Rudy, R. L. 1974. Stifle joint. Pp. 1104-1117 and 1142-1153 in Canine Surgery. 2nd Archibald Ed. American Veterinary Publications, Inc., Santa Barbara, Calif.

Ryan, J. R. and B. W. Drompp. 1966. Evaluation of tensile strength of reconstructions of the anterior cruciate ligament using the patellar tendon in dogs: A preliminary report. Southern Medical Journal 59:129-134.

Schroeder, E. F. and G. B. Schnelle. 1941. Veterinary radiography, the stifle joint. North American Veterinarian 22:353-360.

Singleton, W. B. 1957. The diagnosis and treatment of some stifle deformities in the dog. Veterinary Record 69:1387-1396.

Singleton, W. B. 1963. Stifle joint surgery in the dog. Canadian Veterinary Journal 4:142-150.

Singleton, W. B. 1969. Observations based upon the surgical repair of 106 cases of anterior cruciate ligament rupture. Journal of Small Animal Practice 10:269-278.

Stark. 1850. Two cases of rupture of the crucial ligaments in the knee joint. Edinb. Med. Surg. (Abstr.)

Strande, A. 1966. Replacement of the anterior cruciate ligament in the dog. Journal of Small Animal Practice 7:351-359.

Tillberg, B. 1977. The late repair of torn cruciate ligaments using menisci. Journal of Bone and Joint Surgery 59-B: 15-19.

Vaughan, L. C. 1963. A study of the replacement of the anterior cruciate ligament in the dog by fascia, skin, and nylon. Veterinary Record 75:537-541.

Vaughn, L. C. and N. L. Bowden. 1964. The use of skin for the replacement of the anterior cruciate ligament in the dog: A review of the thirty cases. Journal of Small Animal Practice 5:167-171.

Vaughan, L. C. and M. A. Scott. 1966. An experimental study of the fate of autografte of whole-thickness skin used to replace the anterior cruciate ligament. Veterinary Record 79:412-416.

Wouters, L., F. Verschooten and A. DeMoor. 1976. Rupture of the anterior cruciate ligament in the bovine. Vlaams Diergeneeskundig Tijdschrift 45:167-181. (Abstr.)

Zahm, V. H. 1966. Operative treatment of crucial ligament injuries in the dog with synthetic material. Berliner und Muenchener Tieraerztliche Wochenschrift 79:1-4.

ACKNOWLEDGEMENTS

The author wishes to thank the following people for their sincere help and encouragement, without which this project could not have been possible.

Dr. Wallace M. Wass for making time and funds available, and for his advice, guidance and many long hours spent in helping with the preparation of the manuscripts.

The members of the author's graduate committee for their encouragement and guidance.

Dr. James Thompson and Dr. Jeanne Löfstedt for relieving the patient work load in the large animal clinic.

Dr. Dennis M. McCurnin, Dr. Donald DeYoung, and Mr. Thomas H. Ferguson for their interest, advice and helpful suggestions throughout the project.

Miss Deborah Stambaugh for her excellent work in preparing the illustrations.

Finally, and most importantly, my greatest appreciation goes to my wife, Berna, and my sons, Douglas and David, for the sacrifices they so willingly made, and the encouragement they gave.

APPENDIX: ADDITIONAL RESULTS FROM PART II

Fig. 15. Example of the tracing of the UTL required to rupture the normal cranial cruciate ligament (left), and the replacement graft (right) in animal Y-7

The centimeters of deflection are converted to kg of load on the scale of 1 cm = 50 kg.

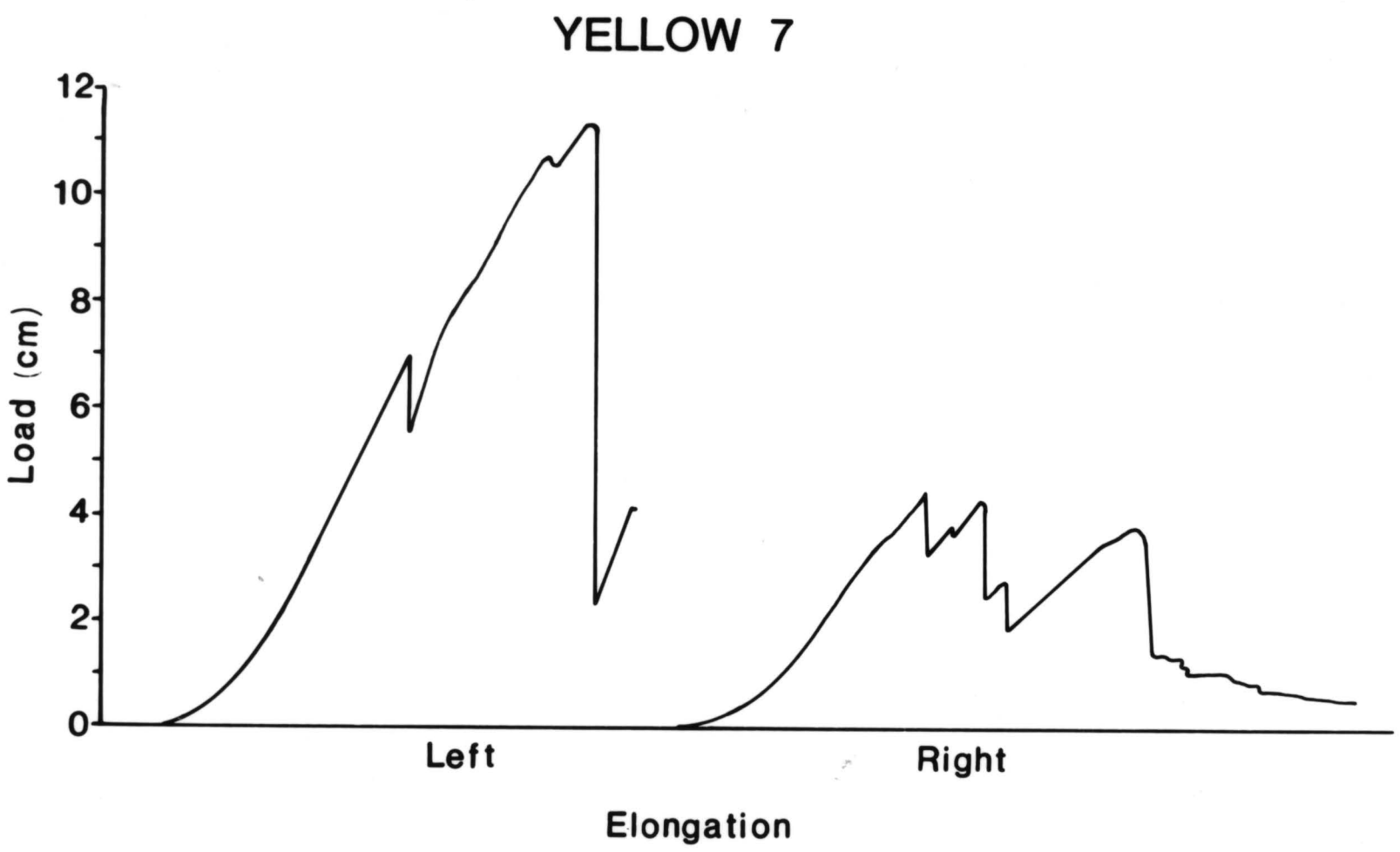
YELLOW 7
12
10
8
6
4
2
0
Load (cm)
Left
Right
Elongation

Fig. 16. Example of the tracing of the UTL measurement for animal G-8

The normal cranial cruciate ligament is labelled "left" and the replacement graft is labelled "right." The scale is 1 cm of deflection equals 50 kg of load.

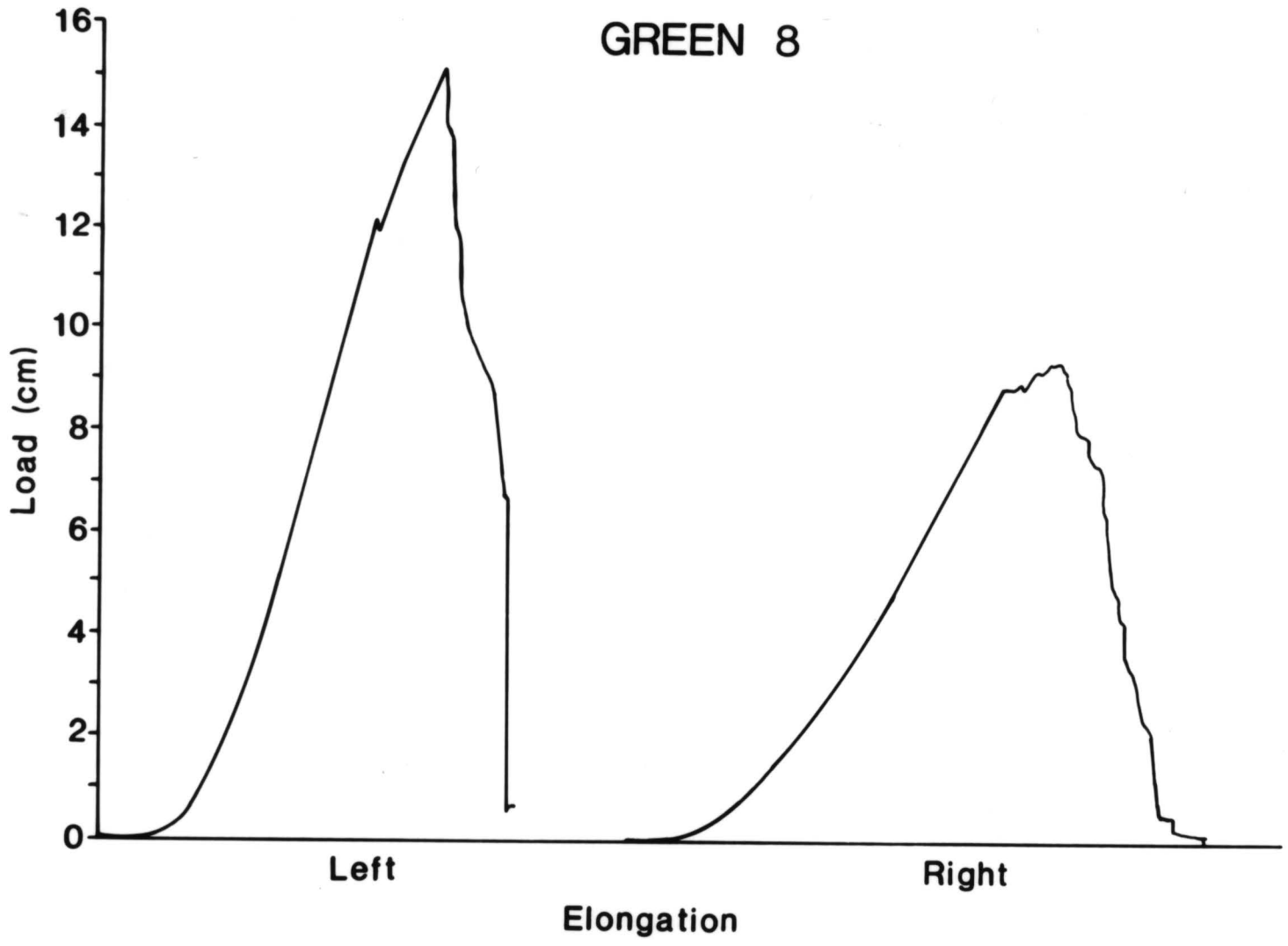
GREEN 8
Load (cm)
16
14
12
10
8
6
4
2
0
Left
Right
Elongation

Fig. 17. Necropsy findings in the operated joint (left), and the normal joint (right), of animal Y-7, cranial view, 141 days following surgery

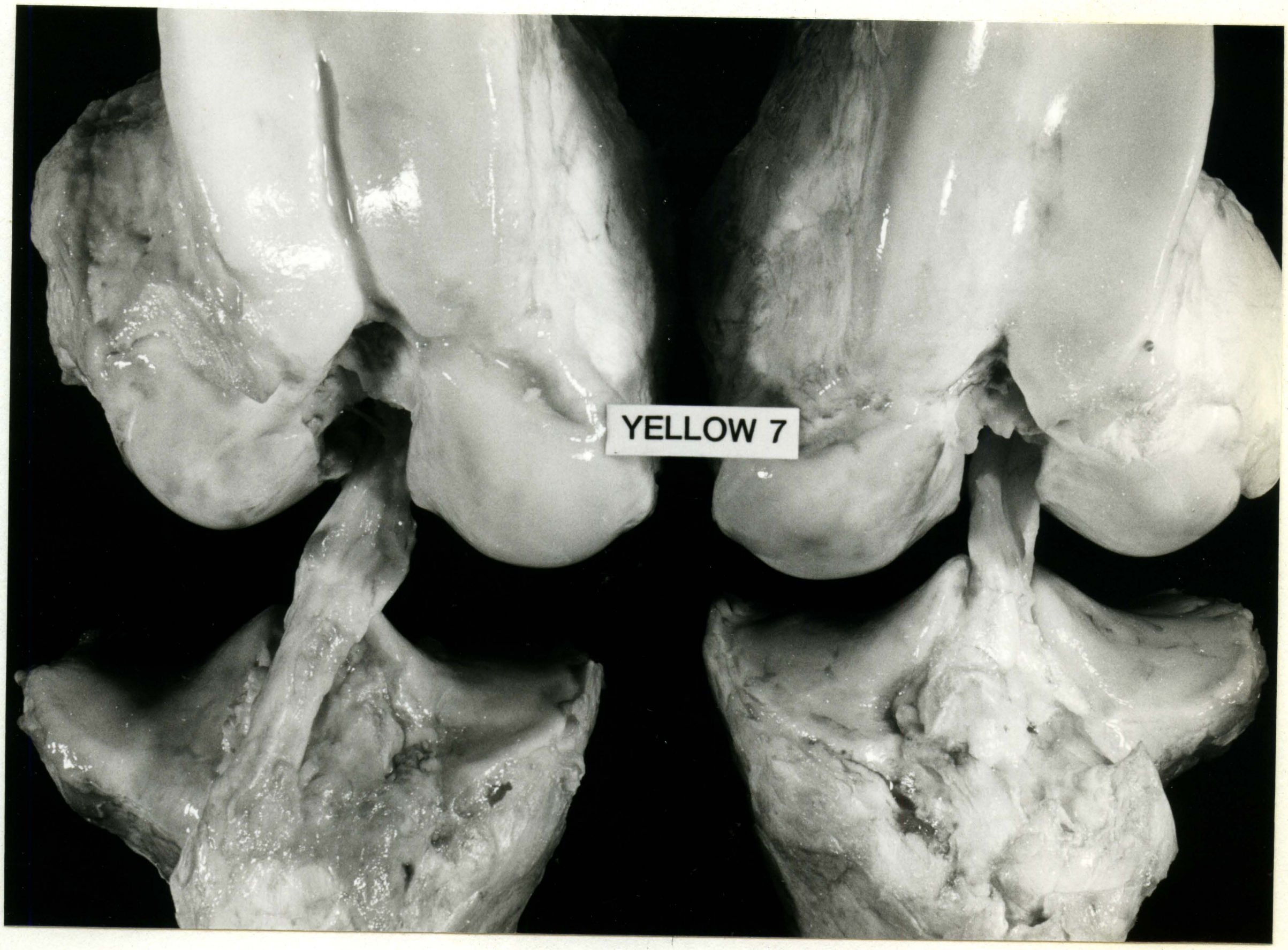
YELLOW 7

Fig. 18. Necropsy finding in the operated joint of animal Y-7, caudal view

a) location of graft over the caudal aspect of the lateral condyle of the femur.

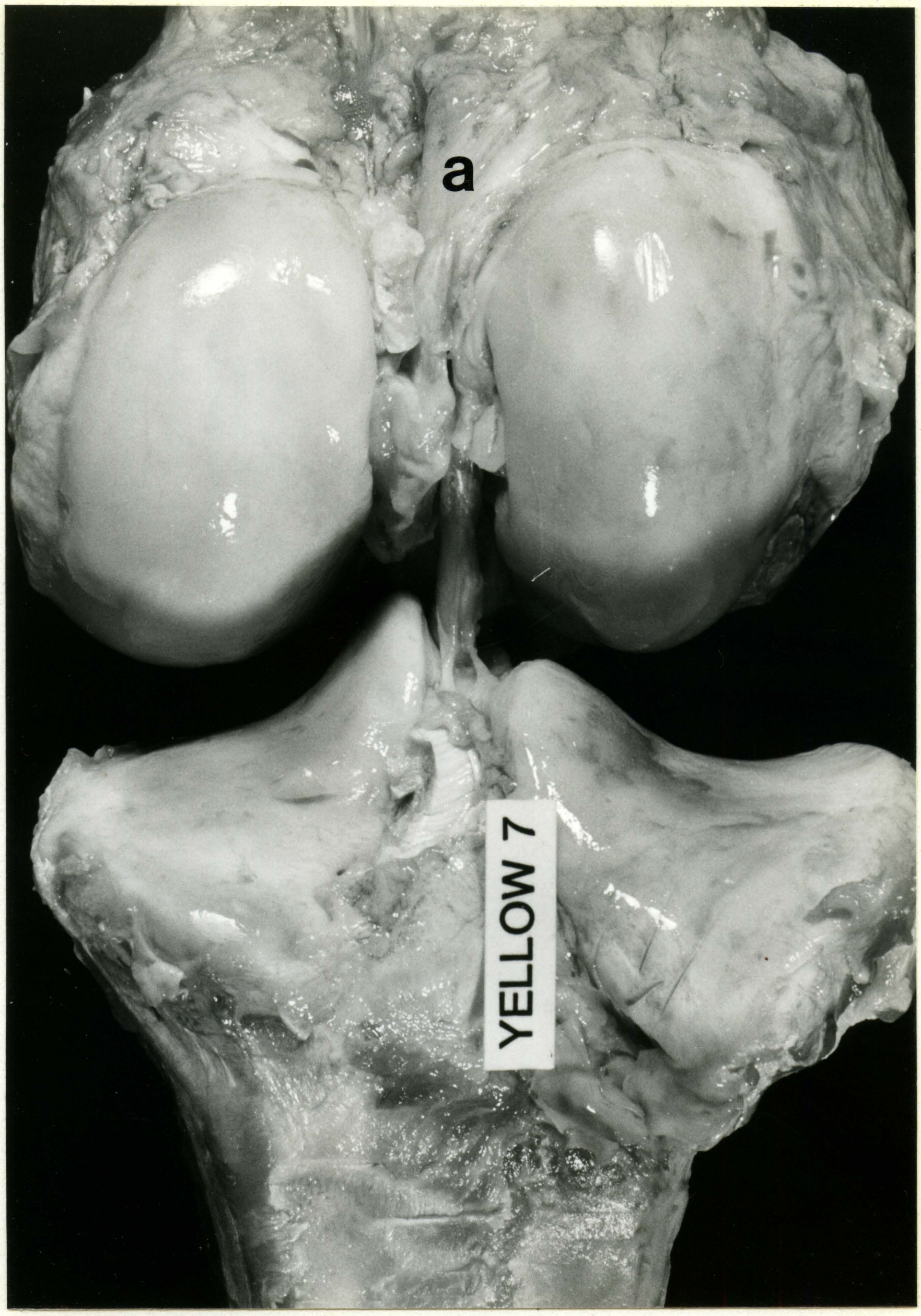
a
YELLOW 7

Fig. 19. Necropsy findings on the operated joint (left), and the normal joint (right) of animal Y-21, cranial view, 161 days following surgery

In this animal the bone plate protruded into the distal bursa of the gluteobiceps tendon. Degenerative arthritis and bone lysis of the periarticular areas, are evident in the operated joint.

YELLOW 21

Fig. 20. Necropsy findings in the operated joint (left), and the normal joint (right), of animal G-8, cranial view, 138 days following surgery


GREEN 8

Fig. 21. Necropsy findings in the operated joint of animal G-8, caudal view, 138 days following surgery

a) ligament entering bone tunnel;
b) ligament existing bone tunnel on dorsocaudal border of the lateral epicondyle of the femur.


GREEN 8
b
a

Fig. 22. Necropsy findings in the operated joint (left), and the normal joint (right), of animal G-9, cranial view, 132 days following surgery

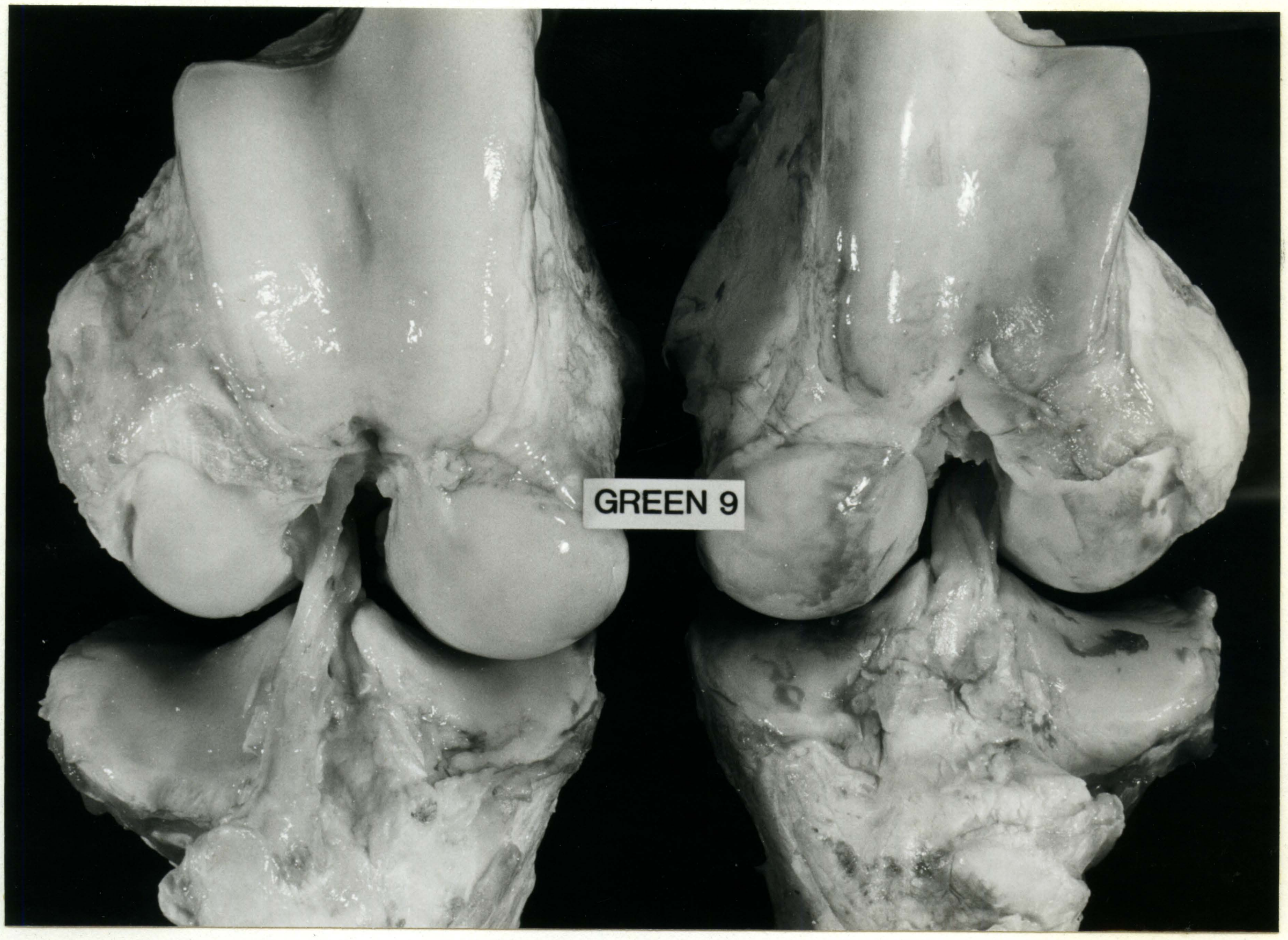
GREEN 9

Fig. 23. Necropsy findings in the operated joint of animal G-10, caudal view, 131 days following surgery

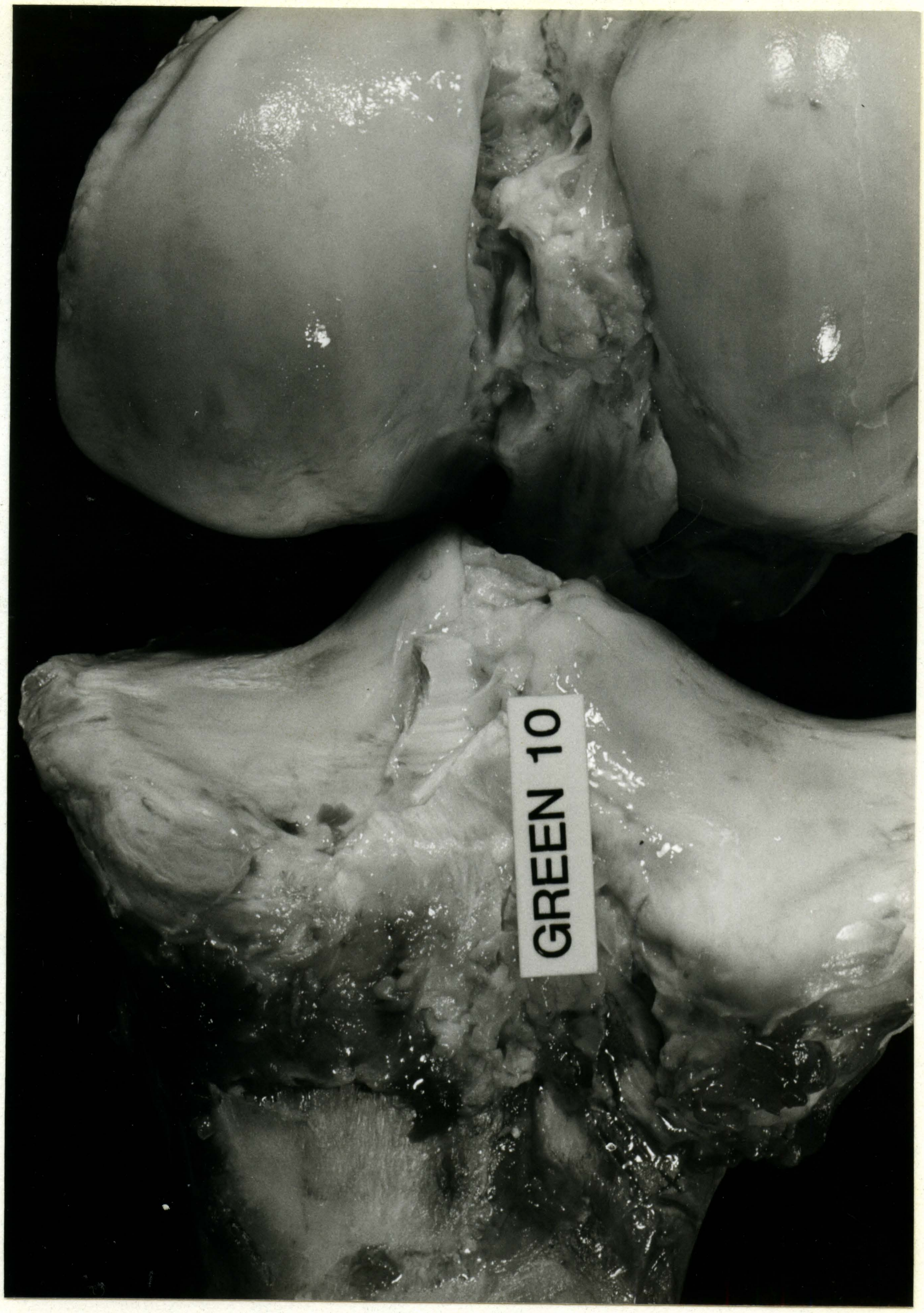
GREEN 10

Fig. 24. Necropsy findings in the operated joint (left), and the normal joint (right), of animal G-11, cranial view, 125 days following surgery


GREEN 11

Fig. 25. Necropsy findings in the operated joint of animal Y-23, caudal view, 143 days following surgery


YELLOW 23

Fig. 26. Necropsy findings in the operated joint (left), and the normal joint (right), of animal G-12, cranial view, 142 days following surgery

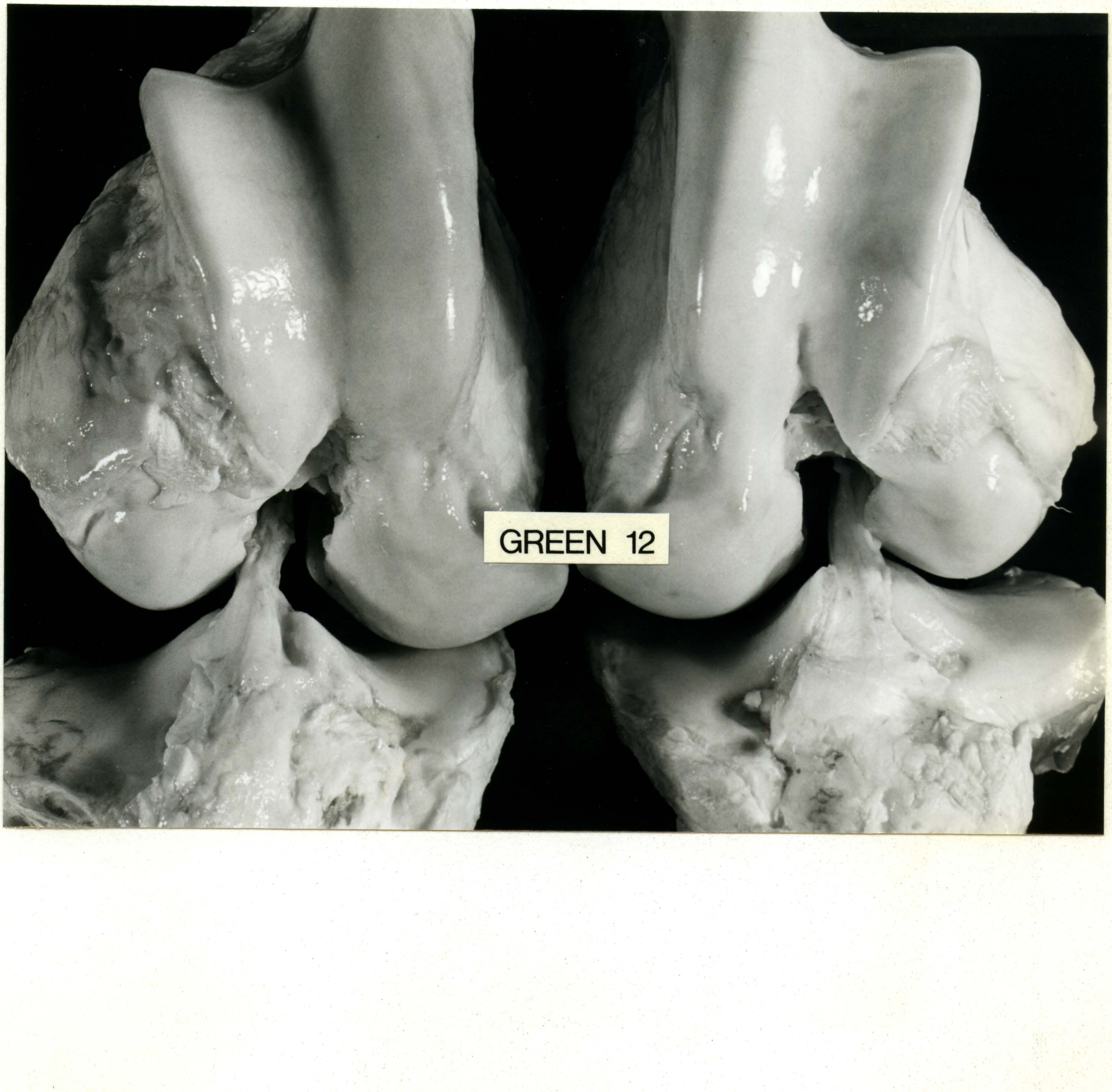
GREEN 12

Fig. 27. Necropsy findings in the operated joint (left), and the normal joint (right), of animal Y-24, 118 days following surgery

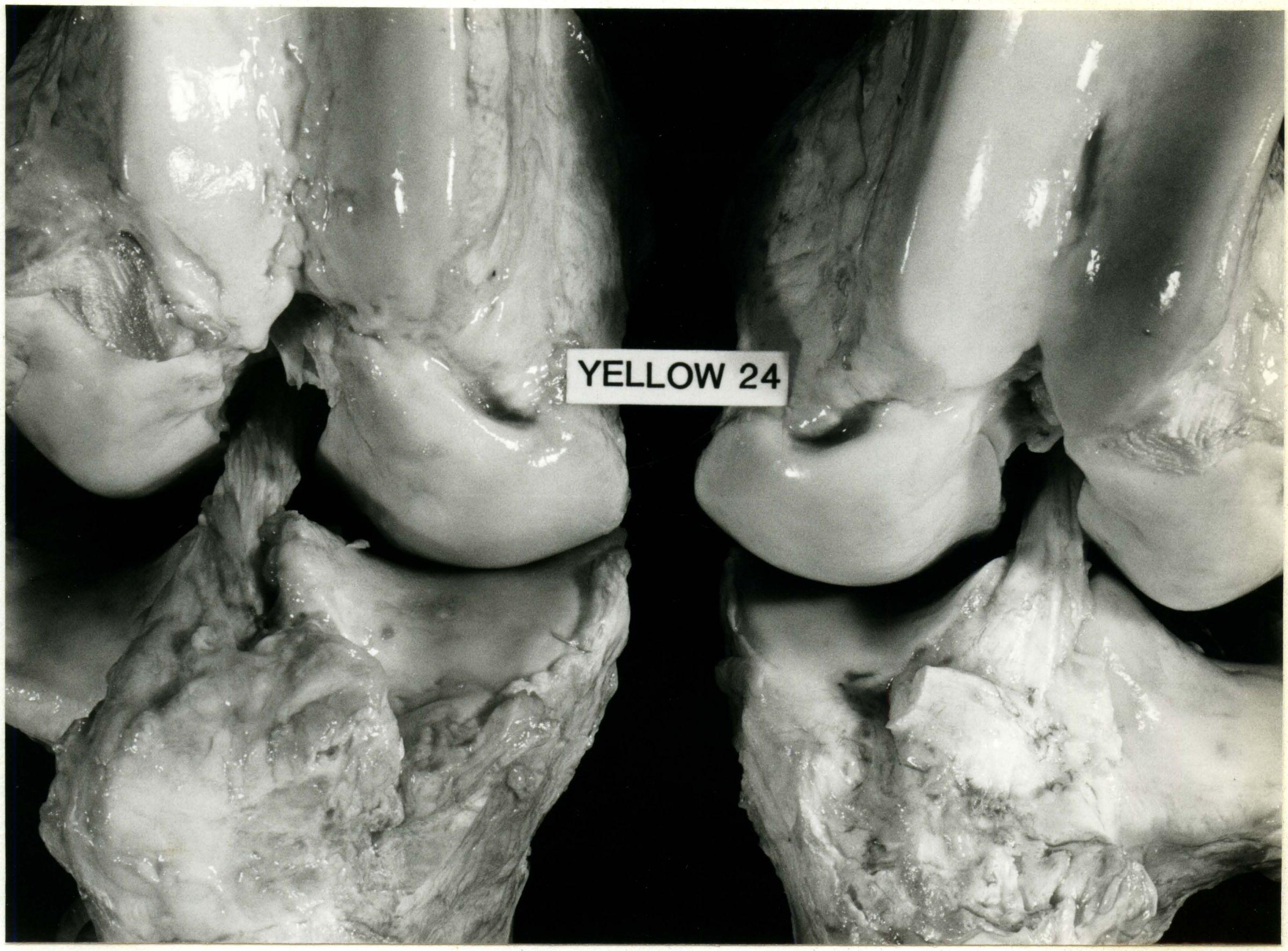
YELLOW 24

Fig. 28. Necropsy findings in the operated joint of animal G-13, caudal view, 137 days following surgery


GREEN 13