The angioarchitecture of the nasal cavity
and its functional significance
in the sheep

by

Wael Abdul Hameed Khamas

A Thesis Submitted to the
Graduate Faculty in Partial Fulfillment of the
Requirements for the Degree of
MASTER OF SCIENCE

Major: Veterinary Anatomy

Signatures have been redacted for privacy

Iowa State University
Ames, Iowa

1980

TABLE OF CONTENTS

DEDICATION

Dedicated to the soul of my father

ABDUL HAMEED KHAMAS

INTRODUCTION

Literature concerning the gross and microscopic anatomy of different animals is available, however, very few publications have dealt with the angioarchitecture of the nasal cavity of the sheep. Scott (1954) reported that the surface area of the nasal mucosa in seal may approach, if not exceed, the total surface area of the skin covering the body because of the complexity of the conchae. In sheep, pig, deer, horse, kangaroo, and new world monkey the osseous structure of the conchae is less complicated and, therefore, the surface area of the nasal mucosa is less than the surface area of the skin covering their bodies. Among the latter species, however, the ungulates showed the highest degree of vascular complexity of the nasal mucosa. Further, Naessen (1970) found that the respiratory epithelium of man and guinea pig has furrows or gutters aligned in rows, which commence abruptly at the beginning of the olfactory region. He hypothesized that the additional surface area available, when these gutters open, may enhance the heat transfer capacity of the nasal mucous membrane. On the other hand, cyclic respiratory changes in the nasal mucosa and its vasculature of man were investigated by Stoksted (1952) and Principato and Ozenberger (1970), while Moller and Fahrenkrug (1971) described the presence of swell bodies in the nasal cavity of the rat and rabbit and related them to the normal cyclic changes associated with air conductivity.

Vascularity of the nasal mucous membrane has been studied in different animals. Dawes and Prichard (1953) described the latticework arteries in the pig, goat, and sheep, which run closely together obliquely and horizontally in the nasal septum in the dorsal concha. Swindle (1937) observed that the blood vessels of the nasal cavity of the rabbit, dog, sheep, and deer are arranged in superficial, middle, and deep layers and described their relationship to the surface epithelium. Batson (1954) studied the venous network of the human nasal mucosa and indicated some of its clinical significance.

Menschik and Dovi (1965), Nawar et al. (1975), and Taher (1976) described the intraarterial bolster of the nasal vessels in different animals and implicated them to the regulation of the blood flow. Further, Dawes and Prichard (1953) reported on the significance of the arterio-venous anastomoses (AVA) in the nasal mucosa of the dog, especially of the ventral concha. Here the mucosa is in direct contact with the inspired air, thereby affecting greatly the circulation in the area.

The absence of the internal carotid artery in sheep was reported by Balankura (1954) and McGrath (1977). Because of the caudal direction of the blood flow in the basilar artery in the sheep and ox (Baldwin, 1964), the main blood supply to the brain is derived from the external carotid via branches off the maxillary artery (Daniel et al., 1953; Baldwin, 1964). These branches arborize into a network of small arteries forming the carotid rete or rete mirabile epidurale rostrale (International Committee on Veterinary Anatomical Nomenclature, 1973). In sheep the rete mirabile epidurale caudale is, however, absent (Baldwin, 1964). The carotid rete is bathed in a meshowrk of veins called the cavernous sinus, which is present in all domestic animals (Gillilian, 1974). In view of this close relationship between the arteries of the carotid rete and the venous meshwork of the cavernous sinus, countercurrent heat exchange between these vessels takes place. This was reported to be true in dog (Magilton and Swift, 1968) and in sheep (Baker, 1979). Further, Baldwin (1964) suggested that the carotid rete plays an important role in hyperthermia of the sheep and ox due to its close relationship with the cavernous sinus at the base of the brain. Moreover, Robertshaw (1976) reported that in the ruminants the blood from the nose and part of the mouth drains into several intracranial dural sinuses, including the cavernous sinus, which bathes the carotid rete. Taylor (1966) reported that the horn of the goat may play a role in cooling the brain via the connection of the horn veins with the cavernous sinus. Connection of the veins draining the nasal cavity with the cavernous sinus in dog via the angularis oculi and ophthalmic veins were first demonstrated by Magilton and Swift (1969). Further, injection of latex via the nasal veins of the sheep revealed filling of the cavernous sinus of the same side, indicating a venous drainage system of the nose similar to the dog (Baker, 1979).

The efficiency of the heat exchange mechanism on the surface of the nasal mucosa is directly related to its vascularity as well as availability of moisture in that area. Blood vessels in the nasal cavity were shown to be controlled by the autonomic nervous system (Ritter, 1970), especially by the a-adrenergic receptors in the dog (Hall and Jackson, 1968). This activity can be controlled centrally or locally leading to either dilatation or constriction of the nasal vessels, thereby increasing or decreasing the evaporative surface area of the nasal cavity, respectively.

Availability of moisture largly depends on the lateral nasal glands, which was reported to be present in the dog, cat, pig, sheep, goat, and small antelopes (Nickel et al., 1960), and in man (Moller, 1965). Moreover, electron microscopic study by Cauna and Hinderer (1969) and Cauna (1970a) showed that the subepithelial and periglandular capillaries of the nasal vascular bed in man are fenestrated and, therefore, by their permeability assist to keep the nasal mucosa moist. In addition, Cauna and Cauna (1975) described the subendothelial cushions in the veins of the nasal mucosa of man, which may aid in regulating the blood flow in the nasal mucosa. They also reported that the subendothelial cushion cells contain vesicles, which may play a role in keeping the nasal mucosa moist by virtue of their secretory and absorptive abilities.

Recent investigations have demonstrated that the nasal vasculature of the sheep and other mammals plays a significant role in thermal regulation and humidification of the inspired air. Caputa et al. (1976a) showed that the vasodilatation and vasoconstriction of the nasal mucosa in rabbit results in decrease and increase of brain temperature, respectively. Further, hypothalamic temperature in sheep is cooler than the body temperature under normal physiologic conditions (Hemingway et al., 1966). In addition, Ralston and Kerr (1945) reported a decrease or increase of nasal temperature of man, after general chilling or warming of the body, showing the direct relationship between body temperature and the nasal temperature. Dixon et al. (1949) demonstrated that the nose temperature is constantly about 1.2°C higher than normal in tracheostomized patients due to the absence of the inspired air, which indicates that the nose is the site for heat exchange. Besides, Cole (1954) demonstrated that the temperature of the inspiratory airstream in man is higher in the oropharynx (after a voluntary constriction of the anterior nares) than the ambient airstream, which indicates that the air absorbs heat from the nasal mucosa. Moreover, Baker and Hayward (1968b) showed that blowing cool air, at a rate of 50 times per minute for 5 minutes, into the nostrils of the sheep resulted in a decrease in temperature of 2°C in the venous blood inside the cavernous sinus of the same side.

The sheep survive both hot and cold climate in spite of its woolly thick coat. Scott (1954) reported that in animals with hair, wool, or feathers the skin surface is not very efficient for heat exchange as compared to man and, therefore, these animals developed a compensatory mechanism to lose heat from the body; for instance, ears in rabbit or ox (Ingram and Whittow, 1962) and panting mechanism in ungulates (Robertshaw, 1976) serve the same function. In the dog and other panting animals the respiratory rate is dependent upon both ambient and hypothalamic temperatures (Hellstrom and Hammel, 1967). The manner of breathing in different species was also found to be true for some animals, according to Schmidt-Nielson et al. (1970), who also demonstrated in the dog that inspiratory air enters through the nose and expiratory air leaves through the mouth. Further, Negus (1958) cited that most animals pant with their mouths closed because of the position of the epiglottis above the soft palate preventing mouth breathing. True mouth breathing, however, is possible only in man and apes, where the larynx opens into the oropharynx instead of the nasopharynx.

Caputa and Cabanac (1978) stated that in hypothermia in man, the venous blood in the angularis oculi vein flows from the brain toward the face, while in hyperthermia the blood flows rapidly in the opposite direction. Many investigators demonstrated that the blood vessels of the nasal cavity of the sheep play an important role in the regulation of brain temperature, but none have yet described conclusively the venous pathway of the nasal cavity and its connection with the cavernous sinus at the base of the brain.

The objectives of this experiment were: 1) to describe the normal blood supply of the nasal cavity of the sheep and sites of arteriovenous anastomoses; 2) to depict the relationship between the arteries and veins on the surface epithelium; 3) to describe structures of these vessels, especially thickness of the smooth muscle layers, elastic fibers, collagen fibers, and approximate location of the valves, if any, in these vessels; 4) to correlate the thickness of the tunica media and the number of smooth muscle layers to the luminal diameter of the arteries in three different regions of the nasal cavity; and 5) to evaluate the current literature in view of these findings and to relate them to brain temperature regulation.

REVIEW OF LITERATURE

The nasal cavity of animals has been studied extensively because of its complexity and vascularity. Scott (1954) studied the nasal mucous membrane of different animals and stated that in seal the surface area of the nasal mucosa may approach, if not exceed, the total surface area of the skin covering the body due to the complexity of the conchae. In sheep, pig, deer, horse, kangaroo, lemur, and new world monkey, the conchae are, however, less complicated in their osseous structures. Naessen (1970) was able to recognize many furrows or gutters which are aligned in rows. These gutters commence abruptly at the olfactory region and lead away from it. He considered the gutters as a mucosal reserve of ciliated surface area which could be brought into play in case of inflammatory conditions of the nasal mucosa. Further, he hypothesized that the additional surface available, when these gutters open, may enhance the heat transfer capacity of the nasal mucous membrane. Arterial supply to the nasal cavity of the sheep and goat were described by Schnorr and Hegner (1967). In addition, they studied both gross and microscopic structures of the venous plexuses and the arteriovenous anastomoses (AVA).

Dawes and Prichard (1953) studies the vascularity of the nasal muocsa of dog, cat, rabbit, goat, sheep, and pig and described the great size and the large number of veins as compared to arteries. They also showed that the nasal muocsa is more vascular in the areas where it is exposed to airstream. Moreover, Scott (1954) stated that the ungulates showed the highest degree of vascular complexity among different animal species (viz., deer, horse, sheep, kangaroo, lemur, and new world monkey). May (1967) described that the normal arterial supply of the head and neck of the sheep and ox has a great complexity of anastomoses, but this probably remains nonfunctional unless some pressure barriers exist within the system. Further, Swindle (1937) described the principal vascular networks of the nasal cavity (except the general capillary network) representing three layers, viz., superficial arterial layer extending through the greater part of the nasal cavity; it is divided into greater and lesser superficial layers and are connected by simple anastomoses. The middle venous layer, supplying its greater part; it is also divided into greater and lesser middle layers. The deep layer is nonfunctional and remains collapsed in rabbit and dog, while in sheep and deer it is patent throughout life. Hegner (1962) found that all the veins of the head in the dog have valves and reported that the sphenopalatine vein at first joins the deep facial and the infraorbital vein and then it joins the ventral external ophthalmic vein to drain into the cavernous sinus. Further, Dawes and Prichard (1953) mentioned the presence of valves in veins at the nasal tip of the dog but not in the veins of the nasal mucosa rostral to the middle nasal concha. Gillilian and Markesbery (1963) showed that the venous plexus of the cat is connected with all the deep and superficial veins of the face as well as with the dural sinuses intracranially. Moreover, Nawar et al. (1975) described two types of muscular arteries, thin-walled and thick-walled, in the nasal cavity of Egyptian buffalo.

Detailed study of the minute ramifications of the nasal blood vessels cannot be made by routine dissection, but with the help of corrosion casts. Batson (1954) revealed the absence of valves in the veins of the human head and neck, with a few exceptions. He further stated that the mucous membrane of the nasal cavity is pervaded throughout by interlacing venous networks and these veins are valveless. They communicate extensively with each other and the thickness of the venous network parallels the thickness of the epithelium.

The absence of the extracranial portion of the internal carotid artery in adult sheep was reported by Balankura (1954), Getty (1975), and McGrath (1977). Within a few weeks after birth the extracranial portion of the internal carotid artery is obliterated and the intracranial portion arborizes into a network of small arteries, forming the carotid rete or rete mirabile epidurale rostrale (International Committee on Veterinary Anatomical Nomenclature, 1973). Baldwin (1964) and Getty (1975) reported that the rete mirabile epidurale caudale is absent in sheep. In addition, De Boissezon (1941) described the intracranial rete of the sheep, which cannot be considered as capillaries owing to their structural similarity with the arterioles. He hypothesized, further, that the function of this rete is only mechanical for regulation of cerebral circulation. In both ox and sheep blood flows from rostral to caudal direction in the basilar artery (Baldwin, 1964). The main source of the blood supply to the brain of the sheep, is from the external carotid via branches from the maxillary artery (Daniel et al., 1953; Anderson and Jewell, 1956; Baldwin, 1964). Gillilian (1974) described the blood supply of the cranial region of ungulates with and without carotid rete and he reported that in all cases the arterial carotid rete was found to be enmeshed in a very large venous plexus (i.e., the cavernous sinus). He postulated that the position of the arterial rete in the cavernous sinus is coincidental due to the presence of the cavernous sinus in all mammals. Daniel et al. (1953) described a vessel as the ascending pharyngeal off the occipital artery, which Baldwin (1964) considered as a misnomer for the internal carotid artery because the former authors were only able to demonstrate this vessel in the near term fetus. In Thompson's gazelle, Taylor and Lyman (1972) also reported the absence of the internal carotid artery and the presence of the carotid rete, which lies in the cavernous sinus. Further, Baldwin (1964) showed that the arteries composing the carotid rete are invested by an endothelial layer, which forms the lining of the venous sinus. In both ox and sheep he stated that all the blood destined for the brain at first passes through the well-developed intracranial rete, which is located in the cavernous sinus.

Baker and Hayward (1968b) demonstrated a connection between the nasal veins and the cavernous sinus of the sheep via the lateral nasal, the dorsal nasal, and the angularis oculi veins. They injected latex ventrally into the angularis oculi vein, which entered the nasal cavity through the lateral and dorsal nasal veins and filled the superficial venous plexus of the nasal mucosa of the same side over the ventral concha, the median septum, the lateral wall and portion of the middle concha. Moreover, Hegedus and Shackelford (1965) studied the veins of the cranial cavity of the dog, horse, rabbit, ox, and sheep and reported the presence of anastomoses between the orbital and the deep facial veins. The venous blood from the nasal and part of the oral regions drain, either directly or indirectly, into several intracranial dural sinuses. including the cavernous sinus, in ruminants via the connection of the deep facial, angularis oculi, and external ethmoidal veins (Robertshaw, 1976).

Some recent researchers have suggested that the cooled blood draining the nasal cavity plays an important role in brain temperature regulation. Baker et al. (1974) found that there was an immediate rise in cerebral arterial blood temperature when the dogs were placed on bypass breathing, which is due to the absence of airstream in the nasal cavity. The previous situation was possible due to the anatomic connection between the venous network and the cavernous sinus, via the angularis oculi and the ophthalmic veins (Magilton and Swift, 1968). This may be true in sheep as Baker (1979) demonstrated a connection between the nasal venous network and the cavernous sinus after a latex injection via the nasal veins. She further reported that, with the increased blood flow through the nasal mucosa, the temperature of the nasal mucosa rose, while the temperature of the nasal mucosa fell with decreased blood flow. Also, vasodilatation and vasoconstriction in the nasal mucosa of the rabbit resulted in a decrease and increase of the brain temperature, respectively (Caputa et al., 1976b). Further, Taylor and Lyman (1972) mentioned that the cool venous drainage from the wall of the nasal passages is connected to the cavernous sinus in Thompson's gazelle.

Prichard and Daniel (1953) described the arteriovenous anastomoses (AVA) in the tongue of the dog and they (1959) described the distribution and morphology of AVA in human external ear, while Daniel and Prichard

(1956) reported their presence in the external ears of sheep, goat, and pig. In addition, Spence et al. (1972) reported the presence of AVA in the skin and paw in the pelvic limb of the dog, while Anggard (1974) found that AVA in the cat nose usually near the nasal gland and frequently in the deeper section of the nasal mucosa. Sherman (1963) described the morphology, distribution, and possible function of the AVA in general and reported that AVA were in extreme contraction shortly after death and for that reason they may be easily overlooked. Gillilian and Markesbery (1963) demonstrated the presence of AVA in the retroorbital region between the carotid rete and the cavernous sinus in the cat, rat, guinea pig, rabbit, dog, and to a lesser extent in monkey. No such anastomoses were, however, seen in sheep, ox, horse, and pig (Gillilian, 1974). Besides, Cauna (1970b) reported that the venous limbs in the AVA in human nose are devoid of smooth muscles.

The intraarterial bolsters in different mammals were described by Menschik and Dovi (1965), Moffat (1969), Nawar et al. (1975), and Taher (1976). They reported the presence of the bolsters in most cases at the branching site of the arteries and opposite to the blood flow, indicating that they act as sphincters to regulate the blood flow. These bolsters are composed of smooth muscle, which can be controlled by the autonomic nervous system. The nasal mucosa of the sheep is controlled by autonomic nervous system like the skin (Ritter, 1970), but only a-adrenergic receptors were reported in the nose of the dog (Hall and Jackson, 1968) while the b-adrenergic receptors were absent. So the control of the blood flow could be either by increasing vasomotor tone through the a-adrenergic receptors via the cranial cervical ganglia or by decreasing the parasympathethc activity, which will result in vasoconstriction and decreased blood flow. The opposite could be possible to induse vasodilatation and result in increased blood flow. Further, Magilton and Swift (1976) showed that the dorsal nasal, angularis oculi, and facial veins possess a circular layer of smooth muscle which provides a mechanism to control the blood flow in that area. In general, smooth muscles are innervated by autonomic nerves, and therefore, this mechanism of blood flow could also be controlled by this system.

Moisture is needed for evaporative cooling in the nose and it comes mainly from the lateral nasal glands which were described in the dog, cat, pig, sheep, goat, and small antelopes (Nickel et al., 1960). Blatt et al. (1972) found that the lateral nasal glands are the main source of water in panting dogs and demonstrated a change in rate of secretion as the air temperature changed. Further, Scott (1954) described many mucous secreting glands in the nasal mucous membrane of man, which by their activity keep its surface moist. The general organization of the blood capillary in muscles was described by Bruns and Palade (1968). They mentioned three layers in the wall of the blood capillary and postulated that the adventitia of the capillary wall cannot play an important role in capillary permeability because of its discontinuity. Further, by electron microscopic study, Cauna and Cauna (1975) demonstrated the subendothelial cushions in the veins of the nasal mucosa of man, in which the tunica media consists of 4-6 layers of smooth muscle alternating with distinct layers of collagen fibers. Elastic fibers were scarce in the tunica media and tunica adventitia. They also described vesicles or vacuoles accumulation in the cushion cells of the vein (subendothelial cushion cells), which are in fact epithelioid cells with processes and are not present in the regular smooth muscle cells of the tunica media. On the other hand, Cauna and Hinderer (1969) and Cauna (1970a) reported that the subendothelial and periglandular capillaries of the nasal vascular bed of man are fenestrated, while those of the deeper region (i.e. the perichondrial and periosteal) are not. Both types of the nasal capillaries possess porous basement membranes, while venules, arterioles, and the cavernous sinus have continuous endothelial linings without fenestrations.

Toppozada and Gaafer (1974) reported that the epithelial as well as the serous secreting cells in the propria of the respiratory nasal mucosa are active and proliferative in tracheostomized patients. Further, they (1976) mentioned a variation from the normal when the ventral nasal conchae of tracheostomized humans were examined by electron microscope. These variations were proliferations of capillaries, venous congestion, and arteriolar contraction and most of the arterioles and arteries were found in a contracted condition with the endothelial cell nuclei bulging into the lumen. In addition, Dixon et al. (1949) showed that the nose temperature is constantly higher by 1.2°C than normal in tracheostomized patients in the absence of the inspired air and most of the arterioles were found in a contracted state, reducing blood flow resulting in a decrease in mucosal temperature. On the other hand, Moller (1965) described the compound tubuloalveolar glands of the mixed type in the lamina propria of the respiratory region of man, in which the mucous acini predominate. The glands were particularly abundant on the medial surface of the concha. Katz and Merzel (1977) studied the various glands of the nasal septal mucosa of the rat, which were rich with mucous secretory structures, such as goblet cells, intraepithelial glands, PAS positive acinous glands, and Bowman's glands.

Cyclic breathing at a certain time interval in man was reported by Stoksted (1952) and Principato and Ozenberger (1970). Moller and Fahrenkrug (1971) showed that the distension of the swell bodies in rats and rabbits exhibit a cyclic alternation between the two halves of the nasal cavity. They stated that the total conductivity is independent of the cyclic changes in respiration of the animals. The cyclic alternation in nasal mucosa of the sheep was reported by Ritter (1970). He stated that it ceases if the nose is blocked by hypertrophied adenoids, or after tracheostomy.

To substantiate the hypothesis that the nasal mucous membrane plays a role in brain temperature regulation, Cole (1954) showed that the upper respiratory mucosa has a thermoregulatory function in man, which is similar to the skin, and is much more effective in animals with complicated conchae. Cabanac and Caputa (1979) mentioned that the skin near the angularis oculi vein was significantly lowered during facial firing, thus affecting the cavernous sinus and the brain temperature. They also compared that to arm firing and its effect on the body core temperature. Further, increase in respiratory frequency or increase in the skin temperature of the ear of the ox by using infrared irradiation under certain conditions resulted in detectable cooling of blood in the external jugular vein (Ingram and Whittow, 1962). They also demonstrated that an increase in the skin temperature of the ears and forelimbs is not related to a change in the temperature of the blood in the bicarotid trunk. Young et al. (1976) stated that mechanical blockage of the nostrils caused an increase in hypothalamic temperature and unblocking the nostrils caused a decrease in hypothalamic temperature of the sheep. Moreover, under normal physiologic conditions the hypothalamic temperature in sheep is cooler than the body temperature (Hemingway et al., 1966) and panting in ruminants is dependent on both hypothalamic and ambient temperatures (Hellstrom and Hammel, 1967). Moreover, Caputa et al. (1976b) described a decrease in brain temperature or in arterial blood temperature in rabbit due to vasodilatation of the nasal mucosa or the external ear. The same event could occur in sheep because sheep can reduce brain temperature rapidly by panting in a hot environment, while the rest of the body core temperature is more slowly reduced (Baker, 1979). Panting, in general, accelerates airflow through the nasal passages and thereby enhances the rate of heat exchange from the circulating blood to the inspired air on the surface of the nasal mucosa. All ruminants pant on heat exposure with their mouths closed (Robertshaw, 1976). In addition, panting in sheep can occur in spite of the blood temperature supplying the brain and the deep body organs remaining constant (Bligh, 1959).

Some researchers hypothesized that the oral cavity might be a site for heat exchange in animals which pant with their mouths open, but Kluger and D'Alecy (1975) stated that the nasal passages offer a greater area for cooling venous blood than the oral area due to its complexity, vascularity, and the moisture. Moreover, Baker (1972) reported that cooling of cerebral arterial blood increased as the rate of panting increased in cats subjected to a hot environment. Negus (1958) cited an increase of air temperature in the nasopharynx region in man as compared to ambient temperature, which indicated that the nasal mucosa is responsible for the change in air temperature. Further, Bligh (1957) supported the previous finding when he stated that the temperature of the blood passing through the lungs was constant in the calf. The lung is, therefore, excluded as a possible site for heat loss from the arterial blood.

In support of the hypothesis that the nasal mucous membrane plays a role in brain temperature regulation, Magilton and Swift (1968) described two physiological heat exchange systems for the control of the brain temperature of the dog. The "external system" comprises the venous lakes in the alar fold region of the ventral nasal concha which lie in close proximity to the ambient air, while the "internal system" is the relationship between the carotid rete (the major supply to the brain) and the cavernous sinus, which drains blood from the nasal area. Kluger and D'Alecy (1975) showed that the upper respiratory passages cool the brain even in the species which have no carotid rete as the rabbit. They hypothesized that the venous blood draining the nasal cavity, cooled by evaporation and convection, has two possible mechanisms for the cooling of the brain, countercurrent heat exchange between the carotid rete and the veins in the cavernous sinus and by conduction from the cavernous and ventral petrosal sinuses to the brain. They also hypothesized that the variability of hypothalamic temperature in the normal animal might be related to the variation in breathing pattern. Schmidt-Nielsen et al. (1970) demonstrated that in the panting dog, most of the inspired air enters through the nose and leaves through the mouth. Further, Magilton and Swift (1969) found that hot and cold water irrigation of the alar fold in the dog was directly reflected in the temperature of the angularis oculi and the facial veins. Carithers and Seagrave (1976) irrigated the nasal alar fold of the dog having body core temperature elevated to 42°C. At this elevation, a difference of 0.5-1.0°C between brain temperature and body core temperature was maintained for up to 1.5 hours. Baker and Chapman (1977) stated that brain temperature of a quiet dog is higher than the carotid blood temperature. Moreover, a decrease in brain temperature and an increase in carotid blood temperature were noticed in restless dogs and they also noticed that the brain temperature was maintained 1.3°C cooler than the carotid blood temperature when they let a mongrel dog exercise for three minutes. In addition, Krabill (1979) recorded an increase in brain temperature when the sheep was placed on bypass breathing while the temperature of the brain returned to normal when normal nasal breathing was resumed. Baker and Hayward (1968b) observed a fall in brain temperature when cool air was blown into the nostrils and buccal surfaces of the sheep at a rate of 50 times per minute for 5 minutes, the cavernous sinus temperature on the same side dropped by 2°C. Heat exposure on regional and total blood flow in the brain of the sheep was described by Hales (1973), when he exhibited that the dorsal sagittal sinus receives blood from the face and the nose, but he failed to describe arteriovenous anastomoses in the brain region.

MATERIALS AND METHODS

Thirty-five sheep were used in this investigation. Age, sex, breed and body weight were not considered.

Table 1. Indicates the number of animals used for various studies.

Group	Number of Animals	Purpose
A	24	gross study
B	10	microscopic study
C	1	venography

Animals from Groups A and B were killed either by bleeding or decapitation after 1/M injection of Rompun solution (Xyalzine hydrochloride) in doses of 10 mg/lb body weight. The sheep heads of Group A were perfused with physiologic saline solution, then injected with various intravascular materials via different routes (Table 2).

Specimens were embalmed with buffered neutral formalin (BNF) solution one day before they were injected with latex, then routine dissection was followed on them. The specimens injected with Decopour, Batson's #17, and Technovit 7001 were placed in a 33% potassium hydroxide (KOH)[1] for 1-2 weeks at room temperature for maceration (Batson, 1955) to depict the vascular arrangement of the cranial region, especially of the nasal

---

[1] Mallickrodt, Inc., Kentucky.

Table 2. Group A. Gross study

Number of animals	Material injected	Route of injection
4	red latex	common carotid arteries
3	blue latex	lateral nasal veins
2	double injected with red and blue latex	common carotid arteries and lateral nasal veins
9	Batson's #17[a]	common carotid arteries and/ or external jugular veins
2	Decopour[b]	common carotid arteries and/ or external jugular veins
4	Technovit 7001[c]	common carotid arteries

[a] Polyscience, Inc., Paul Valley Industrial Park, Warrington, Penn.

[b] Flecto, Co., Inc., P. O. Box 12955, Oakland, Calif.

[c] Kulzer and Co., Gmbh Bereich Technik, 6380 Bad Homburg, Germany.

cavity of the sheep. On alternate days the specimens were removed from the KOH solution, cleaned under running water for half an hour and replaced in the solution. After complete maceration, the specimens were transferred into a 20% hydrochloric acid (HCl) solution[1] for several hours to remove the fat and the residual tissue.

Animals from Group B were used for microscopic study and tissues were obtained from different regions of the nasal cavity (Table 3).

The tissues were immersed in 10% BNF solution for 24 hours. For

---

[1] Mallickrodt, Inc., Kentucky.

Table 3. Group B. Microscopic study

Sheep number	Sites for obtaining tissue[a]
1-3	FV
1-9	AF, PM, LM, SAF, SPM, and SLM
10	DMV (AF, PM, LM), SAF, SPM, and SLM

[a] FV - bifurcation of the dorsal nasal into angularis oculi and facial veins; AF - alar fold region (stratified squamous epithelium); PM - at the level of the second upper premolar, i.e., first cheek tooth (respiratory epithelium); LM - at the level of the third upper molar tooth (olfactory epithelium); SAF - septal at the alar fold region; SPM - septal at the second upper premolar; SLM - septal at the third upper molar; and DMV - dorsal, middle, and ventral of the above mentioned areas (AF, PM, LM).

decalcification, five of them were transferred to ethylene diamine tetra acetic acid (EDTA) solution (Hillemann and Lee, 1953) and the remaining tissues to formic acid solution. After complete decalcification with EDTA, tissues were placed in formol saline solution for 24 hours to remove its residue and to prevent precipitation in alcohol. The tissues decalcified with formic acid were placed in 70% alcohol solution overnight (Culling, 1974) to remove its residue.

Tissues were processed for paraffin embedding by standard histologic techniques; slides were made with 5-8 uM thick serial sections and stained with the following stains: 1) Harris' hematoxylin and eosin, after Luna (1968); 2) Masson's trichrome (collagen - blue/green; smooth muscle - red) after Luna (1968); 3) modified Van Gieson's (collagen - red; tissue - yellow); 4) modified Weigert's resorcin fuchsin (elastic tissue - brown/

black), after Bancroft and Stevens (1977).

Modified Van Gieson's stain:

PREPARATION:

A. Weigert's iron hematoxylin solution

Solution I

Hematoxylin crystals	1.0 gm
Alcohol, 95%	100.0 ml

Solution II

Ferric chloride, 29% aqueous	4.0 ml
Distilled water	95.0 ml
Hydrochloric acid, conc.	1.0 ml

Working solution

Equal parts of Solution I and Solution II

B. Van Gieson's solution

Acid fuchsin, 3%	5.0 ml
Picric acid, saturated aqueous	95.0 ml

STAINING:

1. Deparaffinize and hydrate to distilled water.
2. Place in Weigert's iron hematoxylin solution for 10 minutes.
3. Wash in distilled water.
4. Stain in Van Gieson's solution for 5 minutes.
5. Dehydrate in 95% alcohol, absolute alcohol, and clear in xylene, two changes each.
6. Mount with Permount.[1]

---

[1] Fisher Scientific Co., Histological Mounting Medium, Chemical Manufacturing Division, Fair Lawn, New Jersey.

RESULTS:

collagen - red, muscles and cornified epithelium - yellow, and nuclei - blue to black.

Modified Weigert's resorcin fuchsin stain (after Bancroft and Stevens, 1977):

PREPARATION:

To 100 ml of distilled water, 1 gm of basic fuchsin and 2 gm of resorcin were added. The mixture was boiled, then 12.5 ml of freshly prepared 30% ferric chloride solution was added and boiling continued for 5 minutes. The mixture then cooled, filtered and the filterate was discarded. The precipitate was dissolved in 100 ml ethanol, using hot water bath to control heating and at the same time 2 ml of concentrated hydrochloric acid (HCl) was added to the mixture.

STAINING:

1. Deparaffinize and bring section to 70% alcohol.
2. Place in staining solution for 1 hour at 69°C.
3. Rinse in tap water.
4. Treat with 1% acid alcohol.
5. Rinse in tap water.
6. Counter stain with Van Gieson's for 4 minutes.
7. Dehydrate in 95% alcohol, absolute alcohol, and clear in xylene, two changes each.
8. Mount with Permount.

RESULTS:

elastic tissue fibers - brown/black.

Thickness of the arterial wall, the lumen diameter, and the number of smooth muscle layers in the tunica media were measured at different levels of the nasal cavity mentioned above. The data obtained from Group B animals were statistically analyzed: 1) to correlate the luminal diameter of the arteries with the thickness of the tunica media, including the number of smooth muscle layers of the arteries of the alar fold region, at the level of the second upper premolar tooth, and at the level of the third upper molar tooth of the nasal cavity; and 2) to show a linear correlation of each of the above parameters in sections taken from the above three levels of the nasal cavity.

The animal from Group C was used for venography to demonstrate the direction of the blood flow from the angularis oculi and the facial veins toward the cavernous sinus. Flouthan anaesthesia was used (Halothane U.S.P.) for cannulation of the left angularis oculi vein and the right facial vein. In each vein, sodium diatrizoate 8 ml was injected as a radio-opaque contrast medium.

RESULTS

Gross Anatomy

The nomenclature used here conforms to the International Committee on Veterinary Anatomical Nomenclature 1973 and 1975 (N.A.V., 2nd Ed), and most official Latin terms have been translated to accepted English equivalents. The description below includes only the vessels that contribute to the nasal region.

Arterial supply

Blood supply to the nasal cavity of the sheep was mainly derived from the sphenopalatine and ethmoidal arteries and to a lesser extent from the major palatine artery, while the external surface of the nose was supplied by the malar and infraorbital arteries (Figure 1).

1. The sphenopalatine artery arose from the descending palatine and entered the nasal cavity via the sphenopalatine foramen. Dorsally, it gave several branches to supply part of the middle nasal concha and, following a short rostral course, it released branches to the frontal and maxillary sinuses, and to the dorsal and lateral walls of the nasal cavity in the area of the middle nasal concha. Finally, the sphenopalatine artery terminated into dorsal, ventral, and septal branches (lateral, caudal, and septal branches of N.A.V., 1973) (Figure 2).

The dorsal branch of the sphenopalatine artery vascularized mainly the dorsal nasal concha as well as the lateral wall of the nasal cavity covering it. By repeated branching, it formed a delicate arterial network which ran horizontally in the nasal mucosa. As these small branches proceeded rostrally, they were disposed close to each other and were obliquely or almost vertically oriented to the long axis of the nose. From its ventral aspect a small branch descended and, after anastomosing with branches of the ventral branch, it supplied part of the ventral nasal concha.

The ventral branch of the sphenopalatine artery continued ventrally and rostrally, giving off several branches along its ventral aspect to supply the floor of the nasal cavity in the vicinity of the caudal choanae. From its dorsal aspect, it gave several branches to the mucous membrane, covering the ventral nasal concha laterally, and anastomosed with the infraorbital artery. The ventral branch wound around the ventrolateral aspect of the ventral nasal concha releasing several branches to the floor of the nasal cavity. It vascularized mainly the lateral aspect of the ventral nasal concha similar to the dorsal branch, while medially the small branches arising from it coursed horizontally to the mucosa throughout the length of the nasal cavity.

The septal branch of the sphenopalatine artery was the ventralmost branch and furnished the caudal one-third of the nasal septum, the floor of the nasal cavity, and the lateral part of the ventral nasal concha. Its direct continuation ramified into the nasal septum and anastomosed rostrally with the palatonasal branch of the major palatine artery (Figure 3).

2. The malar artery was a branch of the maxillary and, at the medial canthus of the eye, gave off the medial inferior palpebral artery. Then it ascended curving around the medial border of the bony orbit, detaching the lateral nasal artery. After coursing rostrally, under cover of the

levator labii superioris muscle, it supplied the lateral aspect of the nasal region. After a short course, following its emergence from the orbit, the malar artery split into the medial superior palpebral and the dorsal nasal arteries. The dorsal nasal artery descended rostrally and ramified in the dorsal aspect of the nasal region, anastomosing with branches of the infraorbital artery.

3. The infraorbital artery was also a branch of the maxillary and entered the infraorbital canal via the maxillary foramen and, after its emergence at the infraorbital foramen, it divided into two major branches. The ventral branch, after supplying the superior lip, supplied the lateral wall of the alar fold, while its dorsal branch, after dividing into three main branches, vascularized the lateral alar fold region. Subsequently, it entered the nasal cavity to anastomose with the ventral and dorsal branches of the sphenopalatine, superior labial, and dorsal nasal arteries (Figure 4).

The major palatine artery was a branch of the descending palatine and stretched rostrally in the palatine groove. Rostrally, both major palatine arteries united together to form the palatolabial artery, which entered the nasal cavity via the interincisive canal. Further, it anastomosed with the dorsal branch of the superior labial and the septal branch of the sphenopalatine arteries (Figure 3 and 4).

The transverse facial artery was a branch of the superficial temporal. It turned around the caudal border of the ramus of the mandible and passed superficially on the lateral surface of the face. It bifurcated into superior labial and inferior labial arteries. The larger superior labial artery was included here only for its contribution to the nasal region. It supplied the caninus, levator nasolabialis, levator and depressor labii superioris, and part of the buccinator muscles. In the region below the infraorbital foramen, it divided into a larger dorsal branch, which coursed toward the superior lip, supplied it and anastomosed with the infraorbital and the dorsal nasal arteries. After curving toward the philtrum, it anastomosed with its fellow of the opposite side. Further, it ascended to the nasal tip, where it ramified in the floor of the alar fold region, anastomosing with the palatolabial artery of the major palatine. Its ventral branch supplied the angle of the mouth and the adjacent part of the inferior lip.

Venous drainage of the nasal cavity

1. The sphenopalatine vein represented the main venous pathway draining the nasal cavity. It drained the ventral and dorsal nasal conchae, part of the middle nasal concha, the nasal septum, as well as the floor of the nasal cavity. It anastomosed with the infraorbital, major palatine, and the rostral branch of the deep facial veins (Figure 5). Finally, it emptied either into the maxillary vein via the connection with the deep facial vein, which is seemingly valveless, or the connection with the pterygoid plexus.

2. The external ethmoidal vein drained the middle nasal concha and part of the nasal septum. It entered the orbit via the ethmoidal foramen contributing to the ophthalmic plexus. The left and right ethmoidal veins were connected via an anastomosing branch across the midline inside the cranial cavity.

3. The major palatine vein drained the hard palate where it arborized into a venous network extending throughout its length. Several small branches off the floor of the nasal cavity, after passing through the interincisive canal, anastomosed with it rostrally. Caudally, the major palatine vein joined the infraorbital, spehnopalatine, and the rostral branch of the deep facial vein (Figure 5).

Further, similar to the findings reported by Burnham (1935) and Dawes and Prichard (1953) in the dog, cat, and the rabbit, the venous spaces in the nasal mucosa showed a characteristic grape-like or bead-like space in all specimens injected with Batson's #17; Decopour, and Technovit 7001 (Figure 4). Their distributions were, however, found to be different between nasal regions as well as between specimens. Generally, these bead-like venous spaces were found in large numbers in the rostral portion, especially on the lateral surfaces of the dorsal and ventral nasal conchae, gradually decreasing caudally until they disappeared completely in the region of the middle nasal concha. They were also present on the medial surface of the nasal septum (i.e., adjacent to the perichondrium).

Superficial veins

The facial vein was a branch of the linguofacial (Figure 5) and during its course along the lateral surface of the face it gave off the following branches:

1. Inferior labial vein did not contribute to the nasal region.

2. Deep facial vein was a branch off the facial and arose opposite to the origin of the inferior labial. It was directed caudally and

dorsally along the deep face of the masseter muscle and divided into two branches. The larger rostral branch coursed towards the eye and drained the area ventral to the inferior eyelid, while its direct continuation joined the infraorbital, sphenopalatine, and the major palatine veins. The smaller caudal branch was connected with the maxillary via an anastomotic branch near its origin, while its direct continuation joined the plexus of the deep facial vein. A branch off the caudal branch of the deep facial coursed dorsally to join the rostral auricular vein.

3. Superior labial veins, usually two, arose by a common trunk. In addition to the superior lip, they drained the area of the philtrum and part of the floor of the nasal vestibule in the alar fold region. Both left and right superior labial veins anastomosed at the midline and from this confluence arose one vein which entered the nasal cavity draining the floor of the nasal vestibule of the alar fold region. In this region, the superior labial anastomosed with the palatolabial, lateral, and dorsal nasal veins.

4. Medial inferior palpebral vein was variable in size, which drained the area of the medial canthus of the eye, and anastomosed with a branch of the transverse facial vein ventral to the inferior eyelid.

5. Lateral nasal vein, sometimes two, arose either directly from the facial or by a common trunk with the dorsal nasal veins off the facial. It drained the lateral part of the alar fold and anastomosed rostrally with the superior labial and the dorsal nasal veins.

6. Dorsal nasal veins, usually two or more, arose from the facial either directly or by a common trunk with the lateral nasal vein. They

drained the dorsal surface of the nose and entered the nasal cavity by piercing the nasal bone and the dorsal lateral nasal cartilage to drain the dorsal nasal concha via its anastomoses with the venous spaces in the dorsal aspect of the nasal cavity. The left and right dorsal nasal veins were connected by a transverse anastomotic branch across the midline which was evident in four specimens injected with Batson's #17 and Technovit 7001.

7. Angularis oculi vein arose from the caudal aspect of the facial vein and passed caudodorsally towards the medial canthus of the eye. Along its course it received two branches from the nasal cavity (one of them was the dorsal nasal of Hegner, 1962). Before traversing the supraorbital foramen, tributaries from the forehead and adjoining superior eyelid region joined it. Inside the supraorbital canal, the tributaries from the frontal sinus emptied into it. In one specimen (injected with Batson's #17) at the entrance of the supraorbital foramen the angularis oculi vein divided into two branches for a short distance. Superficially in the frontal region, the left and right angularis oculi veins were joined by an anastomotic branch. Beyond the supraorbital canal it continued as the dorsal external ophthalmic vein, receiving several branches from the retrobulbar area, to the ophthalmic plexus.

The carotid rete and the cavernous sinus

The main blood supply to the brain of the sheep was via rete branches from the maxillary artery (i.e., one caudal and two to three rostral rete branches). These branches arborized into a network of small arteries to form the carotid rete or rete mirabile epidurale rostrale (N.A.V., 1973).

The rete mirabile epidurale caudale was absent in the specimens used for this investigation, which is in agreement with those reported by Balankura (1954), Baldwin (1964), and Getty (1975). The carotid rete was bathed in the cavernous sinus at the base of the brain (Figure 6), which was connected to the ophthalmic plexus rostrally via a large branch. Both rostral and caudal intercavernous sinuses (between left and right cavernous sinuses) were found in three specimens (injected with Batson's #17) but only the caudal one was constantly present in all specimens. The rostral intercavernous sinus was, however, smaller than the caudal ones and sometimes it was represented by several small veins instead. In addition, the cavernous sinus was found to be directly connected to the pterygoid plexus or the maxillary vein via a large anastomotic branch. These findings were further confirmed by venography in the live animal, when contrast media was injected via the left angularis oculi, revealing filling of the cavernous sinus on the same side of injection (Figure 7). Further, when the injections were performed on the left angularis oculi and the right facial veins, both left and right cavernous sinuses were filled with the contrast media (Figure 8). The anastomotic branch between the cavernous sinus and the pterygoid plexus or the maxillary vein appeared only on the right side on the venograph when the injections were performed bilaterally and that was because digital pressure was applied on the right side of the external jugular vein during the injection.

Microscopic Anatomy

The nomenclature used here conforms to the International Committee on Veterinary Anatomical Nomenclature (1974) (Nomina Histologica Veterinaria, N.H.V.) and most official Latin terms have been translated to accepted English equivalents. For the sake of convenience each region will be described separately.

Alar fold region (AF)

The alar fold region was lined by stratified squamous epithelium. Elastic fibers were observed scattered subepithelially in the mucosa without forming a distinct layer. Compound tubuloalveolar type mixed glands, predominantly serous, were found (Figure 9). In some sections the glands appeared subepithelially located, especially at the alar tip and its ventral part (Table 4). The nerve fibers usually appeared disposed in the periglandular region.

Arteries of the AF region were of thin-walled type, lying superficial to the satellite veins. Large collagen bundles were found surrounding them, especially those close to the surface epithelium. These arteries possessed well-developed internal and external elastic laminae; large amounts of elastic fibers were admixtured with the collagen bundles surrounding the arteries in the alar tip, to a lesser extent in its dorsal part and very few in its ventral part. In this region, the septal mucosa showed similar distribution of arteries in the AF region (Figure 10). In the alar tip, the venous wall was thicker (Figure 11), except those lying next to the perichondrium, which were of thin-walled type. Thick-walled or cushion veins were characterized by very well-developed external elastic

Table 4. Alar fold region

	Dorsal	Middle (alar tip)	Ventral
a. epithelium	thick, highly interdigitated with the submucosa	thin, few interdigitations	thick, highly interdigitated with the submucosa
b. glands (mixed, predominantly serous)	+[a] (perichondrial)	++++ (close to the arterial layer)	++ (perichondrial)
c. arteries	one superficial layer	two superficial layers	one superficial layer
d. intra-arterial bolsters	-	+	-
e. veins	2-3 layers, thin-walled type	5-8 layers, thick-walled type	4-6 layers, thick-walled type
f. collagen and elastic fibers	++	++++	+
g. free smooth muscle cells in the propria submucosa	-	++	+
h. arterio-venous anastomoses (AVA)	-	++	-

[a] + indicates small quantity, ++ larger and so on.

lamina and large quantity of elastic fibers in their adventitia. Smooth muscle cells in the AF region were found in bundles around the glands and adjacent to the cushion veins in the deep portion of the propria submucosa.

Second upper premolar (first cheek tooth) region (PM)

The epithelial lining of this region was respiratory in nature (i.e., pseudostratified ciliated columnar with goblet cells). Few elastic fibers and collagen were found subepithelially (Table 5) and very well-developed subepithelial capillaries in the areas were exposed to the air-stream. On the contrary, the epithelial lining of the conchal sinus, which was not toward the air passages, had fewer goblet cells and elastic fibers (Figure 12), without well-developed subepithelial capillaries. The glands, in general, were simple tubuloalveolar mixed type but were predominantly mucous (Table 5). They were found in the upper part of the propria submucosa and superficial to the arteries, but fewer in number in comparison to the AF region.

The arteries of this region were usually superficial to the veins, but in the areas where the mucous membrane followed the spiral contour of the conchal cartilage, the arteries were embedded deep in the propria submucosa. In addition, the veins in these areas were thin-walled structures surrounding the relatively thin-walled arteries with larger lumen than in other arteries (Figure 13). In addition, the arteries of this region had a very distinct internal and an external elastic laminae, with abundance of collagen in their tunica adventitia. In the ventral part, there were 3-5 layers of thick-walled veins with no distinct

Table 5. Second upper premolar region (PM)

		Conchal sinus mucous membrane	Mucous membrane facing airstream
a.	epithelium	few goblet cells	large number of goblet cells
b.	glands (mixed, predominantly mucous)	+[a]	++
c.	arteries	absent or very few	large number, thick-walled type
d.	intraarterial bolsters	-	+++ (stalked type)
e.	veins	1-2 layers, thin-walled type, deeply located	2-4 layers, thin-walled type, deeply located
f.	collagen and elastic fibers	+	+++
g.	free smooth muscle cells in the propria submucosa	-	++
h.	arteriovenous anastomoses (AVA)	-	+

[a] + indicates small quantity, ++ larger and so on.

external elastic lamina though the veins in the ventral conchal region had well-developed external elastic lamina. In general, elastic fibers were found in larger quantity around the arteries and in areas where the concha spiralled medially. In such areas the elastic fibers increased in the subepithelial, periglandular, and perichondrial locations. Similarly, the veins were also surrounded by collagen and elastic fibers in the tunica adventitia as the arteries.

The epithelium of the septal mucosa of this region presented a large number of goblet cells with a few thick-walled veins in the propria submucosa, especially in its deeper portion.

Last molar tooth region (LM)

The epithelial lining of this region was olfactory in nature with very few elastic fibers subepithelially or even absent in some areas (Table 6). The glands were simple tubuloalveolar mixed type, predominantly mucous, and were scattered throughout the region (Figure 14). They were more numerous in the areas where the concha projected into the nasal cavity. Elastic fibers were dispersed in larger quantity in those areas projected into the nasal cavity and in the perichondrial region of these areas. The arteries consisted of a distinct internal and an external elastic laminae with collagen bundles surrounding them, but the amount of the collagen was relatively less than the AF region.

Veins were lying superficial to the arteries and at places even surrounding them. They formed four or more layers in areas where the tip of the concha projected into the nasal cavity. In the ventral part of this region, there were 3-5 layers of cavernous spaces, which communicated with each other, lying superficial to the arteries. Few elastic fibers were found in the tunica adventitia of these veins but bundles of collagen were persistently present.

Table 6. Last molar tooth region (LM)

		conchal sinus mucous membrane	mucous membrane facing airstream
a.	epithelium	low	high
b.	glands (mixed, predominantly mucous)	+[a]	++
c.	arteries	absent or very few, deeply located	thick-walled type, mostly deep
d.	intraarterial bolsters	-	+ (stalked type)
e.	veins	one layer of thin-walled type	2-3 layers of thin-walled type
f.	collagen and elastic fibers	-	++
g.	free smooth muscle cells in the propria submucosa	-	-
h.	arteriovenous anastomoses (AVA)	-	-

[a] + indicates small quantity, ++ larger and so on.

The septal part of this region consisted of very well-developed subepithelial capillary layers. In some areas there were two layers of arteries, viz., small superficial and very large deep. In the ventral part, the arteries were close to the epithelium and there were some thick-walled type veins. The glands were also simple tubuloalveolar mixed type, predominantly mucous.

Facial, angularis oculi, and dorsal nasal veins

The walls of the facial, angularis oculi, and dorsal nasal veins were similar in structure and were composed of several layers of smooth muscles (5-8) with very prominant internal elastic lamina. The elastic fibers were scattered all around the wall of the veins in the tunica adventitia and in-between the smooth muscle layers of the tunica media. The tunica media consisted of both longitudinal and circular smooth muscle cells which alternated with collagen bundles (Figure 15). The thickness of the tunica media was almost the same as that of the adventitia. The dorsal nasal vein had a valve at its junction with the angularis oculi (Figure 16) whereas valves were not grossly visible in the angularis oculi vein at this site.

Arteriovenous anastomoses (AVA)

Arteriovenous anastomosis is usually defined as the connection of an artery directly to a vein, thus bypassing the capillary bed. Grossly, the type and location of AVA could not be ascertained, while microscopically, they appeared quite visible in all the regions investigated, except in the LM region, in spite of their appearance in its corresponding septal part (Figures 17, 18 and 19). Two kinds of AVA (coiled and epithelioid) were differentiated in the mucosa of the nasal cavity of the sheep. The coiled type of AVA was evident mostly in the periglandular region, while the epithelioid form could be visible throughout the nasal mucosa. The AVA appeared to extend from the periglandular region to the deep perichondrial or periosteal regions and occasionally in the subepithelial region.

Thickness of the arterial wall and lumen diameter

The thickness of the tunica media (TTM), the number of smooth muscle layers in the tunica media (NSMTM), and the luminal diameter (LD) of the arteries at three different regions (AF, PM, and LM) of the nasal mucosa, with their corresponding septal counterparts, were measured in 10 sections from each region. The data were statistically grouped and analyzed to show the correlations between these parameters and in between regions (Table 7).

Table 7. Range and grouping of arteries in different regions (TTM and LD in um)

	region	grouping	range	standard deviation
TTM	PM	A	66.26-115.81	13.28
	SLM	B	39.90-105.97	20.80
	LM	B	27.47-81.29	15.94
	SPM	B	28.95-66.81	12.19
	AF	B	20.41-68.49	13.28
	SAF	B	18.56-68.67	13.66
NSMTM	PM	A	5.00-7.00	0.70
	SPM	B	3.00-5.00	0.67
	LM	B C	3.00-5.00	0.82
	SLM	B C	3.00-5.00	0.53
	AF	C	2.00-4.00	0.70
	SF	C	3.00-4.00	0.48
LD	AF	A	24.87-95.03	23.35
	SAF	A B	17.63-98.74	29.35
	SLM	A B	26.36-78.32	15.86
	SPM	A B	32.85-68.49	10.23
	LM	A B	17.45-72.20	19.51
	PM	B	20.23-55.68	13.32

In the above table alpha level = 0.05 and degree of freedom = 45 for all of them but the mean square error was different.

For TTM mean square error = 232.54

For NSMTM mean square error = 0.37

For LD mean square error = 283.32

AF, SAF, PM, SPM, LM, and SLM were used here in the same context as used in Table 3. Groupings of the means of 10 measurements were designated by letters (A, B, and C). Means with the same letter were not significantly different. From Table 7 it is obvious that there were a lot of overlappings of certain parameters between regions under investigation, which is quite normal due to the gradual changes in the structure of the arteries.

Table 8. Significant correlations of the thickness of the tunica media and luminal diameter of arteries within each region

Region		NSMTM
AF	TTM	0.77696[a]
		0.0083[b]
LM	TTM	0.72636
		0.0174
LM	LD	0.71305
		0.0206

[a] Correlation coefficient.

[b] Probability.

No significant correlation was evident in the PM region due to the thickness of the tunica media or in between regions. In addition, all three septal areas (i.e., SAF, SPM, and SLM) lacked significant correlation.

DISCUSSION

The nasal cavity of the sheep was supplied exclusively, either directly or indirectly, by branches of the maxillary artery. The arteries coursed horizontally in the dorsal and ventral nasal conchae. They became closer together as well as somewhat obliquely oriented in the alar fold (AF) region, while in the septal mucosa they ran obliquely throughout its entire length. The thin-walled type arteries in the AF region were found superficial to the satellite veins (Table 4 and 7) which corresponds to the findings of Swindle (1935) in the rabbit, dog, sheep, and deer. In some areas of the nasal cavity, these arteries were disposed into two superficial layers. Table 7 shows the thickness of the tunica media (TTM) and the luminal diameter (LD) of the arteries, but their values were rather relative than absolute because bleeding, decapitation of animals, and buffered neutral formalin fixative might have caused identical degrees of constriction in all regions.

Two physiologic heat exchange mechanisms for the control of the brain temperature of the dog were described by Magilton and Swift (1968). An "external heat exchange mechanism" is described to function between the venous blood in the lakes of the alar fold region and the ambient air passing over it and the "internal heat exchange mechanism" is operative between the warm blood in the carotid rete and the cavernous sinus, which receives cool venous blood from the nasal area. Arteries of the AF region and its septal counterpart showed the thinnest wall owing to its relatively thin tunica media (Table 7) compared to other regions of the nasal cavity. this could play a role in the external heat exchange mechanism, or could be due to the direct exposure of this region to the inspired air to adjust easily to outside mechanical pressure. Moreover, the thickness of the collagen in the tunica adventitia of the arteries was found to be greatest in the AF region and it decreased gradually from rostral to the caudal part of the nasal cavity. This collagen in the AF region could be considered as a compensatory mechanism for the arteries because of their thin tunica media to help in pumping the blood from the arteries to the venous side.

In the premolar region (PM) the arteries lay also superficial to the satellite veins, except in the areas where the mucous membrane followed the curve of the conchal cartilage medially, where the mucosal surface is in contact with the airstream, in which the veins became superficial to the satellite arteries. The arteries were, in general, characterized by a very thick tunica media with correspondingly small lumina. This modification of the arterial wall in the PM region may assist in pumping the blood toward the AF region. Besides, it can control blood pressure and flow rate in that region because the blood flow to any region is inversely related to the diameter of the vessel (Ganong, 1977). Blood flow in the nasal cavity could be controlled either locally by thermoreceptors in the nasal mucosa or abdominal viscera (Robertshaw, 1976), or centrally via the autonomic nervous system (Ritter, 1970). Further, Baker (1979) reported that increase in blood flow through the nasal mucosa of the sheep resulted in the increase of the mucosal temperature and with decreased blood flow the temperature of the mucosa dropped.
In the last molar (LM) region the arteries lay deep in the submucosa (mostly adjoining the perichondrium).

The large number of anastomoses observed between the arteries of the nasal region was, perhaps, to facilitate shunting of the blood from one area to another. In the present study, two types of anastomoses were evident, viz., between terminal branches of different arteries and between branches of the same artery. The most extensive anastomoses between the superior labial, infraorbital, and the malar arteries were noted grossly around the nose and the superior lip which aid also in shunting the blood from one area to the other. These were evident only between the small terminal branches of the superficial arteries, which are contrary to the findings of May (1967), who stated that anastomoses in the head and neck regions of the sheep, in general, were normally nonfunctional, but under pressure or obstruction in the system they become functional. The other type of anastomoses was between branches of the same artery, for instance, the anastomoses inside the nasal cavity between branches of the sphenopalatine artery. This shows the ability to shunt blood from one region to another or even to regulate the rate of flow in certain areas within the same region of the nasal cavity.

Moreover, there were some structural modifications in the arterial wall assisting in controlling the blood flow in the nasal cavity. Nawar et al. (1975) described the presence of two kinds of intraarterial bolsters (polyploid and stalked) in the nasal cavity of the Egyptian buffalo. In the present study all bolsters were noticed as stalked type (Figure 20) and some appeared to be polyploid in nature which were believed to be due to sectioning incidence. Function of the intraarterial bolsters, in addition to control of blood flow, may be to skim blood cells off the collateral branch because of their projection into the blood stream as was observed in the uterine artery of the rat (Fourman and Moffat, 1961). Further, it has been hypothesized that they could be controlled by humoral system rather than nervous system because of their close proximity to the blood stream. The exact function of the intraarterial bolsters is, however, still unknown. Inner longitudinal smooth muscle cells in the subendothelial region of the arteries in the nasal cavity of the buffalo as reported by Nawar et al. (1975) were absent in all regions studied in this investigation. In addition, the presence of the free smooth muscle cells in the submucosa of the AF and PM regions, around and in between the veins, may help in venous drainage of the nasal cavity. These free smooth muscle cells were also described by Taher (1976) in the submucosa of the nasal septum of the albino rat.

Proceeding from rostral to caudal region of the nasal cavity, the TTM of the arteries (from an average of 10 readings) were increased. The thickest wall was found in the PM region, while the opposite was true for the LD (Table 7). The smallest LD was at the PM region and the largest at the AF region, where the TTM is smallest. This indicates that the possibility of epistaxis in the PM region is relatively low as compared to the AF region, which is apparently more vulnerable to this condition. The TTM of the PM region was probably responsible to increase pressure and velocity of the blood in this region, while in the AF region the pressure and velocity decrease because of the large luminal diameter of arteries thereby slowing the venous return to augment the efficiency of the external heat exchange mechanism. Numbers of smooth muscle layers in the tunica media (NSMTM) of the arteries were approximately the same throughout the entire nasal mucosa, except for the PM region where the TTM was conspicuously thick. It is obvious that in both AF and LM regions positive correlations exist between TTM and NSMTM (Table 8), while in the PM region no significant correlation is evident because of the thickness of the tunica media. The number of observations was only limited to 10 readings, which were considered to be insufficient to establish statistical correlations between TTM, NSMTM, and LD. Therefore, no significant correlations were observed between regions of the nasal cavity, except in a few sections and their corresponding septal areas.

Venous plexuses and the deep thick-walled or cushion veins of the nasal mucosa of the sheep were described by Schnorr and Hegner (1967). In this investigation, the cushion veins were found mainly in the AF region, while those adjoining the perichondrium were of the thin-walled type (Table 4). Cushion veins formed 5-8 layers at the alar tip, but were absent in the ventral conchal region (Table 5), and formed 2-3 layers in the floor of the PM region. They were, however, absent in the LM region (Table 6). Cushion veins may accommodate large quantities of blood in response to the need, or by constriction they may allow the veins rostral to them to be engorged with blood. Thus by decreasing the rate of venous return, they augment the efficiency of the external heat exchange mechanism. Another possible function for the cushion veins could be to absorb and release water, thus assisting in keeping the surface has been hypothesized by Cauna and Cauna (1975) for the nasal mucosa of man.

The drainage of the nasal mucosa was mainly via the sphenopalatine vein, which was connected to the pterygoid plexus via the rostral branch of the deep facial vein. The external ethmoidal vein drained part of the nasal cavity, especially the middle nasal concha, and joined the ophthalmic plexus. Both of the above communications have been postulated by Baker and Hayward (1968b) in the sheep. These connections allow the cool venous blood from the nasal area to flow toward the cavernous sinus at the base of the brain, where the "internal heat exchange mechanism" between this venous blood in the cavernous sinus and the carotid rete takes place.

The veins on the lateral surface of the face were guarded by valves at the sites of confluence with other veins, except the deep facial and the angularis oculi veins. The angularis oculi vein was connected to the cavernous sinus via the ophthalmic plexus and this situation was found similar to that of the dog (Magilton and Swift, 1968), sheep (Baker and Hayward, 1968c), Thompson's gazelle (Taylor and Lyman, 1972), and man (Caputa and Cabanac, 1978).

The cool inspired air passes over the nasal mucosa, especially at the nasal vestibule, where the "external heat exchange mechanism" operates, resulting in cooling of the venous blood present in the so-called venous lakes in the AF region. The cool venous blood leaves the nasal cavity via the nasal veins to the angularis oculi or the facial vein. Due to the apparent absence of valves in the angularis oculi vein, blood can flow to either direction (i.e., toward facial or ophthalmic plexus). For the blood to reach the ophthalmic plexus, it has to go uphill against gravity, which is more difficult than going toward the facial vein. The presence of several layers of smooth muscles in the wall of the angularis oculi vein (Figure 15) facilitates pumping of the blood toward the ophthalmic plexus. These findings were similar to those described by Magilton and Swift (1968) in the facial and angularis oculi veins of the dog, but no mention has been made about the presence of inner longitudinal smooth muscle cells in cross section. Further, Baker (1979) demonstrated the connection between the angularis oculi vein and the cavernous sinus by injecting latex via the nasal veins and thus filling the cavernous sinus of the same side of the sheep. In addition to the injection of dead animals, further confirmation of this venous pathway was established in this study by venography on a live animal to show the connection between the nasal veins and the cavernous sinus via the angularis oculi vein and the ophthalmic plexus (Figure 7 and 8). The direction of the blood flow in the angularis oculi vein depends upon the body temperature as stated by Caputa and Cabanac (1978). For example, in hyperthermic conditions in man the blood flows from the nose toward the cavernous sinus via the angularis oculi vein, while in hypothermia the blood flows rapidly in the opposite direction (i.e., from the angularis oculi vein towards the facial vein).

Another possible route for the venous drainage of the nasal cavity is accomplished via the sphenopalatine vein, which joins the valveless deep facial vein and then, in turn, to the pterygoid plexus. The anastomotic branch between the pterygoid plexus and the cavernous sinus could carry the auxiliary blood from the sphenopalatine, infraorbital, and major palatine veins, therefore aiding to bring additional cool blood to the cavernous sinus where the "internal heat exchange mechanism" takes place.

Arteriovenous anastomoses (AVA) were present in all three regions of the septal mucosa, on the other hand they were only present in the rostral two sections of the nasal mucosa (i.e., AF and PM regions). These anastomoses usually aid to shunt blood from the arteries to the veins bypassing the intervening capillary beds. Thus, the amount of blood flow to the nasal mucosa was regulated either by imbibition of the epitheloid cells, which constitute the walls of the anastomotic vessels, resulting in swelling or by shrinkage (Schumacher, 1938). This will be reflected in the decrease or increase of the venous blood pressure, respectively. Further, AVA may play a role in temperature regulation as Brown (1937) hypothesized that dogs pant vigorously while their mouths are open and protrude their tongues in hot weather. However, this is not the case in the sheep, which pant with their mouths closed. In addition, Grant and Bland (1931) reported that AVA in human fingers were responsible for the increase in blood flow as a reaction to cooling. Clark and Clark (1934) showed that AVA in a live rabbit ear responded to temperature changes when the ear was placed in a transparent chamber. Moreover, Schnorr and Hegner (1967) described grossly three kinds of AVA in the nasal cavity of the sheep but in the present study no AVA could be grossly identified and that might be attributed to the injection technique employed. Microscopically, most of the AVA were found to be epithelioid in nature (Figure 17) and some of them appeared as a branch of a terminal artery (Figure 18). The number of AVA was found to be high in the AF region and decreased caudally and in the LM region was altogether absent. The characteristic epithelioid cells of the wall of the AVA could also play a role in the tongue (i.e., as a site for heat exchange; Brown, 1937) by either increasing or decreasing the blood flow to the area in response to temperature changes. Finally, AVA can divert large quantities of blood from the arterial to the venous side due to their conspicuous occurrence in the AF region.

The main source of the blood supply to the brain of the sheep was derived from branches off the maxillary artery, which was concordant with those described by Baldwin (1964) and Getty (1975). This resembles closely the cerebral vasculature for the goat described by Anderson and Jewell (1956). The carotid rete of the sheep was first described by Balankura (1954). In this investigation, both left and right retia were connected by a communicating artery across the midline, which Gillilian (1974) considered to function as an aid to shunt the blood when the pressure gradient increases in the carotid rete. The carotid rete was enmeshed in a network of veins in the cavernous sinus at the base of the brain (Magilton and Swift, 1968). Gillilian and Markesbery (1963) described a vessel having both a thick-walled and a thin-walled segment, which they considered as AVA between the carotid rete and the cavernous sinus of the cat. Such interconnections were, however, not seen in the sheep, ox, horse, and pig (Gillilian, 1974), which seems logical because of the sensitivity of the brain tissue to carbon dioxide content of the blood.

The air conditioning capacity of the nasal mucous membrane and its effect on brain temperature were described by several investigators [Magilton and Swift (1968) and Carithers and Seagrave (1976) in the dog; Kluger and D'Alecy (1975) and Caputa et al. (1976a) in the rabbit; and Young et al. (1976) and Krabill (1979) in the sheep]. Moreover, Baker and Hayward (1968b) stated that blowing cool air into the nostrils of the sheep showed a decrease in the temperature of the cavernous sinus on the same side. Heat exchange mechanism does not necessarily include the whole nasal mucous membrane and the only area involved was the area directly in contact with the airstream. Dawes (1952) stated that in dog, cat, and rabbit the air during rest did not enter the olfactory region but flowed through the ventral nasal meatus only. With medium pressure the air flowed through both ventral and dorsal nasal meatuses but did not pass through the olfactory region. Only under higher pressure can the air reach the olfactory region and if an analogous situation exists in the sheep, the heat exchange mechanism also could function in the AF region and the ventral meatus during rest.

In addition, cyclic alternation of air flow through both nostrils due to the engorgement of the venous plexuses in the conchae and the nasal septum of man was reported by Stoksted (1952) and Principato and Ozenberger (1970). In the rabbit and rat, Moller and Fahrenkrug (1971), and in the sheep Schnorr and Hegner (1967) and Ritter (1970) showed that the distension of the swell bodies exhibit a cyclic alternation in flow pattern between the two halves of the nasal cavity. It can be inferred that for certain time intervals the countercurrent heat exchange mechanism takes place in one nostril more effectively than in the other. In the present study the caudal intercavernous sinus was always present, whereas the rostral invercavernous sinus was inconstant. In sheep, the time intervals for the cyclic alternation in flow pattern have not been estimated, but if the time interval is increased it may be postulated that the temperature gradients between the cavernous sinuses will probably increase. Therefore, the presence of the rostral and caudal intercavernous sinuses, the temperature changes in one side of the cavernous sinus may influence the other side more rapidly than in the case of the presence of the caudal intercavernous sinus alone.

Furthermore, heat exchange mechanism depends upon the presence of moisture in the nasal cavity, which is mainly derived from the lateral nasal glands in the sheep (Nickel et al., 1960). The function of these glands was found to be dependent on the ambient air temperature in the nasal cavity of the dog (Blatt et al., 1972). In this investigation, the submucosal glands were found to be present in large numbers in the AF region and they were predominantly of serous type. Their secretions keep the surface epithelium moist due to the fact that the AF region is the first region exposed to the inspired air. On the contrary, in the PM and LM regions the submucosal glands were predominantly mucous type for the protection of the surface epithelium from the inspired air. This might partially explain the presence of the large number of these glands on the medial surfaces of the conchae toward the airstream, while on their opposite surfaces facing the conchal sinus the glands were fewer or even absent in some areas.

Several investigators studied the countercurrent heat exchange between the inspired air and the venous blood in the nasal mucosa. Other investigators stated that the oral cavity is as effective as the nasal cavity in heat exchange mechanism because of the presence of the palatine plexus in the hard palate in man and ungulates (Cole, 1954; Scott, 1954). This could be possible, but in the heat exchange the nasal cavity of the sheep is more efficient than the oral cavity due to the following reasons: 1) the complexity of the blood supply to the nasal cavity is more extensive than that to the oral cavity, 2) the surface area of the nasal mucosa is by far larger than the oral cavity, and 3) the source of the moisture comes from several sources in the nasal cavity. Besides, most animals pant with their mouths closed (Negus, 1958) and Robertshaw (1976) reported that ruminants pant with their mouths closed in hot weather. Therefore, the oral cavity does not seem to play a major role in heat exchange in sheep.

SUMMARY

The gross and microscopic anatomy of the blood vessels of the nasal cavity of 35 sheep was described. The microscopic structure of the nasal mucosa in respect to thickness of smooth muscle layers, elastic fibers, and collagen fibers was described.

Twenty-four sheep heads were injected for gross studies of the blood vessels. The nasal cavity of the sheep was mainly supplied by the sphenopalatine and ethmoidal and their anastomoses with the infraorbital, malar and the superior labial arteries in the region of the superior lip and the adjacent part of the nose.

The venous drainage of the nasal cavity had connection with the cavernous sinus via two routes. The first route was between the nasal veins to the ophthalmic plexus via the angularis oculi vein. The second route was via the connection of the sphenopalatine vein to the pterygoid plexus via the rostral branch of the deep facial vein.

Ten sheep were used for microscopic study. Certain structures, for example, the presence of arteriovenous anastomoses, collagen fibers, elastic fibers, thick-walled or cushion veins, and the smooth muscle cells in the submucosa were observed to decrease from rostral to caudal region of the nasal cavity.

More vascularity was evident in areas of the nasal cavity which were in direct contact with the air. Intraarterial bolsters were present in large numbers in the premolar region (PM), fewer in the last molar (LM), and very few in the alar fold (AF) regions.

Tissues were obtained from the same 10 sheep heads used for micro-

scopic study to measure the thickness of the tunica media (TTM), number of smooth muscle layers in the tunica media (NSMTM), and the luminal diameter (LD) in the AF, PM, LM, and their corresponding septal portions. The tunica media was very thin in the AF region and relatively thicker in the PM region. On the other hand, LD was very small in the PM region and relatively larger in the AF region. No significant correlations between TMT, NSMTM, and LD between different regions were established.

Sections from the angularis oculi, dorsal nasal, and the facial veins were microscopically examined. Valves at the junction of the dorsal nasal and the facial veins were evident, while no valve was visible in the angularis oculi vein. Inner longitudinal smooth muscle in the subendothelium was found in the angularis oculi vein.

One live sheep was used for venography to demonstrate the pattern of venous drainage from the angularis oculi vein to the cavernous sinus.

BIBLIOGRAPHY

Allison, A. C., and R. T. T. Warwick. 1949. Quantitative observations on the olfactory system of the rabbit. Brain 72:186-197.

Anderson, B., and P. Jewell. 1956. The distribution of carotid and vertebral blood in the brain and spinal cord of the goat. Quart. J. Exp. Physiol. 41:462-474.

Anggard, A. 1974. Capillary and shunt blood flow in the nasal mucosa of the cat. Acta Otolaryngol. (Stockh.) 78:418-422.

Baker, M. A. 1972. Influence of carotid rete on brain temperature in cats exposed to hot environment. J. Physiol. 220:711-728.

Baker, M. A. 1979. A brain cooling system in mammals. J. Sci. Am. 240(5):130-139.

Baker, M. A., and L. W. Chapman. 1977. Rapid brain cooling in exercising dogs. Science 195:781-783.

Baker, M. A., and J. N. Hayward. 1967. Carotid rete and brain temperature of the cat. Nature 216:139-141.

Baker, M. A., and J. N. Hayward. 1968a. Intra-cranial heat exchange and regulation of brain temperature in sheep. Life Sci. 7:349-357.

Baker, M. A., and J. N. Hayward. 1968b. The influence of the nasal mucosa and the carotid rete upon hypothalamic temperature in sheep. J. Physiol. 198:561-579.

Baker, M. A., and J. N. Hayward. 1968c. Carotid rete and regulation of brain temperature in sheep. Anat. Rec. 160:309-310.

Baker, M. A., and J. N. Hayward. 1968d. Thermal polypnea and intracranial vascular heat exchange in sheep. Anat. Rec. 160:458.

Baker, M. A., L. W. Chapman, and M. Nathason. 1974. Control of brain temperature in dogs. Effects of tracheostomy. Resp. Physiol. 22:325-333.

Balankura, K. 1954. Observations on the development of intra-cranial rete in the sheep. J. Anat. 88:572.

Baldwin, B. A. 1964. The anatomy of the arterial supply to the cranial regions of the sheep and ox. Am. J. Anat. 115:101-118.

Bancroft, J. D., and A. Stevens. 1977. Theory and practice of histological techniques. Churchill Livingstone, New York.

Batson, O. V. 1954. The venous network of the nasal mucosa. Ann. Otol. Rhinol. Laryngol. 63(3):571-589.

Batson, O. V. 1955. Demonstration of corrosion specimens prepared by a new material. Am. Assoc. Anat. Meet. 68th Session, Philadelphia.

Best, P. V., and D. Heath. 1968. Interpretation of the appearance of the small pulmonary blood vessels in animals. Circ. Res. 60(2): 288-294.

Blatt, C. M., C. R. Taylor, and M. B. Habal. 1972. Thermal panting in dog: the lateral nasal gland, a source of water for evaporative cooling. Science 177:804-805.

Bligh, J. 1957. A comparison of the temperature in the pulmonary artery and in the bicarotid trunk of the calf during thermal polypnea. J. Physiol. 136:404-412.

Bligh, J. 1959. The receptors concerned in the thermal stimulus to panting in sheep. J. Physiol. 146:142-151.

Brown, M. E. 1937. The occurrence of arteriovenous anastomoses in the tongue of the dog. Anat. Rec. 69:287-297.

Bruns, R. R., and G. E. Palade. 1968. Studies on the blood capillaries in muscles. J. Cell. Biol. 37:244-299.

Bugge, J. 1968. The arterial supply of the rabbit nose and oral cavity. Acta Anat. 70:168-183.

Burnham, H. H. 1935. An anatomical investigation of blood vessels of the lateral nasal wall and their relation to turbinates and sinuses. J. Laryngol. 50:569-593.

Cabanac, M., and M. Caputa. 1979. Natural selective cooling of the human: evidence of its occurrence and magnitude. J. Physiol. 286:255-264.

Candy, C., and T. McKean. 1977. The carotid and orbital retia of the proghorn, deer and elk. Anat. Rec. 189:91-108.

Caputa, M., and M. Cabanac. 1978. Behavioral and circulatory evidence of selective brain cooling. Exp. Brain Research 32(3):2762.

Caputa, M., W. Kadziela, and J. Narbeski. 1976a. Significance of cranial circulation for the brain homeothermia in rabbit. I. The brain-arterial blood temperature gradient. Acta Neurobiol. Exp. 36:613-624.

Caputa, M., W. Katziela, and J. Narbeski. 1976b. Significance of cranial circulation for the brain homeothermia in rabbit. II. The role of the cranial venous lakes in the defense against hyperthermia. Acta Neurobiol. Exp. 36:625-638.

Carithers, R. W., and R. C. Seagrave. 1976. Canine hyperthermia with cerebral protection. J. Appl. Physiol. 40:543-548.

Cauna, N. 1970a. Electron microscopy of the nasal vascular bed and its nerve supply. Ann. Otol. Rhinol. Laryngol. 79(3):443-450.

Cauna, N. 1970b. The fine structure of the arteriovenous anastomosis and its nerve supply in human nasal respiratory mucosa. Anat. Rec. 168:19-22.

Cauna, N., and D. Cauna. 1975. The fine structure and innervation of the cushion veins of human respiratory mucosa. Anat. Rec. 18(1):1-16.

Cauna, N., and K. H. Hinderer. 1969. Fine structure of blood vessels of the human nasal respiratory mucosa. Ann. Otol. Rhinol. Laryngol. 78(4):865-885.

Christensen, G. C., and S. Toussaint. 1957. Vasculature of external nares and related areas in the dog. J. Am. Vet. Med. Assoc. 131: 504-509.

Clark, E. R., and E. L. Clark. 1934. Observations on living arteriovenous anastomoses in transparent chambers introduced into the rabbit's ear. Amer. J. Anat. 54:229-288.

Cole, P. 1954. Respiratory mucosal vascular responses, air conditioning and thermoregulation. J. Laryngol. Otol. 68(1):613-627.

Culling, C. F. 1974. Handbook of histopathological and histochemical techniques. 34d ed. Butterworths, London.

Daniel, P. M., and M. M. L. Prichard. 1956. Arteriovenous anastomoses in the external ear. Quart. J. Exp. Physiol. 41:107-123.

Daniel, P. M., J. D. K. Dawes, and M. L. Prichard. 1953. Studies of the carotid rete and its associated arteries. Phil. Trans. Roy. Sci. B, 237:173-208.

Dawes, J. D. K. 1952. The course of the nasal air streams. J. Laryngol. Otol. 66:583-593.

Dawes, J. D. K., and M. L. Prichard. 1953. Studies of the vascular arrangement of the nose. J. Anat. 85:311-322.

De Boissezon, P. 1941. Le réseau admirable artériel intracranien de l'agneau. Bull. Soc. Hist. Nat. (Toulouse) 76:299-304.

Dixon, F. W., N. L. Hoerr, and J. W. McCall. 1949. The nasal mucosa in the laryngectomised patients. Ann. Otol. 53:535.

Drury, R. A. B., E. A. Wallington, and S. R. Cameron. 1967. Carleton's histological techniques. Oxford University Press, New York.

Fourman, J., and D. B. Moffat. 1961. The effect of the intraarterial cushions on plasma-skimming in small arteries. J. Physiol. London 153:374-389.

Ganong, W. F. 1977. Review of medical physiology. Eighth Ed. Lange Medical Publications, Los Altos, Calif. 599 pp.

Getty, R.(ed). 1975. Sisson and Grossman's anatomy of the domestic animals. 5th Ed. Vol. I. W. B. Saunders Co., Philadelphia.

Gillilian, L. A. 1974. Blood supply to brains of ungulates with and without a rete mirabile caroticum. J. Comp. Neurol. 153:275-290.

Gillilian, L. A., and W. R. Markesbery. 1963. Arteriovenous shunts in the blood supply to the brain of some common laboratory animals-with special attention to rete mirabile cojugatum in the cat. J. Comp. Neurol. 121:305-312.

Godynicki, S. 1975. Blood supply of the nasal cavity in the rabbit. Folia Morphol. (Wasz.) 34(1):69-76.

Grant, R. T., and E. F. Bland. 1931. Observations on arteriovenous anastomoses in human skin and in bird's foot with special reference to the reaction to cold. Heart 15:385-411.

Hales, J. R. S. 1973. Effects of exposure to hot environment on total and regional blood flow in the brain and spinal cord of the sheep. Pflugers Arch. 344:327-337.

Hall, L. J., and R. T. Jackson. 1968. Effects of alpha and beta adrenergic agonist on nasal blood flow. Ann. Otol. Rhinol. Laryngol. 77(6):1120-1130.

Ham, A. W., and D. H. Cormack. 1974. Histology. Eighth Ed. J. B. Lippincott Company, Philadelphia. 955 pp.

Harper, W. F. 1949. Further observation on the blood vessels of the nasal mucous membrane in mammals. J. Anat. London 83:61.

Heeschen, W. 1958. Arterien und Venen am Kopf des Schafes. Dr. med. vet. Diss., Hannover.

Hegedus, S. A., and R. T. Shackelford. 1965. A comparative-anatomical study of the cranio-cervical venous systems in mammals, with special reference to the dog: Relationship of anatomy to measurements of cerebral blood flow. Am. J. Anat. 116:375-386.

Hegner, D. 1962. Des Blutgefässsystem der Nasenhöhle und ihrer organe von Canis familiaris, gleichzeitig ein Versuch der funkionellen Deutung der Venenplexus. Dr. vet. med. Diss., Giessen.

Hellstrom, B., and H. T. Hammel. 1967. Some characteristics of temperature regulation in the unanesthetized dog. Am. J. Physiol. 213:547-557.

Hemingway, A., R. Robinson, C. Hemingway, and J. Wall. 1966. Cutaneous and brain temperature to respiratory metabolism of the sheep. J. Appl. Physiol. 21:1223-1227.

Hillemann, H. H., and C. H. Lee. 1953. Organic chelating agent for decalcification of bones and teeth. Stain Technol. 28:285.

Ingram, D. L., and G. C. Whittow. 1962. The effects of variations in respiratory activity and in the skin temperature of the ears on the temperature of the blood in the external jugular vein of the ox (Bos taurus). J. Physiol. London 163:211-221.

International Committee on Veterinary Anatomical Nomenclature. 1973. Nomina Anatomica Veternaria. Second ed. Adolf Holzhausen's Successors, Vienna, Austria. 218 pp.

International Committee on Veterinary Anatomical Nomenclature. 1974. Nomina Histologica Veterinaria. Minnesota, U.S.A. 114 p.p.

International Committee on Veterinary Anatomical Nomenclature. 1975. Nomina Anatomica Veterinaria. Second Ed. 1973. Amended.

Jackson, D. E. 1942. Experimental and clinical observations regarding the physiology and pharmacology of the nose. Ann. Otol. Rhinol. Laryngol. 41(4):973-994.

Katz, S. and J. Merzel. 1977. Distribution of epithelium and glands of the nasal septum mucosa in rat. Acta Anat. 99:58-66.

Kluger, M. J., and L. A. D'Alecy. 1975. Brain temperature during reversible upper respiratory bypass. J. Appl. Physiol. 38:268-271.

Krabill, V. A. 1979. The effect of interrupting normal nasal breathing on the brain temperature and cerebrospinal fluid pressure in the sheep. M.S. Thesis, Iowa State University, Ames, Iowa.

Krajina, Z., J. Krmpotic, S. Vecerina, M. Krajina, and A. Zirdum. 1975. Histology of the mucous membrane of the lateral nasal wall. 6th Cong. Europ. Rhinol. Soc., Ireland.

Leeson, T. S., and C. R. Leeson. 1979. A brief atlas of histology. W. B. Saunders Co., Philadelphia.

Luna, L. G. 1968. Manual of histologic staining methods of the Armed Forces Institute of Pathology. 3rd Ed. McGraw-Hill Book Co., New York.

McGrath, P. 1977. Observations on the intra-cranial carotid rete and the hypophysis in the mature female pig and sheep. J. Anat. 124(3): 689-699.

Magilton, J. H., and C. S. Swift. 1967. Thermoregulation of the canine brain by alar-fold and intervening arteriovenous heat exchange systems. The Physiologist 10:241.

Magilton, J. H., and C. S. Swift. 1968. Description of two physiological heat exchange systems for the control of brain temperature. Inst. Elec. Electron. Engrs. Ann. Rocky Mountain Bioeng. Symp. 5:24-27.

Magilton, J. H., and C. S. Swift. 1969. Response of veins draining the nose to alar-fold temperature changes in the dog. J. Appl. Physiol. 27:18-20.

Magilton, J. H., and C. S. Swift. 1976. Effect of nasal constriction on the temperature of the angularis oculi and facial veins and internal carotid artery. Israel J. Med. Sci. 12:1079-1081.

Malomson, K. G. 1959. The vasomotor activities of the nasal mucous membrane. J. Laryngol. Otol. 73:73-98.

May, N. D. S. 1967. Arterial anastomoses in the head and neck of the sheep. J. Anat. 101(2):381-387.

Menschik, Z., and S. F. Dovi. 1965. Normally occurring intraluminal projection in the arterial system of the mouse. Anat. Rec. 153: 265-274.

Moffat, D. B. 1969. Intra-arterial cushions in the arteries of the rat's eye. Acta Anat. 72:1-11.

Moller, F. B. 1965. Glandulae nasales anteriores in the human nose. Ann. Otol. Rhinol. Laryngol. 74:363-375.

Moller, F. B., and J. Fahrenkrug. 1971. Nasal swell-bodies and cyclic changes in the air passages of the rat and rabbit nose. J. Anat. 110(1):25-37.

Naessen, R. 1970. The anatomy of drainage of nasal secretions. J. Laryngol. Otol. 84:1231-1234.

Nawar, S. M. A., M. A. Elayat, and I. S. Ibrahim. 1975. Some anatomical and histological studies on the arterial supply of the nasal cavity of the buffalo in Egypt (Bos Bubalis L.). Anat. Anz. 138(3):203-221.

Negus, V. 1958. The comparative anatomy and physiology of the nose and paranasal sinuses. E. and S. Livingstone Ltd., Edinburgh and London.

Nickel, R., A. Schummer, and E. Seiferle. 1960. Lehrbuch der Anatomie der Haustiere. Vol. II. Parey, Berlin.

Osborn, A. G. 1978. The nasal arteries. Am. J. Roentgenol. 130:89-97.

Prichard, M. M. L., and P. M. Daniel. 1953. Arteriovenous anastomoses in the tongue of the dog. J. Anat. 87(1):66-74.

Prichard, M. M. L., and P. M. Daniel. 1959. Arteriovenous anastomoses in the human external ear. J. Anat. 90:309-317.

Principato, J. J., and J. M. Ozenberger. 1970. Cyclical changes in the nasal resistance. Arch. Otolaryngol. 91:71-77.

Ralston, H. J., and W. M. J. Kerr. 1945. Vascular responses of the nasal mucosa to thermal stimuli with some observations on skin temperature. Am. J. Physiol. 144:305-310.

Rawson, R. O. 1976. Temperature regulation in sheep. Pro. Biomet. 1:81-87.

Richter, E. 1962. Das Blutgefässsystem der Nasenhöhle und ihrer organe von Felis domestica, gleichzeitig ein Versuch der funkionellen Deutung der Venenplexus. Dr. med. vet. Diss., Giessen.

Ritter, F. N. 1970. The vasculature of the nose. Ann. Otol. Rhinol. Laryngol. 79:468-474.

Robertshaw, D. 1976. Evaporative temperature regulation in ruminants. Pro. Biomet. 1:132-139.

Scholander, P. F., and W. E. Schevill. 1955. Countercurrent vascular heat exchange in the fins of whales. J. Appl. Physiol. 8:279-282.

Schumacher, S. 1938. Über die Bedeutung der arteriovenösen Anastomosen und der epitheloiden Muskelzellen (Quellzellen). Z. Mikr. Anat. Forsch., 43:107-130.

Schnorr, B. and D. Hegner. 1967. Gefässarchitektur der Nasenhöhle bei Schaf und Ziege. Zentralbl. Veterinaermed. Reihe A. 14(5):445-468.

Scott, J. H. 1954. Heat regulating function of the nasal mucous membrane. J. Laryngol. Otol. 68:308-317.

Shaheen, O. 1970. Studies of the nasal vasculature, and the problems of arterial ligation for epistaxis. Ann. Roy. Coll. Surg. Engl. 47: 30-44.

Sherman, J. L. 1963. Normal arteriovenous anastomoses. Medicine 42: 247-267.

Schmidt-Nielsen, K., W. L. Bretz, and C. R. Taylor. 1970. Panting in dogs: Unidirectional air flow over evaporative surfaces. Science 169:1102-1104.

Spence, R. J., B. A. Rhodes, and H. N. Wagner. 1972. Regulation of arteriovenous anastomoses and capillary blood flow in dog leg. Am. J. Physiol. 222:326.

Stoksted, P. 1952. The physiologic cycle of the nose under normal and pathologic conditions. Acta Otolaryngol. 42:175-179.

Swindle, P. F. 1935. The architecture of the blood vascular networks in the erectile and secretory lining of the nasal passages. Ann. Otol. Rhinol. Laryngol. 44:913-932.

Swindle, P. F. 1937. Nasal blood vessels which serve as arteries in some animals and as veins in some others. Ann. Otol. Laryngol. 46:600-628.

Taher, El-S. 1976. Micromorphological studies of the nasal septum of the albino rat. Acta Anat. 96(3):366-385.

Taylor, C. R. 1966. The vascular and possible thermoregulatory function of the horns in goat. Physiol. Zool. 39:127-139.

Taylor, C. R., and C. P. Lyman. 1972. Heat storage in running antelopes: Independence of brain and body temperatures. Am. J. Physiol. 222(1): 114-117.

Toppozada, H. H., and H. A. Gaafer. 1974. Human nasal sero-mucinous glands after permanent tracheostomy. Otol. Rhinol. Laryngol. 36:299-395.

Toppozada, H., and H. A. Gaafer. 1976. Human nasal blood vessels after permanent tracheostomy. Otol. Rhinol. Laryngol. 38:35-44.

Young, B., J. Bligh, and G. Louw. 1976. Effect of thermal tachypnoea and of its mechanical or pharmacological inhibition on hypothalamic temperature in sheep. J. Ther. Bio. 1:195-198.

ACKNOWLEDGMENTS

A very special appreciation is extended to Dr. N. G. Ghoshal, who not only is an inspiring major professor, but also is a wonderful friend. His guidance, encouragement, efforts, and devotion to the discipline of veterinary anatomy allowed me to initiate and complete this investigation.

I wish to thank the members of my graduate advisory committee, Dr. H. S. Bal, Dr. J. H. Magilton, and Dr. F. B. Hembrough for their advice and constructive suggestions.

Sincere appreciation is extended to Dr. R. W. Mitten, Department of Veterinary Clinical Sciences for his help in preparing the radiographs and Dr. D. F. Cox, Department of Statistics for the analysis of the results presented in this project.

Gratitude is also expressed to the faculty and staff of the Department of Veterinary Anatomy for their assistance and suggestions.

I want to thank Mr. K. K. Booth and Dr. P. Simon for their help in injections of the gross specimens and Mrs. G. Faber and Miss R. M. Aspengren for their help in preparation of the microscopic slides.

I also want to thank the National Veterinary Services Laboratory for providing most of the sheep used in this project.

Special thanks are extended to Mrs. J. Smart for typing this manuscript.

Thanks are extended to the Iraqi government for their financial support.

Special appreciation is extended to my wife, Afaf, for patience, understanding, and support during many trying hours.

APPENDIX: ILLUSTRATIONS

Figure 1. The arterial supply to the nose of the sheep (diagrammatic drawing after removal of the nasal and maxillary bones).

1. Left common carotid a.
2. Occipital a.
3. External carotid a.
4. Lingual a.
5. Caudal auricular a.
6. Transverse facial a.
7. Maxillary a.
8. Superficial temporal a.
9. Rostral auricular a.
10. Lateral superior palpebral a.
11. Lacrimal branch
12. Muscular branches to the masseter muscle
13. Superior labial a.
14. Inferior labial a.
15. Mental a.
16. Mandibular alveolar a.
17. Caudal rete branch
18. Rostral rete branches
19. External ophthalmic a.
20. Malar a.
21. Lateral nasal a.
22. Ethmoidal plexus
23. Medial superior palpebral a.
24. Dorsal nasal a.
25. Infraorbital a.
26. Descending palatine a.
27. Minor palatine a.
28. Major palatine a.
29. Sphenopalatine a.
30. Dorsal branch of 29
31. Ventral branch of 29
32. Septal branch of 29
33. External ethmoidal a.
34. Branches from the rostral cerebral a.
35. Palatonasal branch of 28.

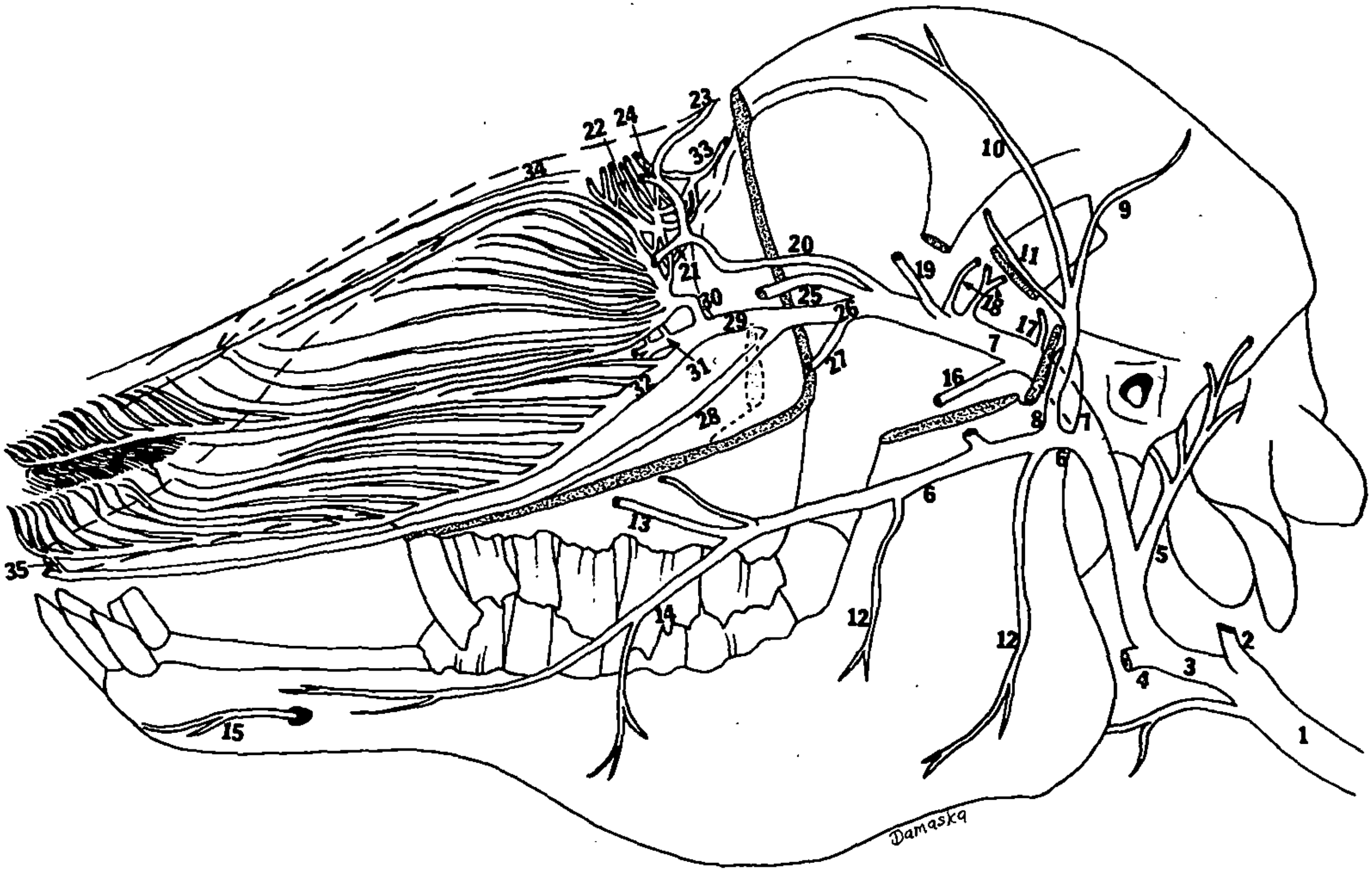

Figure 1. The arterial supply to the nose of the sheep

Figure 2. The arterial supply to the nose of the sheep. Decopour. Mag. 1.75 times.

A. Descending palatine a.
B. Malar a.
C. Infraorbital a.
D. Minor palatine a.
E. Major palatine a.
F. Sphenopalatine a.
G. Dorsal branch of F
H. Ventral branch of F
I. Septal branch of F

Figure 3. The septal branch of the sphenopalatine artery and its ramification. Decopour. Mag. 1.25 times.

a. Septal branch of the sphenopalatine a.
b. Major palatine a.
c. Palatonasal branch of b

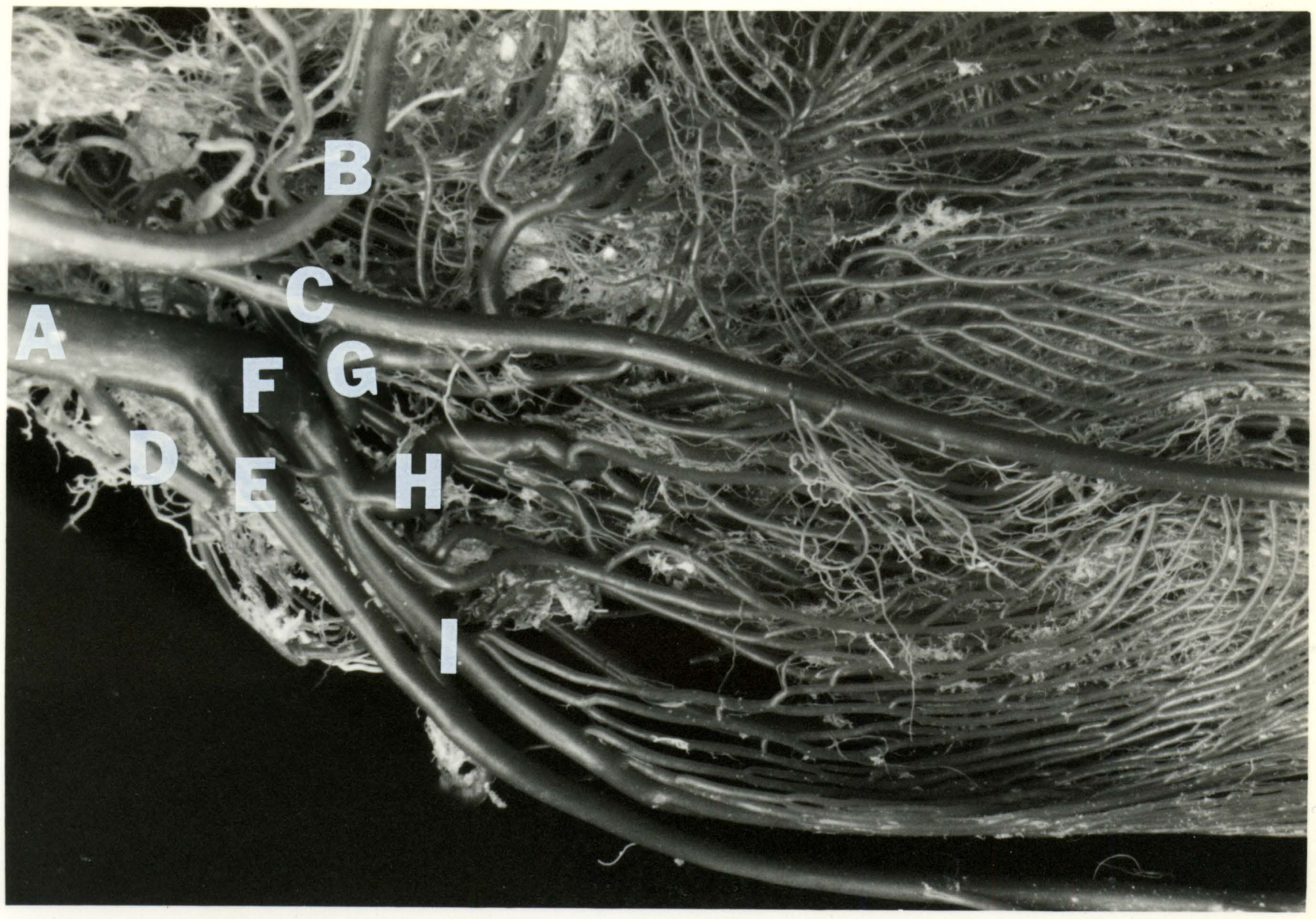
B
C
A
G
F
D
E
H
I

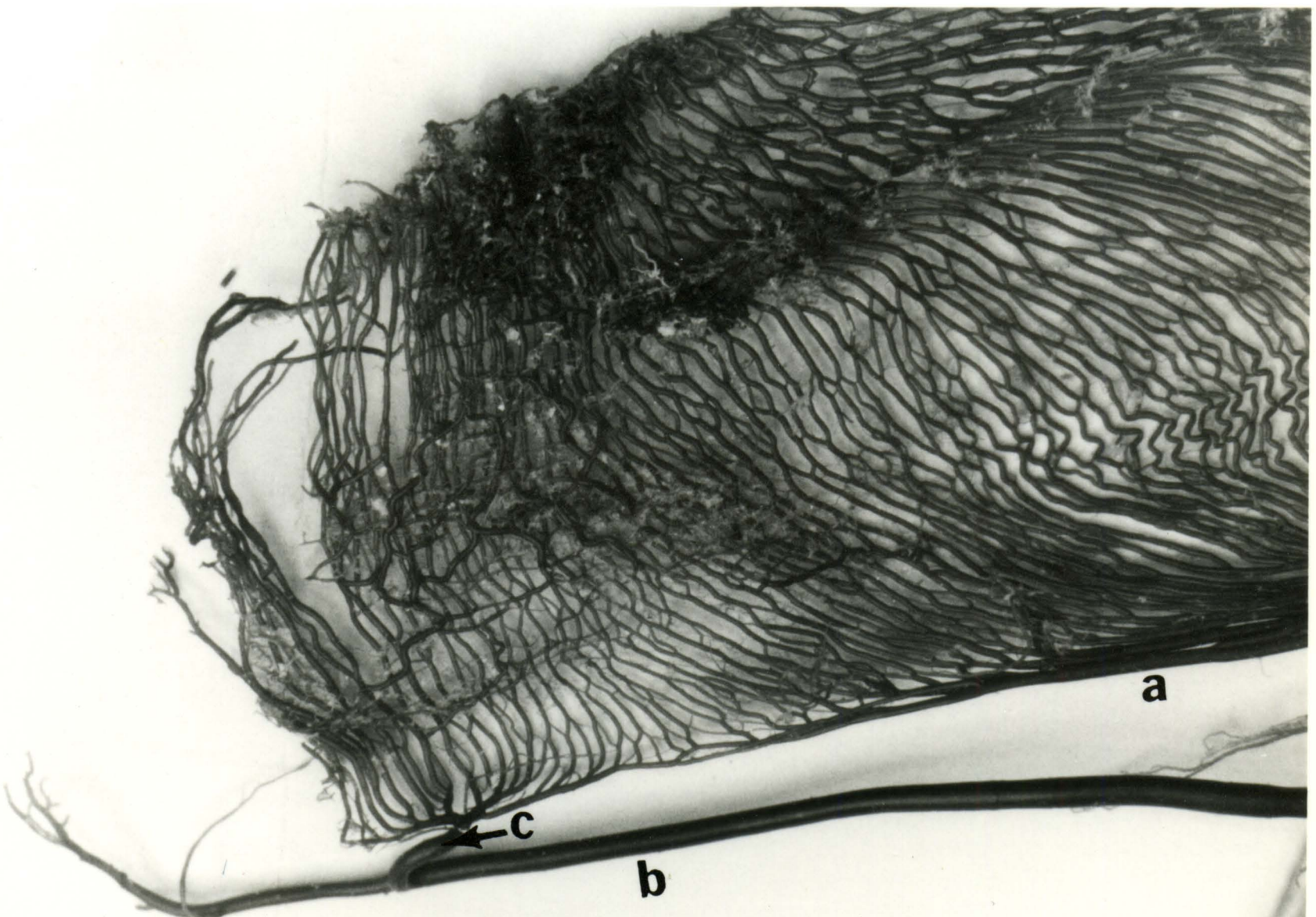
a
c
b

Figure 4. The arterial anastomoses around the tip of the nose and the venous bead-like structures. Batson's #17. Mag. 1.67 times.

a. Infraorbital a.
b. Major palatine a.
c. Palatonasal branch of b
d. Dorsal nasal v.
e. Lateral nasal v. (not injected)
f. Clusters of bead-like structures

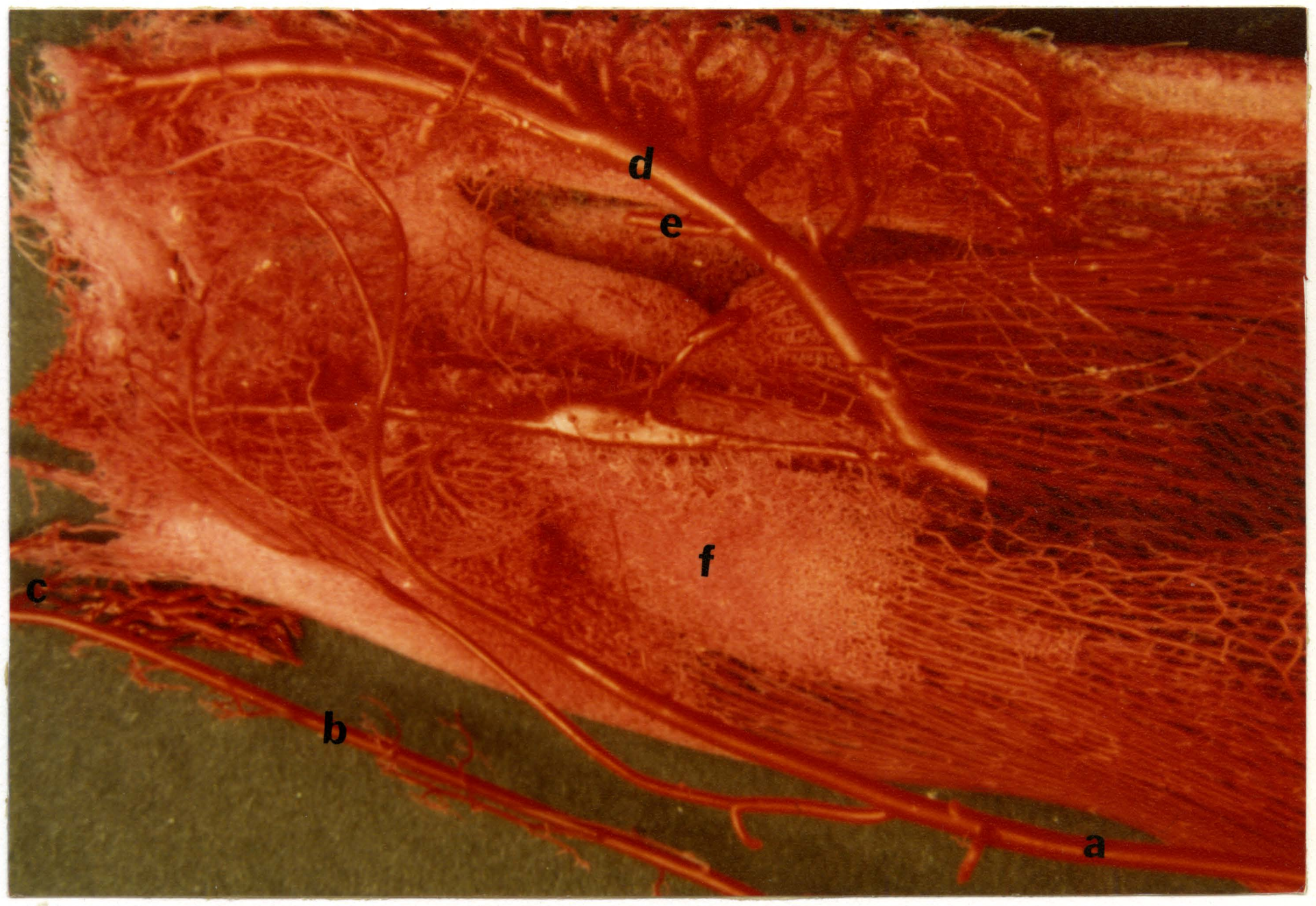
d
e
f
c
b
a

Figure 5. Venous drainage of the nasal cavity of the sheep - lateral view.

1. External jugular v.
2. Occipital v.
3. Linguofacial v.
4. Facial v.
5. Inferior labial v.
6. Deep facial v.
    6a. Rostral branch of 6
    6b. Caudal branch of 6
7. Anastomotic branch with the superficial temporal v.
8. Superior labial v.
9. Medial inferior palpebral v.
10. Common trunk for dorsal and lateral nasal Vv.
11. Lateral nasal v.
12. Dorsal nasal v.
13. Anastomotic branch between the right and left dorsal nasal Vv.
14. Angularis oculi v.
15. Small dorsal nasal v.
16. Anastomotic branch between the right and left angularis oculi Vv.
17. Ventral external ophthalmic v.
18. Malar v.
19. Ophthalmic plexus
20. Infraorbital v.
21. Sphenopalatine v.
22. Major palatine v.
23. Transverse facial v.
24. Plexus of deep facial v.
25. Dorsal external ophthalmic v.
26. Rostral auricular v.
27. Superficial temporal v.
28. Anastomotic branch between 24 and 27
29. Maxillary v.
30. Maxillary v.

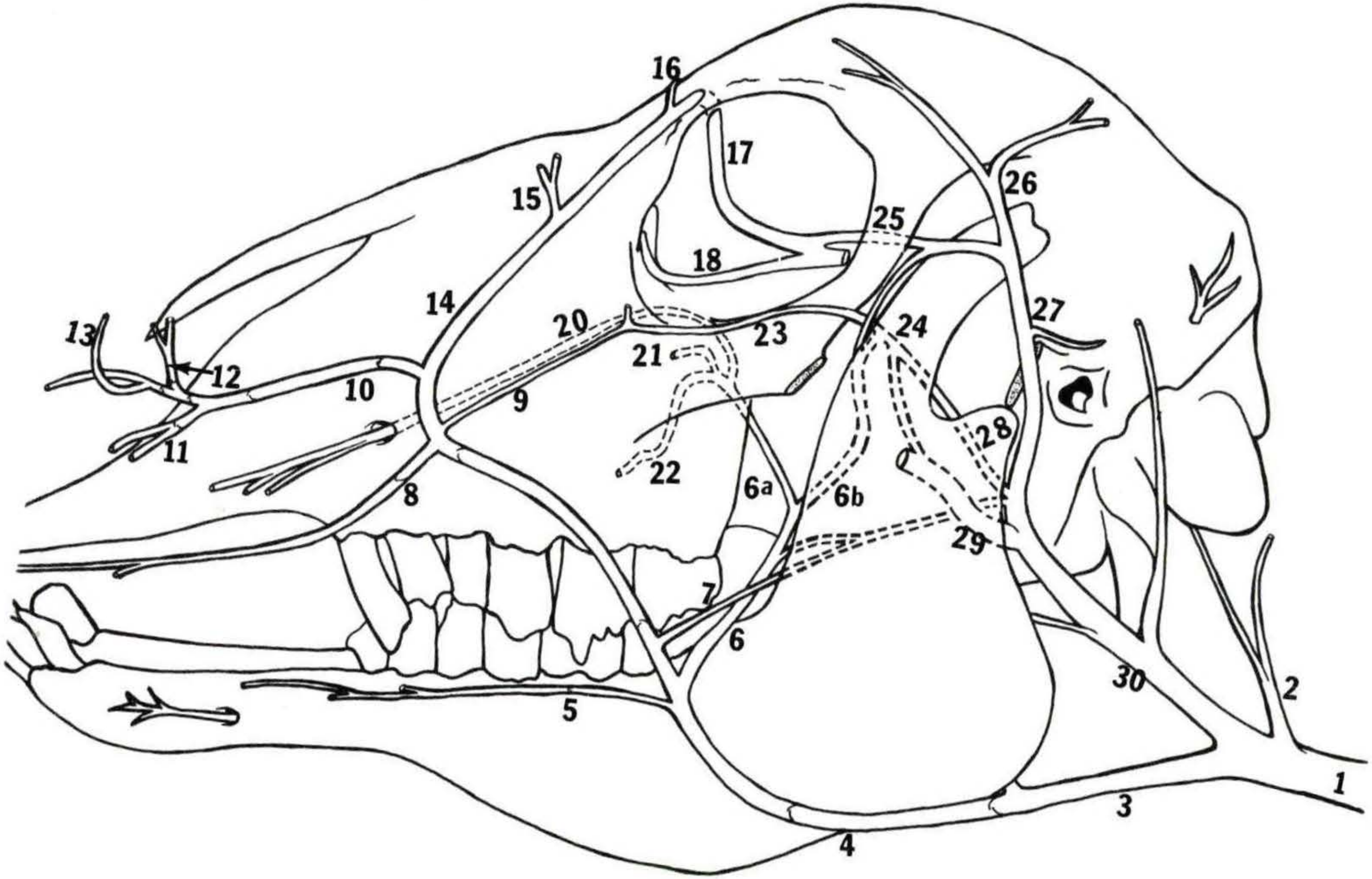
16
17
15
26
25
18
14
13
20
24
27
23
12
21
10
9
28
11
22
8
6a
6b
29
7
6
5
30
2
1
3
4

Figure 6. The cavernous sinus of the sheep - ventral view. Batson's #17. Mag. 3 times.

A. Ophthalmic plexus
B. Cavernous sinus
C. Anastomotic branch between A and B
D. Rostral intercavernous sinus
E. Caudal intercavernous sinus

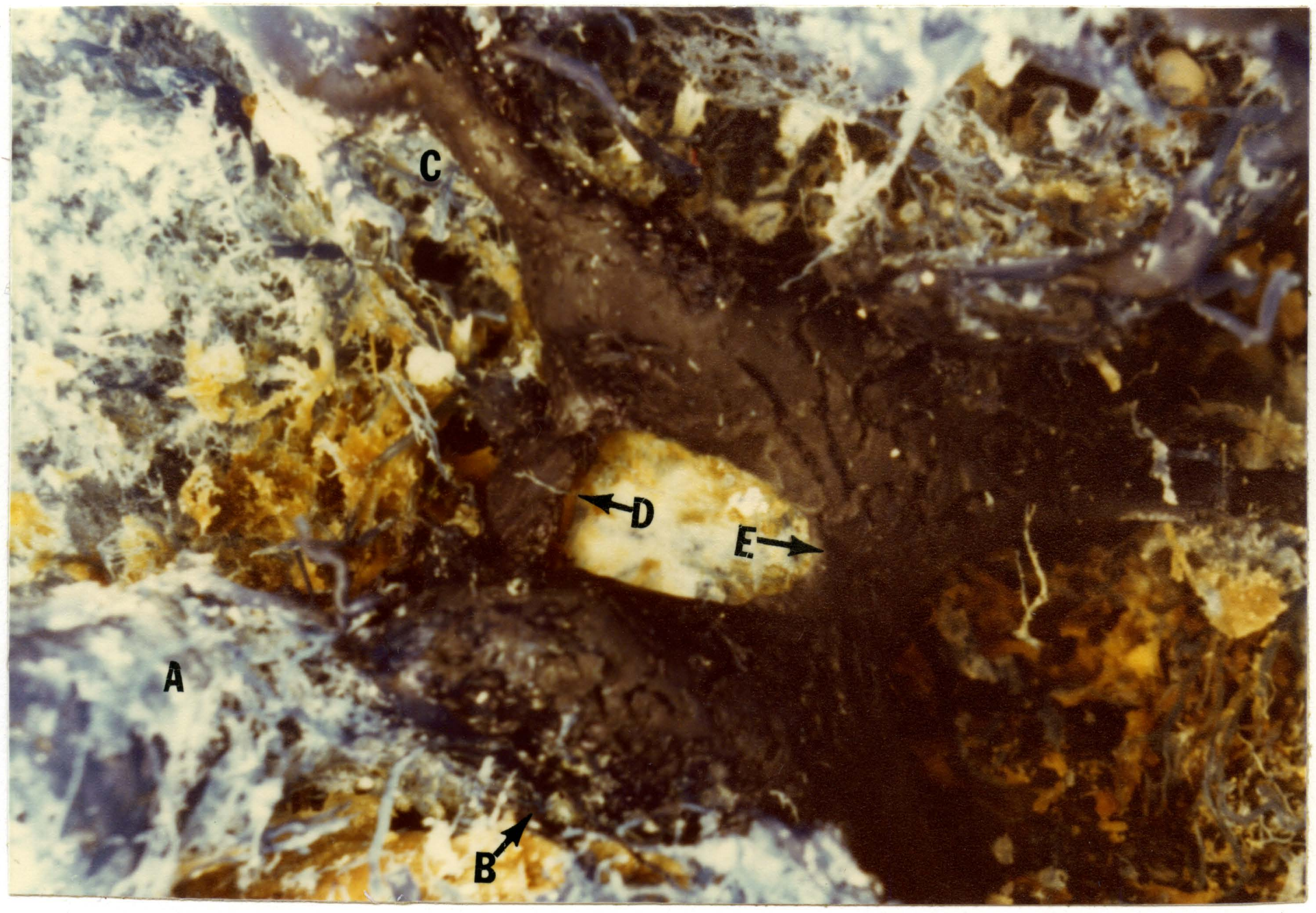
C
D
E
A
B

Figure 7. Venograph of the cavernous sinus - dorsal view.

- A. Angularis oculi v.
- B. Ophthalmic plexus
- C. Cavernous sinus
- D. Anastomotic branch with the pterygoid plexus
- E. Caudal intercavernous sinus
- F. Anastomotic branch with the ventral petrosal sinus

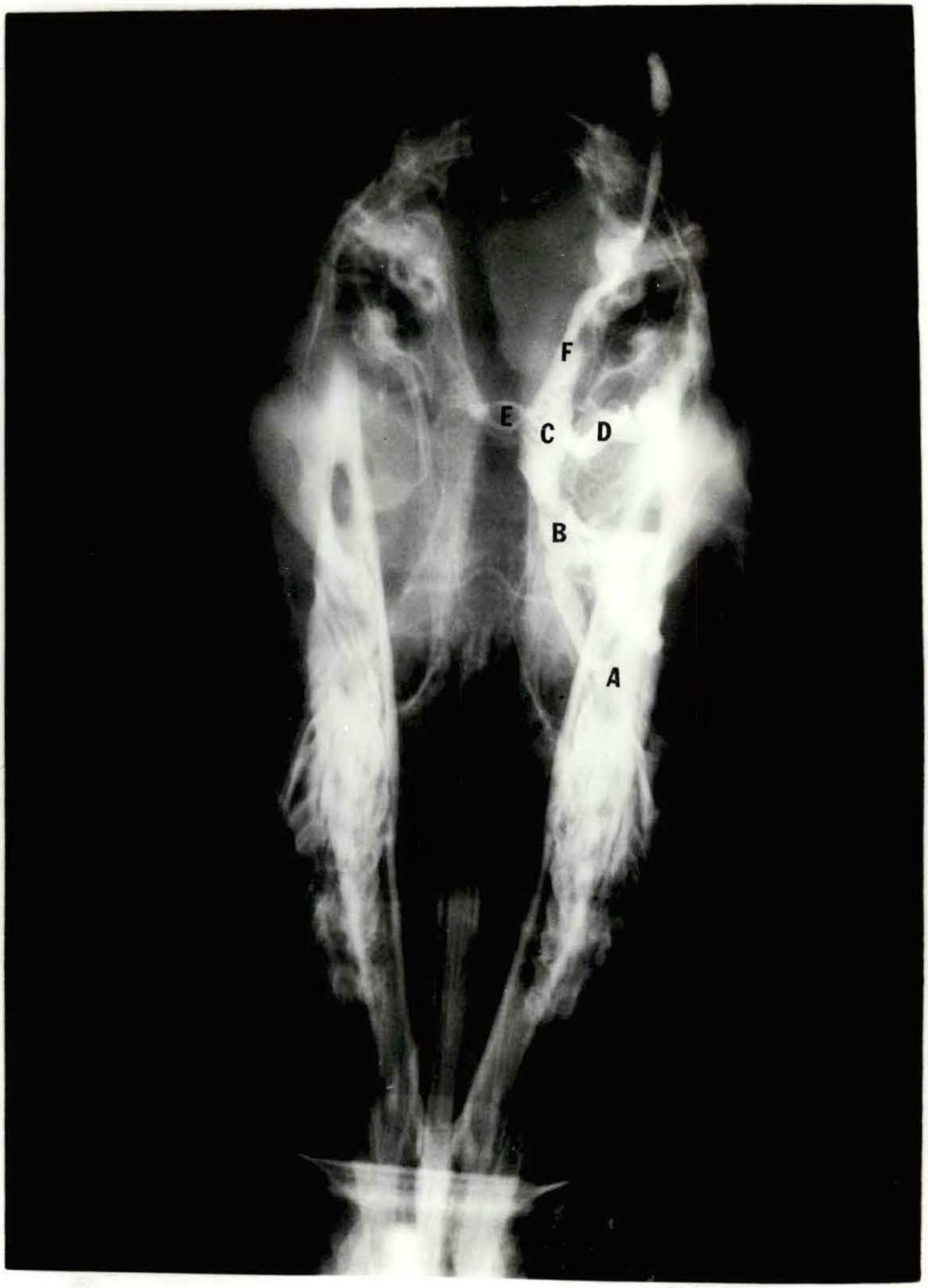
F
E
C
D
B
A

Figure 8. Venograph of both cavernous sinuses of the sheep - dorsal view.

A. Angularis oculi v.
B. Ophthalmic plexus
C. Dorsal external ophthalmic v.
D. Cavernous sinus
E. Anastomotic branch with the pterygoid plexus
F. Caudal intercavernous sinus
G. Anastomotic branch with the ventral petrosal sinus

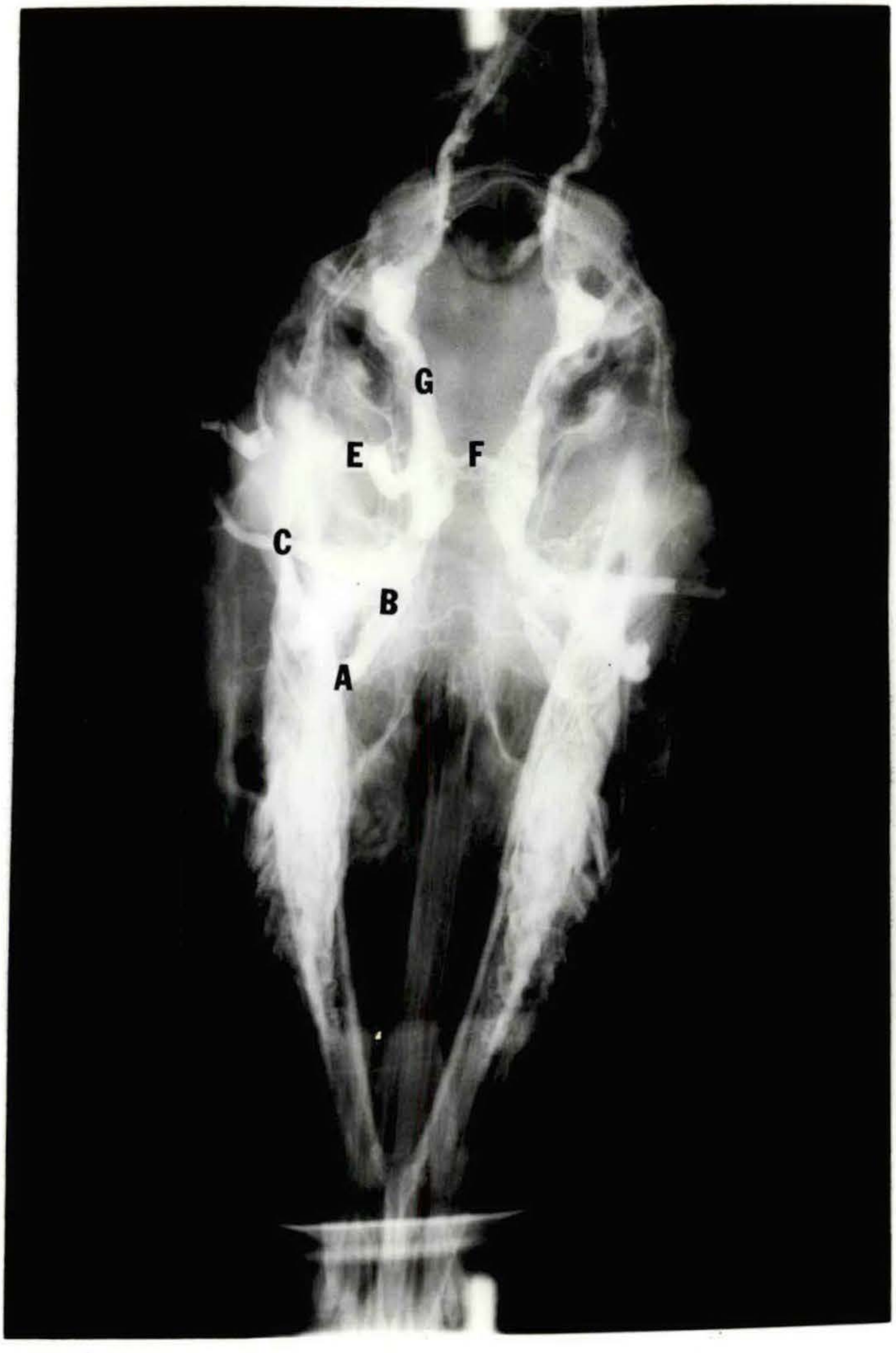
G
E
F
C
B
A

Figure 9. Spetal alar fold region showing mixed glands, predominantly serous. Harris' hematoxylin and eosin stain. Mag. 64 times.

a. Serous acini
b. Mucous acini

Figure 10. Thin-walled artery and thick-walled veins in the alar fold region. Weigert's resorcin fuchsin stain. Mag. 64 times.

a. Thin-walled a.
b. Thick-walled v.

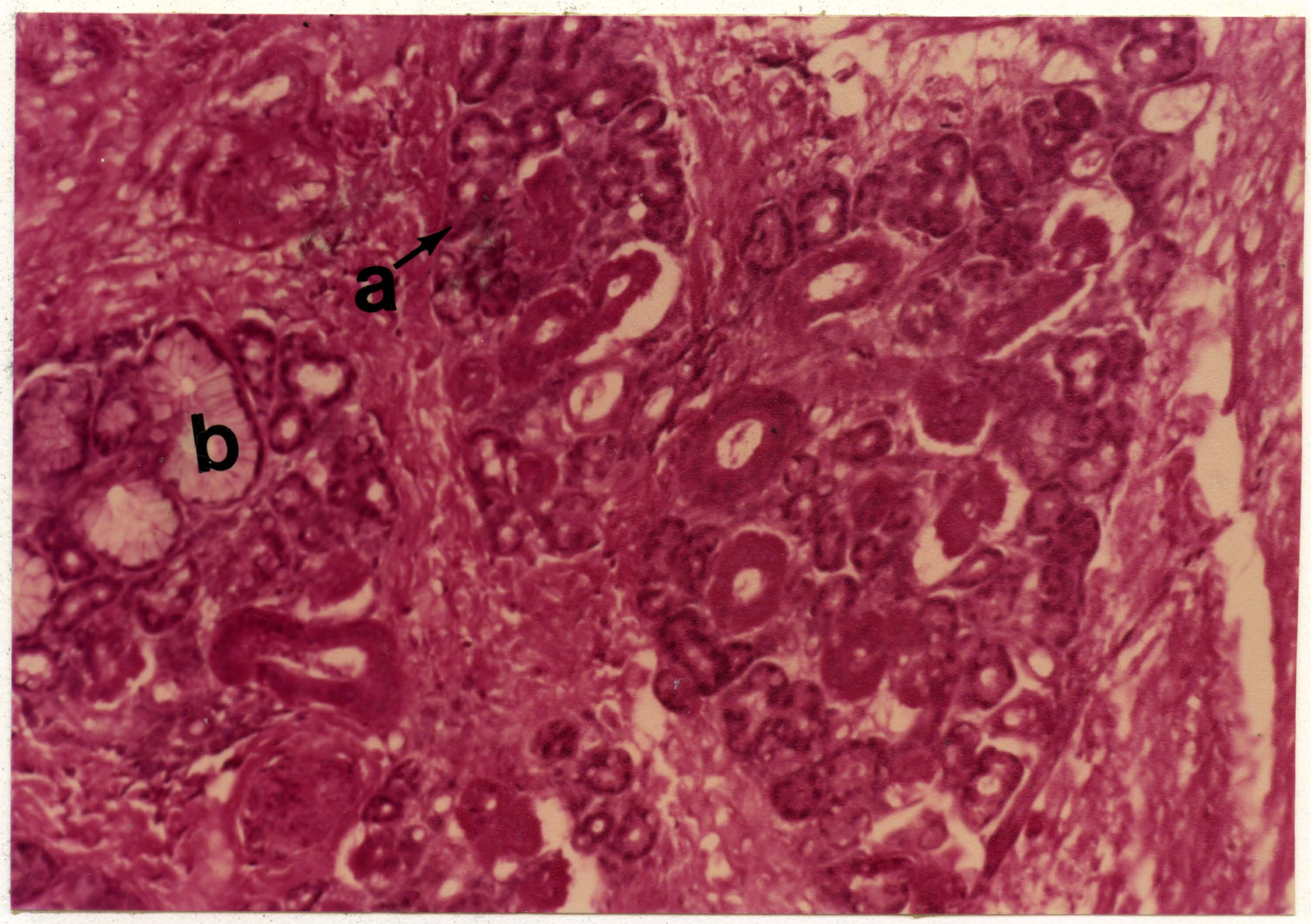
a
b

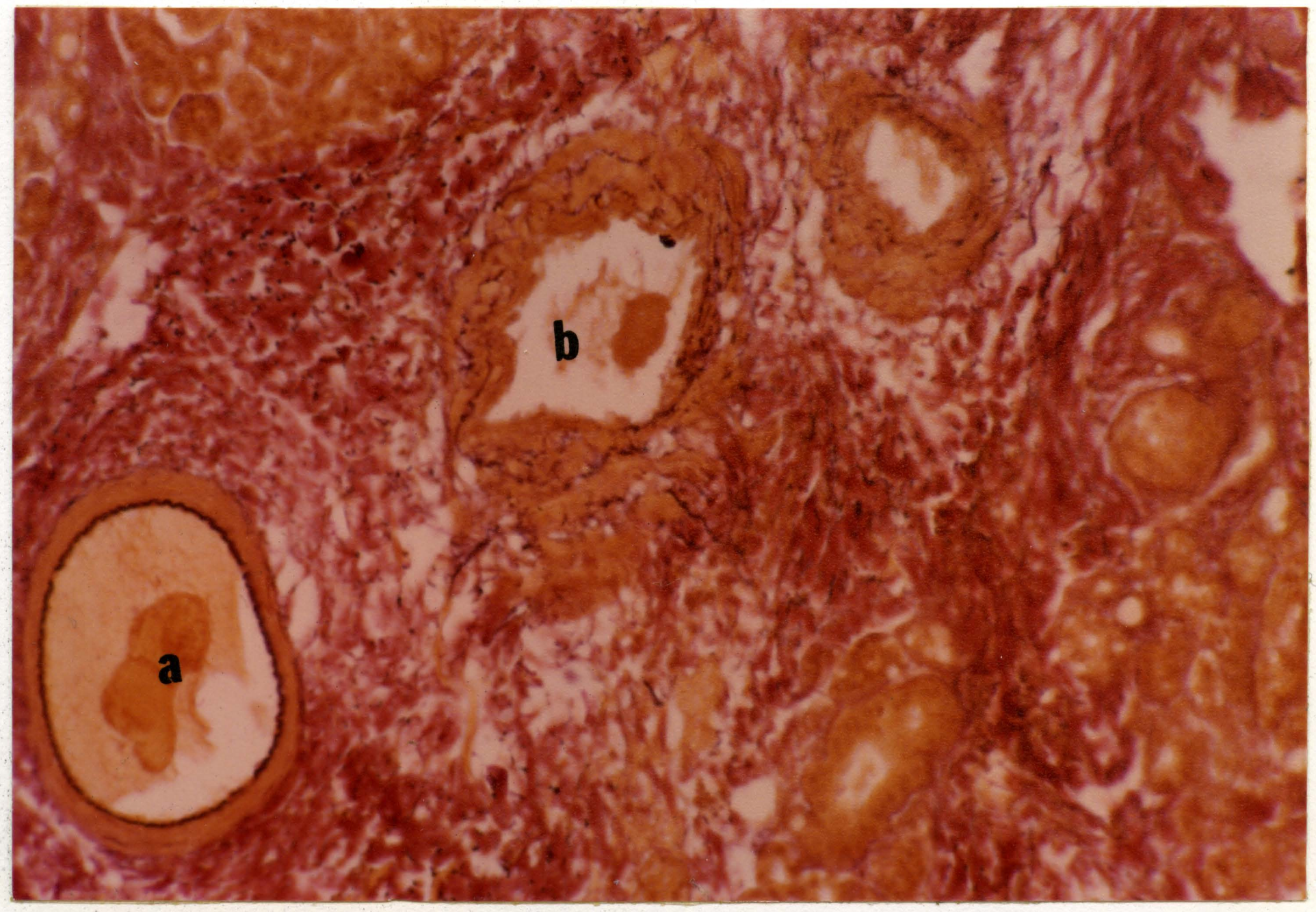
b
a

Figure 11. Thick-walled veins in the alar fold region and notice the presence of mixed glands - predominantly serous. Harris' hematoxylin and eosin stain. Mag. 160 times.

a. Thick-walled v.
b. Serous acini
c. Mucous acini

Figure 12. Premolar region showing thick-walled arteries and thin-walled veins. The upper side facing the airstream while the lower side facing the conchal sinus. Notice the scarcity of glands and blood vessels on the surface facing the conchal sinus. Van Gilsen's stain. Mag. 25 times.

a. Thick-walled a.
b. Thin-walled v.

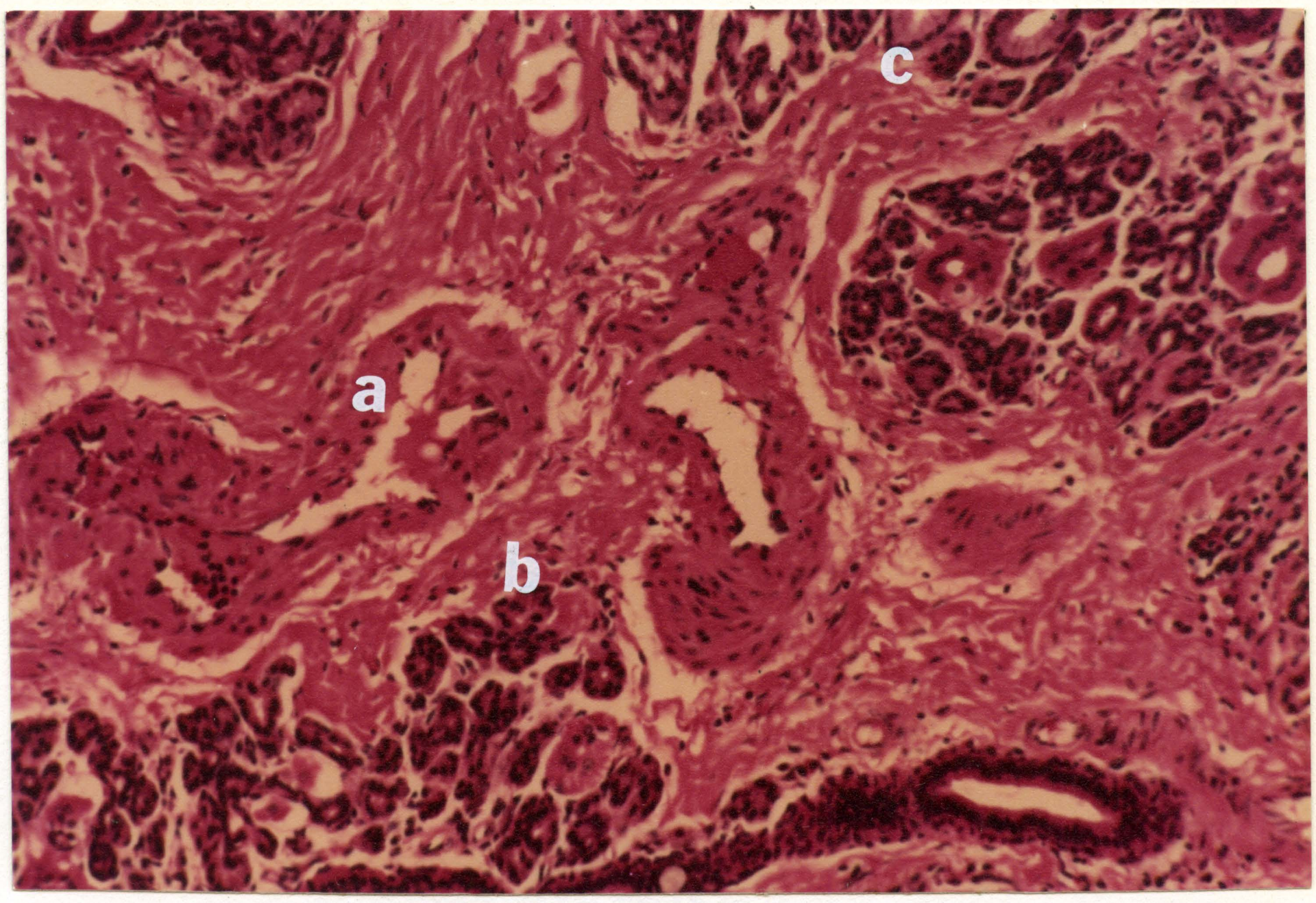
c
a
b

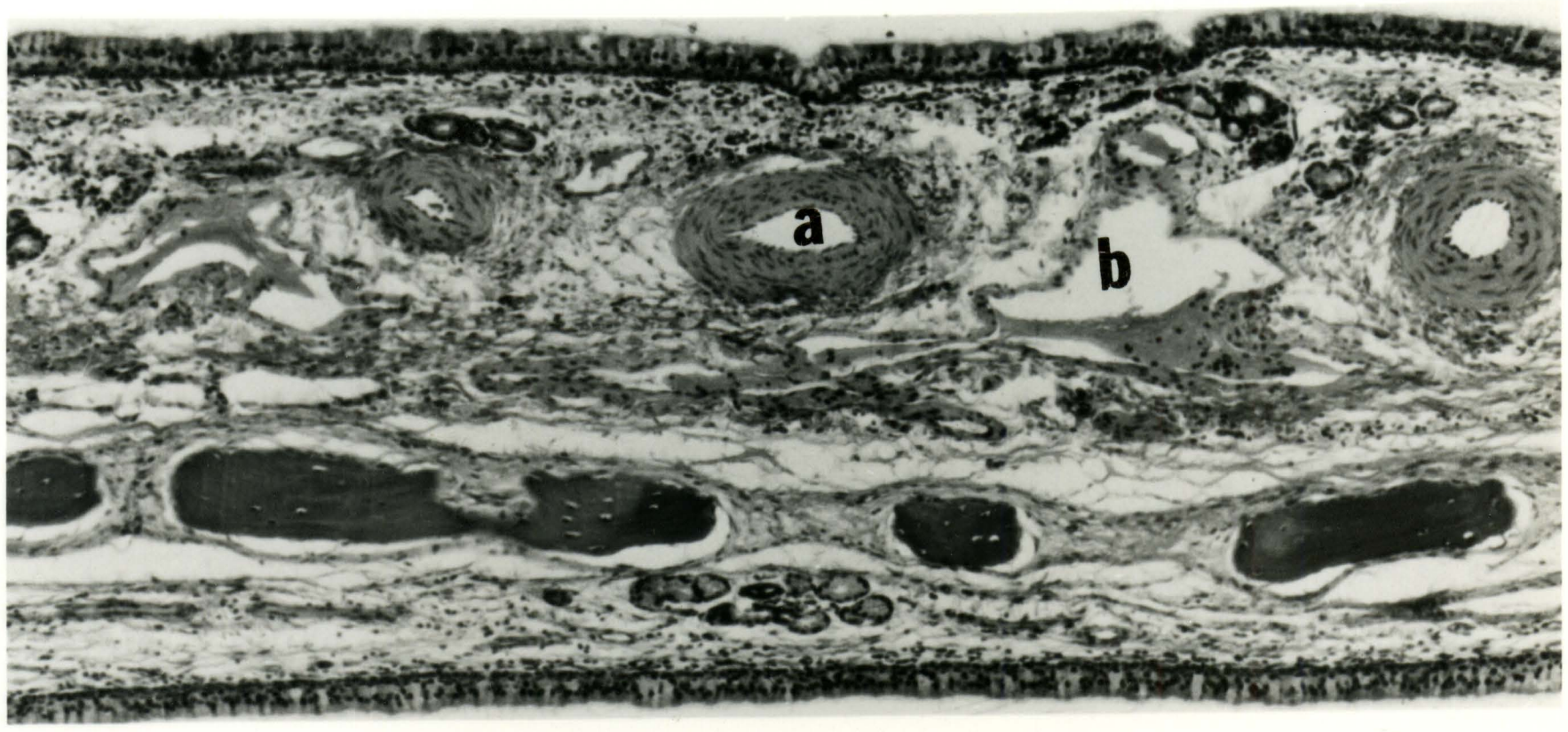
a
b

Figure 13. Large numbers of veins around an artery along the convex contour of the conchal cartilage facing the airstream in the premolar region. Weigert's resorcin fuchsin stain. Mag. 160 times.

a. Vein
b. Artery

Figure 14. Mixed glands - predominantly mucous in the last molar region showing also the deeply situated arteries surrounded by thin-walled veins. Harris' hematoxylin and eosin stain. Mag. 25 times.

a. Artery
b. Vein

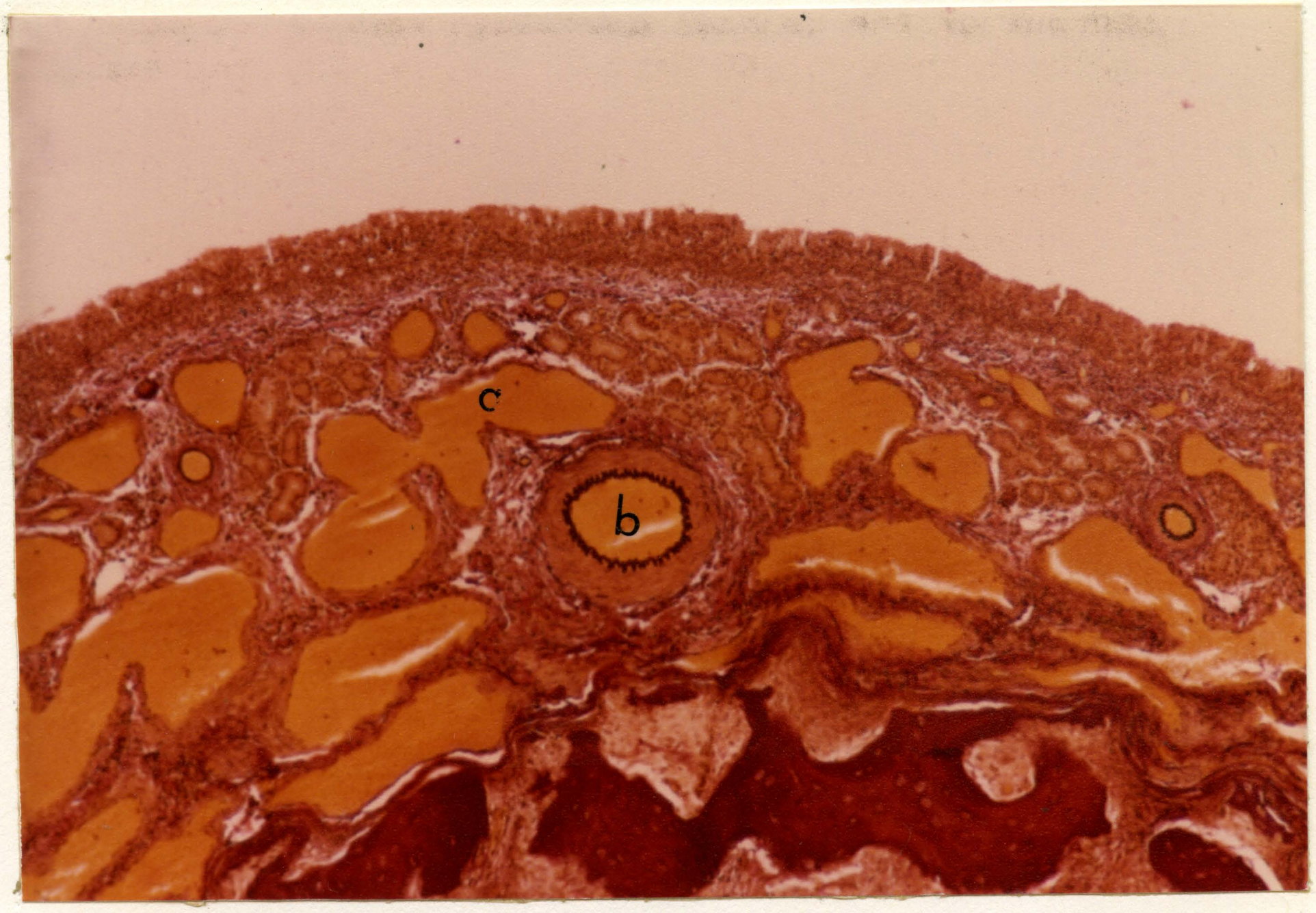
c
b

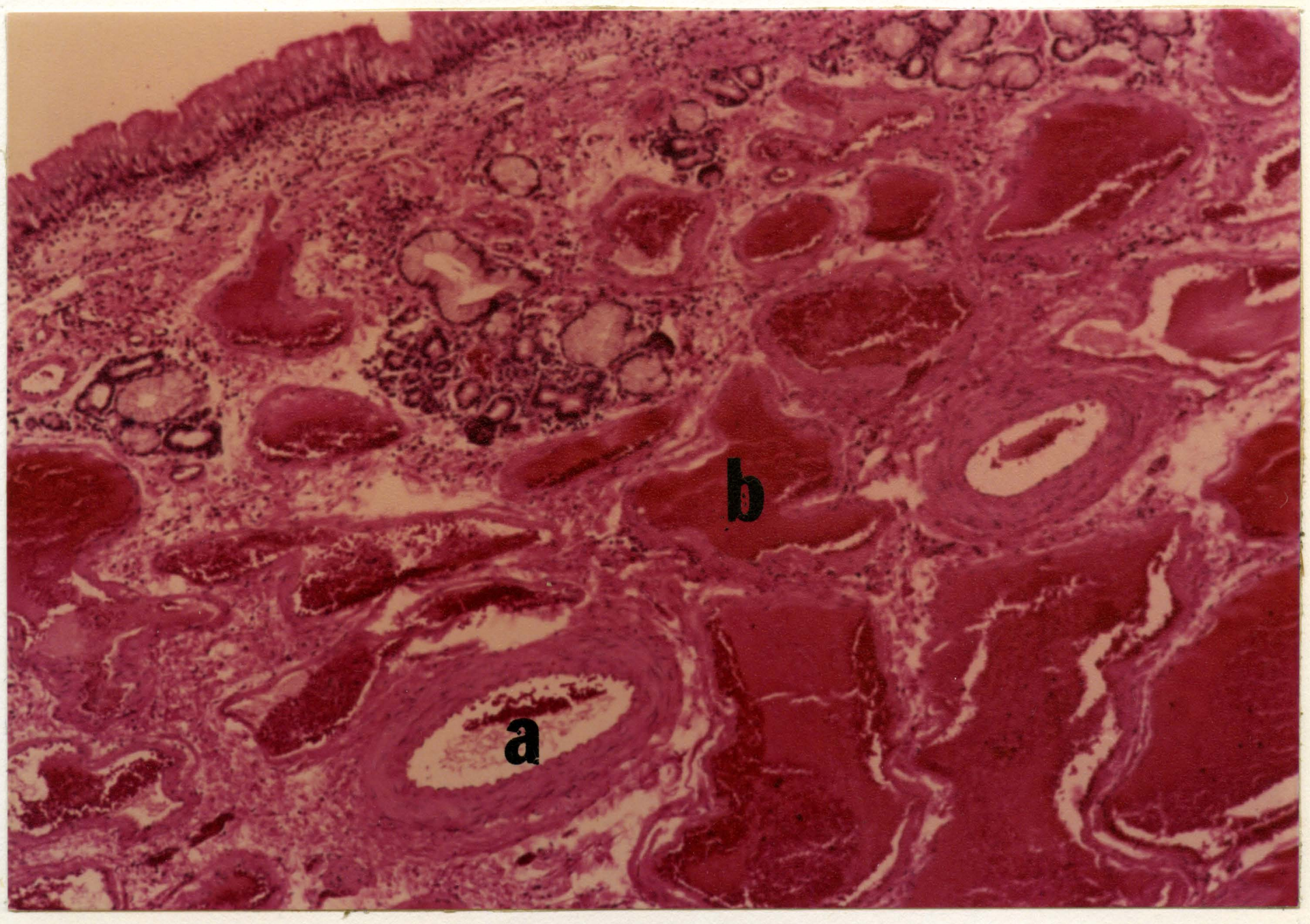
b
a

Figure 15. Cross section of the wall of the angularis oculi vein showing the inner longitudinal muscle layers in the tunica media. Van Giesen's stain. Mag. 160 times.

Figure 16. Presence of a valve in the wall of the dorsal nasal near its junction with the angularis oculi vein. Harris' hematoxylin and eosin stain. Mag. 64 times.

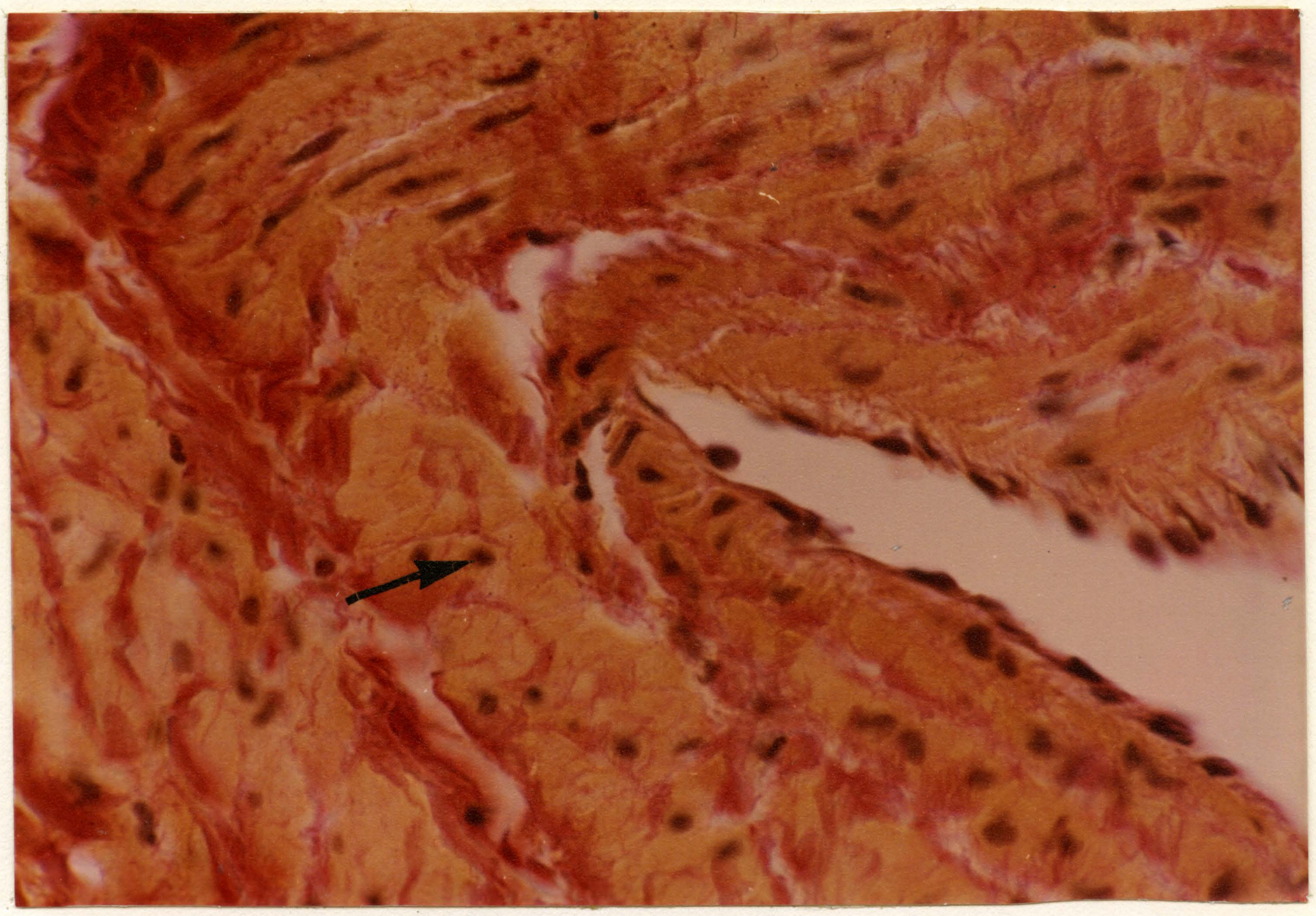

Figure 17. Arteriovenous anastomosis in the septal part of the premolar region showing the epithelioid cells in the wall. The section is passing twice through the arteriole. Harris' hematoxylin and esoin stain. Mag. 160 times.

a. Arteriole
b. Epithelioid cells

Figure 18. Arteriovenous anastomosis in the septal part of the last molar region showing the epithelioid cells in the wall of the arteriole. Van Giesen's stain. Mag. 400 times.

a. Arteriole with epithelioid cells
b. Venule

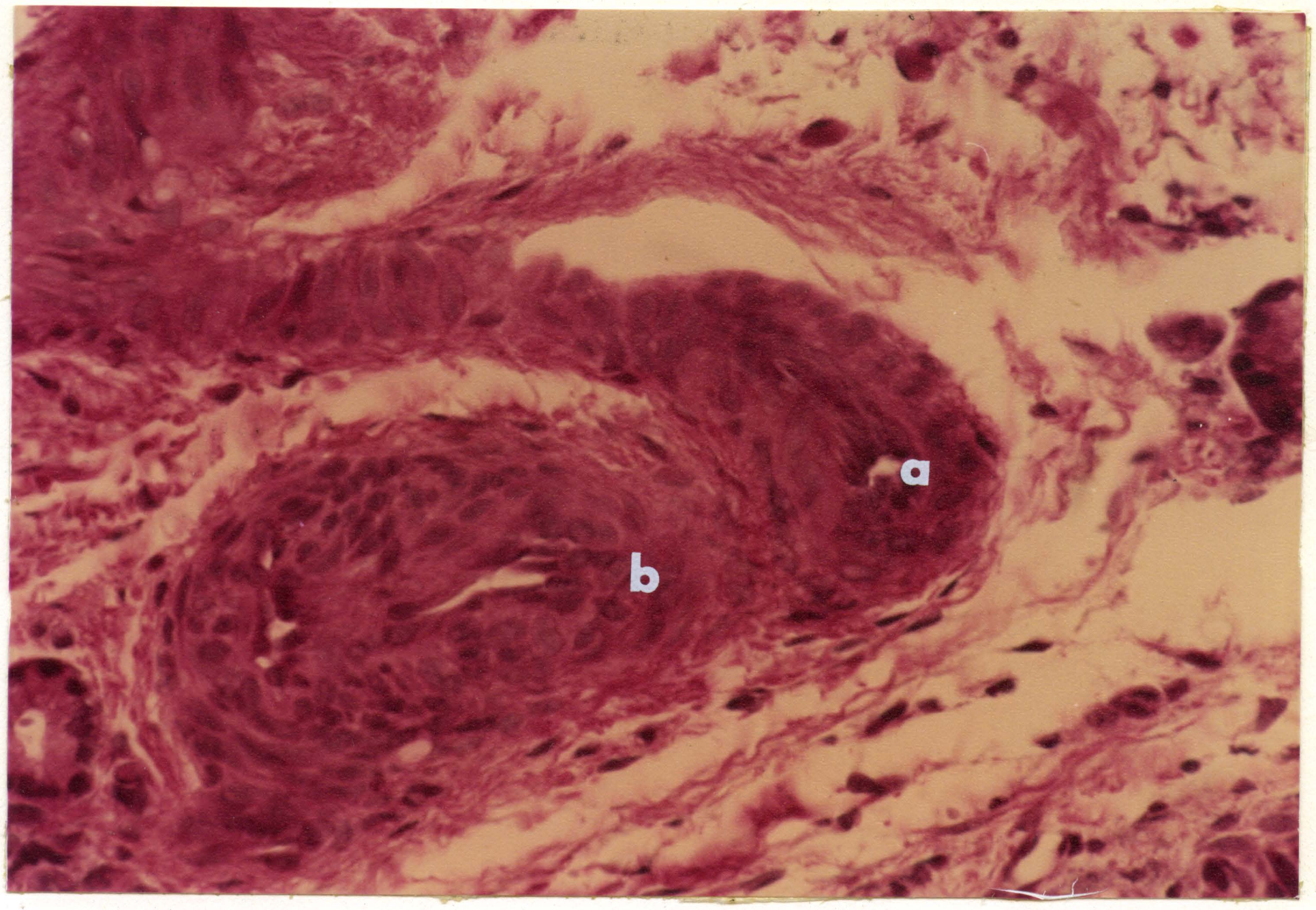
a
b

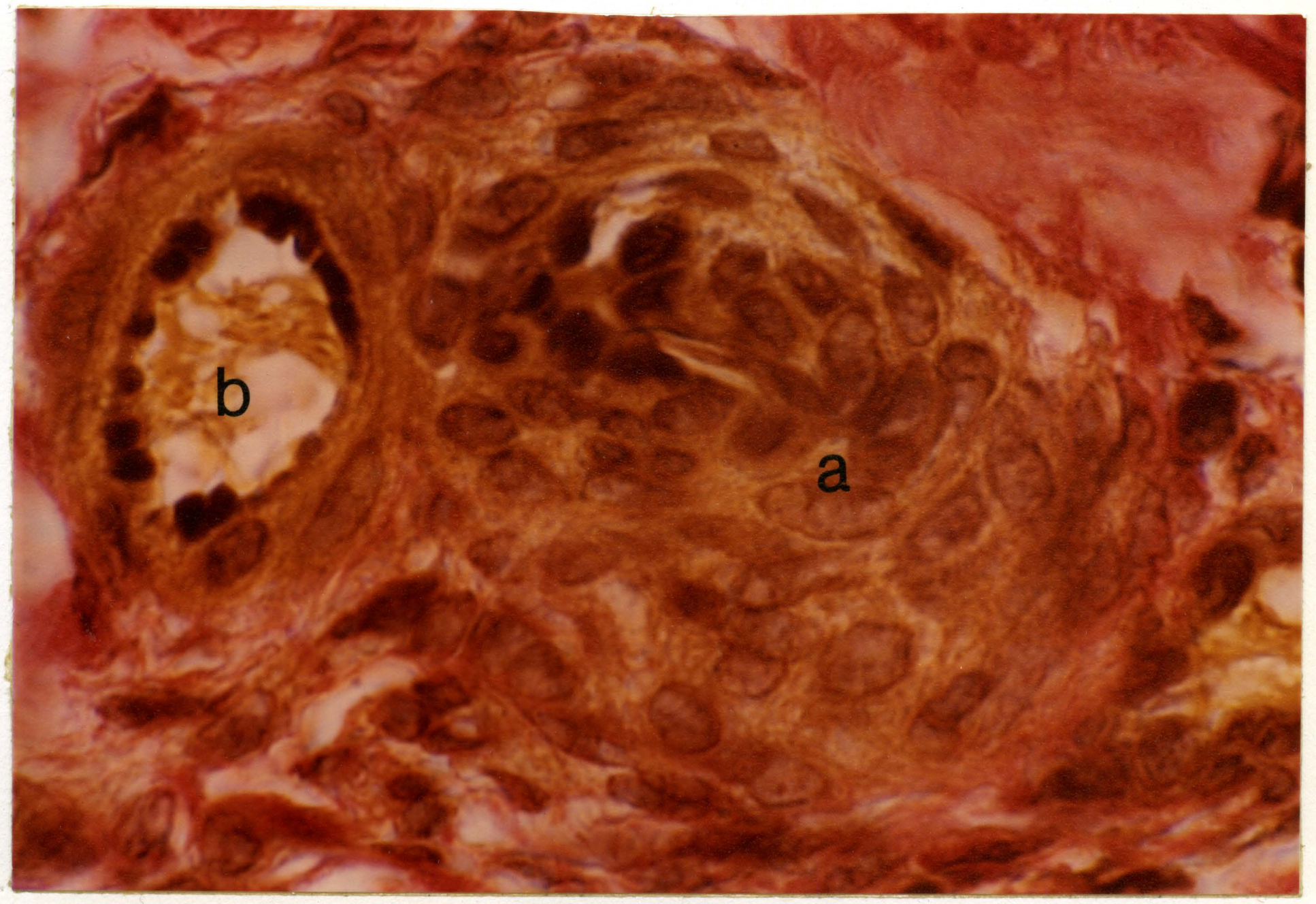
b
a

Figure 19. Arteriovenous anastomosis in the alar fold region showing the direct connection between the venules and the arterioles. Masson's trichrome stain. Mag. 64 times.

a. Arteriole
b. Venule

Figure 20. Intraarterial bolster in the premolar region. Harris' hematoxylin and eosin stain. Mag. 160 times.

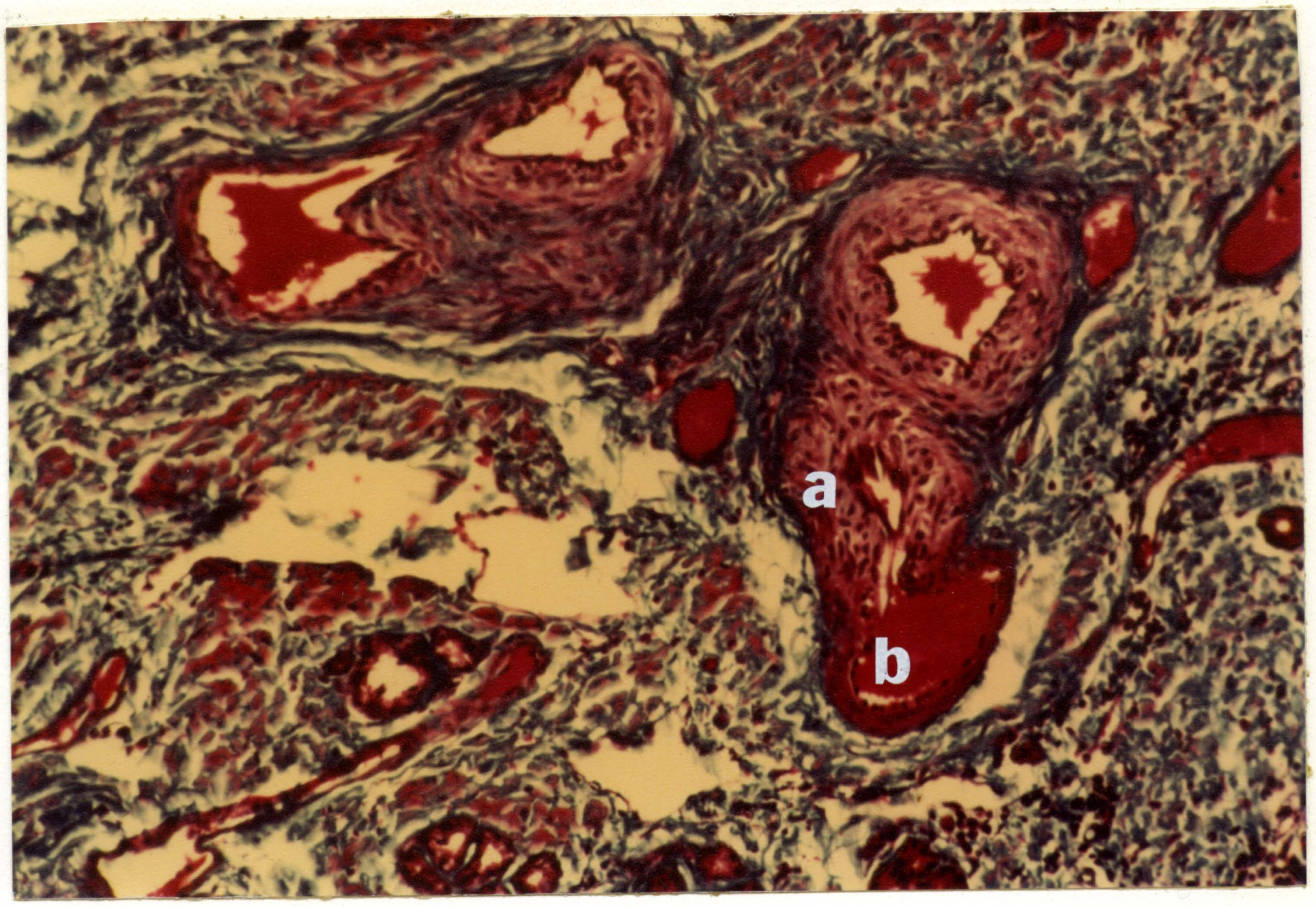
a
b

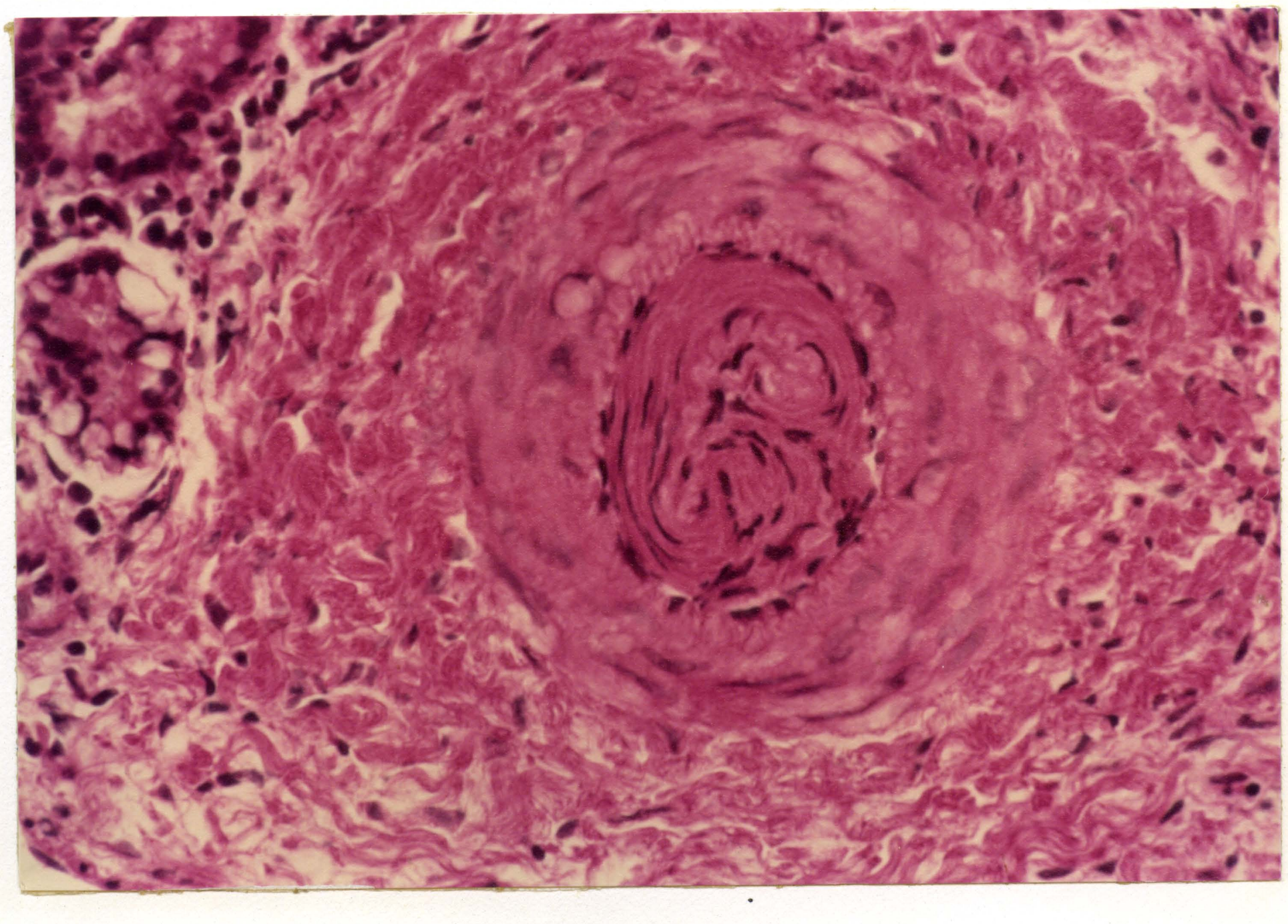

Figure 21. Free smooth muscle cells in the propria submucosa of the premolar region surrounding the veins. Harris' hematoxylin and eosin stain. Mag. 160 times.

Figure 22. Free smooth muscle cells in the propria submucosa of the premolar region, mostly surrounding or in between thin-walled veins. Harris' hematoxylin and eosin stain. Mag. 64 times.