

SF911
J453C
c. 2

CANINE AUTOGENOUS SKIN GRAFTING

by

Elroy Clarence Jensen

A Thesis Submitted to the
Graduate Faculty in Partial Fulfillment of
The Requirements for the Degree of
MASTER OF SCIENCE

Major Subject: Veterinary Medicine and Surgery

Signatures have been redacted for privacy

Iowa State College

1958

1493999

TABLE OF CONTENTS

	Page
I. INTRODUCTION	1
II. REVIEW OF LITERATURE	4
III. METHODS AND PROCEDURE	12
A. Surgical Procedures	12
1. General considerations	12
2. Preoperative preparation	13
3. Operative techniques	15
(a) Series 1	15
(b) Series 2	20
(c) Delayed transfer of tube grafts - series 2	21
(d) Immediate transfer of tube grafts - series 2	28
(e) Series 3	29
(f) Series 4	35
(g) Series 5	41
(h) Series 6	46
IV. OBSERVATIONS	48
A. Series 1	48
B. Series 2	51
1. Delayed transfer of tube grafts	51
2. Immediate transfer of tube grafts	61
C. Series 3	67
1. Grafts applied to non-granulating lesions	67
2. Grafts applied to granulating lesions	74
D. Series 4	77
E. Series 5	83
F. Series 6	89
V. DISCUSSION	106
VI. CONCLUSIONS AND SUMMARY	114

	Page
VII. LITERATURE CITED	116
VIII. ACKNOWLEDGMENTS	119

I. INTRODUCTION

The use of plastic surgery to correct defects arising from extensive injuries to the integument is common in the human species. Much of the experimental work has been done on laboratory animals for the development of techniques which would be applicable to the human patient. However, little recorded work has been attempted in the surgical correction of clinical cases pertaining to the canine species concerning injuries to the skin which result in objectionable scars, deformities and areas which fail to resist trauma satisfactorily when healed. With the possibilities of dermal injuries to the dog increasing each year as a result of present day mechanization, more dogs are suffering severe injuries which when left to the normal physiological processes associated with healing leave a very objectionable cosmetic appearance. Removal of neoplasms, extensive burns and perivascular necrosis resulting from faulty administration of drugs may cause unsightly scarring of valuable dogs.

Because of the relatively loose skin on the dog in regions of the neck, thorax, flank and lumbar region, skin grafting is seldom indicated in these areas. Undermining of the skin and "skin shifting" suffices unless the wound is exceptionally large. The skin of the legs and around the face does not lend itself to this "skin shifting". It is in these

areas that a satisfactory technique for skin grafting would be of value.

There are several factors which make this type of surgery difficult in the dog. Surgery of this nature is naturally time consuming for the surgeon, requires considerable hospitalization of the patient and is costly for the client. Thus, economics becomes a factor. Also, trying to get the cooperation of the patient is most difficult, so restraint is a major problem. Because of the above mentioned factors, dermal autogenous grafting in the dog from a clinical standpoint has been discouraged. With these difficulties in mind, the investigation of a practical method for skin grafting in the dog was undertaken.

There are several histological factors which have made skin grafting possible in man and animals. First, there is the comparative ease with which epithelium can regenerate. This new growth of tissue occurs either from the periphery of a wound or it may result from proliferation of the external root sheath of the hair follicles providing the dermis has not been completely destroyed. Another feature of skin is that its constituent cells may be kept alive for several days by means of the tissue fluid, from below the graft, by the process of osmosis. This affords sufficient time for new vessels to be formed which will then nourish the skin. The ability of the capillaries to proliferate and then anastomose

with those of the graft makes skin grafting possible. It is only because of these physiological processes that this type of surgery is successful.

II. REVIEW OF LITERATURE

According to Neuhof (1923) the first attempts at skin grafting were made centuries ago by some members of the tile makers caste in India. They used pedunculated skin flaps from the forehead and cheek to reconstruct the nose. The use of this type of graft has since been called the Indian method of rhinoplasty. Neuhof related that in 1597 Gaspar Tagliocozzi modified the method of rhinoplasty so as to transplant the skin from the arm instead of from the forehead. This method is now known as the Italian method of rhinoplasty.

Neuhof further stated that free skin grafting started early in the nineteenth century by two charlatans. The first one was a woman named Gamba Curta. In order to show the efficacy of an ointment she was selling, she cut a piece of skin from her thigh, passed it around amongst the crowd for inspection, then replaced it on its original bed and dressed the area with the ointment. By the next evening the transplant was so well healed that no further dressing was necessary. The other charlatan, as related by Neuhof, was a man who sold an ointment described as a cure for all ills and called by him "The ointment of the French Army". This man cut a large piece of skin, including some of the underlying muscle from his forearm, held it up for the spectators to observe, replaced it and then dressed the wound with the ointment. Eight days later the scar of the wound could scarcely

be seen. Maltz (1946, p. 221) related in his book "Evolution of Plastic Surgery", that the above named incidents suggested to Guiseppe Baronio in 1804 a series of autografts on sheep. Maltz stated that Baronio carried out a series of successful experiments on animals (mostly sheep) transplanting pieces of skin 12.5 cm. by 7.5 cm. In his first experiment two portions of skin of equal size and free from subcutaneous tissue were removed from the sides of the root of the tail of a sheep. The pieces were transferred immediately to the opposite sides of the tail. In his second experiment, which was similar, he transferred the pieces of skin after an interval of 18 minutes. In his third experiment Baronio procured a larger piece of skin (5 in. by 5 in.) and included the subjacent tissue with a small muscle fragment. This was transplanted in one hour.

May (1947, p. 19) stated that skin grafting was a development of the nineteenth century. He further stated that Reverdin in 1869 put skin grafting on a scientific basis. Reverdin (1869) reported taking small pieces of epidermis from a patient's right arm and transplanting them to a granulating surface on the left arm. Reverdin (1872) reported that the title "epidermic grafts" was not perfectly correct as the transplanted bit was composed of the whole epidermis and a very small amount of the dermis. The tiny grafts of Reverdin were gradually superseded by larger grafts of the same thick-

ness. Lawson (1870) reported that pieces of skin the size of sixpence could easily be grafted on granulating surfaces. Ollier (1872) reported the use of pieces of skin, 4 cm. to 8 cm. square and larger, which included not only the superficial layers of the skin but a thin layer of the dermis. Thiersch (1874) suggested the use of strips of skin about 1 cm. in diameter of similar thickness as those reported by Ollier. Twelve years later he modified his technique by using larger strips of skin. Maltz (1946, p. 260) stated that the names of Ollier and Thiersch have been used to designate the type of graft which contains the epidermis and only a small portion of the dermis. Wolfe (1876) reported the successful use of a full thickness graft. Krause (1893) reported his perfected method of whole thickness grafts on 21 cases. Davis and Davis (1949, p. 56) stated that free whole thickness grafts were called Wolfe-Krause grafts in honor of these two men. Davis (1914) introduced the small deep graft which was similar to Reverdin's idea, but included the full thickness of the skin at its center, tapering off toward the periphery.

Davis (1925) in an editorial entitled "The Nomenclature of Skin Grafting" listed and defined the four skin grafts commonly used today. He defined a skin graft as a mass of tissue cut free to be transplanted where desired and receives its blood supply from the surface on which it is placed. He enumerated and defined the following types of grafts: (1)

Reverdin graft or "pinch graft" which is 3 mm. to 5 mm. in diameter and consists of the epidermis and a very small amount of the dermis; (2) "small deep graft" which is about the same size as the Reverdin, but includes almost the entire thickness of the corium at least in the center; (3) Wolfe-Krause or the "whole thickness graft" which includes the entire skin; and (4) the Ollier-Thiersch or split thickness graft which consists of the epidermis and only a portion of the dermis.

Davis and Davis (1949, p. 39) stated that a pedicled or tubed flap was

. . . a mass of tissue which is attached at some portion of its periphery or base by a pedicle through which it receives its blood supply and which can be shifted only as far as its pedicle will allow.

Just what occurs after a graft has been transplanted on a recipient area was studied by Davis and Traut (1925) who were interested in whether vessels of the graft anastomosed with those of the grafted area; whether capillaries of the grafted area grew into the graft by extending into the old vessels of the graft, or whether capillary up growth from the grafted areas penetrated the connective tissue of the transplant and thus established a blood supply. This work was done on dogs in which they removed grafts 3 cm. long by 1 1/2 cm. wide, suture skin to muscle and then closed the wound edges over the graft to apply pressure to the new transplants. Davis and Traut found that a fibrin network was formed in just a few hours. During the next 24 hours there was migration of

round cells and wandering cells from the graft bed in the fibrin and then into the graft. These cells found their way into the connective tissue stroma and all parts of the corium but not into the epidermis. During the same 24 hours there was a development of highly vascular granulation tissue which replaced the fibrin network. As a result, the graft rested on rich newly formed capillaries transporting blood 18-24 hours after transplantation. There were also some degenerative changes. The epidermis sloughed down to the Malpighian layer. The endothelium of the blood vessels degenerated except in an occasional area. Hairs and sebaceous glands were only slightly affected. The degenerative process occurred up to 7-8 days. This seemed to be the turning point since the first vascularization reached all of the parts about that time. The first blood supply was formed by an anastomosis of vessels of granulation tissue to those of the graft. Davis and Traut also found that the first blood supply took place in this way as early as 22-72 hours. The second means of blood supply was slower, according to these authors, but a more voluminous blood supply occurred by the upward growth of capillaries of granulating tissue which developed loops and penetrated the connective tissue of the corium. They further stated that most of the vascularization was in this way. Invading loops reached the Malpighian layer by 12 days and were more numerous in normal skin and less numerous in

older grafts because of some degeneration. The third means found by Davis and Traut was by the sprouting capillaries in the granulating tissue. The capillaries found their way inside the old vessels of the graft and grew rapidly due to less resistance than found in the connective tissue stroma. They found that this only occurs occasionally and that large vessels of the graft were usually absorbed after transplantation. These authors also found that the earliest time in which circulation in the graft was demonstrated was at the end of 22 hours. They stated that adequate circulation was not established until the end of 8 days. During the interim the graft was nourished by a plasmatic circulation and by early anastomosis of small capillaries.

Very little veterinary literature is available concerning skin grafting, in either the dog or cat. Self (1934) reported the use of small pin point or small deep grafts on 5 dogs in which he reported the results as being successful. Small grafts about the size of grains of rice, consisting of the epidermis and part of the dermis, were removed with a straight suture needle inserted into the donor skin area, lifted slightly upward, the small tuft of skin then severed with a razor blade and placed on the granulating wound. He stated that the grafts must be placed one-half inch or less apart as each "seed" only grows to about the size of a dime. A sterilized rubber sponge was cut to fit the area and then sutured

to the surrounding skin. Adhesive tape was then applied over the sponge and encircled the body or limb of the dog as indicated. The sponge was moistened daily with saline. The bandages were removed in 10 days.

Keefe (1946) reported the use of one immediate pedicle and one delayed graft to cover a denuded area on the left hind leg of a cat. He stated that the use of these grafts was only partially successful as a large granulating wound still remained. His final operation consisted of pin point grafts which were placed on the granulating area. At the end of 10 days the area was completely covered with epithelium. Keefe concluded that the pin point grafts were much simpler and gave quicker results than did the pedicle method.

Armistead (1956) reported the use of full thickness skin grafts removed from the medial surface of the thigh from three dogs. These grafts were used in the abdominal cavities to seal and reinforce intestinal anastomoses in each of the 3 animals. He concluded that the use of a strip of skin to reinforce an intestinal anastomosis was successful and appeared to have practical advantages.

Markowitz (1954) commented on skin grafting in the dog in which he stated that it was interesting to remove a section of skin, rotate it one-half turn and then note the change in the direction of the hair growth following the healing of the graft.

Riser (1957) stated that in the dog the skin graft has very little practical value.

Jensen (1957) reported the use of 14 delayed pedicle grafts on dogs, utilizing the medial aspect of the tibia and thigh for the formation of the tube and then transferring the pedicle to the dorsal metatarsal area. Thirteen of these grafts were reported as being complete "takes". The use of 4 split thickness and 3 free full thickness grafts was also reported.

Cawley and Francis (1958) reported the successful use of a delayed pedicle graft to repair a chronic ulcerated area on the right dorso-lateral aspect of the metatarsal region of a 3 year old Shepherd dog.

III. METHODS AND PROCEDURE

A. Surgical Procedures

1. General considerations

Experimental animals were selected without regard for sex, age or breed from the supply obtained by the Department of Medicine and Surgery. The majority of the dogs were of mixed breeding. Clinical cases were utilized when available so that actual subjects requiring this type of surgery could be evaluated. All were in states of good health as far as could be determined by a general physical examination.

During the period of maintenance the animals were fed on a standard dry commercial dog food without supplementation. Fresh water was available at all times. Except for the clinical cases, which were given homologous canine distemper-hepatitis serum when indicated, no precautions were taken prophylactically to guard against infectious diseases other than the daily disinfection of the kennels.

Thirty-two dogs were used in these autogenous skin grafting experiments. More than one type of graft was often performed on a single dog so the same animal was actually used in a number of different experiments. The animals were kept under observation for varying lengths of time following surgery depending on the success or failure of the graft. Clin-

ical cases were discharged as soon as there was evidence that the graft was successful.

As the experiments progressed, changes were made in the techniques in an effort to overcome features which were considered undesirable or not adequate for good clinical results. Observations were made of the skin grafts with special reference to: (1) percentage of viability of each graft, (2) cosmetic appearance, (3) hair growth, (4) pliability of the graft, (5) resistance to trauma.

2. Preoperative preparation

Surgical sites were selected on the basis of those areas on the dog which would be most likely to require skin grafting. Since the dog has very loose skin over the thorax and abdominal areas, skin wounds in these areas, unless very extensive, could be repaired by "skin shifting". This operation consists of merely undermining the subcutaneous tissue of the skin margins and then bringing the edges into apposition. However, in skin lesions of the face and the extremities there is little or no excess skin, making "skin shifting" impossible. Because the areas of the legs are the most likely sites to necessitate skin transplantation, most of the surgery was confined to these regions. A small number of grafts were performed on the thorax to determine how well they would "take" since there is considerable deposition of fat underlying the

skin in this area which would make successful grafts more difficult.

Preoperative preparation of the surgical areas consisted of removal of the hair with an electric clipper fitted with a #40 clipper blade. Shaving was performed to further remove the hair. Following removal of the hair, the area was scrubbed with a germicidal soap¹, which was removed with cotton and then the area was rescrubbed. Ether was used to defat the area, followed by the application of 50 per cent isopropyl alcohol. When preparation of the surgical field was complete, the animal was restrained on the table in such a manner so as to best expose the surgical sites and facilitate the operative procedure. Just prior to draping the patient, another application of 50 per cent isopropyl alcohol was applied by means of sterile forceps holding a sterile sponge which was saturated with the antiseptic.

The surgical field was draped with sterile plastic sheeting² with an aperture of sufficient size to expose only that area of skin where surgery was to be performed. The drape was fixed in place by means of towel clamps placed through the drape and skin near the edges of the drape opening.

¹Hexachlorophene liquid soap U.S.P. Pitman-Moore Co., Indianapolis, Ind.

²Koroseal - Burrows and Co., Chicago, Ill.

Aseptic surgery was maintained during the entire surgical operation.

3. Operative techniques


(a) Series 1. Eleven dogs, 3 females and 8 males, ranging in age from 1 to 10 years were used in this experimental series. The purpose of this particular series was to become acquainted with the surgical procedures associated with skin grafting. An attempt was made to evaluate techniques for removal of the skin from the donor area, suturing and a satisfactory bandaging. Also, as part of this series the actual inspection of the grafts from day to day to learn the characteristics of transplants which were "takes" as well as those which were non-survival grafts was done.

The lateral aspect of the tibial region and the thoracic wall were selected as areas which might be satisfactory for these skin transplantation experiments. Both areas are relatively flat, so transplantation experiments would be more easily accomplished in this area. The free full thickness graft was decided upon as being the transplant of choice for this series. A total of 21 grafts were performed.

Special instruments and equipment needed for this surgery (Fig. 1) consisted of a Kalt needle holder, # 2, 3/8 circle cutting edge corneal needle, Russian tissue forceps, a Von Graefe fixation forceps, size 0000 braided, black silk, ster-

Fig. 1. Special instruments and equipment used in the skin transplantations:

1. Fixation forceps (Von Graefe)
2. Eye needle holder (Kalt)
3. Sterile "Telfa" pads (Curity)
4. Russian tissue forceps
5. # 2 corneal needle (3/8 circle, cutting edge). Size 0000 braided, black silk
6. Tensor elastic bandage (2 in.)



ile Telfa strips¹ which consist of an absorbent layer of cotton surrounded by a thin perforated layer of plastic, and Tensor elastic bandages¹. To immobilize the leg following surgery, a modified Thomas splint was used with the bandages incorporated around the splint.

Following preoperative preparation and draping of the operative field an area of skin 2 in. x 2 in. was removed from the ventral lateral wall of the thorax. A similar sized section of skin was removed from the lateral aspect of the tibial region. The two freed segments of skin were then interchanged so that the donor area of the thorax became the recipient area for the graft from the tibial region and vice versa. The grafts were not soaked in saline nor treated in any way prior to the transfer. A #10 Bard-Parker blade in a #3 handle was used to incise the skin as well as sever the skin from the subcutaneous tissue. The grafts were the same size as the dimensions of the recipient area as suggested by Davis (1927). An attempt was made to remove as much of the hypoderm as possible so that this tissue would not interfere with the revascularization of the transplant. After the graft was transplanted to the recipient area, each corner was sutured first with interrupted sutures of size 0000 braided,

¹Curity (Bauer and Black) Division of the Kendall Co., Chicago, Ill.

black silk. Interrupted sutures were then placed about 1/4 in. apart along the graft edges until the entire transplant was fixed in place. Continuous sutures were not used because it was felt that the dog might be more likely to destroy the graft should the bandage loosen or be removed. Two sterile Telfa strips were placed on the grafts after suturing was complete. Four or 5 sterile gauze pads were then applied to aid in equalizing the pressure on the grafted area. A modified Thomas splint was then placed on the leg, tape applied on the medial aspect of the leg from the tarsal region, over the end of the splint and then on the lateral aspect of the foot to the tibial-tarsal region. A 3 in. Tensor elastic bandage was wrapped around the sterile sponges and then incorporated around the splint. Two in. roller gauze was then placed over the elastic bandage followed by 2 in. waterproof tape. In 4 cases a cellulose sponge¹, soaked in 1:1250 quaternary ammonium compound for 30 minutes, squeezed dry and then placed over the sterile gauze, was used in an effort to try to equalize the pressure on the graft. This was abandoned as the sponges did not have sufficient resiliency to be of any value. The purpose of the roller gauze was to prevent the tape from adhering to the Tensor bandage, thus making it possible for reuse. The thorax was bandaged in a similar man-

¹Burgess Cellulose sponge, Burgess Cellulose Co., Freeport, Ill.

ner using sterile Telfa strips, 4 to 5 layers of sterile gauze sponges, Tensor elastic bandage, roller gauze and waterproof tape. The bandages were examined daily to determine if there were a need for further care. Bandages were changed at 2 day intervals unless sooner indicated because of soiling, loosening or removal by the patient. With the exception of 2 cases, which were used in further transplantation experiments, the dogs were observed for a maximum of 25 days. They were then sacrificed for the teaching of surgical techniques to the students. This afforded sufficient time to develop a degree of proficiency in the surgical procedure, observation of the grafts and the post operative care required.

(b) Series 2. The results obtained from series 1 were not as satisfactory as anticipated, so it was felt that the use of a delayed transfer of a tube or pedicle graft for use on the extremities of the leg might be more successful in the dog. In this particular type of graft the skin which is being transferred does not at any time lose all of its blood supply if the technique is properly performed. This was thought to be advantageous in the case of the dog especially if the bandages were loosened by the patient during the night. This was encountered in the dogs in the experiments of series 1.

This series of experiments was divided into two categories: (1) the delayed transfer of a tube graft and (2) the immediate transfer of a tube graft. The delayed transfer of

a tube graft has reference to the fact that there is a delay of several days to weeks following the formation of the tube. This provides for the development of a satisfactory blood supply prior to the actual transfer. This was not a new principle as it was first employed by Tagliacozzi in the sixteenth century in his operation for rhinoplasty as reported by Davis and Davis (1949, p. 87). The immediate transfer of a tube graft consists of the formation of a tube of skin and flap, severing this tube at one end and then moving the flap to the area to be grafted and then suturing the transplant in place.

(c) Delayed transfer of tube grafts - series 2. Eight dogs, 6 males and 2 females, were used for this series of grafts. A total of 14 grafts were performed. It was felt that by doing the delayed transfer of a tube graft first, one could have a chance to observe the healing processes peculiar to tubing of the skin and thus have a better understanding of what to expect when immediate transfers of a tubed flap were made. All of the surgery was performed on the rear legs, as this region seemed better adapted to the use of this type of graft than did the forelegs. There is very little excess skin in the axillary region of the dog, so the raising of sufficient skin to form a tube and still be able to cover the area from which the flap was removed by undermining and shifting of adjacent skin would be most difficult.

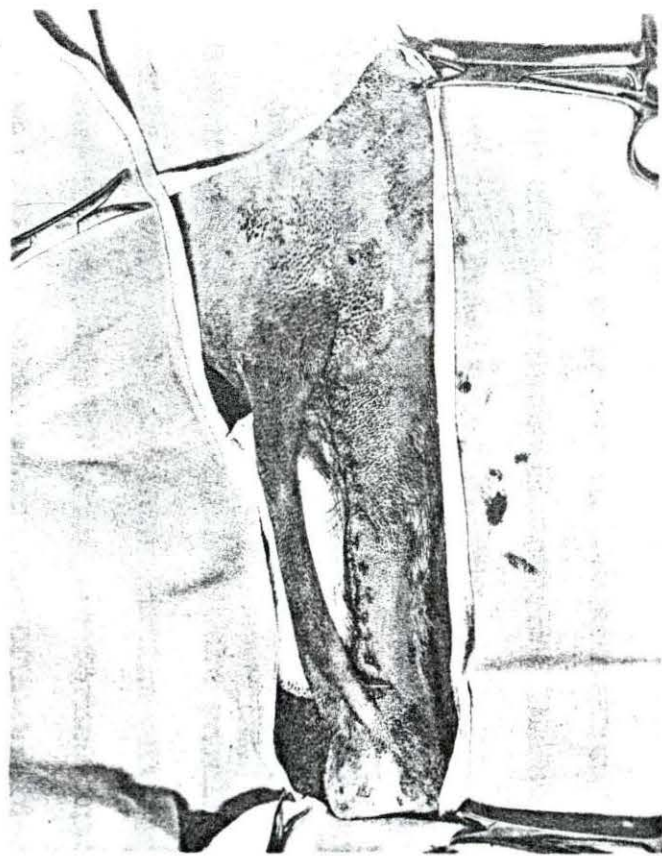
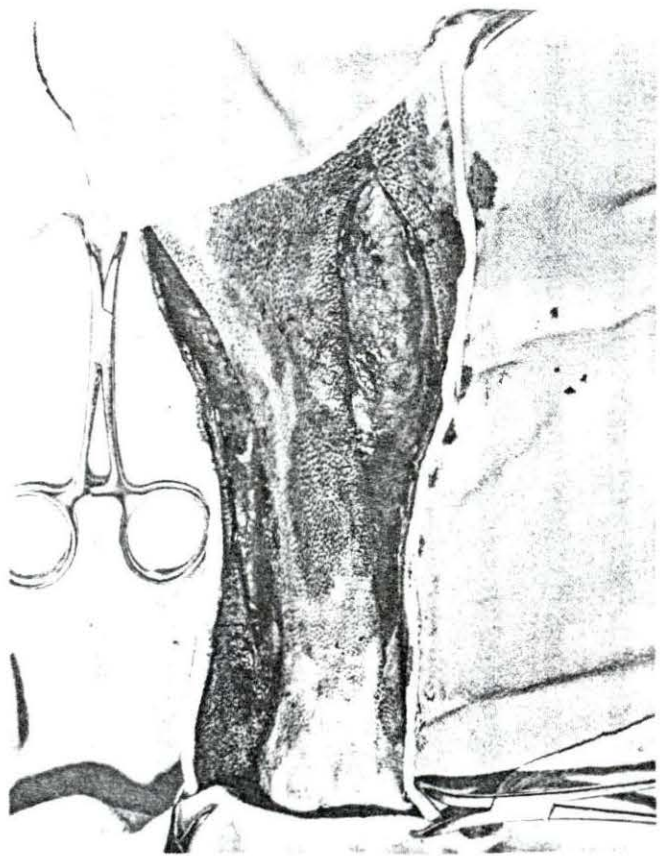One clinical case was utilized in this series of experiments. This was a Boxer which had been hit by a car resulting in the denuding of the skin and subcutaneous tissue of the dorsal aspect of the right metatarsal region measuring 2 in. x 4 in. A pedicle graft was made so that by the time the granulation tissue was deposited over the exposed metatarsal bones, the tube would be ready to be shifted to cover this area.

Preoperative preparation and draping of the operative field were basically the same as that described in series 1.

A pedicle or tube was formed on the medial aspect of the tibial region (Figs. 2 and 3) by making two parallel longitudinal incisions about $1\frac{1}{2}$ in. apart leaving the skin attached on both ends. The 2 parallel incisions were made as far apart as possible and still permit closure of the area from which the tube was raised by means of shifting and suturing of the adjacent skin. By grasping the loose skin of the medial region of the tibial area and pulling it upward it was possible to determine about how wide the proposed tube could be cut and still allow for skin closure after the tube was raised. It is surprising how much stretching of the skin can be done in that area to execute a proper skin closure. The parallel incisions in the skin extended from the femoral-tibial articulation to within $\frac{1}{2}$ in. of the tibial-tarsal articulation. With the aid of a Russian tissue forceps and a

Fig. 2. Two parallel incisions made on medial aspect of tibial region prior to formation of the tubed flap graft

Fig. 3. The tubed flap graft completed by suturing of the edges of the elevated strip of skin followed by "skin shifting" of the adjacent skin



blunt pointed scissors the strip of skin was freed from the subcutaneous tissue. Care was exercised so that there was a minimum of trauma to the skin during the elevation procedure. The saphenous vein and its branches traverse the medial aspect of the tibial region. This vein was avoided. If any part of the vein were accidentally punctured, hemorrhage was controlled by ligation or merely clamping with a hemostat and leaving it on the vessel for a short time. When the strip of skin had been elevated the full length of the parallel incisions, the only blood supply to this portion was from the two attached ends. This strip of skin was formed into a tube by the use of interrupted sutures of size 0000 braided, black silk using the same instruments as described in series 1. The defect from which the flap was raised may be sutured before or after the tube formation, but in this series the tube was formed first. One interrupted stitch was placed near the skin margins at about the center of the skin to be tubed. This suture was left a little long so that it could be held by the assistant or grasped with a forceps and used to hold the skin while the remaining sutures were placed to form the tube. If fat or subcutaneous tissue bulged between the sutures it was trimmed off with scissors. By so doing, all raw surfaces were in apposition and allowed for satisfactory healing of the tube. Interrupted sutures were used as suggested by Davis and Davis (1949, p. 91) who stated that the closure

was safer this way as only one stitch would tear out at a time. They also stated that if bleeding did occur in the tube it would often seep out between the stitches without destroying the suture line as would be the case if a continuous suture were employed. The area from which the tube was raised was closed by shifting of the adjacent skin so that the denuded area was covered with skin. Simple interrupted sutures of medium Vetafil¹ were used. It was noted that there were 2 triangles at each pedicle end, one on the tube and the other adjacent to it on the surface from which the tube was closed. These areas were difficult to close. When suturing these areas it was important that the sutures should not interfere with the blood supply coming to the tube from the ends. These triangular areas were closed to prevent an oozing of serum and hence serve as a good portal of entry for infection. In two cases the skin beyond the proximal end of the tube was incised on the lateral margins commensurate with the size of the anticipated graft. This was done in an attempt to increase the blood supply to the area. A 2 in. stockinette was cut so that it was long enough to extend from the hock to the stifle region. One in. adhesive tape was placed at both ends of the stockinette so that part of the tape adhered to the stockinette and the remainder on the skin. Ether was ap-

¹Vetafil Bengen - Bengen and Co., GmbH., 8-12 Dreyerstr., Hanover, West Germany.

plied to the tape prior to the wrapping so as to increase its adhesiveness. This method afforded protection for the tube and yet did not interfere with normal wound healing. The tube was inspected by removal of the tape from the distal end of the stockinette. After 4 days this protective bandage was removed and the tube left unbandaged.

After 12 to 40 days the tube plus the desired amount of skin needed to cover the experimentally produced recipient area was reflected distally to cover the lesion on the dorsal aspect of the metatarsal region. It was calculated that the tubed skin would extend to the proximal edge of the skin lesion while the untubed skin extended over the region to be grafted. The sizes of the grafts varied from 1 in. - $1\frac{1}{2}$ in. wide to $1\frac{1}{4}$ in. - 3 in. long. Interrupted stitches of size 0000 braided, black silk were used. The tension of the skin on the grafted area was that of the normal skin. An antibiotic ointment such as Polyotic compound mastitis ointment¹ or Terramycin ointment² was applied to the suture line. Two layers of sterile Telfa pads were placed over the graft. Three to 4 layers of sterile 3 in. x 3 in. gauze sponges were then applied followed by a layer of cotton which surrounded the foot from the hock distally. Care was exercised so as

¹American Cyanamid Co., New York 20, N.Y.

²Chas. Pfizer and Co., Inc., New York, N.Y.

not to bandage too tightly in the region of the tube as this was the only blood supply for the flap. A 2 in. roller gauze bandage was then applied followed by adhesive tape. The tips of the toes were allowed to protrude through the bandage. The bandages were changed in 3 days and then every other day for 8-10 days when bandages were no longer required. The tube, furnishing the blood supply to the new graft was ready to be severed after 12-14 days.

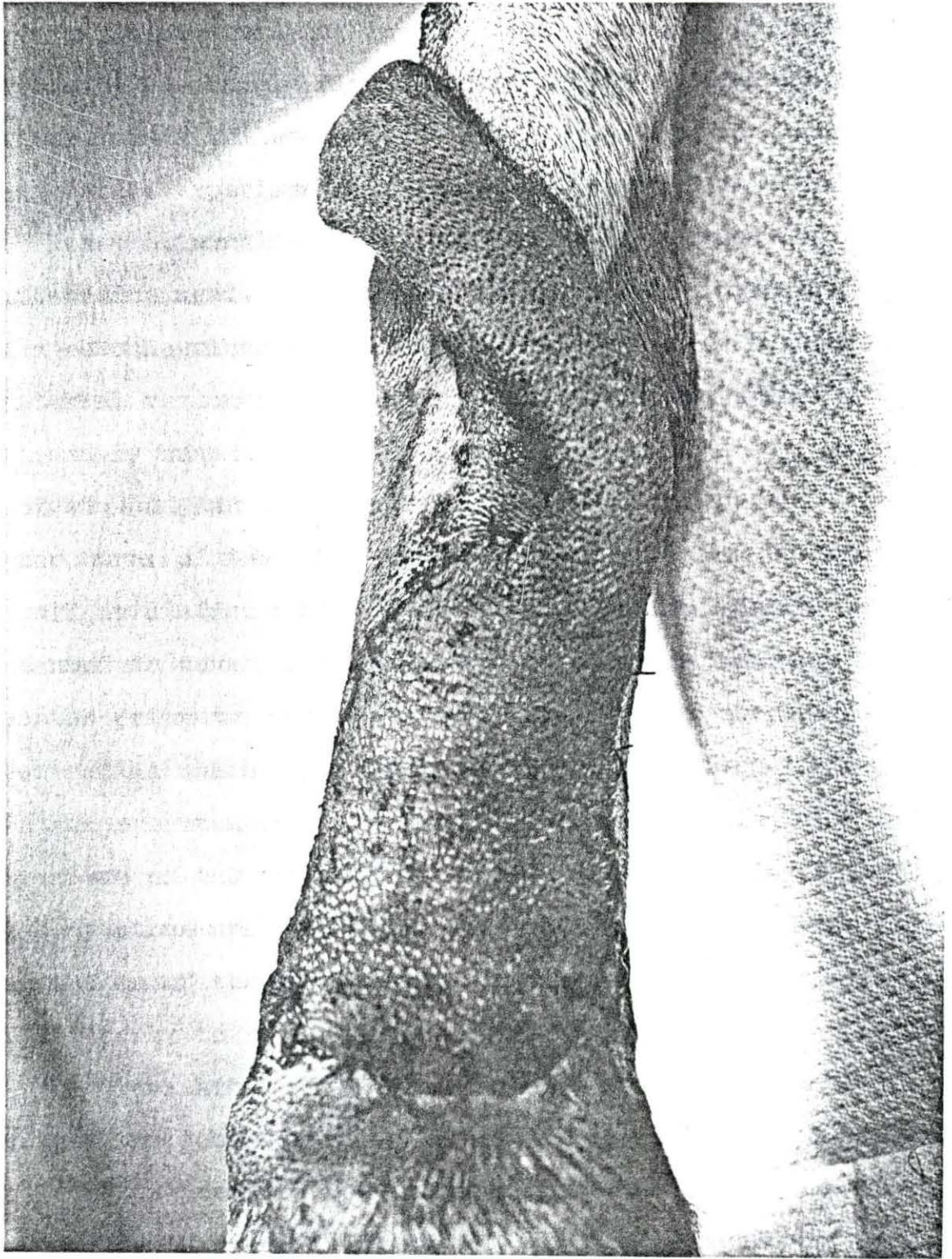
(d) Immediate transfer of tube grafts - series 2. Seven dogs, 2 males and 5 females, comprised this series. The grafts varied in size from $\frac{1}{2}$ in. - 3 in. wide by $1\frac{1}{2}$ in. - 3 in. long. Four clinical cases were utilized in this series. Two of the clinical patients were the result of a severe necrosis of the foreleg following faulty intravenous administration of pentobarbital sodium. The third patient had sustained a severe pressure necrosis of the flexor surface of the right metatarsal region due to faulty bandaging. An immediate transfer of a pedicle graft was used to correct this condition. A chronic ulcerative dermatitis of the dorsal aspect of the left metatarsal region was present on the fourth clinical patient. The remaining 3 grafts were experimental in nature. Two of these were transferred to the dorsal metatarsal area, utilizing the skin of the medial aspect of the tibial region and thigh as was done in the transfer of delayed tube or pedicle grafts. The third graft was removed from the antero-lateral aspect

of the humeral area to cover a lesion of the dorsal radial-ulnar region.

Basically, the technique for the formation of the tube for immediate transfer was the same as that for the delayed transfer. The only difference was that after the tube was formed the transplantation was made immediately rather than after a delay of several days to weeks. Fig. 4 shows a tubed flap graft which had been transferred immediately after formation. The tube for the 2 dogs suffering from a perivascular necrosis was secured from the medial aspect of the humeral area, making certain that the pedicle would be long enough to extend to the proximal edge of the graft bed. Sufficient skin was left attached to the pedicle so as to cover the defect to be grafted. Since the free skin in the axillary region was limited, the antero-lateral aspect of the humeral area was tried as a donor site in one case for a transplant to the dorsal aspect of the radial and ulnar region. Suturing and bandaging of the grafts were the same as for the delayed transfer of pedicle grafts which has already been described. The grafts were observed for a period ranging from 14 to 523 days.

(e) Series 3. Eleven dogs, 7 males and 4 females, ranging in age from 1 to 10 years were used in this series. After having completed series 2 it was felt that a satisfactory technique could be developed for the use of the free full

Fig. 4. The completion of an immediate transfer of a tubed flap graft on the dorsal metatarsal region



thickness transplant. A total of 31 free full thickness grafts were made ranging in size from $\frac{1}{2}$ in. - 3 in. wide by 1 in. - $3\frac{1}{2}$ in. long. Five of these grafts were used on granulating wounds while the remaining 26 grafts were placed on fresh wounds experimentally produced.

Three clinical cases were utilized with a total of 6 grafts being used. The first case was a Black Laborador which had a chronic ulcerative granulomatous lesion on the left metatarsal region which was initially caused by a wire cut, followed by constant licking of the area. The second case involved a 2 year old male Dachshund which had suffered third degree burns of the face with resultant scar tissue formation as well as disfiguration of the upper eyelids. Four grafts were used to cover this area. The accident had occurred about 6 months prior to surgery. The third case was concerned with a Pomeranian which had been hit by a car resulting in the skin and subcutaneous tissue being removed from the area of the dorsum of the carpus to the extremities of the digits. The bony structures of the area were exposed. Following granulation of the area, skin was taken from the lateral wall of the thorax to cover the denuded site.

The remaining 9 dogs were utilized for a total of 25 grafts. The donor site for 14 of these transplants was from the medial aspect of the left or right thigh, while the recipient area was an experimentally produced denuded area on

the dorsal aspect of the skin of the forelegs about midway between the proximal and distal ends of the radius and ulna. One graft was removed from the medial thigh region and placed on a granulating lesion of the dorsal aspect of the metatarsal region. Another transplant was transferred from the left lumbar area to a non-granulating lesion of the left dorsal metatarsal area. Two grafts from the thorax were transferred to the forelegs in the same relative location as described previously. Six grafts were transferred from the thorax to the tibial region, 2 cases being interchanged which accounts for 4 grafts. The remaining 2 cases utilized the thorax as the donor site and the tibial region as the recipient area with the skin removed from the tibial area disposed of when the graft site was prepared.

The preoperative preparation and draping of the operative field were the same as that described in series 1. The size of the skin to be removed for the graft was predetermined by the use of a sterile gauze sponge or a sheet of sterile aluminum foil cut to the desired size. This pattern was then placed on the donor area and the skin at the margin was incised with a sharp scapel. A Russian tissue forceps was used to gently secure the skin while the subcutaneous tissue was being severed and the section of the skin lifted from the area. A similar procedure was executed to prepare a recipient area for the transplant. Hemorrhage following the removal of

the skin was controlled primarily by the application of sterile gauze sponges and pressure until capillary bleeding had ceased. If an artery or vein was severed or perforated, a mosquito hemostat was applied, being careful not to traumatize the surrounding tissue. The suturing technique was similar to that described in series 1. When the suturing was completed an antibiotic ointment such as Polyotic or Terramycin was applied along the edges of the graft. It was found in the first series of experiments that the free full thickness transplants were very susceptible to infection. The prevention of contamination in the region of the extremities was difficult especially when it was necessary to observe the results at relatively short intervals for this study. Two sterile Telfa strips, $2\frac{1}{2}$ in. x 3 in., were then placed on the graft followed by 3-4 sterile 3 in. x 3 in. gauze sponges. One of the sponges was unfolded so as to encircle the other bandages and thus assist in keeping them fixed at that position. A thin layer of absorbent cotton was then placed around the dressings so as to extend from the hock or elbow joint distally to the paw leaving just the tips of the digits exposed. If the bandaging was not extended sufficiently so as to cover most of the paw, excessive swelling or edema would occur at the uncovered portion of the toes. Two in. roller gauze was snugly wrapped around the cotton in an effort to produce an equivalent of 30 mg. of mercury pressure as suggested by Smith

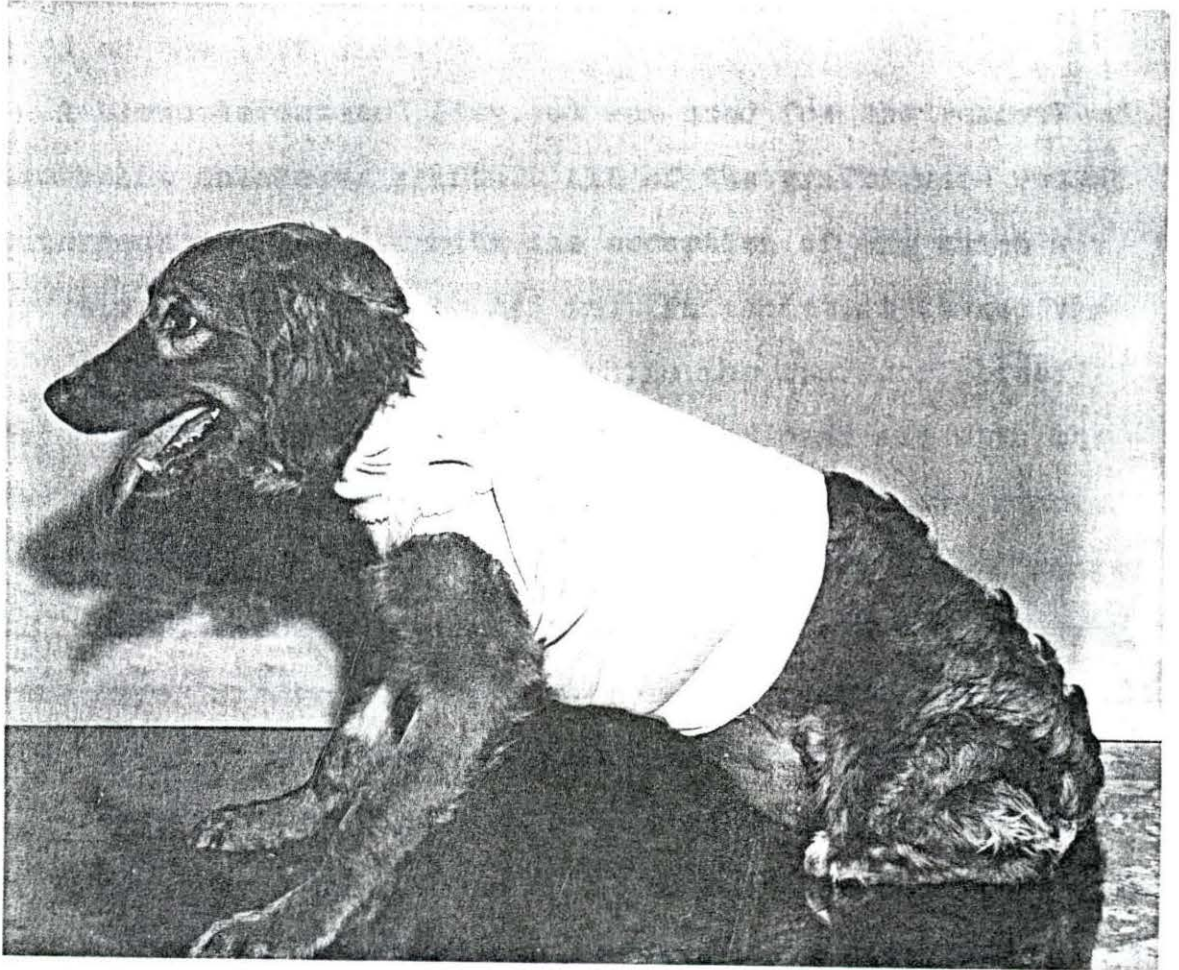
(1926) which he stated was equal to a snugly wrapped bandage. One in. waterproof adhesive tape was then spiraled around the leg starting just proximal to the tip of the toes and continued to the next joint which was either the elbow or the hock. For the 6 grafts which concerned the thorax and lateral tibial region, the bandaging procedure was the same as that described in series 1. The 4 grafts of the head region were bandaged in a somewhat similar fashion to those of the legs, with roller gauze and tape encircling the head. The bandage material was applied both anterior and posterior to the base of at least one of the ears to prevent slipping or easy removal by the patient. Bandages were redressed every 2 days unless loosened or removed by the dog prior to that time. The grafts were observed for a period ranging from 14 to 382 days.

Fig. 5 shows a method of restraint made of stockinette and cardboard used to prevent mutilation of grafts of the rear legs during the first 10-14 days following transplantation.

(f) Series 4. Four dogs, all males, ranging in age from 3-4 years old, were used in this series which consisted of 5 split thickness grafts. All of the transplants were made on non-granulating lesions, experimentally produced.

The preoperative preparation and draping of the operative field were essentially the same as that described in the preceding series except that the donor area was lightly powdered

Fig. 5. A stockinette and cardboard restraint used to prevent the patient from mutilation of the grafts of the rear legs during the first 10-14 days following transplantation



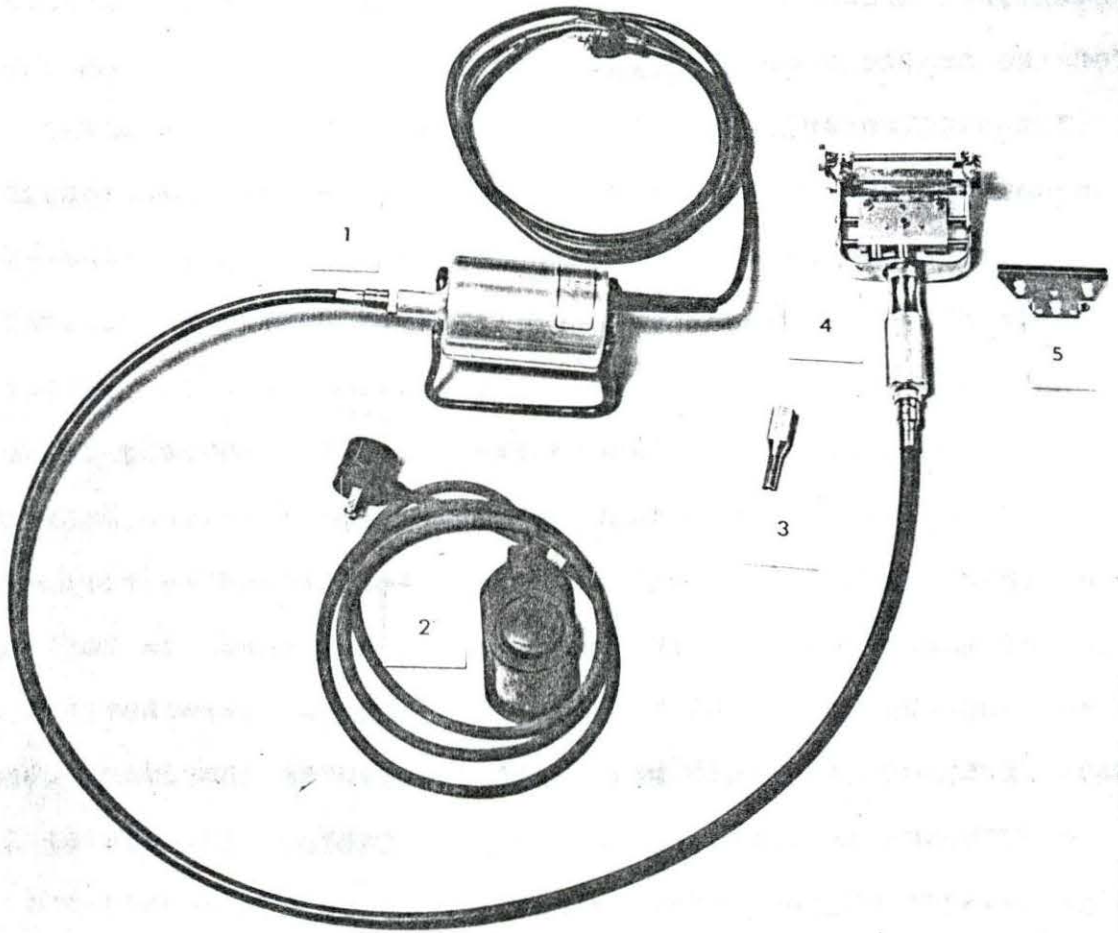
with sterile talcum after the antiseptic had dried. This facilitated the removal of the skin by mechanical means. The dorsal lateral aspect of the thorax was the area of choice. Three transplants were made on the right thorax while 2 were placed on the left side.

A Brown dermatome¹ (Fig. 6) was used for the removal of these split thickness grafts. All of the grafts were cut at a thickness of .030 in. with the exception of one which was removed at a thickness of .035 in. An assistant tensed the skin anterior to the donor area while the operator placed tension in an opposing direction with one hand and with the other manipulated the dermatome so that the skin was removed at the desired thickness. The size of the transplants ranged from 3 in. sq. to $4\frac{1}{2}$ in. sq. After removal, the remaining dermal layer was removed as evenly as possible with a sharp scalpel so that this area could then be used for the graft bed. When this was completed and hemorrhage controlled by sterile pressure packs, the split thickness graft was then replaced in the area from which it was removed. Continuous sutures of size 0000 braided black silk were used to fix the transplant to the wound edges. Polyotic mastitis ointment was then applied over the graft. Two layers of sterile Telfa pads were then applied followed by 3-4 layers of sterile 3 in.

¹Zimmer Manufacturing Co., Warsaw, Indiana.

Fig. 6. The Brown Dermatome and accessories:

1. Motor and flexible shaft
2. Foot pedal switch
3. Instrument to tighten "set screws" on blade
4. Cutting head of dermatome
5. Replaceable blade



in. by 3 in. sponges which were unfolded prior to placing on the area. Interrupted sutures of medium Vetafil were placed in each corner of the sponges so that they included all of the dressings and a small amount of skin surrounding the margin of the graft. One or 2 extra stitches were placed on each side of the 2 longer sides of the sponges. The purpose for the anchor stitches was to prevent slipping of the dressings if the outer bandages should become loosened. One roll of 3 in. Tensor elastic bandage was then applied over the dressings and continued so as to encircle the thorax. Three in. roller gauze was placed over the elastic bandage followed by 2 in. waterproof adhesive tape which was placed so as to incorporate part of the skin and hair at both the anterior and posterior margins of the bandages. The bandages were removed in 3-5 days and redressed. After 10 days the bandages were not replaced. A bland ointment¹ was applied daily to the graft area for 1 to 2 weeks to keep the skin more pliable. The grafts were observed for a period ranging from 84 to 350 days.

(g) Series 5. Five dogs, all females, ranging in age from 11 to 24 months, were used for this series of experiments. Keefe (1946) suggested that the seed graft in the dog was much simpler and gave quicker results than the tubed flap method. The technique for obtaining the small deep grafts in this series was similar to that described by Davis (1914).

¹Moruguent ointment, The S. E. Massengill Co., Bristol, Tenn.

The preoperative preparation and draping of the operative field were basically the same as that described in series 1.

The medial aspect of the thigh was selected as the donor area for the grafts. Lesions were experimentally produced on the thorax to simulate skin wounds which might occur as a result of injury. The size of the lesions ranged from $1\frac{3}{4}$ in. to 5 in. wide by 2 in. to 5 in. long. The lesions were allowed to granulate for 7 to 16 days until a suitable "seed bed" was obtained. The recipient area was considered acceptable for grafting when the granulation tissue was firm and bright red in color which indicated a good blood supply at the site. Prior to the actual "seeding" of the area, the lesion was cleansed with gauze sponges saturated with ether as suggested by Davis (1929). This was followed by sterile gauze sponges saturated in 1:3,000 solution of aqueous Zepharin¹ which was allowed to remain on the area for at least 15 minutes. The small deep grafts were obtained by placing a straight atraumatic intestinal needle in the jaws of a Mayo needle holder so that about $\frac{1}{2}$ in. to $\frac{3}{4}$ in. of the needle protruded beyond the distal end of the jaws of the needle holder. The tip of the needle was inserted into the dermal layer of the skin of the medial aspect of the thigh which was used as the donor area for these transplants. A small bleb of skin was elevated and removed with a sharp scalpel (Figs.

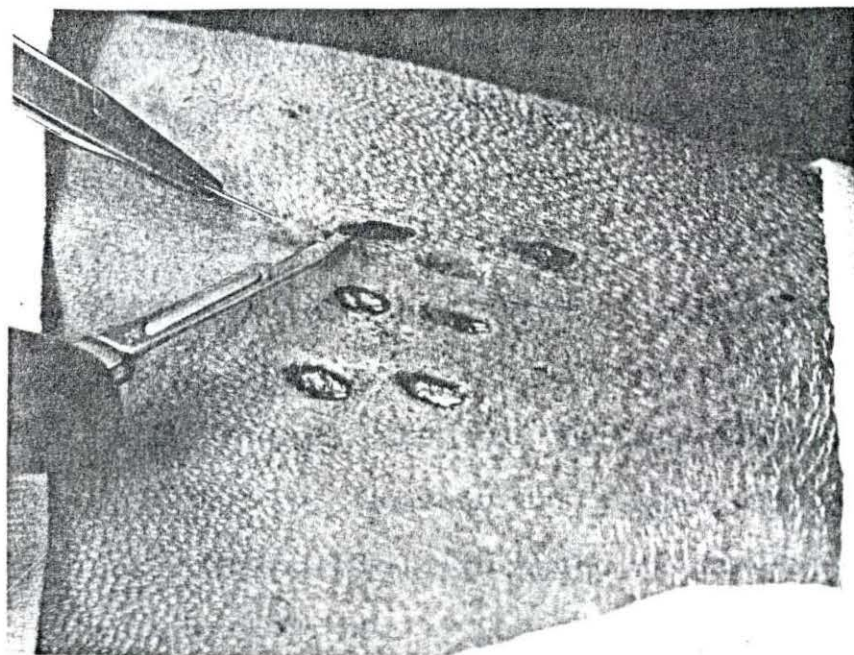
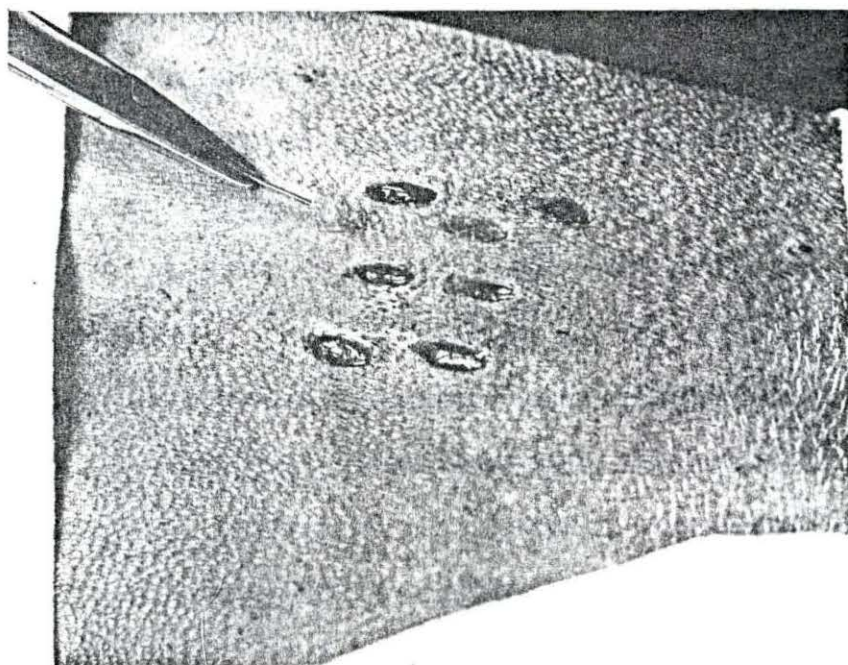
¹Aqueous Zephiran, Winthrop Laboratories, New York.

7 and 8) so as to cut with a slight slant downward to about center and then raising the scalpel upward so as to have full thickness only at the center. These grafts were then placed on the recipient area making sure that the granulation tissue was dry prior to placing the graft on it so that there would be better adhesion of the transplant to the "seed bed". The "seeds" of skin were placed about $3/8$ in. apart. The grafts were cut oval in shape and ranged in size from 2 mm. - 4 mm. An antibiotic ointment¹ was placed between the seeds prior to the application of the dressings. Two layers of sterile Telfa strips were placed over the area, followed by 4 layers of sterile 3 in. x 3 in. sponges which were unfolded prior to being applied. The dressings were then sutured to the skin in the same manner as described in series 4. The use of a Tensor elastic bandage, roller gauze and tape was similar to that described in series 4. Five days postoperatively the dressings were removed and the graft area checked. New dressings were applied and left in place for 3-5 days longer depending on the condition of the transplants at the time of the first examination. Bandages were kept on the transplanted area for at least 10-14 days. If the dog persisted in licking the area, the lesion was bandaged for a few extra days.

¹Furacin - Penicillin Gel. Eaton Laboratories, Norwich, N. Y.

Fig. 7. Raising of a bleb of skin with an atraumatic
needle prior to excision

Fig. 8. Excision of the bleb of skin from the donor area
to complete the removal of the small deep graft



(h) Series 6. This series was completed in an effort to study the macroscopic and histological changes which occur when free full thickness skin grafts were removed from the donor site and transplanted to a new location. Six dogs, 1 male and 5 females, were used for this series of experiments. A total of 12 grafts were made. The size of the transplants was $3/4$ in. wide by $1\frac{1}{4}$ in. long.

The preoperative preparation and draping of the operative field were the same as that described in series 1. The medial aspect of either the right or left thigh was utilized as the donor area while the dorsal aspect of both metatarsal regions was the recipient site. The lesions on the metatarsal area were experimentally produced. A sterile gauze was used as a pattern in the removal of the donor skin from the thigh region. A sufficiently long strip was obtained so that the skin removed could be divided into half transversely and thus provide two transplants, one for each leg. As the skin was removed, the subcutaneous tissue was freed from the skin by the use of a sharp scalpel. A small portion of skin from this area was saved for sectioning so as to microscopically compare the normal skin of this area with that which was transplanted to the metatarsal regions. The donor site was covered by shifting of the adjacent skin and held in place by horizontal mattress stitches of medium Vetafil. The skin transplant was placed on the denuded recipient bed after hemorrhage had been

controlled. The grafts were sutured with size 0000 braided, black silk as described in series 3. Furacin - penicillin ointment was applied to the transplant prior to bandaging. The dressing of the transplants was the same as that described in series 3. Bandages were changed at 2 day intervals and were not replaced after 10-12 days.

At 2 day intervals a portion of one graft was sacrificed for histological study. Two parallel incisions $3/8$ in. apart were made transverse to the long axis of the leg so as to remove the center portion of the graft. The incisions were extended so as to remove about $1/4$ in. to $1/2$ in. of the adjacent normal skin on each side of the graft. A portion of the graft on the right leg was removed first, then followed by the graft on the left leg for each dog in this series. Each dog contributed 2 grafts for histological study which were made at 2 day intervals. From the first dog a 2 and a 4 day old graft were removed and from the second dog a 6 and 8 day old graft. This was continued until the last dog in the series of 6 had yielded a 22 and a 24 day old graft. The strip of the graft removed for histological study was placed in 10% formalin prior to being sectioned. Paraffin sections were cut at 8 microns and stained with hematoxylin-eosin.

IV. OBSERVATIONS

Results obtained from the skin transplantations in each series were recorded following observations made on the following factors:

1. Percentage of viability of each graft.
2. Cosmetic appearance of the grafts.
3. Hair growth.
4. Pliability of the graft.
5. Resistance to trauma.
6. To study the histological and pathological changes of the graft following transplantation (series 6 only).

A. Series 1

The main purpose of this series was to become familiar with the surgical techniques involved in free full thickness skin transplants. An attempt was made to observe the gross appearance of the graft at frequent intervals so as to be able to gain experience in being able to ascertain the viability of the graft. To establish a satisfactory bandaging technique was also a part of this series.

The viability of grafts was determined solely on the basis of macroscopic appearance. Only those areas which indicated a satisfactory vascularization, as evidenced by color changes, were considered as "takes". For the first forty-

eight hours postoperative, the transplants were a black and blue color with little hint of a blood supply. Seventy-two to ninety-six hours following surgery the grafts gradually lost the dark colors and began showing a light red tinge which became more pronounced with each succeeding day. Usually by the seventh to the eighth day a light red color had permeated the graft. Davis and Traut (1925, p. 877) reported that the establishment of a satisfactory vascular system was evident in 12 days. The percentage of viability of each graft was exceptionally poor due to the loosening of bandages and lack of restraint. Probably, the failure to remove all of the subcutaneous tissue from the graft before placing it on the donor area was also a factor. There was considerable subcutaneous fat on the lateral wall of the thorax, so a graft placed on this tissue was not likely to receive a satisfactory blood supply. Table 1 seems to indicate this fact as the percentage of viability of each graft placed on the thorax was not as good as those on the lateral tibial region. The grafts from the thoracic region to the tibial site were somewhat more successful although the donor skin from the thorax had considerable subcutaneous fat which adhered to the transplant and which was not completely removed at the time of surgery in this series.

Only 2 of the 11 dogs used in this series were kept a sufficient time to make any evaluations concerning cosmetic

Table 1. Free full thickness grafts performed for technique only

Case no.	Donor and recipient sites	Size of graft (inches)	Percentage of viability of each graft		
			Tibial region	Thorax	Foreleg
1	Left thorax to left tibial region interchanged	1½ x 1½	40	0	
4	"	2 x 2	75	85	
3	Left thorax to left tibial region (not interchanged)		100		
5	Right thorax to right tibial region interchanged	2 x 2	0	0	
6	"	2 x 2	0	0	
7	"	2 x 2	0	0	
8	"	2 x 2	30	25	
11	"	2 x 2	0	60	
2	Left thorax to left foreleg interchanged	2 x 2		0	10
9	Medial aspect of left thigh to right tibial region (not interchanged)	1 x 3½	45		
10	Medial left thigh to right tibial region not interchanged)	2 x 2	10		

appearance, hair growth, pliability of the skin and resistance to trauma. The remaining 9 dogs were observed a maximum of 25 days and then sacrificed for the teaching of surgical techniques to the students. Case #3 was observed for 162 days. The donor site for this graft was the left thorax and the recipient region was the left tibial area. This graft was a complete "take". Hair growth was not as dense as that of the thorax from which it was taken. The graft was pliable and was resistant to trauma. There was some pigmentary change as the graft was darker in color than the adjacent skin. This was a light skinned dog. Case #11 was observed for 671 days as other grafting techniques were performed on this patient. Only 60 per cent of the graft survived, but appeared to have a normal color, resisted trauma well, and hair growth was reduced by at least one-half of that found in the lateral tibial region which was the donor area.

B. Series 2

This series was divided into two sections, the first being a study of the transfer of delayed tube grafts, the second being observations on the immediate transfer of tube flap grafts.

1. Delayed transfer of tube grafts

Fourteen delayed tube transplants were performed on 8 dogs, utilizing the medial aspect of the tibial and thigh re-

gions for the formation of the tube and flap, while the donor area was the dorsal metatarsal region. Table 2 lists some of the pertinent information concerning this type of graft and will be frequently referred to in an effort to facilitate the interpretation of the observations made in this study.

The period of delay before the tube was shifted to the new graft bed ranged from 12 to 40 days. The reason for this variance was to determine a satisfactory period for the delay of the tube prior to the actual transplantation. In the tube flap graft, as described by Davis and Davis (1949, p. 111), a portion of the tube may be split longitudinally following the delay and utilized as the graft. This was only done on the left leg of case #102 in which an immediate tube flap was tried but did not "take". The tube, however, remained viable so 32 days later a portion of its length was split open and grafted to an experimentally produced lesion. This was not completely satisfactory as it limited the size of the graft. If this were performed in all of the cases it would have meant that a longer tube would have to be formed which in turn would lessen the chances for a good blood supply. Also, there is a shrinking of the tube upon healing, so the width of the graft would be much less than that from which the tube was formed. In case #102 the graft was much thicker than the surrounding skin, but gradually decreased in thickness until by the end of 35 days it was about the same thickness as the

Table 2. Delayed transfer of tube flap skin transplants from the medial aspect of the tibial region and thigh to the dorsal metatarsal region

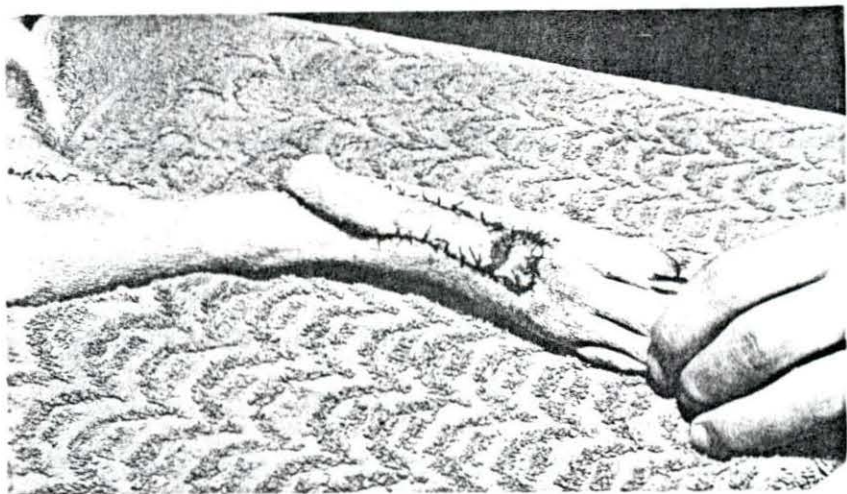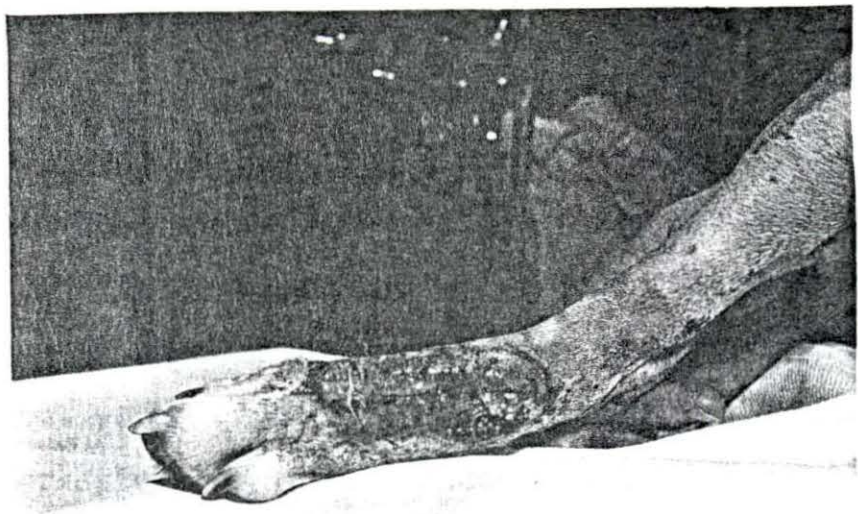
Case no.	Width and length of skin for tube formation (inches)	No. of days tube delayed	Size of graft or flap (inches)	Percentage of viability of each graft	Length of observation (days)
11	1 1/2 x 4 1/2	-	R ^a -	0	Tube destroyed on 6th day
	1 x 5	25	L ^a 1 1/4 x 2	100	473
101	1 1/4 x 5	20	L 1 1/4 x 1 1/2	100	526
102	1 1/4 x 5	32	L 1 1/2 x 2	100	491
	1 x 3 3/4	30	R 1 x 1 1/2	100	362
104	1 1/4 x 5	20	L 1 1/4 x 2	100	527
	1 1/4 x 5	20	R 1 1/4 x 1 3/4	100	527
105	1 1/4 x 3 1/4	39	L 1 1/2 x 2 1/2	100	216
	1 1/4 x 3 1/4	39	R 1 1/2 x 2 1/2	100	216
106	1 3/4 x 5	24	L 1 1/2 x 2 3/4	100	123
	1 3/4 x 5	24	R 1 1/2 x 2 1/2	100	123
107	1 x 3 3/3	40	L 1 x 1 1/4	100	186
	1 x 3 3/4	40	R 1 x 1 1/4	100	186
14404 (Clinical case)	1 1/2 x 3	12	R 1 1/2 x 3	85	14

^aRight rear leg; left rear leg.

adjacent skin. Because of these shortcomings, in all of the other cases an additional amount of skin was removed adjacent to the proximal end of the tube and then reflected with the tube to the region to be grafted. This was thought to take a longer period of time for a satisfactory blood supply to develop, so hence the longer delays. From Table 2 it would appear that 12 days was too early to complete the grafts, whereas 40 days was longer than necessary. Six of the grafts, cases 11, 101, 104, and 106, were transferred at the end of 25, 20, 20 and 24 days respectively. All resulted in successful "takes". The appearance of the tube as to color and satisfactory healing was important. For example, case 11 removed two stitches from the tube 2 days after formation, causing serum to ooze from the area for several days. This caused a delay in time for completion of the graft. In spite of the delay, the transplant was made on the 25th day with satisfactory results, although several days might have been gained had the dog not molested the tube. On the 6th day the same dog severed the pedicle on the opposite leg. This was the only dog that molested the tubes either during the delay period or after the completion of the transplants. Fig. 9 shows a lesion of the dorsal right metatarsal region following a granulation period. Fig. 10 shows a transfer of a delayed tube flap graft which has been in place for 7 days. The tube was delayed for 12 days prior to transfer. This was the only

Fig. 9. A granulating lesion of the right dorsal metatarsal region just prior to skin grafting

Fig. 10. A delayed transfer of a tubed flap graft 7 days after transplantation. Note the small area of ulceration near the distal end



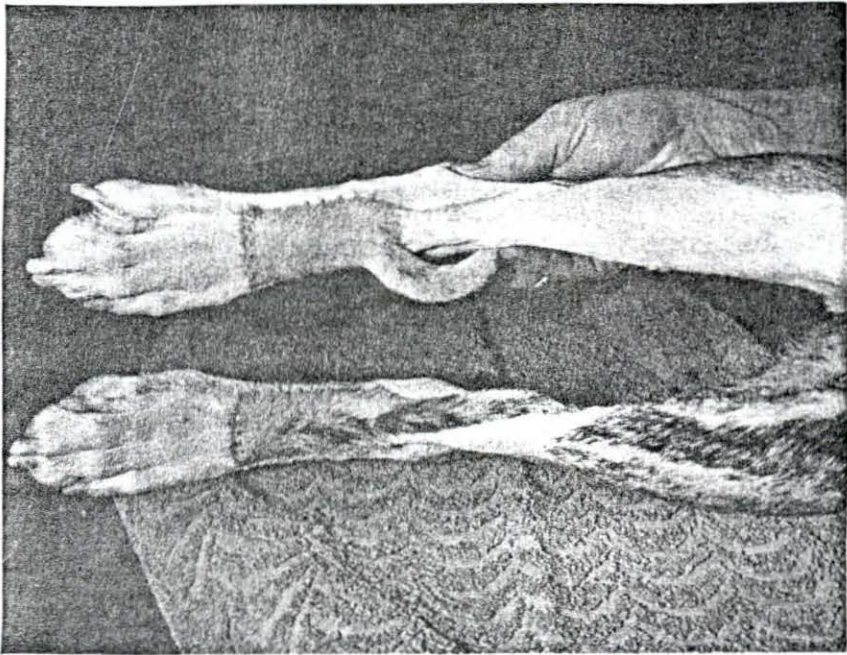
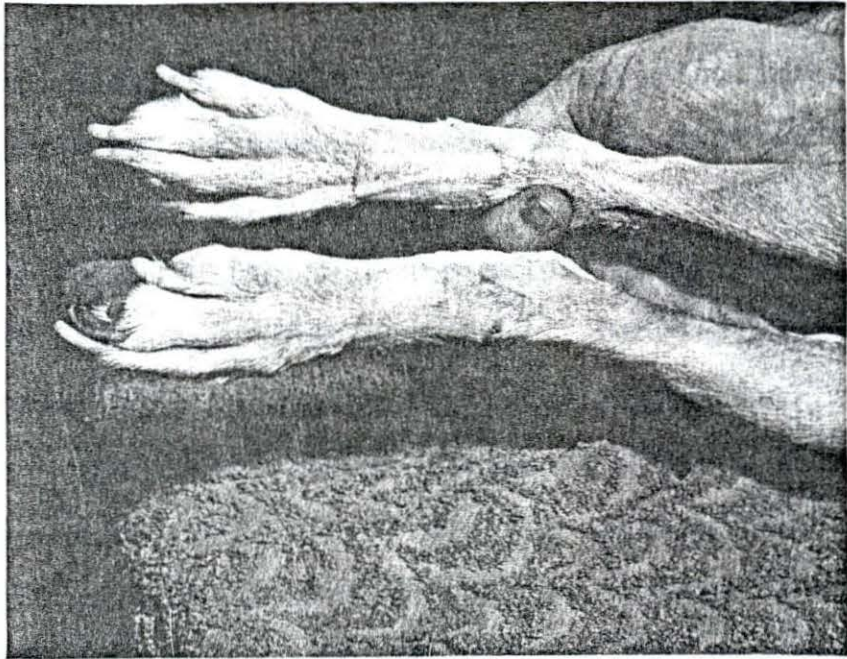
graft of the series in which there was a small area of necrosis following the transplantation. Since this was a clinical case, time was important. Probably a few more days delay would have resulted in a complete "take".

The percentage of viability of each graft was assessed solely on macroscopic appearance. The more adequate the circulation in the tube prior to completion of the transplant, the less change in color evidenced by the graft following transplantation. Some of the flaps were red in color on the second day whereas others showed a bluish tinge almost as severe as those in series 1 which were free full thickness transplants. Those pedicles which were delayed 30 and 40 days showed a red tinge to the grafts in 2 days. Case #11, in which the dog removed two stitches and produced an oozing of serum for several days from the tube, apparently did not have a satisfactory blood supply to the graft even after 25 days. Upon transfer, the flap showed a deeper blue color 2 days postoperatively than did any of the other grafts including case #14404 which was transferred on the 12th day. It is important that the tubes must not be molested by the patient or faulty circulation might develop.

The cosmetic appearance of the grafts was good. The appearance of a graft 135 days after transplanting is shown in Fig. 11. Except for the demarcation at the border and the difference in density and direction of hair growth, the graft

Fig. 11. Two tubed flap grafts 4 1/2 months following transplantation on the dorsal metatarsal region

Fig. 12. Two tubed flap grafts 94 days after transplantation. The pedicles were not severed. Note the direction of the hair growth



is not objectionable. This was true in all of the grafts in this series.

When the tube flap was reflected downward from the medial aspect of the thigh, there was a change in the direction of the hair growth from that of the adjacent skin. Fig. 12 is a graft of 94 days in which the hair can be seen to grow in the opposite direction. The hair was also longer and less dense as the transplant had its origin from the medial aspect of the thigh where this condition was true. There appeared to be no apparent loss of hair of the flap following the surgery. The pedicle in Fig. 12 was not severed in this case so that it could be observed whether there would be any change in the size of the tube after the flap had developed a blood supply of its own. There appeared to be a decrease in diameter of the tube of about one-third.

The pliability of the grafts was evaluated by palpation of the graft and then the adjacent skin. After the transplant had established its own blood supply, which appeared to require about 8-10 days, the pliability of the graft began improving so that by the 21st day there was little or no difference from that of normal skin in the area. In all cases the graft could be freely moved about just as easily as the adjoining normal skin.

Resistance to trauma was observed under kennel conditions and this could be misleading. However, when the dogs were

inactive there was a greater opportunity for the dogs to molest the grafts just from boredom. This was not observed in any of the cases except case #11 which has already been cited. With the dogs being confined, there was less chance for injuries to occur than might have been the case if the dog was left in its normal habitat. In spite of the fact that the region was devoid of a nerve supply for some time, the dogs did not attempt to destroy the graft. All of the grafts were not affected by trauma under the kennel conditions described above.

2. Immediate transfer of tube grafts

The immediate tube flap grafts were similar to the delayed tube transplants as far as the actual surgical techniques were concerned except for the fact that there was no delay following the formation of the tube to allow for the establishment of a satisfactory blood supply in the tube prior to completion of the graft. A total of 7 grafts were performed, each graft on a separate patient.

The viability of the transplants was assessed on the basis of gross appearance. The color of the grafts in this section of the series seemed to indicate that the blood supply, which was to have been furnished by the pedicle, was not as adequate as that of the delayed tube flap grafts. All of the grafts progressed through the changes in color similar to

those of a free full thickness graft as reported in series 3. The periphery of the grafts seemed to show a greater lack of blood supply than did the center and the region nearest the tube. In none of the cases was it possible to achieve a 100 per cent "take". Table 3 enumerates some of the pertinent information associated with this section of the series. Even though the length of the tubes were relatively short, there evidently was not a satisfactory blood supply through the pedicle to nourish the flap until it developed a blood supply of its own. When the pedicles were severed on the 9th to the 15th day, there was not the flow of blood from the tube like there was in the delayed tube flaps. It was interesting to note in case #102 that the graft appeared to be viable until the eighth day when the reddish color disappeared and was replaced by a blackened area with some exudation. Here was a case that gave early evidence of a "take" and yet later became a total loss. The exudate was cultured and Pseudomonas aeruginosa and Bacillus sp. were isolated.

Four of the grafts were performed on clinical cases. Numbers 201 and 47261 were grafted on an area where a severe perivascular slough of the dorsal aspect of the radial and ulnar region had resulted following faulty pentobarbital sodium administration. Case #08561 was a result of pressure necrosis resulting from bandaging the hock region too tightly following a bursitis. In case #08010 a graft was used to cor-

Table 3. Immediate transfer of tube skin transplants

Case no.	Donor and recipient area	Size of graft or flap (inches)	Percentage of viability of each graft	Length of observation (days)
102	Medial left tibial region to dorsal metatarsal area	1 1/4 x 1 3/4	0	523 ^a
107	Anterio-lateral-humeral region to dorsal radial-ulnar area	1 1/2 x 2	75	171
201 ^b	Right axillary region to dorsal radial-ulnar area	1 x 3	85	80
202	Medial right tibial region to dorsal metatarsal area	1 1/4 x 1 1/4	90	30
08010 ^b	Left thorax to dorsal left metatarsal area	2 x 3	60	14
08561 ^b	Medial right tibial area to flexor aspect of hock	1 1/2 x 2	75	19
47261 ^b	Right axillary region to dorsal radius-ulnar area	3/4 x 1 1/2	85	17

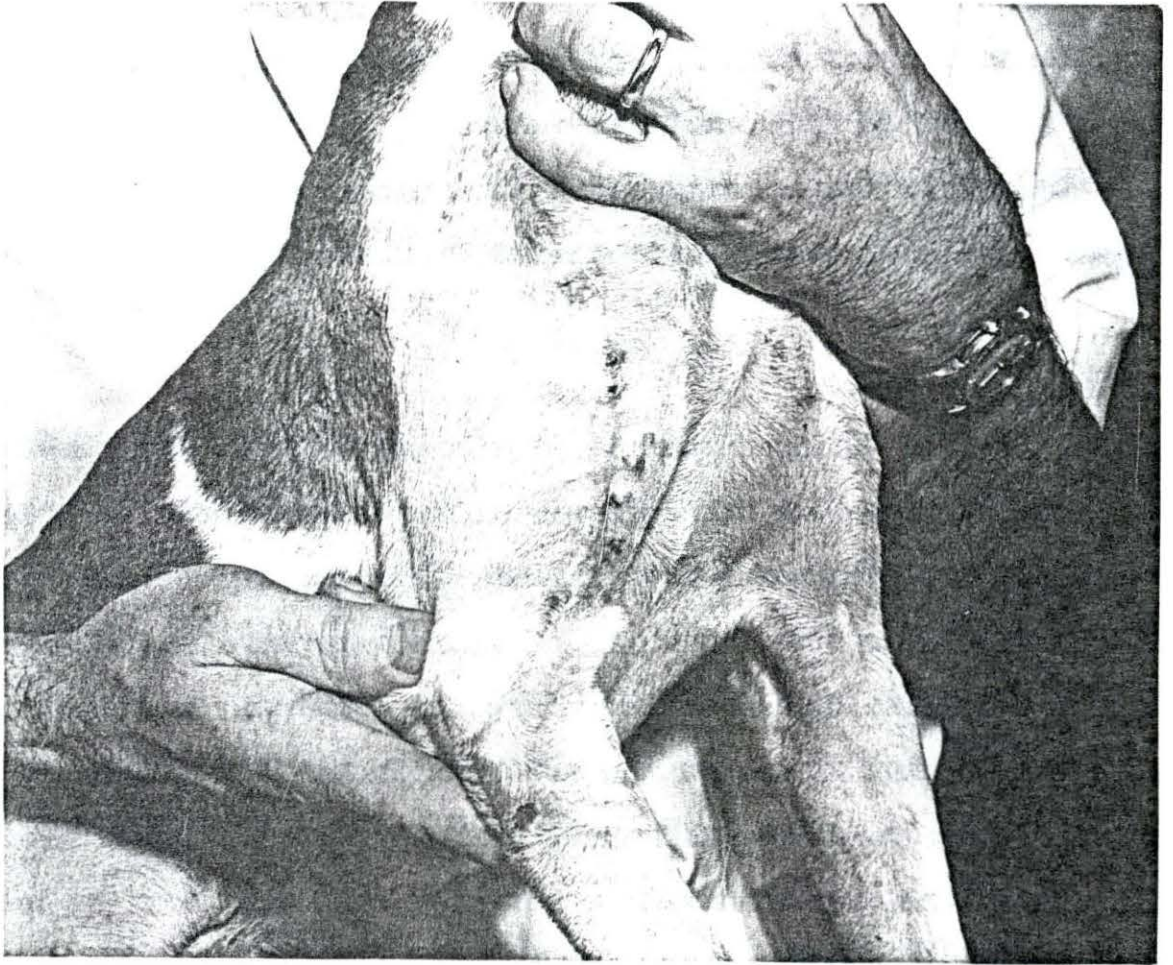
^aDog was used for other series.

^bClinical cases.

rect a chronic ulcerative dermatitis of the metatarsal area of the left leg. This case is also different in that the tube and graft were obtained from the left thorax. The left leg was then fixed to the thoracic wall and the tube and graft moved to the metatarsal region. The leg was immobilized for 9 days until the tube was severed. This resulted in a problem of immobilizing the leg so as to prevent damage to the graft and yet not interfere with the circulation of the leg. Restraint also became a problem as the patient objected to the immobilization of the leg. These difficulties were undoubtedly responsible for the poor results in this particular case. Since these were clinical cases there is also the possibility that more time should have been spent in preparing the graft bed prior to the actual transplant even though it would have meant a few more days of hospitalization. This might have resulted in a higher percentage of viability of the grafts.

The cosmetic appearance of the grafts was satisfactory although the areas which failed to remain viable distracted from the overall appearance. In the case of #107, skin for the graft was obtained from the antero-lateral aspect of the humeral region for reflection downward to the dorsal region of the radius and ulna. Fig. 13 shows the scarring which results on a short haired dog when a non-conspicuous donor area is used. The sutures were left in longer than necessary which added to the scarring.

Fig. 13. An immediate transfer of a tubed flap graft from the antero-lateral aspect of the humeral region 45 days after transplantation. Note the conspicuous scarring of the donor area



The rate of hair growth of the grafts was not changed significantly following the transplantations. The length and density of the hairs appeared to be similar to that of the donor sites.

The pliability of the skin was satisfactory, resembling that described in the preceding section.

The grafts were not affected by trauma associated with the activities of the dogs during the observation period.

C. Series 3

A total of 31 free full thickness grafts were performed on 11 dogs. Three of the dogs were clinical patients in which a total of 6 grafts were used. Twenty-six grafts were placed on non-granulating wounds while 5 grafts were applied to granulating lesions, 2 of which were used on clinical patients. Table 4 is a tabulation of the more pertinent information associated with the transplantation of free full thickness grafts when applied to non-granulating lesions. Those grafts which were applied to granulating lesions will be discussed in part 2 of this series.

1. Grafts applied to non-granulating lesions

The 26 grafts which represent the number of transplants utilized in this section, appeared to follow a very characteristic pattern as far as vascularization of the graft was

Table 4. Free full thickness grafts applied to non-granulating wounds

Case no.	Donor and recipient area	Size of graft and area grafted (inches)	Percentage of viability of each graft	Length of observation (days)
11	Left thorax to left tibial region (interchanged)	Thorax 1 1/4 x 1 1/4 Tibial 1 1/4 x 1 1/4	60 0	319 7
"	Right thorax to right tibial area (interchanged)	Thorax 2 x 2 Tibial 2 x 2	50 0	303 6
"	Left lumbar area to dorsal left metatarsal area	1 3/4 x 1 1/2	90	441
"	Medial thigh area to right and left forelegs	L 1 3/4 x 1 1/2 ^a R 2 x 1 1/2	10 0	199 7
101	Right thorax to right tibial area	2 3/4 x 2 3/4	60	716
"	Medial thigh region to right and left forelegs	L 1 3/4 x 1 1/4 R 1 3/4 x 1 1/4	100 0	321 6
102	Medial thigh region to right and left forelegs	L 1 1/2 x 1 1/8 R 1 1/2 x 1 1/4	10 75	65 65
104	Medial thigh region to right and left forelegs	L 2 x 1 1/2 R 1 3/4 x 1 1/4	100 100	263 263
105	Medial thigh region to right and left forelegs	L 2 3/4 x 1 1/2 R 2 x 1 3/4	0 0	6 6

^aR - right foreleg; L - left foreleg.

Table 4. (Continued)

Case no.	Donor and recipient area	Size of graft and area grafted (inches)	Percentage of viability of each graft	Length of observation (days)
107	Left thorax to right and left forelegs	L 1 1/2 x 1 R 1 1/2 x 1	0 80	6 32
208	Medial thigh region to right and left forelegs	L 1 3/4 x 1 R 2 x 1 1/2	20 0	20 9
209	Medial thigh region to right and left forelegs	L 2 x 1 R 2 x 1 1/2	100 50	17 17
18337 (clinical case)	Right thorax to over right eye	1 1/4 x 3/4	100	193
"	Left thorax to over left eye	1/2 x 3/4	100	170
"	Left thorax to center of forehead	1 x 1	95	170
"	Right thorax to forehead area	1 x 1	100	77

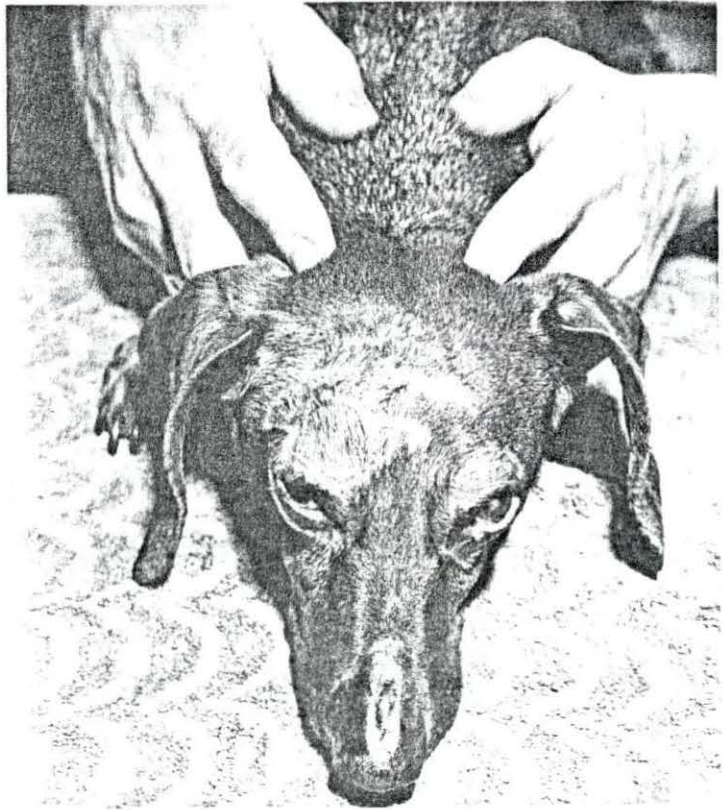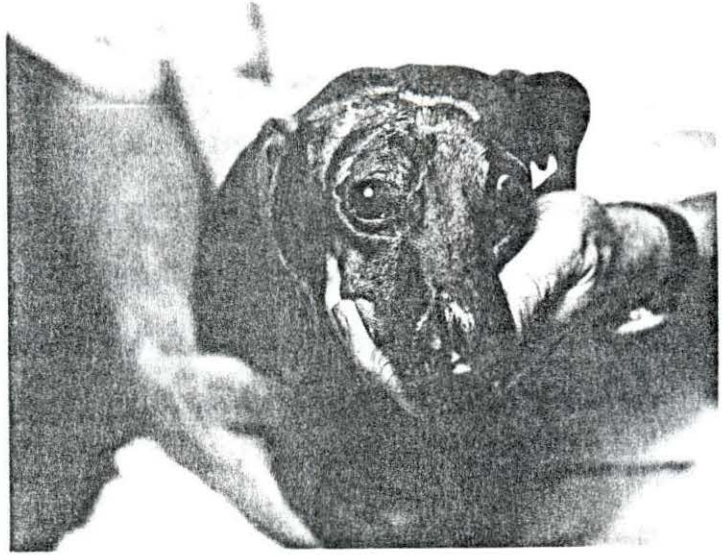concerned. On the second day following transplantation there was only a slight indication of the development of a new blood supply. The grafts were a bluish tinge with a faint reddish color at this time. By the 3rd and 4th days the reddish tinge became more evident. At the end of 6 days the successful grafts were showing a very prominent reddish color indicating an increase in blood supply to the area. It was observed in this series that the critical period for the transplants was the first 10 days. Those grafts which indicated successful "takes" at the end of 10 days continued to remain viable during the observation period. The most serious cause for loss of the grafts was a loosening of the bandages during the crucial period. The earlier in the period the bandages loosened the more likely the loss of the transplant. In Table 4, those patients which had a complete loss of their grafts, the day that the graft appeared dead, as evidenced by a white or black necrosis or due to self mutilation, is recorded as the length of the observation period. It was noted that all of the losses occurred within the first 10 days postoperative. Infection was not a problem except in case #208 in which the patient removed the bandage during the night of the 4th day and contaminated the area, resulting in a bacterial destruction of the graft by the 9th day.

The cosmetic appearance of the transplants cannot be evaluated separately in that the hair growth and the pliability

ity of the graft affected the cosmetic appearance in this series. Maximow and Bloom (1948) reported that in the human species the majority of the hair follicles are located in the hypoderm. Davis and Traut (1925, pp. 874-875) reported that the hair follicles were one of the most viable elements of the skin and least likely to be destroyed in the transplantation process. The density of the hair on the graft, therefore, would be dependent somewhat on the extent to which the hypoderm was removed from donor skin prior to transplantation. It was observed in this series that there was a decrease in hair growth in a small percentage of the cases. Clinical case #18337 was a Dachshund that had suffered severe burns over the forehead and both upper eyelids six months prior to surgery. Figs. 14 and 15 show the patient before and after surgery. A series of 4 grafts were made. The grafts used to replace the upper left eye lid indicate no loss of hair while the ones to replace the right upper eyelid and the 2 grafts over the forehead show a marked decrease in hair growth. This was probably due to the removal of an excess amount of hypoderm. The pliability of the 2 grafts on the forehead was not as satisfactory as the 2 over the eyelids as they appeared somewhat dry and leathery. This was relieved by applying Moruguent ointment daily for ten days. At the time this picture was taken all grafts were pliable. In case 101 the graft was removed from the right thorax to the right

Fig. 14. Severe burning of face six months previously resulted in scar tissue formation over eyelids, forehead and nose. The dog was unable to close its left eye

Fig. 15. The same dog 6 months after 4 free full thickness grafts were placed on forehead and over both eyelids. Note that the hair growth is less than that of the adjacent skin. Surgery was not performed on the dorsal aspect of the nose



tibial region, there was a slight pigmentary change. This was the only graft of the series in which this was noted.

Resistance to trauma appeared to be satisfactory following the first 21 days. However, in case #104, the dog was noted to be licking the graft two hundred days following transplantation, after exercising in cold weather. A mild erythema resulted, but subsided in 3 days with no treatment. There was no recurrence of this condition during the remainder of the observation period.

2. Grafts applied to granulating lesions

Five grafts were completed on granulating lesions. Table 5 contains some of the pertinent information associated with these transplants. Case #101 represents an ulcerative lesion on the dorsal right metatarsal region. This was initiated by a skin graft which failed and was perpetuated by the incessant licking of the patient. After 7 months, in which the lesion failed to heal, the granulation tissue was removed surgically and a free full thickness skin graft applied. Considerable hemorrhage resulted from the extirpation of the granulation tissue which was difficult to control even after Thrombin¹ was applied. Oozing hemorrhage still persisted and was evident even after the transplant was applied. As reported by

¹Parke, Davis and Co., Detroit, Michigan.

Table 5. Free full thickness grafts applied to granulating wounds

Case no.	Donor and recipient area	Size of graft (Inches)	Percentage of viability of each graft	Length of observation (Days)
101	Medial right thigh region to right dorsal metatarsal area	1 1/2 x 1	10	382
	Right thorax to right dorsal metatarsal area	2 x 2	0	25
102	Left thorax to left tibial region	2 x 2	60	567
301 ^a	Left thorax to left dorsal metatarsal area	3 1/2 x 3	0	14
19350 ^a	Right thorax to right carpal region	2 1/2 x 1/2	80	14

^aClinical cases.

King (1945) this can interfere with the viability of a graft. After ten days of questionable viability, all of the graft except about 10 per cent became necrotic. Twelve months later, following other transplantation experiments, the same area was regrafted. This time the granulation tissue was removed 3 days prior to the transplantation so that hemorrhage would not be a problem. This attempt was even less successful than the first. The viability of the graft was doubtful for 10 days as the graft remained blue in color with very little redness appearing. After 6 days there appeared to be an erosion of the epithelium. After 10 days it became apparent that the graft was unsuccessful although there appeared to be remnants of hair follicles over parts of the grafted area. The lesion never did heal as the dog persisted in his licking habits. Case #301 was a clinical patient which had a similar condition caused by an injury and followed by persistent licking of the lesion. The transplant on this patient followed a similar pattern as that explained in case #101. Clinical case #19350 was a patient which had a lesion of the dorsal carpal-metacarpal area following an automobile accident which denuded an area $3/4$ in. wide by $2\ 3/4$ in. long. After 13 days satisfactory granulation had occurred so that a graft was attempted. This transplant required 5 days before a satisfactory reddish tinge appeared and 12 days before it could be ascertained if the tissue would be viable. A small ero-

sion of the epithelium occurred in the center of the graft on the 12th day. Case #102 followed a similar pattern. There appeared to be a delay in vascularization of the grafts with a lower percentage of "takes" than was evident for those transplants applied to non-granulating lesions.

Although there were only 5 grafts to evaluate, the cosmetic appearance, hair growth, pliability and resistance to trauma appeared to be similar to the transplants applied to non-granulating wounds.

D. Series 4

Five split thickness grafts were performed on 4 dogs for this series. Considerable difficulty was encountered in obtaining satisfactory sized grafts since the dog has few areas where the anatomical structures are such that a rather large flattened area of skin exists. The Brown dermatome was designed primarily for use on the human species, so was not completely adaptable for use in the dog. As a result, the lateral wall of the thorax seemed to be about the only area where the machine worked fairly well. Although the sizes of the recipient areas were rather small, 3-4 strips of skin were used to cover the site due to faulty removal which might be partially attributed to inexperience in operating the dermatome.

Table 6 depicts some of the more pertinent information associated with the transplants in this series. Being able to determine the viability of these transplants was somewhat more difficult than in any of the other series described heretofore. Since the bandages were changed at 4-5 day intervals in 3 of the 5 cases, so as not to needlessly disturb the grafts, it was not possible to observe them each day. The bandages on cases #102 (second graft) and #105 were removed on the 4th day. The grafts appeared to be somewhat blue in color interspersed with tinges of red. Case #102 had a small white colored area in the corner of the graft. By 7 days the graft was red in color. Some exudate appeared around the transplant. After 14 days the bandages were not replaced. At this time the transplant appeared healthy although there was some shrinking and scaling of the graft. Case #105 was not rebandaged after 5 days because the dog was not disturbing the area. The graft became dry and showed some shrinking at the end of 11 days. Similar results were obtained with case #101 except that it did not indicate a healthy condition until about 9 days. The bandages were not removed from case #11 until the 10th day. There was considerable exudate over the graft at the time of the bandage removal. Three days later the transplant resumed a healthy appearance. The transplant from the left thorax to the right lumbar region in case #102 was placed over granulation tissue. The changes associated

Table 6. Split thickness skin grafts removed with a Brown dermatome

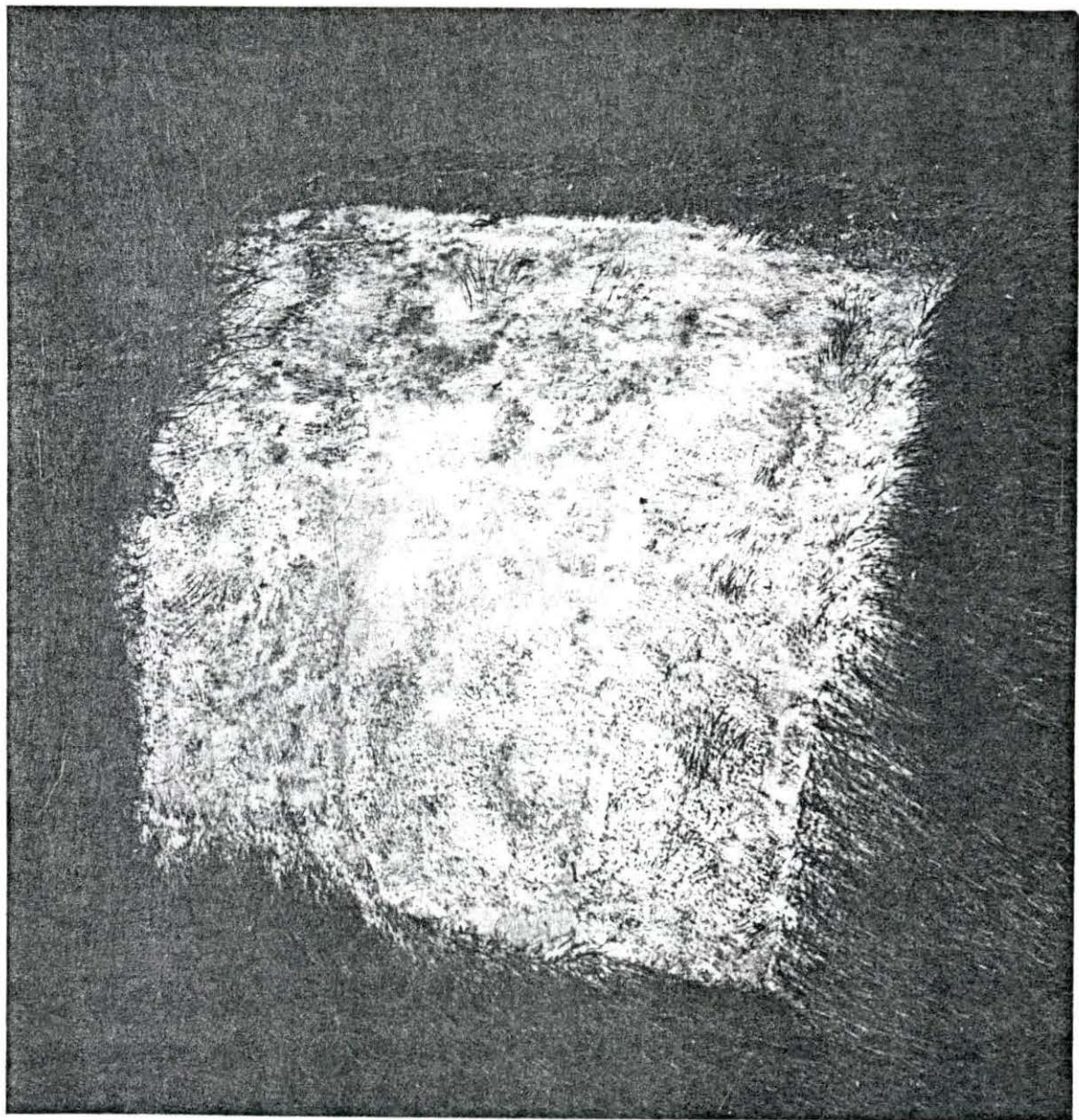
Case no.	Donor and recipient area	Size of graft (inches)	Percentage of viability of each graft	Length of observation (days)
11	Left thorax to right thorax	4 x 4	40	350
101	Right thorax and replaced to the same area	4 1/2 x 4 1/2	95	337
102	Left thorax to right lumbar area	2 x 2	50	334
"	Left thorax to right thorax	3 1/4 x 3	90	200
105	Right thorax and replaced to the same area	4 x 3 1/2	75	84

with the vascularization of the graft were not significantly different from the other 4 grafts placed on non-granulating lesions.

The cosmetic appearance of the grafts was not as satisfactory as those resulting from the tube flap or the free full thickness methods. The transplants developed a scaly appearance about the 11th day. This tended to persist indefinitely although not as severe as during the first few weeks. Case #101 was observed for 337 days during which time there was a marked exfoliation from the transplanted area. This graft was cut at a depth of .035 in. which probably is very near the complete depth of the normal skin in the thoracic area. When examined microscopically there was evidence of sebaceous and sudoriferous glands being present suggesting that the graft might have included all of the skin layers. In spite of this there was some shrinking and considerable scaling of the transplant. All of the other grafts were cut at .030 in. for transplantation. Scaling was also evident in these grafts.

Hair growth was not observed on the grafts except in case #101 in which the graft might have been nearly a full thickness transplant. Fig. 16 shows the small amount of hair which has grown from the graft after 42 days. All of the other grafts were hairless because the hair follicles are located in the deeper layers of the corium and the hypoderm.

Fig. 16. Split thickness graft in the thoraco-lumbar region .035 in. thick. 42 days postoperatively



The pliability of the transplants left much to be desired. Even after several months the grafts had a "leathery" character when palpated. Very little subcutaneous fat accumulated underneath the split thickness grafts which made them less pliable than the full thickness grafts.

The grafts were not traumatized by the dogs under kennel conditions, but this might not have been the case if the dogs could have been free to run. Also, the fact that the transplants were located on the lumbar and dorsal-lateral thoracic wall would tend to lessen the chances for injury were they located on the extremities.

E. Series 5

Five dogs were utilized to produce a total of 8 graft areas which were used for the application of the small deep graft technique. Table 7 enumerates some of the more pertinent information concerned with this series.

It was observed that producing experimental lesions on the lateral thoracic wall of the dog created difficulty in evaluating the value of the seed grafts in that the looseness of the skin in this region in conjunction with the decrease in size of the wound resulting from cicatrization of the site, made a relatively large lesion appear small in 10 to 14 days. Table 7 shows the decrease in size of the original wound in contrast to the size of the same lesion following the period

Table 7. Small deep grafts performed on granulating lesions

Case no.	Original size and location of lesion (inches)	Size of lesion following specified granulation period (inches)	Number of grafts "seeded"	Number of grafts that survived	Observation period (days)
301	3 x 1 3/4 right thorax	2 x 1 (10 days)	11	5	40
302	5 x 5 left thorax	2 x 3 1/2 (9 days)	30	10	33
	3 x 3 3/4 right thorax	2 3/4 x 1 3/4 (8 days)	22	21	12
303	2 x 2 1/4 left thorax	1 1/2 x 1 (16 days)	10	2	60
	3 1/2 x 3 1/4 right thorax	2 1/4 x 2 1/2 (7 days)	17	11	27
304	3 1/2 x 4 1/2 right thorax	2 7/8 x 2 3/8 (11 days)	11	0	56
	4 x 3 left thorax	3 x 2 (7 days)	21	8	34
305	2 3/4 x 2 1/4 right thorax	2 x 1 3/4 (7 days)	43	27	53

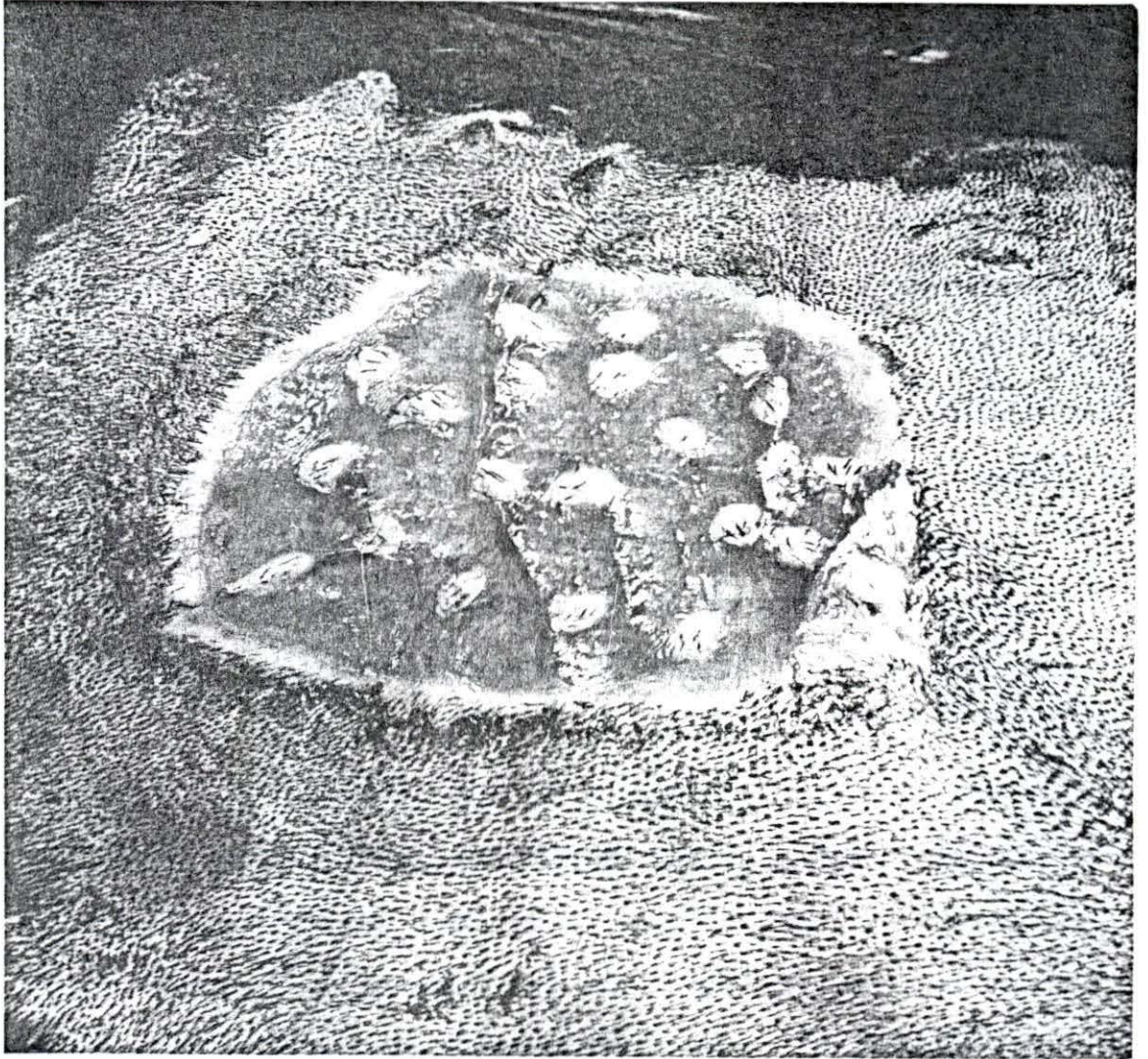
allowed for a satisfactory granulation bed to occur. It was soon realized that the original experimental lesion would have to be at least 3 in. x 3 in. in size or the area would be too small for satisfactory evaluation of this technique as the wound would be nearly completely epithelized in about 21 days. Probably this could have been avoided if the lesions had been produced over the lumbar or thigh area where the skin was not so loose and hence wound closure from scar tissue would not have been as great.

The lesion on the left thorax of case #303 was allowed to granulate for 16 days prior to grafting because the dog was pregnant during earlier experiments and whelped the day following the formation of this lesion. This produced an extra strain on the animal which might have been responsible for a delay in formation of good healthy granulation tissue.

Fig. 17 shows a seed graft which has been in place for 9 days. The condition of the seed bed of this graft was excellent and the seeds appeared to be viable. As shown in this picture and also present in the other grafts of this series, it appeared that the placing of the "seeds" closer together would probably have been better as each island of skin would have coalesced sooner and more completely.

The viability of the seed grafts was determined by macroscopic examination. Only the grafts which were present at the end of the observation period were counted as being viable.

Fig. 17. Small deep grafts 9 days following transplanta-
tion



After the bandages were removed on the 12th day, cases #303 and #304 destroyed, by licking or chewing, a number of the viable grafts.

The cosmetic appearance of the transplants was not as satisfactory as those of the free full thickness or pedicle grafts. However, they were more satisfactory than the split thickness grafts. A "cobble stone" effect resulted on the healed area, both at the donor and recipient site. Probably placing the seeds about 1/4 in. apart would have resulted in a more favorable cosmetic appearance. Davis (1914, p. 989) stated that by placing the small deep grafts closer together the appearance of the grafted area was very much improved. He suggested that the "seeds" be placed no farther than 5 mm. apart.

Hair growth was very scanty in this type of graft since only a few hair shafts appeared on each island of skin. This was due to the size of the grafts as well as the technique used in cutting the "seeds" from the donor area because only the center portion of each graft contained the full thickness of the skin.

The pliability of the grafted area did not approach that of a free full thickness nor a pedicle transplant. The skin felt somewhat roughened and very little subcutaneous tissue was present to add to the pliability of the area.

Resistance to trauma was somewhat better than for those patients in which a split thickness was used. In those areas where the seeds were not sufficiently close together so as to cause a coalescing of the adjacent islands of skin, scar tissue epithelium covered the area and hence was very thin and susceptible to trauma.

F. Series 6

The purpose of this series was to study the macroscopic and the histopathological changes which occur when a free full thickness of skin was removed from one area of the body and transplanted to an experimentally produced lesion. The medial aspect of the thigh was selected as the donor area while the dorsal metatarsal region served as the recipient site. Six dogs were utilized in this study. One graft was performed on each rear leg of the dog, making a total of 12 transplants. The size of the grafts was $3/4$ in. x $1\ 1/4$ in. since small breeds of dogs were used. At 2 day intervals a $3/8$ in. section transverse to the long axis of the graft involving the entire width of the transplant plus about $1/4$ in. of the normal skin on each side was removed for histopathological study.

Table 8 presents some of the more important details concerned with this study. An attempt was made to correlate the macroscopic appearance of the grafts with the microscopic findings.

Table 8. Free full thickness grafts used for histo-pathological study

Case no.	Donor area	Macroscopic appearance of each graft	Time when removed for histo-pathological study (days)
306	medial left thigh	right - blue in color ^a	2
		left - blue tinged with red	4
305	medial left thigh	right - red color predominant	6
		left - area of erosion of the epithelium	8
304	medial left thigh	right - a complete "take"	10
		left - a complete "take"	12
303	medial right thigh	right - some erosions of epithelium	14
		left - a complete "take"	16
302	medial left thigh	right - some erosions of epithelium	18
		left - a complete "take"	20
301	medial left thigh	right - a complete "take"	22
		left - a complete "take"	24

^aRight dorsal metatarsal region; left dorsal metatarsal region.

Fig. 18 shows a normal section of skin removed from the medial thigh region, the donor area for this series.

Grossly the transplant which had been in place for 2 days had a bluish tinge. Histological examination revealed necrosis of the superficial layers of the epidermis of the skin graft and mild leucocytic infiltration in the subepithelial tissues (Fig. 19) at the border of the skin graft and the skin.

The 4 day old graft appeared to be "taking" with a tinge of red permeating the transplant. When the graft was removed for study, there was some adhesion of the transplant to the underlying tissue. Microscopic examination revealed a more advanced necrosis of all layers of the epidermis of the skin graft. Degenerative changes in the stratum germinativum (Fig. 20) and some minute ulcerations were present. There was increased leucocytic infiltration of the subepithelial tissues in comparison with the previous grafts. There were indications that some revascularization was occurring in focal areas of the transplant as noted by the presence of erythrocytes in some blood vessels.

Macroscopically, the 6 day graft appeared to be "taking" as indicated by a diffuse red color. Histopathological study revealed necrosis of the epidermis (Fig. 21) of the graft throughout most of its length except at one end where the epidermis was of normal thickness and appearance. The epi-

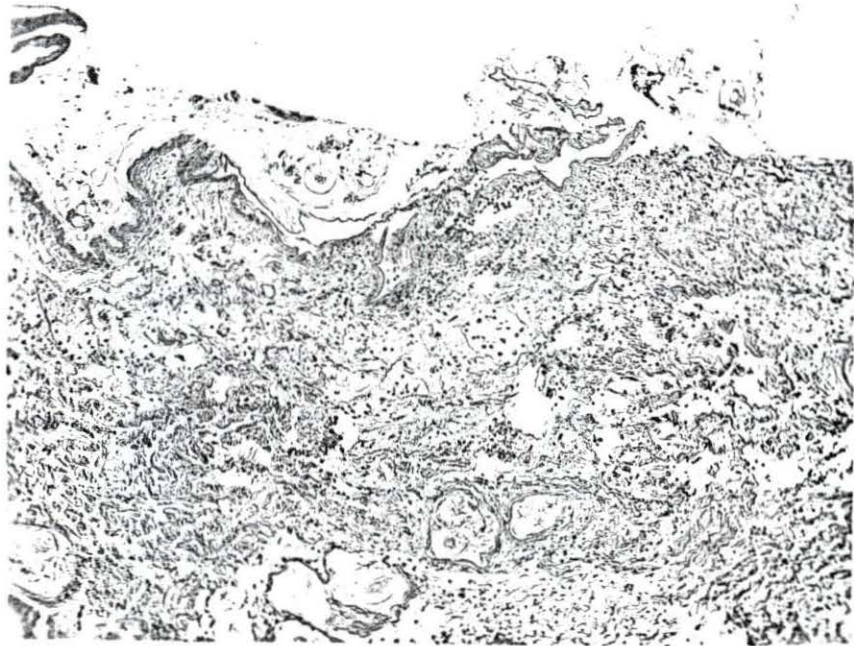Fig. 18. Section of skin removed from the medial thigh region which was the donor area for this series. 96X

Fig. 19. A graft 2 days old. Note the degenerative changes of the superficial layers of the epidermis and the mild leucocytic infiltration. 96X


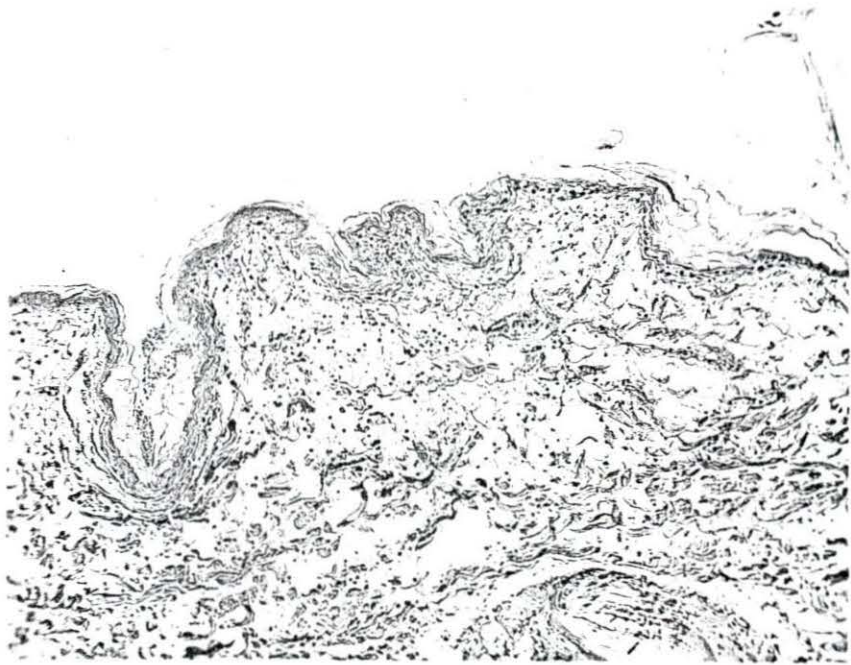


Fig. 20. A skin graft 4 days after transplantation. Note that the degenerative changes have extended into the stratum germinativum and the increased leucocytic infiltration in the subepithelial tissue. 96X

Fig. 21. A skin graft of 6 days duration. Note the increased leucocytic infiltration of the graft. Much of the epidermis shows severe degenerative changes. 96X

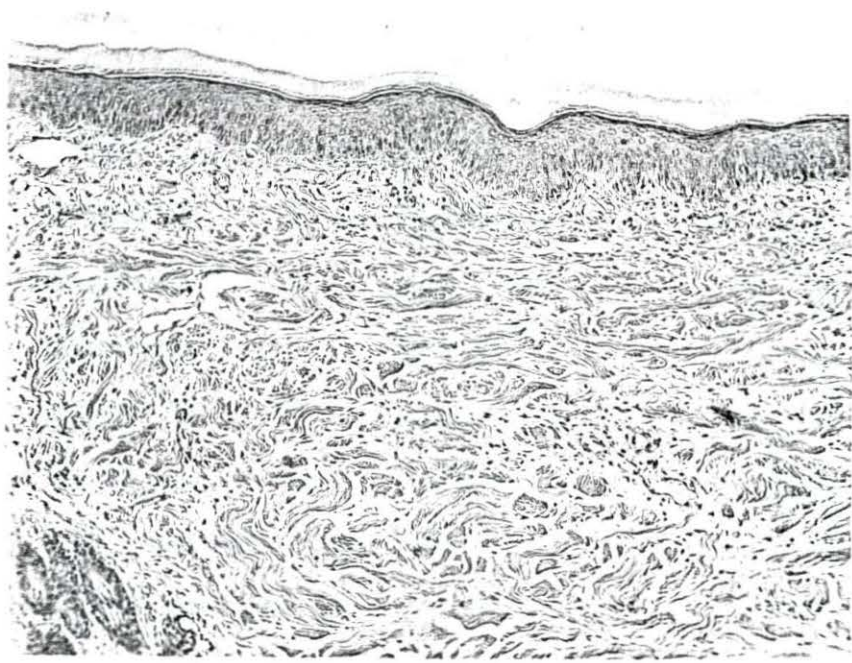



thelium of many hair follicles appeared intact and normal. In a few there was hyperkeratinization of the follicles and loss of a few hair shafts. Hyperemia, fibrin, hemorrhage and granulation tissue were noted in the deeper layers of the transplant at its junction with the normal tissue. In the areas of granulation tissue there was a heavy leucocytic infiltration. A mild leucocytic infiltration was noted throughout the graft.

Grossly, the 8 day graft appeared to have sloughing or erosion of the epithelium near its center. Microscopic examination revealed that there was a necrosis of the layers of the epithelium which had the appearance of kerato-hyaline. In most of these same areas much of the stratum germinativum was undergoing degenerative changes while in others the nuclei of the stratum germinativum appeared fairly normal. Focal ulceration (Fig. 22) was apparent. In the corium of the graft some leucocytes were noted. In the deeper layers, there was well formed granulation tissue. In some blood vessels erythrocytes and leucocytes were apparent. Atrophy of some blood vessels was noted. In the normal tissue at the edge of the graft well formed granulation tissue was extending into the graft. Only small amounts of fibrin and hemorrhage were noted at the junction of the graft with the adjacent tissue.

Fig. 22. A skin graft of 8 days. Focal areas of ulceration are apparent. There is some degenerative change in the stratum germinativum. A few leucocytes are present in the corium. 96X

Fig. 23. Ten day old skin graft. Note that the dermis appears to be intact with very few leucocytes in the corium, but collagenous fibers are very evident. 96X



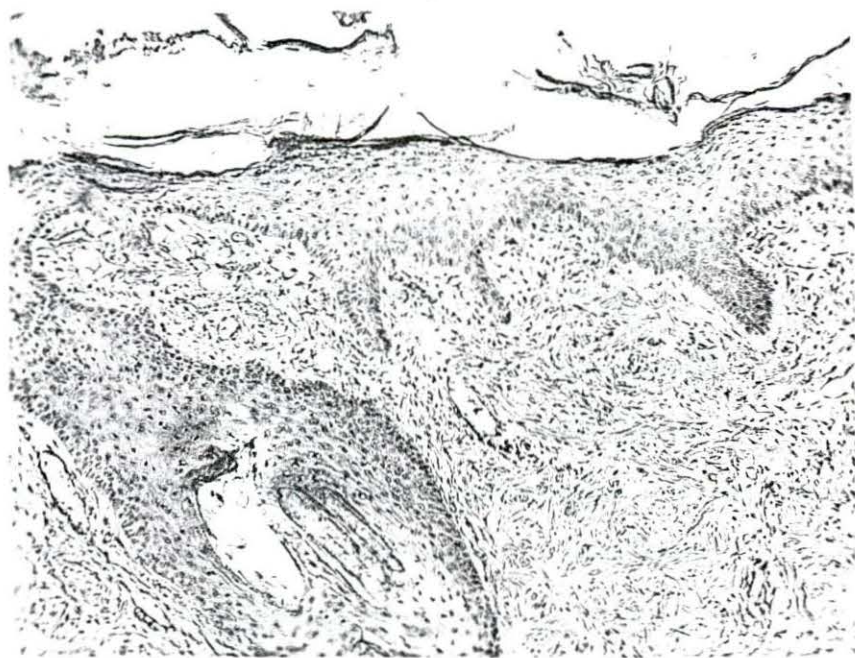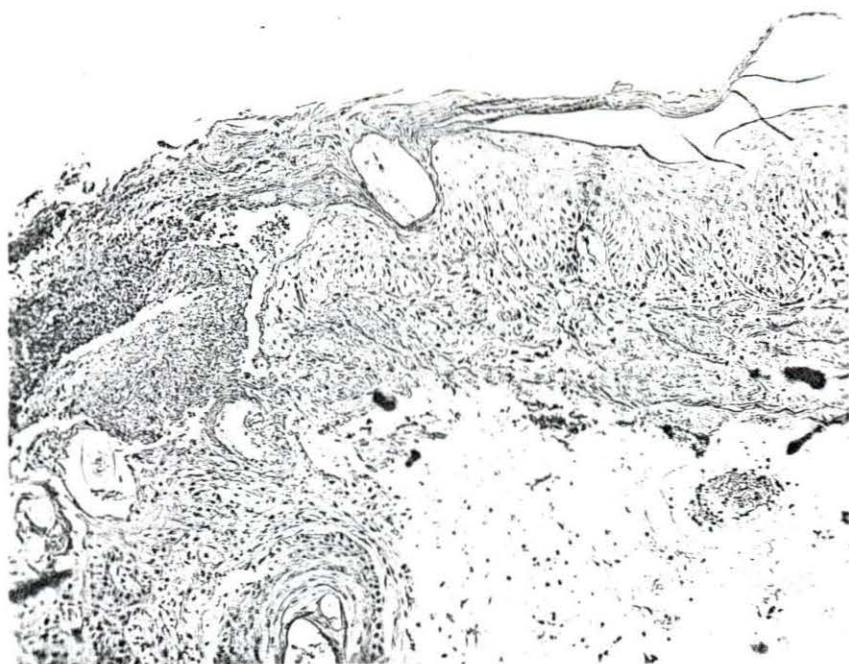
The 10 day graft was an apparent "take" and appeared to have a satisfactory blood supply. Microscopically, the epidermis appeared to be intact with very few leucocytes in the corium (Fig. 23), but collagenous fibers were very evident. There was a complete bridging of the epithelium between the skin graft and the adjacent skin. In the corium at the ends of the graft, small vascular sinuses were noted containing blood. Granulation tissue in the same region was very pronounced, but it definitely was showing maturation. Functional blood vessels were noted. Very few hair follicles were evident.

The 12 day transplant had a normal color and appeared to be intact throughout. Microscopically, the epithelium as a whole appeared normal and intact, but there were a few foci of microscopic ulcerations with marked leucocytic infiltration (Fig. 24). In the corium of the graft, the hair follicles appeared normal. In the deeper layers of the corium of the transplant, granulation tissue with marked leucocytic infiltration was present. Functional blood vessels of the graft were evident. At one end of the skin graft in the corium a sinus was noted containing strands of fibrin.

Grossly, this 14 day graft showed considerable superficial necrosis indicating possible trauma. The microscopic study showed severe ulceration and traumatization of the

Fig. 24. A 12 day old skin graft. Note that the hair follicles appear normal. Functional blood vessels are present indicating satisfactory revascularization of the graft. The epithelium is intact except for small focal ulcerations. 96X

Fig. 25. A 16 day old skin graft. Basal layers of the epidermis are showing definite rete-pegs. There is maturation of the granulation tissue. 96X



transplant which would not be typical of a viable graft at this stage.

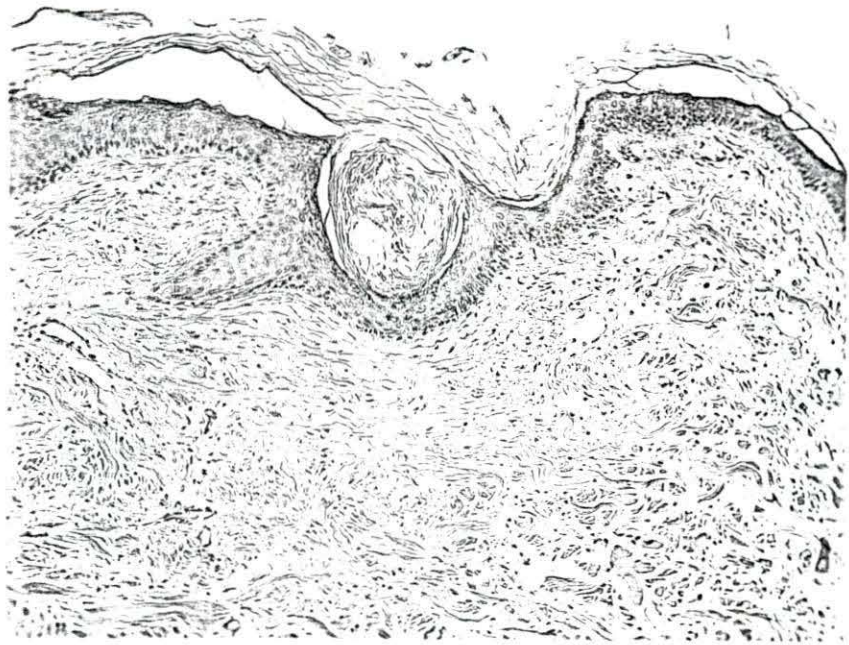Macroscopic observation of the 16 day graft showed a healthy transplant indicating a complete "take". Histological examination revealed an almost intact epithelium (Fig. 25) with some microscopic ulceration and focal areas of hyperkeratosis. The basal layers of the epidermis were showing definite rete-pegs. Maturation of the granulation tissue was pronounced. There was a definite reduction in leucocyte numbers and a gradual disappearance of granulation tissue.

Grossly the 18 day graft showed some erosion of the epithelium which was not characteristic of a successful "take" for that length of implantation. On microscopic examination there was much subepithelial granulation tissue and subepithelial cellulitis. Healing was occurring, but inflammatory reaction was also present.

The 20 day old graft appeared to be a complete "take" with the surface appearing intact. Microscopically, the graft indicated that healing was almost complete, but there were still foci of granulation tissue containing giant cells.

The 22 and 24 day old grafts appeared to be successful grafts when observed macroscopically. Microscopically, the 22 day old transplant resembled normal skin. There was some hyperkeratinization (Fig. 26) in the hair follicles. The 24

Fig. 26. A skin graft of 22 days. The graft nearly resembles that of normal skin. Since the original graft came from the medial aspect of the thigh where the hair is sparse, few follicles were evident on each section. 96X



day graft also resembled normal skin. Some granulation tissue remained at the ends of the graft.

V. DISCUSSION

The basic surgical techniques which are successful for skin transplantation in the human species are also applicable to the dog. However, the bandaging and postoperative care differ considerably. Restraint, effective bandaging and the possibility of contamination are problems which become magnified in the dog.

Four types of skin grafts were attempted on experimental animals and clinical cases to assess their value as a means of correcting defects of the integument. It was found that there was not a single type of graft which would meet all of the requirements of a successful graft on all regions of the body.

The criteria used for the final evaluation of the grafts in the various series included the following: (1) percentage of viability of each graft, (2) cosmetic appearance of the graft, (3) hair growth, (4) pliability, (5) resistance to trauma. It was found that the delayed tube flap or pedicle was the most successful graft used in this study with regard to percentage of viability. Other qualifications, as listed above, were also favorable. This method was very well adapted to lesions on the extremities of the rear legs. The formation of a delayed tube graft on the forelegs would have been more difficult due to a lack of sufficient skin in the axillary region. Although the technique gave the best results,

it appeared to be best adapted to the rear legs since the tube can be formed on the medial aspect of the tibial region and thigh thus lessening the chances for a conspicuous scar. This graft is limited to relatively small areas of transplantation because the area of skin removed for the tube must either be covered with another graft or by "skin shifting". In the dog the practical approach would be the latter. If the tube is excessively long there is the possibility of a faulty blood supply to the tube with necrosis of the pedicle. Davis and Davis (1949, p. 102) reported that in the human species the length of the tube used for an immediate tube flap should not be over 2 1/2 to 3 times its width. This is probably a good criterion to follow even in the use of the delayed transfer of a tube flap. Since the available skin on the medial aspect of the tibial region is limited, it was necessary to remove an additional section of skin proximal to the tube which was used to cover the defect. Because this segment of skin was also dependent on the tube for its blood supply, a tube no longer than necessary was advantageous. In this study the maximum size of the tubes used without any serious interference to the blood supply was 1 1/4 in. x 5 in. Davis and Davis (1949, p. 99) suggested that the blood supply of the tube can be ascertained by compressing the pedicle with a rubber tube at the proximal end and observing whether there is a "blanching" of the tube due to an insufficient blood supply from the

distal end. This was not done in this study because it was considered more important to observe the viability of the grafts when transferred at varying intervals following their formation.

The immediate tube flaps were not as successful as the delayed pedicle although they gave promise of being of value in transplants on the extremities. Three of these grafts, used on the forelegs, were partially successful. The remaining grafts were placed on the metatarsal and tibial-tarsal region. The length of the tubes was kept as short as possible, the longest being 4 inches long and 2 inches wide. Some difficulty was experienced immobilizing the leg and maintaining sufficient pressure on the transplant without interfering with the blood supply of the tube.

Thirty-one free full thickness grafts were made. Five of these were placed on granulating lesions. May (1947, p. 20), referring to the human species, stated that the full thickness graft would not "take" on an infected area no matter how harmless the infection. He further stated that on granulation surfaces only one type of skin graft comes into consideration and that is the split graft. Since only 5 grafts were applied to granulating lesions, it is difficult to ascertain whether the above is also true in the dog. Those grafts which were placed on non-granulating, non-infected lesions that were lost during the first 10 days were due pri-

marily to problems encountered with bandaging and restraint. This type of graft is the most difficult to accomplish. Blair (1924) reported this as also being true in the human species. The clinical application for this type of graft includes covering areas of the legs or face following surgical removal of large tumors in which the denuded area cannot be covered by "skin shifting". The cosmetic appearance, hair growth and pliability of the skin is excellent, if a satisfactory "take" can be accomplished. Byars (1942) reported in the case of man, that the smaller free full thickness grafts were easier to obtain "takes".

The small deep grafts or seed grafts are not as cosmetically acceptable as either the free full thickness or the pedicle grafts. Since epithelization has to occur from the periphery of each seed, the grafts must be sufficiently close together so that they eventually coalesce. Eight grafts were performed on granulating wounds of the thorax. The size of the lesions varied from 1 in. to $2 \frac{3}{8}$ in. wide by $1 \frac{1}{2}$ in. to 3 in. long. The area was found to be too small for a satisfactory evaluation of the technique since cicatrization caused a shrinking of the area by at least $\frac{1}{4}$ of the original size in 10 days. One area $2 \frac{7}{8}$ in. x $2 \frac{3}{8}$ in. was reduced to $\frac{3}{4}$ in. sq. in just 21 days. It is doubtful whether an area less than 3 in. square should be grafted due to the looseness of the skin on the thorax and the resultant shrinking of

the wound. The area was not as resistant to trauma as the pedicle or free full thickness transplants. Since the "seeds" were not originally attached to the "seed bed", trouble was experienced in immobilizing the grafts. This was corrected by suturing the dressings to the adjacent skin.

The split thickness, although one of the easiest grafts to obtain a "take", had many objectionable features. Difficulty was experienced in finding a suitable donor area for the use of the Brown Dermatome since the dog has very few flat areas of skin. The shrinking and scaling of the transplants were objectionable. Also, there was no hair growth. Since the grafts were not as resistant to trauma as the full thickness transplants, it would not be advisable to use this type of graft on the extremities of the dog where it would be more susceptible to injury. One of the main indications in the canine species would be following severe burns where extensive areas of the integument had been destroyed.

From the limited histo-pathological studies made in this series, there appears to be degenerative changes in the transplant for the first 8-10 days at which time a balance is reached and regeneration of the surviving elements then exceed that of degeneration. Davis and Traut (1925) stated that this turning point was dependent upon, and determined by, the establishment of an adequate blood supply. The epidermis appeared to show the severest degenerative changes although

there were also changes in the dermis involving some of the blood vessels. The hair follicles and sebaceous glands showed the least degenerative changes. This concurs with the findings of Davis and Traut. It is realized that there is considerable room for error since this study was not repeated several times to confirm the original findings. However, the findings of this study closely follow the pattern described by Davis and Traut which were based on a series of studies on the dog. Microscopic and macroscopic examination of the grafts studied seemed to indicate that the blood supply was adequate by 12 days. The transplants were returning to a nearly normal status by 24 days which was the termination of this study.

Injuries to the grafts from trauma following successful transplantation were not a problem in this study. Since most of the cases were kenneled patients, there is the possibility that a dog which has "free run" might have subjected the graft to injuries which would not occur under kennel conditions.

It is realized that there was no series in this study related to the returning of innervation to the various types of grafts. This would be most interesting providing satisfactory means of evaluating the sensations of pain, cold and heat could be devised for the dog. This information would be valuable since the transplant is in danger of severe trauma until such time as the area becomes re-innervated. McCarroll

(1931), Davis (1934) and Davis and Kitlowski (1934) reported their findings in the human species concerning the return of sensation to the transplant. Whether this would be similar in the dog would have to be ascertained by further study.

The inability to secure sufficient clinical cases for this study is also a matter of consideration. Most of the lesions were experimentally produced which might have affected the final results.

It is believed that the modified sieve graft as reported by Dragstedt and Wilson (1937) in the human species should be experimentally attempted on the dog for lesions of the thorax requiring skin grafting. This graft should have many of the advantages of the small deep graft as well as overcoming some of the difficulties of the seed graft such as the difficulty of immobilizing the small grafts until healing occurs. This technique employs a full thickness graft which is oval in shape. The size of the graft must be $\frac{1}{3}$ longer and a $\frac{1}{3}$ to $\frac{1}{2}$ wider than the defect to be covered. After the graft has been removed from its donor area, it is placed dermal side down and with a sharp scalpel numerous short incisions are made so that they overlap, and when completed, will permit the graft to be stretched into any desired shape. This technique provides for adequate drainage, thus affording better opportunity for overcoming wound infection without loss of the graft. The successful graft would have somewhat the appear-

ance of a seed graft. However, it would be much easier to immobilize the graft in place during the revascularization period.

Due to the looseness of the dog's skin in areas of the neck, thorax and lumbar region and the resultant shrinking of the wound following healing, skin grafting in the canine species has its greatest indications in facial lesions and injuries of the skin of the extremities.

VI. CONCLUSIONS AND SUMMARY

1. Four different types of autogenous skin grafting techniques for use on the dog have been presented involving a total of 98 grafts.

2. Restraint, maintenance of a satisfactory pressure bandage and prevention of contamination of the grafted area appeared to be the greatest difficulties encountered in this study. With proper observance of these prerequisites, a satisfactory percentage of grafts can be successful.

3. No single type of skin graft was uniformly successful for all areas of the dog's body nor for all kinds of skin lesions.

4. The delayed transfer of a pedicle graft appeared to be the most successful and satisfactory transplant for lesions of the extremities, especially the rear legs.

5. The free full thickness graft was relatively successful for those lesions free from infection and excessive granulation tissue.

6. The small deep graft, although easy to perform, does not result in as good a cosmetic appearance as either the free full thickness or the pedicle transplant since it results in a "cobble stone" or a "pitting" effect to both the donor and the recipient area.

7. To obtain a satisfactory split thickness graft requires rather expensive equipment primarily designed for use

on the human species. Following transplantation there is no hair growth and the scaling of the epithelium for several weeks to months is cosmetically objectionable. The resistance to trauma is not as good as for the full thickness or the pedicle graft, so should be used only over the lumbar or dorsal thoracic region where it is less likely to be injured.

8. Areas on the thorax less than 3 in. x 3 in. need not be grafted as cicatricial tissue will result in a complete closure of the lesion in 3-5 weeks with very little scarring due to the looseness of the integument in that area.

9. From the limited histo-pathological work done on the transplants it appeared that there were considerable degenerative changes involving the epidermis and the upper layers of the dermis during the first 8-10 days at which time the regenerative processes equalized the degenerative changes. The blood supply appeared adequate by the 12th day and the transplants were rapidly returning to a nearly normal status by 24 days which was the termination of the study.

10. Skin grafting in the dog has its greatest indications in facial lesions and injuries to the skin of the extremities.

11. Injury to the grafts, as a result of trauma, following successful transplantation were negligible in this study.

VII. LITERATURE CITED

- Armistead, W. W. (1956). An experimental method for intestinal anastomosis in small animals. *North American Veterinarian* 37: 968-972, 977-978.
- Blair, V. P. (1924). The full thickness skin graft. *Ann. Surg.* 80: 298-324.
- Byars, L. T. (1942). Free full thickness skin grafts - Principles involved and technique of application. *Surg. Gynec. and Obst.* 75: 8-20.
- Cawley, A. J. and S. M. Francis. (1958). Pedicle graft in a dog - A case report. *Cornell Veterinarian* 48: 13-16.
- Davis, A. D. (1927). The management of Wolfe grafts. *Ann. Surg.* 86: 947-948.
- Davis, J. S. (1914). The use of small deep skin grafts. *Jour. Am. Med. Assoc.* 63: 985-989.
- _____. (1925). The nomenclature of skin grafting. *Surg. Gynec. and Obst.* 41: 841-842.
- _____. (1929). The small deep graft - Relationship to the true Reverdin graft. *Ann. Surg.* 89: 902-916.
- _____. (1930). The small deep graft. *Ann. Surg.* 91: 633-635.
- _____. (1940). The use of small deep grafts in the repair of surface defects. *Am. Jour. Surg.* 47: 280-296.
- _____ and W. B. Davis. (1949). Plastic surgery. In *Lewis' practice of surgery* 5: 1-191. Hagerstown, Maryland. W. F. Prior Co., Inc.
- _____ and E. A. Kitlowski. (1934). Regeneration of nerves in skin grafts and skin flaps. *Am. Jour. Surg.* 24: 501-545.
- _____ and H. F. Traut. (1925). Origin and development of the blood supply of whole thickness skin grafts. *Ann. Surg.* 82: 871-879.
- Davis, L. (1934). The return of sensation to transplanted skin. *Surg. Gynec. and Obst.* 59: 533-543.

- Dragstedt, L. R. and H. Wilson. (1937). A modified sieve graft - A full thickness skin graft for covering large defects. *Surg. Gynec. and Obst.* 65: 104-106.
- Jensen, E. C. (1957). Skin grafting in the dog. *Iowa State College Vet.* 19: 163-169.
- King, M. K. (1945). Immediate skin grafting following injuries. *Surg. Gynec. and Obst.* 81: 75-78.
- Keefe, F. (1946). Skin grafting in a cat. *Jour. Am. Vet. Med. Assoc.* 108: 43-48.
- Krause, E. (1893). Transplantation of large unpedicled skin flaps (English translation). *Verhandl d. deutsch Gesellschaft. f. Chir.* 22: 46. (Original not available for examination, cited in Davis, J. S. and Davis, W. B., eds. *Lewis' Practice of Surgery* 5, Chap. 8: 188. Hagerstown, Maryland, W. F. Prior Co., Inc.). 1949.
- Lawson, G. (1870). On the transplantation of portion of skin for the closure of large granulating surfaces. *Clinical Soc. of London.* Nov. 11, 1870. (Original not available for examination, cited by Maltz, Maxwell. *Evolution of plastic surgery.* p. 253. New York. Froben Press.) 1946.
- Maltz, M. (1946). *Evolution of plastic surgery.* New York, Froben Press.
- Markowitz, J. (1954). *Experimental surgery.* 3rd ed. Baltimore, The Williams and Wilkins Co.
- May, H. (1947). *Reconstructive and reparative surgery.* Philadelphia, F. A. Davis and Co.
- Maximow, A. A. and W. Bloom. (1948). *A textbook of histology,* 5th ed. Philadelphia, W. B. Saunders and Co.
- McCarroll, H. R. (1931). The regeneration of sensation in transplanted skin. *Ann. Surg.* 108: 309-320.
- Neuhof, H. (1923). *The transplantation of tissues.* New York, D. Appleton and Co.
- Ollier, L. (1872). Greffes cutanées ou autoplastiques. *Bull. de L'Acad. de med. Paris.* 2 me Serie - Tome 1: 243-250.

- Reverdin, J. L. (1869). Greffe epidermique. Bull. de la Soc. imperiale de chir. de Paris, Dec. 8 and 15. p. 493, 511. (Original not available for examination, cited in Jour. Am. Med. Assoc. 63: 985.) 1914.
- _____. (1872). De la greffe epidermique. Arch. gen. de med. p. 276, 55, 703. (Original not available for examination, cited in Jour. Am. Med. Assoc. 63: 985.) 1914.
- Riser, W. H. (1957). Traumatic injuries. In Mayer, K., Lacroix, J. V., Hoskins, H. P., eds. Canine surgery. 4th ed. p. 221. Evanston, Ill. American Veterinary Publications, Inc.
- Self, R. A. (1934). Skin grafting in canine practice. Jour. A. V. M. A. 37: 163-167.
- Smith, F. (1926). A rational management of skin grafts. Surg. Gynec. and Obst. 42: 556-562.
- Thiersch, K. (1874).
"

Uber die feineren anatomischen Ver-
anderungen bei Aufheilung von Haut auf Granulationen.
Arch. f. Klin Chir. 17: 318. (Original not available
for examination, cited by Neuhof, Harold. The trans-
plantation of tissues. p. 62, New York, D. Appleton and
Co.). 1923.
- _____. (1886). Epidermistransplantation. Chir. Kong.
Verhandl. 17. (Original not available for examination,
cited by Neuhof, Harold. The transplantation of tissues.
p. 62, New York, D. Appleton and Co.). 1923.
- Wolfe, J. R. (1876). A new method of performing plastic
operation. Med. Times and Hosp. Gaz. 1: 608. (Original
not available for examination, cited in Davis, J. S. and
Davis, W. B., eds. Lewis' Practice of Surgery, 5, Chap.
8: 188, Hagerstown, Maryland, W. F. Prior Co., Inc.).
1949.

VIII. ACKNOWLEDGMENTS

To Dr. E. W. Kingrey, whose interest, encouragement and constructive guidance was an invaluable aid throughout the entire course of this study.

To Dr. F. K. Ramsey for his excellent cooperation and helpful assistance during the histopathological studies of this work which were so sincerely appreciated.

To Dr. G. R. Fowler for his excellent photography as well as his advice and suggestions during the early phases of this project.

Also, to Mr. John Tobola for the fine photography which he contributed to this project.

To Mr. L. A. Facto for his excellent photographic reproductions and photomicrographs.

To Dr. M. W. Sloss for her technical advice and suggestions which were so helpful during the preparation of this thesis.

To Dr. M. Johnson for the cooperation in the clinical phase of this investigation and the use of clinical equipment.

To Drs. R. Getty and J. Lovell for their advice and assistance which was so greatly appreciated.

To Drs. C. H. Covault, D. L. Baker and P. T. Pearson and to many other of my colleagues whose continuous encouragement was stimulating.