# THE HEMODYNAMICS OF THE ISOLATED PREGNANT UTERUS OF THE COW (BOS TAURUS)

by

Lea Roy Hutchinson

A Thesis Submitted to the
Graduate Faculty in Partial Fulfillment of
The Requirements for the Degree of
MASTER OF SCIENCE

Major Subject: Veterinary Obstetrics

Approved:

Iowa State University
Of Science and Technology
Ames, Iowa

1962

TABLE OF CONTENTS

# INTRODUCTION

The primary objective of this study was to determine the role of the arterial blood supply in maintaining the corpus luteum (CL) of pregnancy in the cow. It has been shown by Reuber (1954) that the circulatory changes to the CL of estrum are definitely synchronized to the various stages of the estrous cycle, thereby indicating a definite role for the hemodynamics of the ovary.

It is generally known that inadequate production of progesterone by the CL of pregnancy or the sudden loss of progesterone through removal of the CL (manual expression or surgical ablation) during approximately the first 200 days of pregnancy in the cow usually results in abortion (McDonald _et_ _al_. 1953). According to Reynolds (1949b), the pregnant uterus is under the influence of two motility-inhibiting substances, one from the CL and the other from the placenta. It is here hypothesized that the change-over from the motility-inhibiting activity of progesterone from the CL to a progesterone-like substance from the placenta is gradual, and therefore variable. This change-over could even be variable in the same animal at different gestation periods. Therefore, the length of time the CL of pregnancy is essential will be variable. Since the CL is necessary for the maintenance of pregnancy for approximately seven tenths of the gestation period in the cow, this species was considered ideal for the study of circulatory changes to the CL of pregnancy.

Another objective of this study was to graphically portray the circulatory changes to the uterus at different stages of pregnancy by radiographically recording the actual arterial distribution. The use of a contrast medium injected into the arterial system of timed, isolated pregnant bovine uteri permitted the true recording of the course of the arterial system in the broad ligaments and in the wall of the uterus or the substance of the ovary. It is realized that variations in the pressures used to inject the radiopaque mass into the arterial system were not constant. Therefore the actual capacity and size of the blood vessels may not be accurately portrayed. Nevertheless, relative differences in the capacity and size of the arterial vessels can be noted.

A third objective was to portray the circulatory changes that occur in those specialized areas of the endometrium, the caruncles, that form the maternal placenta.

Hemodynamics is defined by Dorland (1951) as, the study of the movements of the blood and of the forces concerned therein. In a broader sense, hemodynamics could mean the variations in blood volume to an organ, variations in the blood pressure and degree of congestion, variations in the rate of metabolism of the cells supplied, and even variations in the concentration of the hormone content of a system of organs in which the blood volume and pressure have been increased. Thus, this study was made to gain better understanding of the phenomena associated with pregnancy by investigating the variations in the uterine and ovarian arterial circulation throughout the gestation period of the cow.

# REVIEW OF THE LITERATURE

## Arteriography

Reviews of the literature on arteriographic techniques can be found in the publications of Greene (1951) and Reuber (1954). These two investigators used variations of a technique developed by Lum (1946). Lum formulated his injection mass because of difficulties encountered in working with latex. He found that the radiopaque substance, lead trioxide, which he used was more evenly distributed in the gelatin base than in the latex. Secondly, the new injection mass was easier to handle than latex and did not gum up his injection apparatus; it was more economical and, therefore, could be used on a larger scale. He was able to inject the gelatin base contrast medium with a glass syringe, whereas, the latex contrast medium required special instruments. Further he found the gelatin base contrast medium gave excellent reproductions of the vasculature without excessive distortion. His injection mass set into a firm flexible mold so that the specimens could be handled easily for radiography without fear of breaking the mold thereby causing gaps in the reproductions. Greene (1951) used the same gelatin base but substituted sodium uranate as the radiopaque material. The best criterion he found as evidence of the completeness of the injection was the change in color of the tissues due to the filling of the arterioles with the yellow mass. Reuber (1954) substituted bismuth subnitrate in the gelatin base as his radiopaque substance. He found that neither an increase in digital pressure on the injection syringe nor the observation of a change in color of the tissues was satisfactory criteria for a complete injection. He, therefore, relied more on his experience and judgement as to the amount of contrast medium needed for a complete injection.

## Arterial Blood Supply to the Bovine Female Genitalia

According to Sisson and Grossman (1953), and McLeod (1956) the main blood supply to the internal genitalia of the cow is through the utero-ovarian arteries (Aa spermaticae internae), the middle uterine artery (A. uterina media), and the posterior uterine artery (A. uterina caudalis).

The utero-ovarian artery arises from the posterior aorta, descends to the genital organs through the anterior border of the broad ligaments and divides into two main branches; the ovarian branch of the utero-ovarian (A. ovarica) supplying the ovaries and the uterine branch of the utero-ovarian (A. uterina cranialis) supplying the anterior part of the uterus.

The middle uterine artery arises from the internal iliac artery, courses through the broad ligament to the uterine cornua where its many branches supply the bulk of the uterus through the mesometrial border.

The posterior uterine artery arises from the internal pudic artery (A. urethro-genitalis), supplies the posterior part of the uterus, and gives branches to the bladder, vagina, and cervix.

Hatch (1940), Hansel (1949), Greene (1951), and Reuber (1954) gave detailed descriptions of the vascular pattern within the uterus. The middle uterine arteries provide the principal blood supply to the uterus of the cow. They soon divide into two main branches, anterior and posterior, as it approaches the mesometrial border. The two main branches of the middle uterine artery subdivide and resubdivide into numerous smaller branches thereby providing a rather profuse blood supply to the uterus proper. A branch of the utero-ovarian artery anastomoses with an anterior branch of the middle uterine artery, while the posterior uterine artery sends an anastomotic branch to a posterior branch of the middle uterine artery. There are numerous anastomotic branches with corresponding vessels from the opposite middle uterine artery.

As these arteries enter the myometrium, they send branches dorsally and ventrally around the wall of the uterus, meeting and intertwining, and sometimes anastomosing across the greater curvature of the cornua. These branches are coiled or arcuate (helical) in the non-gravid uterus and have a tendency to straighten out as pregnancy advances. These circumferential or arcuate arteries form a myometrial plexus between the outer longitudinal and inner circular muscle coats; occasionally, in the outer part of the circular muscle layer. Many animals show a vascular plexus under the serous coat in addition to the myometrial plexus. The vast network of vessels, particularly, the myometrial plexus, is sometimes called the "stratum vasculare". The dorsal and ventral arcuate arteries anastomose on the anti-mesometrial border. However, these anastomosing vessels never arise from the same primary artery.

The arcuate or helical vessels show coils of increasing complexity and decreasing diameter. The longitudinal muscle layer is supplied by coiled "T" shaped branches of the arcuate vessels. Branches from the arcuate vessels pass centrally through the circular muscle coat sending straight arterioles and capillaries to the musculature; at the same time supplying numerous and helical vessels to the endometrium. These coiled vessels branch into coiled arterioles which, in turn, distribute coiled capillaries to the endometrium. This network of vessels forms a rich vascular plexus in the uterus of the mature cow.

There are progressive uterine vascular changes as pregnancy advances. Hansel (1949) states that in early pregnancy the vessels of the gravid horn increase in size. The arcuate arteries become larger, their coils are spaced further apart, and the endometrial vessels become more widely spaced.

Hatch (1940) found marked vascular congestion with only slight vascular distention in early pregnancy. The caruncles show the greatest quantitative changes of any uterine structure, and their long axis parallels the long axis of the uterine horn. Intercaruncularly, the vascular channels increased in size and remained capillaries with large lumens. There was a marked increase in the size of the vessels passing into the caruncles. Capillaries to the intercaruncular glands increased in prominence as pregnancy progressed. During gestation there was little change in the size of the lumen or the number of vessels per unit area in the intercaruncular spaces.

Foley and Reece (1953) found an increased vascularization of the caruncles during the first month of pregnancy similar to, but more extensive than, those of the estrous and postestrous periods of the cycle. Numerous capillaries were noted in the upper and middle zones of the caruncles. Parkes (1952) described the caruncles as moderately well vascularized with small vessels running in directions at right angles to the surface. There was edema and increased vascularity of the caruncular and intercaruncular areas during preimplantation. As the caruncles enlarged, there was an increased infiltration of blood vessels between the more superficial cells and the sub-epithelial layer. The cells lining the caruncular crypts showed hypertrophy and became very spongy because of the increased vascularity. The maternal vessels permeated all the trabeculae of the caruncle, with arteries feeding intercrypt columns by branches. These passed directly to the tips of the maternal trabeculae where they formed capillary networks. Hatch (1940) described the advanced caruncle vasculature as radiating capillaries from the narrow caruncular stalk.

Harvey (1959) states that the average cow has from 70 to 120 caruncles in a series of four rows in the body; three rows in the middle of the uterine horn; and two rows in the apex of the horn. The caruncles dorsal to the fetus are usually the largest. Roberts (1956) says that 75 to 120 caruncles per cow are normal, and they are a convex enlargement on a narrow stalk. He states there is a progressive increase in the diameter of the middle uterine artery supplying the gravid horn as pregnancy advances.

Salisbury and VanDemark (1961) state the uterus is prepared for pregnancy by an increased vascularity, growth and coiling of the uterine glands, and leucocytic infiltration around these glands. These glands are supplied by extensive networks of blood vessels.

The caruncles at first are smooth plates which become undulated surfaces at about 30 days when attachment of the fetal membranes begins. Hammond (1927) says that the caruncular areas become highly congested 48 to 72 hours after heat commences. The caruncles have no gland openings and develop extensive vascularity. The increased vascularity results in congestion and edema by 48 hours postestrus.

Reynolds (1949b) considers that, fundamentally, all mammals have the same vascular system to the uterus. He found no evidence of coiled or spiral arteries in the endometrium of mammals except menstruating primates. The areas of implantation are usually the most vascular with no gross evidence of change in the uterine vasculature prior to implantation. Microscopically an endometrial hyperemia can be observed. The rabbit is multiparous and, therefore, there are interconceptus spaces. The vessels in these interconceptus spaces are similar to the non-gravid horn until the spheroid conceptus reaches its maximum size. Thus, initially, only the uterine vessels that surround the conceptus, hypertrophy. The parallel circumferential arteries progress from tortuous to straight, becoming distorted as they are crowded into the interconceptus sites as the spheroid conceptus enlarges. When the conceptus converts from a spheroid to a cylindrical shape, the arteries again become more evenly distributed. At this time all the arteries become involved in the hypertrophy. The blood is always shunted to the areas of major placental attachment. In the rabbit, when the tension increases, the blood vessels in the ventral and lateral walls become compressed and the blood is shunted to the mesometrial vascular bed.

Reynolds (1937a) determined that the rate of blood flow in the pregnant rabbit uterus increased until the 22nd day of gestation; then decreased by one third by the 25th day; increased again by the 27th day; and decreased once more by one half in the next two days. Reynolds (1939) determined that the intrauterine pressure had two maximum peaks. The first peak was about the 22nd day of pregnancy and the second was near term. Conversion, the change from a spheroid to a cylinder shape, occurred sometime between the 20th and the 24th day of gestation. Reynolds (1949a) and (1955) states that the change in the rate of maternal uterine blood flow is closely correlated to intrauterine tension and conversion.

Barcroft and Barron (1946) described the uterine vasculature in the pregnant sheep. The first 90 days of gestation is the period of spheroid growth. During this time the fetal vascular system is undergoing extensive development. Conversion occurs around the 90th day of pregnancy and thus, initiates the second period of uterine growth. During this second stage the maternal uterine vascular system grows rapidly in an effort to match the development of the already extensive fetal system. There is expansion and growth of the maternal capillaries deeper into the caruncle to match the size of the fetal capillary bed near term. The caruncles reach their maximum growth between 80 and 100 days, and are increasingly vascularized to term. Reynolds (1949b) in studying the pregnant sheep, states the first or growth stage occurs during the first 90 days. Conversion occurs at 90 days and the second, or stretching stage, begins. This stage is the period of rapid elongation. There is marked vascularization and anastomosis of caruncular capillaries during the second stage. Metcalfe _et_ _al_. (1959) state that the uterine blood flow in the sheep increases slowly during the first 80 days of pregnancy and then rapidly until parturition. This coincides with the period of rapid elongation.

Microscopic descriptions of the human uterine vasculature can be found in Maximow and Bloom (1952), Ham (1953), and Smith and Copenhaver (1953). Schlegel (1945:46) and Ramsey (1959) give a good review of human uterine vasculature. Two types of arteries originate from the stratum vasculare. Radiate arteries are given off, travel toward the uterine lumen, and give rise to coiled endometrial arteries. The straight basal arteries remain in the basal one-third of the endometrium. The coiled arteries are involved in the menstrual bleeding. Venous lakes observed in the endometrium are directly connected to arterioles and venules. These apparently act as arterio-venous shunts.

McNutt (1924), Hammond (1927), Trautmann and Fiebiger (1952), Reuber (1954) and Nalbandov (1958) discuss the development of the CL in the cavity of the ovulated follicle. The vascular supply is contained in the infolding theca interna and theca externa which provide vascular sprouts to the developing lutein stroma. Maximum vascularity is reached between eight and ten days after the onset of estrus.

Greene (1951) and Reuber (1954) describe the general ovarian vasculature. The utero-ovarian artery divides into an ovarian branch and a uterine branch. The former is the main blood supply to the ovary while the latter supplies the anterior portion of the uterine cornua and anastomoses with an anterior branch of the middle uterine artery. The utero-ovarian and ovarian arteries are very tortuous, and frequently the ovarian artery is spiralled. The ovarian artery divides into several branches before entering the hilum of the ovary. These have an increased lumen volume over the primary artery and are more spiralled. As these branches enter the ovary they give off several tertiary branches with numerous spirals.

The mature follicle is usually supplied by two small and one large artery with typical spirals. There is a rich arteriole supply to the follicular wall especially in the theca interna. The mature CL is very vascular and the luteal tissue is permeated by fine non-spiralled vessels.

Greene (1951) states that in the regulation of blood pressure in the cow's ovary there is a considerable decrease before it even enters the ovary. This is due to the increased lumen volume of the arterial branches over the primary arteries and the coiled nature of the vessels. Therefore, it appears any additional decrease of blood pressure within the cow's ovary is negligible.

Dukes (1955) considers that the CL remains fully developed throughout pregnancy, except in the horse, and undergoes rapid involution after parturition. Roberts (1956) agrees with Dukes and states that the removal of the CL of pregnancy prior to the 200th day of pregnancy in the cow, leads to abortion and, if removed after the 200th day, may produce abortion. Therefore, the CL is essential to the maintenance of pregnancy during at least seven tenths of the gestation period in the cow. Benesch and Wright (1951) say that the CL remains enlarged throughout pregnancy in the cow.

Foley and Reece (1953) in their discussion on the cow, describe considerable variation in the size of luteal cells between the 25th and 33rd days of pregnancy, with all tissues showing abundant capillaries and some larger blood vessels. There was connective tissue along the paths of the blood vessels. During the second month of pregnancy, the lutein cells increase in size and there is increased vascularity of the entire CL. At 78 days, the cells are large, round, and plump with better vascularization than the younger corpora lutea. There are abundant capillaries and many large blood vessels appearing regularly in sections of well developed trabeculae.

Delson et al. (1949) describe the vascular supply to the human ovary. Maximow and Bloom (1952), Ham (1953), and Smith and Copenhaver (1953) discuss the blood supply to the human CL. Generally, the architecture is similar to the cow, and Delson (1949) describes the CL vasculature as a closely woven basket.

Anderson (1926) and Parkes (1956) studied the vasculature of the sow's ovary. The CL in the sow develops similarly to the cow's. The central core of infolding tongues of thecal tissue contain arterioles. They, in turn, run centrally with capillaries radiating out from them. The capillaries grow and when they touch capillaries from another arteriole they anastomose freely, giving a dense network of vessels. The lymphatic system in the sow ovary is very extensive and occupies almost as much space as the blood vascular system. Its development lags behind that of the blood vascular system but when the CL regresses the lymphatics disappear first, the capillaries second, and the arterioles contract, but are slow to regress completely.

Reynolds (1950) and (1952) has studied extensively the blood supply to the rabbit ovary and compared it to the human ovary. In the rabbit, each portion of the ovary is supplied by short arterial branches from a common spiralled artery. In the human, a large artery enters the hilum and gives off 12 or more branches to the ovarian tissue. Each of these are slightly tortuous and divide into numerous spiralled vessels. These spiralled vessels are in clusters and present a more complex arrangement than in the rabbit. The ovary is unique in that it has two endocrine glands; the follicle and CL which vary in size according to the reproductive cycle. Therefore, the ovary must have a blood supply capable of ready adjustment to cyclic changes in size; the vasculature must distribute ovarian stimulating hormones equally throughout the ovarian cortex; and part of the ovarian vasculature serve the function of regulating the blood pressure within the ovary. Endocrine function may be dependent upon development and maintenance of an adequate blood supply to different sizes of ovarian structures; follicular and CL growth and regression. It could serve to force a large fall in arterial pressure between the ovarian artery and the substance of the ovary in a distance of a few millimeters, and provide for an equalization of the blood flow throughout the different parts of the ovary. The spiral arteries seem to obey the laws of flow mechanics in that a decrease in blood pressure could be caused by progressively decreasing the size of the vessels, giving rise to increased peripheral resistance; coiling increases the length traveled for a given distance which increases peripheral resistance. A curved tube has an increased friction over a straight one and an elastic tube carrying a pulsating stream gives a greater decrease in pressure than an inelastic tube. The critical threshold for the onset of turbulence is raised as the diameter of the coil becomes smaller; thus, coiling increases the threshold for the onset of turbulence while maintaining a streamline flow (Reynolds 1948).

Reynolds (1950) and (1952) shows that to keep up a circulation sufficient for a part and no more, nature has not only varied the angle of branching of blood vessels to suit her purpose, but also has regulated the dimension of every branch and capillary. Equalization of the blood flow depends upon the diameter of the branch relative to the stem from which it arises, and its angle of divergence from the stream of axial flow in the stem. Studies of ovarian arteries have shown them to be very close to the optimum for the most efficient equalization of flow. The blood pressure of the ovarian artery is 30 to 50 percent that of the carotid artery, but, a few centimeters away in the minute ovarian vessels, it is about equal to the effective pressure of the plasma proteins. Therefore, the ovarian spiral arteries are peculiarly adapted to changes in size of the organ; the equalization of flow throughout the organ; and to the efficient decrease in blood pressure within the organ itself while maintaining an adequate flow throughout.

## Uterine Accommodation During Pregnancy

Reynolds (1955) lists three phases of uterine accommodation:

1. Uterine preparation, in which there is a progesterone-stimulated mitotic proliferation of all cellular elements with no noticeable increase in uterine weight in preparation for implantation.

2. Uterine growth, in which hypertrophy begins immediately after implantation with the uterine tissue showing a progressive increase in tissue size and weight.

3. Uterine stretching, which occurs when the uterine growth rate decreases even though the uterine contents are growing at a rapidly increasing rate and cause stretching and thinning of the uterine tissue.

All three of these periods are observed in all species but their duration varies between the species. Only the pregnant horn undergoes growth at first, due to the interplay of hormones and the products of conception. Reynolds (1952) states that the non-pregnant horn does not grow until the pregnant side has almost reached its maximum limit of enlargement. There is efficiency in that the uterus produces abundant tissue to accommodate the fetus after conversion when the stretch occurs. The time of conversion is between 100 and 150 days for the monkey, and between the 19th and 21st weeks in man. In the human female, however, the further enlargement includes both an increase in width and elongation, whereas, in rodents and monkeys, only elongation occurs. Reynolds (1946) explains the reason for uterine conversion as the decrease in tension of a cylinder over a sphere of the same diameter which gives less resistance to elongation than to an increase in diameter. The resistance to increasing the diameter of a sphere is two times that of its converting into a cylinder when a certain tension is reached.

Reynolds (1949b) considers the hyperplasia as including myoblasts and metaplasia of histocytes, fibroblasts, and lymphocytes forming new myometrial cells in preparation for hypertrophy. The longer the period of CL activity, the longer the period of uterine growth, all of which depends on the species, breed, and individual.

Salisbury and VanDemark (1961) state that the bovine reproductive tract increases in weight six fold during pregnancy. The fetus, fluids, and fetal membranes make up more than 85 percent of the total weight at term, which is about 150 pounds. More than half of the fetal weight increase occurs in the last two months of pregnancy. The fetus accounts for 60 percent of this total weight at term. Membranes account for no more than ten percent of the total weight. The amniotic fluid reaches a maximum of 50 percent of the total weight around five months, and then decreases to less than 25 percent of the total weight at term.

Hammond (1927) attributes the uterine accommodation to the persistence of the CL causing increased nutrition to the uterus, irritation of the fetal membranes, and pressure of the fetus and fluids. The myometrium hypertrophies greatly during the first five to six months of pregnancy. Hyperplasia occurs early and the uterine connective tissue allows the muscles to expand. The longitudinal layer increases in two bands: one on the greater and one on the lesser curvature of the uterine horn. On the lateral surfaces the longitudinal layer thins leaving only the circular layer intact. The stratum vasculare increases in size and is rich in connective tissue. The intercaruncular areas in the second and third months develop folds which increase as pregnancy advances. The uterine glands in these areas secrete uterine milk and they become very large in size as the uterine tissues grow. As the uterine size increases, the tissues begin to stretch and the wall thins. Hatch (1940) states that the previous hyperplasia and hypertrophy of the muscle tissue are not enough to prevent thinning in later gestation. Thinning becomes visible at the 12th week of pregnancies in the cow.

Robinson (1957) records that in the cow, the uterine percentage of the total weight of the uterus and contents decreases as pregnancy advances; the placental percentage of this total weight is essentially constant throughout gestation; the fluids percentage of this total weight increases to three months of gestation, then decreases to term; and the fetal percentage of this total weight shows a slow increase until the fifth or sixth month then a rapid increase, especially in the last three months of gestation. In all instances, the actual weight of each component increases as pregnancy advances. He also states that near term there is increased uterine motility. Parturition is probably due to the increased motility that is associated with increased uterine dissention, concentration of substances from the fetus in the blood, and degeneration of the placenta. Reynolds (1949b) states that it has been shown that in dogs complete denervation of the uterus does not terminate pregnancy nor interfere with normal parturition.

Involved in uterine accommodation is the interaction of the products of conception, hormones, and the uterine contractile system. Reynolds (1952), Corner and Csapo (1953), Csapo (1956), and Csapo (1959) give extensive discussions of the uterine contractile system. In general, there are two muscle proteins: actin (A) and myosin (M) which combine to give actomyosin (AM) that has contractile properties. Required for efficient contraction is an optimum cell membrane gradient of potassium, sodium, and calcium plus energy rich phosphate from adenosine triphosphate (ATP) and creatinine phosphate (CP). Uterine AM has a longer latent period, contracts more slowly, and to a lesser degree, than striated muscle AM. As pregnancy advances, the efficiency of the contractile system increases with an increase of available ATP and AM. Uterine distention also helps increase the force and efficiency of the rhythm of the uterine contractions.

Estrogen determines the levels of AM and ATP with an increase in these components as estrogens increase. It is believed that progesterone keeps the myometrial system in a state of inactivity by altering the ionic gradients across the excitable cell membranes, thus preventing wave impulses and allowing only local contraction. Progesterone has no effect on the final contractile system so the potential for contraction is always present. The increase of estrogens in late pregnancy eventually dominates the uterine muscle thus restoring a favorable ionic gradient that allows stimulation in all directions to produce rhythmic contractions. Progesterone reduces potassium and increases sodium levels which is the wrong ionic environment for uterine stimulation. There is a slight decrease in AM during the first trimester, a sharp increase in the second trimester, and a high plateau during the last trimester of pregnancy with a sharp drop in AM after parturition. Estrogens increase the production of ATP and CP, as well as the glycogen content of the muscle fibers, thus providing energy for contraction.

## Pregnancy Hormones

Turner (1960) and Guyton (1961) present broad general discussions of the interrelationships of all the involved hormone systems during pregnancy. It is not within the scope of this paper to deal with the entire field of hormones involved in the pregnancy process and, therefore, will mainly be confined to a discussion of estrogen, progesterone, and oxytocin.

Dukes (1955) records that the cow has the lowest sex hormone output requirement of all domestic animals. She has the lowest content of follicle stimulating hormone, shortest heat period, takes the least amount of estrogen to induce heat, and has the least amount of estrogens in the urine.

It is generally conceded that progesterone is required for implantation and maintenance of the embryo (Roberts 1956, Robinson 1957, Nalbandov 1958, and Salisbury and VanDemark 1961). In the cow, it has been difficult to determine conclusively the importance of certain progesterone production sites in the maintenance of pregnancy. In general, Emmens (1959) lists the sites of progesterone production as the CL, placenta, adrenal gland, and possibly the follicle. However, Catchpole (1959) states that the cow placenta does not secrete progesterone. Salisbury and VanDemark (1961) say that there is no work which clarifies whether the cow placenta secretes progesterone or any like substance. Melampy et al. (1959) isolated progesterone from the placenta and McDonald et al. (1953) assumed the placenta secreted progesterone in late pregnancy. Robinson (1957) maintains that isolation of a hormone from a tissue is not conclusive of active secretion and he questions whether progesterone is necessary in advanced pregnancy of any domestic farm species. Gorski et al. (1958) were unable to show a rich source of placental progesterone in late pregnancy and concluded that either the placenta does not produce progesterone or it produces a progestin not yet identified.

Various investigators have studied the pregnancy CL in trying to determine the length of time it remains functional. McDonald et al. (1952) and (1953) removed the CL of pregnancy in the cow at various intervals during the gestation period. Abortion resulted when the CL was removed prior to 191 days of gestation. Removal of the CL between 207 and 236 days gave variable results with abortion occurring up to the 236th day. They assumed that the placenta took over progesterone production and during the period of transition, neither the CL nor the placenta was capable of maintaining pregnancy by itself. Eight out of nine cows carried to term when the CL was removed at 60 days gestation and its loss compensated for by the parenteral administration of progesterone until the 162nd day. They, however, had shorter than normal gestation periods. McNutt (1927) showed that the CL was retained until parturition but could undergo marked retrogression and decrease in size in late pregnancy. The lutein cells at five and one-half months showed retrogression which continued to term. The CL regressed rapidly within 48 hours after parturition. There appeared to be no difference in the CL size from non-pregnancy to pregnancy. Uren and Raeside (1951) removed the CL of pregnancy between 177 and 191 days which resulted in abortion. However, when it was removed after 205 days the cow went to term. Price (1956) observed no cellular degeneration in the CL during the first five months of pregnancy and no gross involution was apparent throughout the cow's gestation. He measured the cholesterol content of the luteal tissue and determined that a low cholesterol content was indicative of active progesterone secretion. Cholesterol is considered a precursor of progesterone. Up to 225 days gestation the luteal tissue cholesterol content was low, and corresponded closely to the estrous cycle levels observed between three and 17 days postestrus, when the gland was most active. Therefore, he concluded that a cow with a live calf had a functioning CL. Velle (1962)[1] states that progesterone has been isolated from the CL up to 250 days of gestation in the cow. Gorski _et_ _al_. (1958) record that progesterone was isolated from the CL and ovary at 280 days of pregnancy. The amount remained high but may be less than that of non-pregnancy corpora lutea.

Progesterone is an intermediary product in the synthesis of adrenal corticoids. Progesterone was found to be present in 10 to 100 times the concentration in the venous blood from the adrenal, when compared to that of the arterial blood for that gland. There is no evidence of adrenal hypertrophy during pregnancy (Catachpole 1959). Melampy _et_ _al_. (1959) isolated progesterone from bovine adrenals as did Balfour _et_ _al_. (1957) and Gorski _et_ _al_. (1958). Velle (1962)[1] states that adrenal production of progesterone and estrogen is essentially constant. Melampy _et_ _al_. (1959) showed an increase in progesterone concentration in the cow's CL, placenta, fetal fluids, and adrenal, reaching its maximum around the 200th day of gestation and then, decreasing until term. Peripheral blood showed a fairly low and fluctuating progesterone concentration up to 130 days, then increased and remained at a fairly constant level until parturition. Short (1960), however, reports a decline in blood progesterone about ten days before parturition.

Nalbandov (1958) reports that cows have large amounts of fecal androgens during pregnancy which might be conversion products of placental progesterone.

---

[1] Velle, Weiert. 1962. Oslo, Norway. Veterinary College of Norway. Estrogenic hormones in domestic animals from the biochemical standpoint. Private communication. June 25.

Estrogens are secreted by the placenta, adrenals, and luteal cells (Nalbandov 1958, Emmens 1959, and Catchpole 1959). Turner (1960), and Gorski and Erb (1959) state that the placental source of estrogen is very significant. Follicles are commonly observed on the ovaries during the first half of pregnancy but none of them mature and ovulate. McNutt (1927) and Velle (1962)[1] say that no estrogen can be isolated from these pregnancy follicles in the cow.

To date no placental gonadotropins have been positively identified in the cow (Cowie 1948 and Velle 1962[1]). Oxytocin is released via the posterior pituitary (Turner 1960 and Robinson 1957) and its secretion is considered to be by nerve cells in the hypothalamus. No discussion will be made of relaxin because of the lack of adequate data in the cow.

Salisbury and VanDemark (1961) consider that the maintenance and termination of pregnancy are due to hormone balances. Estrogens are low in concentration in early pregnancy and increase gradually during the last four months with especially large quantities in the last weeks. Progesterone concentrations are higher during early pregnancy and are maintained until late pregnancy. Robinson (1957) discusses the rise of estrogen concentrations in late pregnancy and the sudden drop after parturition. He does not subscribe to any increase in oxytocin production in late pregnancy. Generally progesterone dominates pregnancy and inhibits uterine motility. As pregnancy advances, estrogens increase and near term progesterone decreases, thus increasing uterine motility and its sensitivity to oxytocin.

---

[1] See Private Communication page 21.

This provides the necessary environment for rhythmic uterine contractions for parturition. Fitzpatrick (1957) states that uterine sensitivity to oxytocin is remarkable. It is increased under the influence of estrogen but depressed under the influence of progesterone. The uterine response to oxytocin increases slowly throughout most of the second half of pregnancy, then increases rapidly just prior to parturition. Turner (1960) cites the increase in estrogen and oxytocin towards the end of gestation as responsible for the increased rhythmic contractibility of the uterus. Nalbandov (1958) says that estrogen is increased, progesterone decreased, and oxytocin increased as parturition approaches. Asdell (1955) says that the uterus, under the influence of estrogen, shows rhythmic spontaneous contractions, but under the influence of progesterone, it is quiescent. Oxytocin causes strong uterine contractions when the uterus is sensitized by estrogen. Nalbandov (1958) states that pregnancy can be maintained with smaller doses of progesterone if it is in combination with estrogen. Short (1960) maintains that, to date, no one has been able to prolong the gestation period in cattle by progesterone injection even though it has been done in species which need their corpora lutea up to parturition, i.e., mouse, rat, and rabbit.

According to Parkes (1952) the importance of the CL in pregnancy varies with the species. For example, in some instances the human placenta takes over the production of progesterone within the first month of pregnancy. Zander (1961) states that the human placenta synthesizes progesterone by the second month of pregnancy and, the highest peripheral blood concentration of progesterone is observed in late pregnancy. Urinary pregnanediol increases as pregnancy advances. There is a very large progesterone production for such a small quantity isolated at the site of action. This may be due to speed of elimination and the rate of metabolism. Plotz (1961) determined that the fat compartment of the body acted as a vast storehouse for progesterone and its metabolites. The myometrium and decidua in advanced human pregnancy 17 to 18 weeks show only moderate amounts of progesterone whereas, relatively higher concentrations are found in them in 11 week pregnancies. Is this due to an alteration in metaboliam and increase storage of the biologically active progesterone?

Wright (1952) and Guyton (1961) cover the hormones of human pregnancy and generally the actions are similar to those discussed for the cow. In the human, the placenta is known to secrete estrogen, progesterone, and chorionic gonadotropin. The latter is a combination of the properties of luteinizing and luteotropic hormones which helps to maintain the CL in early pregnancy. There is an increase in estrogen production in the last six months of pregnancy with a peak in the last three months. The estrogen concentration is rapidly decreased after expulsion of the placenta. The placenta may produce up to 60 times the amount of estrogen that is produced during an estrous cycle. The chorionic gonadotropin increases until about the seventh week of pregnancy then decreases to a low level at 16 weeks.

According to Guyton (1961), as the seventh month of pregnancy begins, estrogen is produced more rapidly than progesterone and immediately before parturition large quantities of free estrogen are found in the extracellular fluids. Oxytocin is secreted by the neurohypophysis at the time of parturition in increased amounts. The uterine response to a given dose of oxytocin at the time of parturition is about 70 times the response during the latter months of pregnancy. However, a hypophysectomized person can still deliver at term but labor is prolonged. Certain mechanical factors aid parturition since simple stretching of smooth muscle usually increases its contractibility while intermittent stretching by fetal movements produces contraction. Stretching or irritation of the cervix elicits uterine contractions and increases the rate of oxytocin secretion. At the onset of labor, there is a positive feedback mechanism. Once the strength of the uterine contractions becomes greater than a critical value, each contraction leads to subsequent ones which become stronger and stronger, giving a maximum effect.

In lower animals, Heckel and Allen (1939), and Robson (1947) suggest that estrogen may be responsible for maintaining the CL and its progesterone production by direct stimulation of the ovary. In the rabbit, estrogen secretion decreases prior to parturition after having steadily increased during the preceding days of gestation. Reynolds (1955) states that progesterone decreases and estrogen increases as the rabbit reaches term. Zarrow (1956) says that in sheep pregnancy progesterone secretion increases from ovulation to the 50th day, then plateaus for another 60 to 80 days followed by a second rise until the birth act occurs. There is no decrease in progesterone until several hours postpartum. If the sheep are ovariectomized between the 66th and 114th day of pregnancy, normal progesterone levels and pregnancy are maintained. Zarrow and Lazo-Wasem (1955) showed that even though the adrenal produces progesterone in the rabbit, when the ovary is removed in pregnancy, the progesterone level drops and the adrenal does not appear to increase production to offset the loss.

Hormonal influences on the powerful contractions of the myometrial muscle during the birth act were discussed under the section on uterine accommodation. Csapo (1956), working with rabbits, discussed placental progesterone synthesis at the end of gestation and did not consider it an essential requirement for a complete control mechanism by the placenta. He considers that if estrogen is required for progesterone synthesis, then the placenta could maintain complete control over pregnancy by estrogen production. Through its estrogen production, the placenta could control the progesterone production of the CL. However, placental progesterone production at the end of gestation is very strongly substantiated. Csapo (1959) discusses the mechanism of myometrial block and attributes the key role of stimulating parturition to the placenta. He maintains that the placenta takes over control from the CL in all animals, the time depending upon the species. It is very hard to assay progesterone at the site of function. Why? Is it in an unrecognizable form or does a local action preclude its detection? Progesterone response is very marked at local placental sites. Progesterone may also participate in maintenance of pregnancy by assuring the quiescence of the otherwise extremely sensitive uterine musculature. In 1961, Csapo is still not sure whether progesterone has a local or systemic myometrial action.

Reynolds (1937b) states that posterior pituitary oxytocin is not necessary for uterine motility but, estrogen is required for synergism if oxytocin is to produce motility. Bengtsson (1961) reports that in women, progesterone makes the myometrium insensitive to oxytocin but near term, one is unable to prevent oxytocin effects on the myometrium by massive intravenous doses of progesterone. Why? Does the myometrium become insensitive to progesterone, or does it undergo a change which makes it ineffective, leaving only the local placental sites progesterone-dominated by local action? Hendricks et al. (1961) dispute the fact that the myometrium becomes insensitive to progesterone. They showed that progesterone caused a decrease in spontaneous uterine activity. This resulted in a decrease in the activity of the uterus under oxytocin stimulation.

Schofield (1961) showed in the rabbit that as the CL develops, progesterone dominates the myometrium until near term when its influence is decreased. Twenty four hours before parturition the progesterone block is removed and the uterus becomes estrogen dominated. Oxytocin begins to affect the myometrium in late pregnancy when progesterone concentrations decrease. The CL, which is the main progesterone source, begins to degenerate several days prior to parturition. However, pregnancy can be prolonged in the rabbit by exogenous progesterone. In animals, where the placenta provides a major source of progesterone, general interference with placental function may induce a decrease in progesterone production. In sheep, there is no decrease in blood progesterone prior to parturition. The sheep also shows an estrogen dominated myometrium prior to parturition which may be due to a decrease of progesterone.

# MATERIALS AND METHODS

## General

The twelve dairy cows used in this experiment were slaughtered at predetermined stages of pregnancy. Every effort was made to acquire cows with known breeding histories and the stages of pregnancy listed are as accurate as can be calculated. Rectal palpation was used in each cow in an attempt to verify the gestation length. No other criteria were used in selection of these animals except the length of pregnancy. Six other pregnant cows' uteri were utilized to gain additional experience in the injection technique. Due to the expense in acquiring pregnant cows and the fact that each stage of pregnancy would have to be considered as a new technique, it was decided that experience would have to be gained while actually collecting the experimental data.

The cows were taken to the abattoir at their designated time and the genital tract was removed under supervision so that as much of the broad ligament as possible was left attached to the uterus. The terminal part of the rectum, the bladder, and the vagina were also left attached. The entire uterus and contents were then moistened with one percent sodium citrate solution and transported back to the laboratory in a covered container. Every uterus was injected the same morning the cow was slaughtered. In every instance, the uterus was still warm upon arrival at the laboratory. The uterus was then placed in a warm water bath, around 150 degrees Fahrenheit, or if in the advanced state of pregnancy, warm water was run over the uterus to maintain the temperature.

Blunt hypodermic needles with rings in their hubs were utilized to cannulate the arteries supplying the genitalia. The size of the needle utilized depended upon the size of the artery cannulated. Cannulae were inserted in each middle uterine artery and each posterior uterine artery. The utero-ovarian artery on the pregnant side was cannulated in some of the uteri in advanced pregnancy. The cannulae were ligated in the arteries with nylon suture material which was then anchored to the ring in the needle hub to prevent the needle from slipping out of the vessel during the injection.

Each cannulated artery was flushed with a one percent solution of warm sodium citrate immediately prior to injection of the radiopaque medium. A 30ml. glass syringe with a siphon adapter was utilized to administer the pre-injection rinse. The amount of rinse used for each artery depended upon the size of the uterus being supplied by that artery and the stage of gestation. The cannulae not being flushed were plugged.

The radiopaque medium was mixed prior to injection and the consistency and efficiency were the same whether it was mixed, cooled, and then reheated, for use, or if it was made fresh just prior to injection. In most instances, the medium was made the day before injection and stored under refrigeration overnight. The injection mass was heated in a water bath to approximately 180 degrees Fahrenheit and then injected into the cannulated arteries with a 50ml. glass syringe under digital pressure. No effort was made to maintain a constant injection pressure because each uterus presented a different resistance. The uteri from cows in advanced pregnancy required very little digital pressure at injection. The main concern was to complete the injection in the minimum length of time to avoid blockage of the vessels by gelling of the medium. It was found that the medium would remain liquid as long as the uterus was not allowed to cool appreciably. Continuous agitation of the medium was necessary to keep the radiopaque bismuth subnitrate in suspension.

The injection mass was prepared by slowly adding 90gms. of U.S.P. gelatin to 600ml. of distilled water while stirring with an electric mixer. This mixture was then placed in a water bath at 180 degrees Fahrenheit. When the gelatin was in solution, 30gms. of potassium iodide, 200ml. of glycerol, 2.4ml. of a ten percent formaldehyde solution, and 64gms. of bismuth subnitrate were added while being agitated by the electric mixer. The entire mixture was kept in a uniform suspension by periodic agitation with the mixer or by stirring with a wooden tongue depressor. The final injection mass was a bright orange color.

Upon completion of the injection, the cannulae were removed, the arteries ligated, and the specimen placed under refrigeration until the gelatin base solidified. The injected uteri were spread out, ventral side down, with as few structures overlapping each other as possible. Prior to radiographing, the bladder, rectum, posterior vagina, excess fat, and any areas of leakage of injection medium were dissected away. Transected vessels did not leak the injection mass because it was set. In the stages of early gestation the fetus and fluids were left in for the views of the intact uterus. However, in the advanced stages, it was necessary to remove the fetus and fluids prior to radiography.

On the first uterus injected, the radiographic technique was worked

Table 1. Data on the cows from which genitalia were obtained

| Number | Breed | Approximate age | | Number of previous calves | Gestation length when marketed | Date marketed |
|---|---|---|---|---|---|---|
| | | years | months | | days | |
| 106-1[@] | Holstein | 3 | 7 | 1 | 211 | 4-3-62 |
| 106-2 | Holstein | 2 | 9 | 1 | 22 | 4-10-62 |
| 106-3[@] | Holstein | 4 | 8 | 3 | 78 | 4-17-62 |
| 106-4[@] | Holstein | 4 | 8 | 3 | 36 | 5-1-62 |
| 106-5[@] | Hereford | 1 | 6[*] | 0 | 50 | 5-30-62 |
| 106-6[@] | Hereford | 1 | 6[*] | 0 | 47 | 5-30-62 |
| 106-7[@] | Hereford | 1 | 6[*] | 0 | 50 | 5-30-62 |
| 106-8 | Ayrshire | 3 | 8 | 2 | 30 | 5-31-62 |
| 106-9 | Holstein | 4 | 10 | 3 | 45 | 6-13-62 |
| 106-10 | Holstein | 2 | 6 | 1 | 60 | 6-13-62 |
| 106-11 | Guernsey | 6 | 5 | 4 | 273 | 6-25-62 |
| 106-12 | Brown Swiss | 2 | 9 | 1 | 90 | 7-9-62 |
| 106-13 | Holstein | 8 | 10 | 7 | 241 | 7-9-62 |
| 106-14 | Holstein | 10 | 7 | 5 | 120 | 7-18-62 |
| 106-15 | Holstein | 4[*] | | 2 | 210 | 8-9-62 |
| 106-16 | Holstein | 3[*] | | 1 | 181 | 8-12-62 |
| 106-17 | Guernsey | 3 | | 1 | 279[+] | 8-12-62 |
| 106-18 | Holstein | 5 | 6 | 3 | 150 | 8-14-62 |

[@] These uteri were used only for developing injection and x-ray techniques.

[*] The exact birth dates were not obtained for these cows.

[+] This was the actual gestation period; however, the cow was marketed 12 hours postpartum.

out. It was decided that a constant technique should be utilized to show the varying thicknesses of the tissues as pregnancy advanced. It was determined that a technique using 45.5KVP, 10Ma, 63FFD, and a 15Sec. exposure gave the best results. Kodak Blue Brand X-ray Film, screen type, enclosed in cardboard holders was used. The radiographs were made with a General Electric Mobile Shockproof Model D-3 X-ray Unit.

In the latter stages of pregnancy the corpora lutea did not inject uniformly by the collateral circulation from the uterus. The utero-ovarian arteries were then cannulated and direct injection of the corpora lutea was attempted. It was decided, due to this difficulty, that microscopic sections of the corpora lutea would be advisable. The corpora lutea of pregnancy from 90 days gestation to postpartum were handled in this manner. The corpora lutea prior to this period had been discarded before this decision was made. The tissue sections were fixed in 10 percent formalin, sectioned at 6 to 8 microns, and stained by Gomori's One Step Trichrome Method to show connective tissue. To gain a comparison of the blood supply of pregnancy in the corpora lutea with that of the estrual cycle, corpora lutea sections were made of ovaries at specific periods after estrus. These sections were handled in the same way as the pregnancy corpora lutea except that they were fixed by Zenker's method.

## Individual Uteri

Uteri numbers 106-1, 106-3, 106-4, 106-5, 106-6, and 106-7 were utilized only to develop injection and radiographic techniques. Even though a certain amount of injection was accomplished in these uteri, they were not deemed informative enough to warrant description in this study.

All radiographic views were dorsal ventral except: the lateral views of the individual caruncles, the medial lateral views of the sectioned ovaries, and the ventral dorsal views of the dorsal half of the uterus in the radiographs showing arterial anastomoses across the greater curvature.

Uterus #106-2: The left horn was slightly larger than the right. Each posterior and middle uterine artery received 25ml. of pre-injection rinse. Each posterior uterine artery received 35ml. and each middle uterine artery received 60ml. of the contrast medium. Two radiographs were taken of the intact uterus and ovaries, and two were taken of the uterus with the dorsal half removed and the ovaries sectioned in half longitudinally.

Uterus #106-8: The left horn was larger than the right. Each posterior and middle uterine artery received 40ml. of pre-injection rinse. Each posterior uterine artery received 50ml. and each middle uterine artery received 75ml. of the contrast medium. The radiographic views were the same as for #106-2.

Uterus #106-9: The right uterine horn was enlarged. Each posterior and middle uterine artery received 50ml. of pre-injection rinse. Each posterior uterine received 50ml., the left middle uterine 100ml., and the right middle uterine 120ml. of contrast medium. The same radiographic views were taken as for #106-2.

Uterus #106-10: The left uterine horn was enlarged. Each posterior and middle uterine artery received 50ml. of pre-injection rinse. Each posterior uterine received 50ml. and each middle uterine 150ml. of the contrast medium. Two radiographs were taken of the intact uterus. Two radiographs were taken of the uterus with the dorsal half removed and the ovaries sectioned in half longitudinally. One radiograph was taken of the dorsal half of the uterus.

Uterus #106-12: The left uterine horn was enlarged. At the abattoir, the left broad ligament was severely lacerated. It was necessary to locate any large branches that still supplied the left uterine horn. Each posterior uterine artery received 30ml. of pre-injection rinse. The right middle uterine received 60ml., the left middle uterine branch near the cervix 30ml., the branch near the middle of the left uterine horn 30ml., the branch near the tip of the left horn 20ml., and the left utero-ovarian 20ml. of pre-injection rinse. Each posterior uterine artery received 50ml., the right middle uterine 150ml., the left middle uterine branch near the cervix 150ml., the one near the mid horn 50ml., the one near the tip of the horn 50ml., and the left utero-ovarian 20ml. of the contrast medium. The radiographs taken were the same views as for #106-10.

Uterus #106-14: The right horn was enlarged. Each posterior uterine artery received 50ml., the left middle uterine 100ml., and the right middle uterine 125ml. of the pre-injection rinse. Each posterior uterine received 80ml., the left middle uterine 100ml., and the right middle uterine 325ml. of the contrast medium. One radiographic view was taken of the intact apex of the right horn and ovary and, one of the intact body, both ovaries, and left horn. These same views were repeated with the dorsal half of the uterus, fetus, and membranes removed. One view was taken of the left horn, cervix, and both sectioned ovaries and, one of the dorsal half of the right horn and the sectioned ovaries.

Uterus #106-18: The left uterine horn was enlarged. Each posterior uterine artery received 90ml., the right middle uterine 150ml., and the left middle uterine 200ml. of pre-injection rinse. Each posterior uterine artery received 100ml., the right middle uterine 200ml., and the left middle uterine 450ml. of the contrast medium. The fetus and fluids were removed prior to x-raying by incising the greater curvature of the uterus in the area of the middle of the horn. One radiograph was taken of the intact left broad ligament, ovary, and apex of the horn and, another of the intact uterine body, tip of both horns, and both ovaries. The same views were taken of the ventral part of these areas after the dorsal half of the uterus and the ovaries had been removed. A radiograph was taken of the intact greater curvature of the pregnant horn with the dorsal half reflected to show the anastomosing vessels. A view was taken of the dorsal half of the right horn, the two sectioned ovaries and lateral views of four caruncles. This view was repeated with half of each caruncle removed. This was accomplished by sectioning through the longitudinal axis in ventral dorsal direction.

Uterus #106-16: The right uterine horn was enlarged. Each posterior uterine artery received 90ml., the left middle uterine 100ml., and the right middle uterine 120ml. of the pre-injection rinse. Each posterior uterine artery received 100ml., the left middle uterine 300ml., and the right middle uterine 400ml. of the contrast medium. It was felt that the CL had not injected properly and therefore, 50ml. of contrast medium was injected into the right utero-ovarian artery. The radiographic views for this specimen were similar to those for uterus #106-18 except that they were taken of the opposite horn.

Uterus #106-15: The right uterine horn was enlarged. This uterus presented a variation from the normal blood supply on the right side of the genital tract. There were two enlarged middle uterine arteries on the right side arising in a common trunk with the round ligament of the bladder. The posterior uterine artery on this side was absent. The left posterior uterine received 100ml., the left middle uterine 100ml., the anterior right middle uterine 100ml., and the posterior right middle uterine 120ml. of pre-injection rinse. The left posterior uterine artery received 200ml., the left middle uterine 400ml., the anterior right middle uterine 400ml., and the posterior right middle uterine 400ml. of the contrast medium. It was felt that the injection of the CL was incomplete and therefore, 10ml. of the contrast medium was injected into the right utero-ovarian artery. Radiographic views were taken of the intact body, tips of both horns, and ovaries; the tip of the right horn with the body superimposed; the tip of the right horn with the superimposed body dissected away; the anastomosis of the greater curvature; the apex of the left horn with the dorsal half removed; the apex of the right horn with the dorsal half of the uterus removed and both ovaries not sectioned; four caruncles, ventral part of the cervix, and both sectioned ovaries; and the latter view repeated with half of the caruncles removed. This uterus presented another peculiarity in that the body of the right horn was firmly attached and superimposed on the apex of the right horn.

Uterus #106-13: The right uterine horn was enlarged. Each posterior uterine artery received 100ml., the left middle uterine 150ml., and the right middle uterine 200ml. of pre-injection rinse. Each posterior uterine artery received 100ml., the left middle uterine 300ml., and the right middle uterine 1200ml. of the contrast medium. The CL did not inject properly and therefore, 200ml. of contrast medium was injected into the right utero-ovarian artery. Radiographic views were taken of the tip of the right horn, ovary, and broad ligament; the body of the uterus and both ovaries; of the first two areas with the dorsal half of the uterus removed; the anastomosis of the greater curvature; three caruncles and the dorsal half of the left horn; and the three caruncles sectioned in half and both sectioned ovaries.

Uterus #106-11: The left uterine horn was enlarged. Each posterior uterine artery received 100ml., the right middle uterine 150ml., and the left middle uterine 350ml. of pre-injection rinse. The right posterior uterine artery received 100ml., the left posterior uterine 150ml., the right middle uterine 300ml., and the left middle uterine 900ml. of the contrast medium. The CL did not appear completely injected but no injection medium was put into the left utero-ovarian artery because this was the uterus which precipitated the decision to alter my technique. This also was the first CL that was saved for microscopic sectioning. All subsequent corpora lutea were saved for microscopic sectioning. Radiographic views were taken of the tip of the left horn, ovary, and broad ligament; the body of the uterus and both ovaries; the ventral half of the apex of the left horn; the ventral half of the body and apex of the right horn; the anastomoses across the greater curvature; three caruncles and ventral half of the cervix; and of the caruncles sectioned in half and both sectioned ovaries.

Uterus #106-17: The right uterine horn was enlarged. Each posterior uterine artery received 90 ml. and each middle uterine 100ml. of pre-injection rinse. Each posterior uterine artery received 150ml., the left middle uterine 300ml., and the right middle uterine 350ml. of the contrast medium. The CL did not inject properly and therefore, 50ml. of the contrast medium were injected into the right utero-ovarian artery. Radiographic views were taken of the apex of the right horn, ovary, and broad ligament; the body of the uterus and both ovaries; the ventral half of view number one and two; three caruncles, both sectioned ovaries, and the dorsal half of the cervix and left horn; and the previous view with the caruncles sectioned in half.

Table 2. Corpora lutea that were taken for microscopic sectioning and staining

| Cow number | Time when corpus luteum was harvested<br>Days | Period |
|---|---|---|
| 12* | 5 | Postestrus |
| 3* | 6 | Postestrus |
| 5* | 9 | Postestrus |
| 7* | 12 | Postestrus |
| 4* | 15 | Postestrus |
| 8* | 16 | Postestrus |
| 10* | 21 | Postestrus |
| 11* | 24 | Postestrus |
| 106-12 | 90 | Gestation |
| 106-14 | 120 | Gestation |
| 106-18 | 150 | Gestation |
| 106-16 | 181 | Gestation |
| 106-15 | 210 | Gestation |
| 106-13 | 241 | Gestation |
| 106-11 | 273 | Gestation |
| 106-17 | 12 (hours) | Postpartum |

*These sections of corpora lutea were obtained from heifers in which the estrous cycles had been timed. They were loaned to me by James E. Lovell, D.V.M., M.S., Ph.D., Veterinary Medical Research Institute, College of Veterinary Medicine, Iowa State University, Ames, Iowa. They were used to compare the microscopic picture of corpora lutea of estrum with the corpora lutea of pregnancy. Acknowledgement is hereby made of the source of this material.

# EXPERIMENTAL FINDINGS

## Arteriography

Uterus #106-2; 22 days pregnant; View L-1: The middle uterine arteries show two main branches, one running cranial (anterior) and one caudal (posterior). These two branches continue to divide and the sugsequent branches also divide, giving a fan-like arrangement to the arteries as they enter the mesometrial border of the uterine horns. These branchings show an increase in number and a decrease in diameter as the vessels approach the mesometrial border of the uterus. The arteries are essentially straight as they enter the mesometrial border but the circumferential vessels show a tortuous appearance and the subsequent branches also show dense coilings. The vasculature of the specimen is a very dense network of fine interwoven tortuous vessels. The left horn contained the embryo but no essential difference could be noted in the vasculature between the two horns. The left horn did appear slightly larger than the right. The dense myometrial plexus is observed in the uterine musculature. A definite plexus of fine subserous vessels can be observed in both horns but is more distinct in the pregnant one. The left utero-ovarian artery is very tortuous and, tortuous ovarian branches (homologue of the pampiniform plexus in the male and referred to later as the pampiniform plexus in the female) can be observed entering the hilum of the ovary. The CL appears very vascular with a dense interwoven network of fine vessels involving the entire substance. The vascular appearance of the CL can be described as having a "woven basket" appearance. The right utero-ovarian artery and

Table 3. Experimental data from gross specimens

| 106 No. | Pregnant horn | Right ovary measurement LxWxD (cm) | Left ovary measurement LxWxD (cm) | Corpus luteum diameter (cm) | Follicle location | Caruncle | | Crown Rump (cm) | Fetal Sex | Gestation Length days |
|---|---|---|---|---|---|---|---|---|---|---|
| | | | | | | Size LxW(cm) | No. | | | |
| 2 | left | 2.5,.9,1.5 | 4.4,2.5,3 | 2.5 | - | - | - | embryo | - | 22 |
| 8 | left | 3,1.5,2 | 3.5,2,2.5 | 2 | 1 left<br>5 right | - | - | embryo | - | 30 |
| 9 | right | 4,2,2.5 | 3,1.5,1.7 | 2.5 | 1 left | .5,.5 | - | 2.5 | - | 45 |
| 10 | left | 3,1.5,2 | 4,2.5,3 | 3 | 5 right | 1,1 | - | 5.8 | M | 60 |
| 12 | left | 4,1.9,2.8 | 3.7,2.2,3.1 | 2.3 | 1 right | - | 68 | 15.5 | F | 90 |
| 14* | right | 4.7,1.3,2.7 | 5,2.3,3 | 2.3 | 1 left | - | 98 | 23 | M | 120 |
| 18 | left | 3.5,1,2 | 4.5,2.5,2.5 | 2.5 | 1 right | 9.3,4 | 50 | 37.3 | M | 150 |
| 16 | right | 5.5,2,3.5 | 4,1.5,2.5 | 2.5 | 3 left | 12,5.5 | 82 | 55 | M | 181 |
| 15 | right | 4.5,2,3 | 3.5,1.2,1.5 | 2.5 | - | 9.5,6 | 87 | 69 | F | 210 |
| 13 | right | 4,2.6,3 | 4,1.2,1.5 | 2.5 | - | 14,8 | 94 | 96 | M | 241 |
| 11 | left | 4,1.4,2.4 | 5.5,2.5,3 | 2.5 | - | 15,5<br>12,7 | 31 | 103.5 | M | 273 |
| 17 | right | 6,2.5,2.7 | 5,1,2.5 | 2.3 | - | 8,5 | 77 | - | F | 279+ |

*This cow had a complete median wall of the Muellerian duct from the vestibulo-vaginal junction anterior. There were two cervices one for each horn with no connection between the horns. The vagina was divided into two equal halves by this dorsal ventral septum.

+This was the actual gestation length. The cow was slaughtered 12 hours postpartum.

ovary did not inject and no evidence of ovarian activity could be determined. Breaks in the continuity of vessel outlines can be attributed to shrinking of the contrast medium during the cooling process. View L-4: The sectioned CL shows the fine meshwork of vessels with a greater concentration and size of vessels at its base. The protuberance of the CL shows a weak blood supply and appears somewhat organized in that it is not as prominent as the protuberance of a CL of estrum.

Uterus #106-8; 30 days pregnant; View L-2: The left uterine horn is somewhat larger than the right and the number of vessels is greater than in the non-pregnant horn. The vessels of the gravid horn appear very dense and, compared to the previous uterus, are of greater size and tortuosity. Generally, the description of the vasculature of this specimen is essentially the same as that for the previous one. The left utero-ovarian artery is slightly larger than the one for the right ovary. The CL shows the definite fine meshwork of vessels giving it its characteristic appearance. The dense myometrial plexus is very prominent. The fine subserous layer of vessels can be especially noted in the pregnant horn. View L-4: Definite concentrations of vessels can be noted, especially along the course of the tortuous circumferential arteries. A definite spacing of these vessels is more noticeable in the pregnant horn than in the non-pregnant side. All the vessels which lie within the uterine tissue show numerous branchings which have a tortuous or coiled appearance. The sectioned CL shows the meshwork appearance with the larger and more numerous vessels at the base. The protuberance has organized and the outer surface of the CL is covered by the fibrous capsule of the ovary. The right ovary shows evidence of attempting a follicular phase during pregnancy with an increased general vascularity of straight fine vessels radiating out from the base of the ovary. A definite outline of a graafian follicle can be observed in this ovary.

Uterus #106-9; 45 days pregnant; View R-2: The left horn shows an increased blood supply of very tortuous vessels with an increase in the size of the circumferential arteries. There is increased vascularity in the myometrial plexus of the pregnant horn. The general vasculature of the non-pregnant horn is very similar to that of the previous pregnant horns. The subserous plexus is still evident. The left ovary did not inject. The pregnant right horn shows a slight stretching and straightening out of the vessels. The circumferential vessels appear larger and less tortuous than the previous uterus. View R-3: The area of the amniotic vesicle appears to be somewhat devoid of dense vasculature. Due to the increased distention of the pregnant horn, the vasculature seems less dense in the area of the fetus and apex of the horn. The part of the horn near the body of the uterus is still densely populated with tortuous vessels. The subserous plexus is faintly discernable. The CL of the right ovary shows a good meshwork appearance with the base of the gland containing the densest blood supply. The amniotic vesicle can be generally outlined in the pregnant horn. The vessels appear straightened in the area of the amniotic vesicle with only the finer ones showing extensive coiling. The area of the vesicle appears somewhat devoid of vessels. The body of the uterus still maintains tortuosity and denseness of the vasculature. The sectioned CL shows the meshwork of vessels and the ovarian capsule covers the outer surface of this body. The dorsal half of the right uterine horn shows the circumferential vessels have some tortuosity but again not as dense a network of vessels as observed in the uterine body or the non-gravid horn.

Uterus #106-10; 60 days pregnant; View L-1: There is a definite enlargement of the left horn over the right. The vessels of the pregnant side are noticeably larger and more abundant than on the non-gravid side. The non-pregnant horn however, is also showing a progressive increase in the size of the vessels and a decreasing tortuosity. There is very slight evidence of the subserous plexus in either horn. Both horns and the body contain fluid filled fetal membranes. Enlargement of the right horn can be definitely noted. The uterine musculature seems to be resisting expansion, thus throwing the uterus into sacculations and folds where a concentration of vessels can be noted, due to the crowding of tissue in the folded areas. The circumferential arteries can be followed to the greater curvature of the uterus. The numerous smaller vessels of the myometrial plexus form a dense network throughout the uterine tissue. The left utero-ovarian artery is prominent and the CL is well injected giving it the typical "woven basket" appearance. View L-3: With the dorsal half of the uterus removed the finer detail of the vasculature can be followed. The amniotic vesicle is readily outlined. The sectioned ovary shows the dense CL meshwork with a basal concentration of vessels. The CL is enclosed by the ovarian capsule. It can be noted that the fluid filled membranes completely occupy both horns and the uterine body. View L-5: The dorsal half of the uterus shows the typical circumferential vessels, and the stretching of the tissues and vessels over the amniotic vesicle. In the uterine body and non-gravid horn, the vascular plexus is more dense but not as well developed in size as in the pregnant horn. There is continued increase in vascularity of the non-gravid horn although it definitely lags behind that of the pregnant horn.

Uterus #106-12; 90 days pregnant; View L-2: The circumferential vessels show a definite increase in size in the left horn. The left horn is larger than the right. The tortuosity of the vessels in the gravid horn is less, and the vessels appear to be straightening out in the manner of stretching out a coiled spring. The fetal skeleton is faintly but definitely discernable. The body of the uterus shows enlargement and increased vascular size but the finer vessels of the myometrial plexus are still somewhat tortuous. The non-pregnant horn definitely shows increased vascularity but considerable tortuosity of the vessels is still evident. The right utero-ovarian artery shows clearly the branches to the ovary and the branch to the anterior portion of the uterine horn. The left ovary shows the larger vessels to the CL in the base of that body. The finer vessels failed to inject. View L-4: This shows the first evidence of caruncles radiographically. The caruncular areas show an increase concentration of vessels. These are supplied by main branches from the circumferential arteries plus numerous smaller vessels. The caruncles near the mesometrial border appear to have more small vessels serving them. Again, a definite difference in the vascular architecture can be noted between the pregnant and non-pregnant horns. The uterine body shows the effect of stretching on the vasculature. Both ovaries injected: the right one shows a general distribution of vessels; the left shows the concentrated meshwork of vessels in the CL with the larger vessels in the base sending radiating branches up to the gland substance.

Uterus #106-14; 120 days pregnant; View R-1: The circumferential vessels in the pregnant horn show definite enlargement but there seems to be an increased coiling of the vessels over the previous specimen. As each major arterial branch enters the mesometrial border, it is observed that definite branching takes place with major branches going dorsally and ventrally. The dorsal and ventral circumferential arteries seem to run in pairs. There is a definite concentration of finer vessels at the mesometrial border. The vessels of the myometrial plexus still show some coiling. The subserous plexus is faintly evident. An increased vessel concentration is faintly visible in the area of the placentomes. Each placentome is served by at least one major branch from a circumferential artery. The skeleton of the fetus is definitely identifiable even to the digits. The chondral and membraneous portions of the skeleton both show signs of calcification. View R-4: A definite difference in size can be noted in the right middle uterine artery over that of the left. The apex of the non-gravid horn still shows a densely tortuous vasculature. The utero-ovarian artery gives off numerous ovarian branches which are tortuous. The CL is well injected and encapsulated, giving the meshwork appearance with the larger vessels at the base of the yellow body. View R-6: The caruncles are readily apparent and each one has at least one major arterial branch from a circumferential artery supplying it. Those caruncles near the mesometrial border have numerous smaller vessels supplying them besides the larger branches. The larger vessels enter the caruncular base and send radiating branches out to serve the entire caruncle. These branchings are essentially straight. The vascular network of the uterus is becoming more concentrated in the caruncular areas. One circumferential artery may supply major branches to more than one caruncle. The sectioned CL shows the typical vascular meshwork but the vessels are not as fine appearing as in some of the previous ones. The left ovary shows a general distribution of small vessels throughout the entire substance. Upon opening the specimen, it was observed that there was a complete persistent median wall of the Muellerian duct from the vestibulo-vaginal junction anteriorly to the uterine cornua. This divided the uterus into two complete units each containing a vagina, cervix, uterine horn, Fallopian tube, and ovary. There was some history of infertility in the animal and it could be explained by the fact that the bull or inseminator had only a 50-50 chance of depositing semen on the side of the functioning ovary. However, she had five normal calves prior to this pregnancy.

Uterus #106-18; 150 days pregnant; View L-1: The circumferential arteries are essentially straight in the pregnant horn. The branches supplying the placentomes enter near the center of the base and seem to give off radiating branches to the entire caruncular tissue. The placentomes show an increasingly complex vascularity. Fine straight vessels can be noted in the intercaruncular areas and they form a freely anastomosing network. Some of these smaller vessels nearing the greater curvature of the uterus show slight evidence of tortuosity. The left utero-ovarian artery is well developed. The CL is very vascular with a network of courser vessels, as in the previous cow, but they still maintain their meshwork appearance. There seems to be a union of the myometrial plexus of vessels and those of the subserous plexus. There is no definite subserous plexus observable in this specimen. View L-5: This shows the anastomoses of the fine terminal branches of the dorsal circumferential arteries across the greater curvature with branches from their ventral counterparts. It should be noted that even though there are anastomoses of blood vessels in this area, it is still the desirable location for surgical incision in Caesarean section because of its relatively small amount of vascularity and the absence of any major caruncles. The vasculature of the caruncles can be observed in fine detail. There appears to be two vascular networks, that of the caruncles and that of supplying the remainder of the uterine tissue. View L-7: The sectioned CL shows the "basket-like" meshwork and the vessels appear somewhat courser than previous specimens. The right ovary did not inject well. The apex of the non-gravid horn still shows tortuous vascularity even though the tissue has been stretched and the vessels have enlarged. The traverse section of the caruncles show the major vessels giving off branches which enter the base of the caruncle. Further branching of these vessels provides a radiating network to the caruncular substance. The radiating branches run from the base to the periphery in a rather straight line. Numerous fine lateral branches can be seen leaving these vessels along their course, supplying a very dense and complex network of vessels within the caruncular substance.

Uterus #106-16; 181 days pregnant; View R-1: The general vascular pattern is essentially similar to the previous specimen. The only difference noted is that all components are larger, and the meshwork of vessels in the placentomes is denser and larger. View R-2: The left ovary shows a well distributed vasculature. The right ovary again shows the typical "basket-like" meshwork of vessels in the CL with larger vessels at the base. The CL is well encapsulated. The apex of the nonpregnant horn shows evidence of increased distention, and the vessels are not as dense and appear straighter.

Uterus #106-15; 210 days pregnant; View R-2: This uterus had two main branches of the right middle uterine artery which arose in a common trunk with the round ligament of the bladder. The posterior uterine artery on the right side was absent. The vasculature to the placentomes is very dense and abundant. The CL appears as a large, densely vascular, encapsulated structure. The general vascular architecture is similar to the previous specimen, but is better developed and the vessels are larger. View R-6: This view again shows the major vessels supplying each caruncle and the definite radiating of the vessels out in the caruncular substance. View R-8: The transverse section of the caruncles show the previously described architecture of the vessels. The CL shows the typical "basket-like" meshwork, the vessels being rather fine in nature. The left ovary did not inject.

Uterus #106-13; 241 days pregnant; View R-1: Essentially the architecture is an enlargement of the previous specimen. The vessels are larger in size but do not appear to be any more abundant. View R-6: Some of the larger caruncles seem to have two centers of vascular distribution somewhat like having two caruncles in one. This view shows very vividly the major vessels entering the base of the caruncle. These vessels then seem to join in a central basal plexus which gives off radiating vessels. These, in turn, travel to the periphery of the caruncular substance. The radiating vessels distribute small lateral branches as they course through the caruncular tissue. The apex of the non-gravid horn shows evidence of stretching but, the vessels still show some tortuosity. View R-7: The transverse section of the caruncles again shows the previously described vasculature. The right ovary contains the "basket-like" meshwork of the CL with the larger vessels at the base. The vessels are essentially fine but the contrast medium ruptured the center of this CL. The left ovary failed to inject.

Uterus #106-11; 273 days pregnant; View L-1: Vessels serving the placentomes appear very large. The vasculature of the individual placentomes seems to be much more complex and abundant than any previous specimen. There are more numerous fine vessels forming a very intricate plexus within the placentome. The left utero-ovarian artery is large and tortuous but the CL did not inject properly. Only the larger vessels at the base of the CL injected. Upon opening this uterus, it was found that there were only 31 caruncles, all in the apex of the left uterine horn. There were no adventitious caruncles noted anywhere in the uterine mucosa. The uterus was receiving adequate blood to maintain the pregnancy even though there were so few caruncles to serve the fetus. View L-6: In this section of the mid-pregnant horn is noted the absence of caruncles. It also shows the intercaruncular fine vascular network which is maintaining nutrition to the uterine tissue. View L-7: The right ovary injected uniformly and shows the fine general vasculature of the ovarian stroma. In the left ovary only the basilar arteries of the CL injected. The contrast medium did not penetrate the finer vessels of the yellow body. The caruncles have a greatly increased network of the fine lateral branching vessels. When these caruncles are compared to those of the previous specimens, it is noted that the vasculature is more dense and the typical radiating appearance of the vessels is less prominent. It appears that, due to the scarcity of caruncles, the ultimate development of those present is much more complex. In order to compensate for the lack in numbers, there is a corresponding increase in complexity, vascularity, and size.

Uterus #106-17; 12 hours after parturition; View R-1: There is a very noticeable decrease in vascularity of this specimen over those of advanced pregnancy. The vessels have shrunken along with the uterine tissue. The caruncles show a peculiar appearance in that the larger vessels are more evident, due to the rapid regression of the finer vessels. The appearance is one of a caruncle with much of its volume taken up by the larger radiating vessels. The ratio of vessel volume to caruncular tissue appears very high. In some areas of the uterus, there is a returning to tortuosity of the vessels. This can be noted in some of the larger vessels as well as the smaller ones. The outline of the CL is evident but not as pronounced as it generally has been in the previous specimens. View R-2: It can be noted that some of the caruncles have hardly any blood supply while still others have the complete plexus of radiating vessels. Involution does not seem to be uniform in all areas of the uterine tissue since some areas appear more regressed than others. The increasing tortuosity of vessels can also be observed here. View R-6: The transverse sections of the caruncles show the decrease in the blood supply with the larger vessels being more prominent. This is due to the more rapid regression of the smaller vessels. The non-gravid apex shows increased tortuosity of the vessels and tissue shrinkage. The cervix is wide open and very avascular. Both ovaries show general vascularity. The CL is less distinct in relation to the vasculature of the rest of the ovarian stroma. The CL meshwork can still be definitely outlined even though there is a definite decrease in the vascularity.

There was definite leakage of the contrast medium between the maternal and fetal placentas in the #106-14 and #106-18 specimens. There was also leakage of contrast medium into the uterine cavity in the #106-17 specimen.

### Microscopic Examinations of the Corpora Lutea of Pregnancy

In the postestrous corpora lutea, a trend in vascularization seems to be present. The five day old postestrous CL contains very immature luteal cells with a definite lack of cellular uniformity. There are few arterioles and very few capillaries. The six day old postestrous CL again contains juvenile luteal cells of varying sizes, and a slight increase in the number of arterioles and capillaries over the previous day. The arterioles are more prominent toward the periphery of the luteal tissue. The nine day old postestrous CL contains mature luteal cells of rather uniform staining and size. The CL stroma is very vascular with numerous capillaries between the luteal cells. There are only a very few immature luteal cells and a slight increase in arterioles. The 12 day old postestrous CL shows an increase in the size and number of arterioles especially near the periphery of the gland. The vasculature tends to decrease as it approaches the center of the luteal tissue. This CL is very vascular and has active mature luteal cells. The 15 day old postestrous CL shows an apparent increase in the size and number of arterioles. There is no noticeable change in the capillaries or the active mature luteal cells. The 16 day old postestrous CL shows a slight change in the luteal cells with an increase staining density and a slightly shrunken appearance. The arterioles are again more prominent and the capillaries are still numerous. There is a definite infiltration of the central portion of the luteal stroma by fibroblasts and fibrous tissue strands. The 21 day old postestrous CL reveals a marked decrease in capillaries, especially in the center of the luteal tissue. There is still a fairly well marked vascularity in the periphery of the luteal tissue. There is marked central fibrosis and clumping of degenerating luteal cells by the invading fibrous tissue. In the periphery there are more shrunken, deep staining luteal cells. The 24 day old postestrous CL shows marked degeneration. The luteal cells have taken on a pyramidal shape and are deep staining even in the periphery. Fibrosis has progressed into the periphery of the luteal tissue. The arterioles are prominent and the capillaries markedly decreased even in the periphery.

The corpora lutea from the pregnant cows seem to show a trend, with one exception, in that the CL from the 241 day old pregnancy did not appear to fall into the normal pattern. The CL from the 90 day old pregnancy contained prominent arterioles which were generally larger than those of any of the cyclic corpora lutea. There is no marked evidence of fibrosis in the luteal tissue. The capillaries are as abundant as any of the cyclic corpora lutea. The cells appear more angular, deeper staining, and not as uniform in size as those in the active cyclic corpora lutea. The CL from the 120 day old pregnancy seems to contain larger arterioles. The cells appear angular with some increase in the space between the luteal cells. The capillaries generally appear unchanged from the previous specimen. The 150 day old pregnancy CL shows evidence of some collagen fibers between the luteal cells. The capillaries are still very abundant. The luteal cells seem to be more angular than those of the previous two, having more space between the cells. The arterioles are large and very prominent. There is a definite fibroplasia beginning. The fibroplasia is not uniform in that one area may appear essentially normal, and immediately beside it is an area of increasing fibrous tissue. The stroma of the CL appears to be undergoing a nonuniform degeneration. The 181 day old pregnancy CL shows increasing fibroplasia with increased fibroblastic infiltration and degeneration of luteal cells. The capillaries do not appear as prominent as in the previous specimens. The arterioles are very prominent. The fibroplasia is again not uniformly distributed. The stroma is extensively infiltrated by numerous macrophages and leucocytes which are mostly neutrophils. The 210 day old pregnancy CL reveals increased fibrosis. The increased degeneration of luteal cells is apparent and they show an increased granularity of their cytoplasm. The arterioles and capillaries are essentially similar to the previous specimen. Degeneration is again sporadic in nature. The 241 day old pregnancy CL is a marked variation from the general pattern being followed by previous specimens. The general appearance of the entire luteal stroma is similar to that of the 12 day cyclic CL. The luteal cells are more uniform in size and staining, but in most cases they show some cytoplasmic degeneration. There is evidence of fibrosis and degeneration but less marked than some of the previous specimens. The arterioles are not as prominent and the capillaries are abundant. This CL appears to be more similar to the active cyclic ones than the other pregnancy corpora lutea. The arterioles are more prominent in this CL than those in the cyclic corpora lutea. The CL from the 273 day old pregnancy is very similar to that of the 210 day specimen. The arterioles seem to be slightly larger. The luteal cells appear quite granular and there is pronounced fibroplasia. The CL of pregnancy taken 12 hours postpartum presents numerous arterioles which are very pronounced. Many of the luteal cells are degenerating with loss of cell membranes, disappearance of nuclei, and dark staining shrunken cytoplasms. Essentially normal appearing luteal cells can still be observed. There are still capillaries present, the abundance depending upon the area of observation. Marked fibrosis is occurring, and almost every luteal cell is surrounded and isolated by collagen fibers. In the corpora lutea there appears to be marked variation in the luteal stroma. For example, a very normal area of active luteal tissue may be immediately adjacent to an area undergoing extensive degeneration.

## DISCUSSION

### Arteriography

The injection procedures utilized by Greene (1951) and Reuber (1954) provided satisfactory results in the pregnant uteri injected in this study. Many problems were encountered due to the fact that each individual uterus provided a different set of circumstances with which to work. It was not possible to establish any set formula for injection quantities of pre-injection rinse or contrast medium. Each uterus was handled with a special technique and only the general procedures common to all injected specimens were static. It was very difficult to determine any increase in digital pressure during injection of the advanced pregnancy uteri. The injection of the small vessels with colored media did serve as a helpful aid in determining the completeness of injection as was noted by Greene (1951). The injection mass quantities may have been excessive in some circumstances as noted by the leakage of contrast medium between the placental membranes in uteri #106-14 and #106-18. It is also definitely known that too much of the medium was injected into the utero-ovarian artery of uterus #106-13 as evidenced by the central rupture of the luteal tissue. In advanced pregnancy, the corpora lutea failed to inject satisfactorily when only the middle uterine arteries were employed and therefore, it was necessary to cannulate the utero-ovarian artery to the ovary and inject some of the medium directly into the ovary. The apparent cause for this lack of injection of the CL could be explained by the fact that the blood tends to follow the way of least resistance, which would be the large uterine vessels rather than the smaller ovarian vessels (Reynolds 1950 and 1952).

It was found that as long as the uterus was kept warm, the contrast medium would not harden or plug the arteries even though the uteri in the latter stages of pregnancy could not be completely immersed in warm water. The injected contrast medium tended to settle out rapidly and therefore constant agitation of the mass and rapid injection became paramount. By using a 50ml. glass syringe, with as rapid an injection rate as possible, only minimal settling of contrast medium occurred within the vessels before complete injection was accomplished. This procedure provided the most satisfactory results.

By using a constant radiographic setting without considering the tissue thickness being radiographed, satisfactory films were obtained which tended to establish a comparable record of the relative thicknesses of various tissues. The contrast medium utilized in the study was formulated exactly like the one used by Reuber (1954). It can be observed from the radiographs that this particular medium provided very graphic representation of the arterial blood supply even to the most minute vessels.

## Arterial Blood Supply to the Bovine Female Genitalia

The general vasculature of the specimens in this study followed the general descriptions given by Hatch (1940), Hansel (1949), Greene (1951), and Reuber (1954). The main area of interest in the blood supply of the uterus was the progressive changes observed as pregnancy advanced. There was a progressive enlargement and development of the vessels supplying the uterus. Initially, there is an increase in the number and size of vessels within the uterus up through the 90th day of pregnancy. The uterus, 120 days pregnant, appears to be the beginning of rapid uterine distention. In comparing the films of the 90 day and 120 day pregnancy, there seems to be a decrease in intrauterine tension as evidenced by the increased coiling of the vessels of the latter. The period of uterine growth in the sheep is up to 90 days of gestation. Then the period of rapid uterine distention or stretching occurs (Reynolds 1949b, and Barcroft and Barron 1946). It appears that in the cow the period of conversion occurs between 90 and 120 days of gestation, as is suggested by the vascular patterns observed in these specimens. In rabbits, there is a definite spheroid development, conversion, and then cylindrical development (Reynolds 1937a). In the cow, however, there seems to be no distinct period of only spheroid development or of only cylindrical development. Instead, there appears to be a progressive increase both in diameter and length throughout the entire gestation period. There also appears to be a distinct period of uterine growth followed by the period of uterine stretching, the time of conversion being sometime between the 90th and 120th days of pregnancy.

There is a progressive development of vascular tissue in size and quantity up to the 90th day of gestation. From this point the changes in the uterine vasculature tend to be more in size of vessels rather in the number. There is, however, one exception to this in that the caruncles begin to grow rather rapidly from the 120th day of pregnancy to term. There is also an increase in the number as well as size of the caruncular vessels. Radiographically, no evidence of the caruncles could be determined until the 120th day of pregnancy. Foley and Reece (1953) were able to show an increased vascularity of the caruncular plates by the 30th day of pregnancy.

Circumferential arteries show definite evidence of stretching in the 150 day pregnant uterus. Throughout the rest of gestation, the major change in the vasculature is increase in length and diameter of the vessels. The caruncles undergo marked development as pregnancy advances from the 120th day on. Each caruncle is supplied with at least one major branch of a circumferential artery and several small vessels. The caruncles seem to attain their maximum size and vascularity by the 241st day of pregnancy. Probably the reason for the definite increase of small vessels in the caruncles of the 273 day pregnancy is that there were only 31 caruncles to maintain the fetus. In studying the radiographs in the order of the length of gestation, a progressive and orderly development of the uterine vasculature is observed which is adequate for the maintenance of pregnancy. Harvey (1959) and Roberts (1956) state that between 70 or 75 and 120 caruncles per cow is normal. However, the 150 and 273 day pregnancies had considerably fewer than 70 caruncles with no apparent ill effect on the pregnancy.

The radiographic outline of the caruncles in advanced pregnancy generally agrees with the description by Hatch (1940). The arteries entering the stalk of the caruncle seem to join in a circular plexus of anastomosing vessels in the base of the caruncular tissue. From this plexus, the vessels radiate to the periphery of the caruncle forming a very dense parallel network. Fine lateral branches sprout from the radiating vessels as they pass to the caruncular surface. These vessels form a dense lateral network of fine anastomosing vessels around the radiate arteries. The most complex caruncular vasculature is observed in the 273 day pregnancy, but this specimen must be considered as somewhat of an oddity.

The vascular network of the intercaruncular areas shows progressive enlargement and anastomosing. The vessels of this area are supplying the uterine tissue and uterine glands. They form a network of vessels which send anastomosing branches across the greater curvature to members on the opposite side of the uterine horn. The general vasculature in this area of the uterus corresponds with the descriptions by Hatch (1940), Hansel (1949), Greene (1951), and Reuber (1954).

Reynolds (1949b) discussed the fact that the uterus in the rabbit shunts the blood to the mesometrial vascular bed when increased intra-uterine tension causes interference with the circulation in the lateral walls of the uterine horn. In this way, the pregnancy is maintained even though there is embarrassment to part of the uterine blood supply. It is noted that the caruncles in the region of the mesometrial border have many more smaller vessels supplying them than the caruncles situated in the lateral walls of the uterine horns. The caruncles of the lateral walls tend to have one major vessel supplying the branches for blood supply along with a few other small vessels. The caruncles in the region of the mesometrial border do not seem to have any one major vessel supplying them. There are, instead, numerous small vessels entering the base of the caruncles in this area. In event that the intrauterine pressure becomes too much for adequte blood supply to the caruncles in the lateral walls, the mesometrial caruncles with their more numerous vasculature could maintain the fetus during this time of stress.

Even though this work was mainly on the pregnant uterine vasculature, it was felt that to appreciate the full cycle of events, a uterus from a postparturient cow should be included. It is noted that even by 12 hours postpartum there is a very marked decrease in the size of the uterus and its components. The vessels again show the tortuosity previously seen before marked uterine distention had occurred. There appears to be a non-uniform involution, with some caruncles showing an almost complete lack of blood supply, while still others maintain the major vasculature observed during pregnancy. In all areas, there appears to be a more rapid regression of the smaller vessels than the larger vessels. All the uterine vessels are markedly reduced in size. It should also be noted, that there is a direct avenue of leakage from the caruncles as evidenced by the collection of contrast medium in the uterine cavity.

The leakage of contrast medium between the maternal and fetal placentas in the 120 and 150 day pregnancies would seem to indicate that the caruncles were developing an intricate blood supply. However, the attachment of the fetal membranes was not complete. The explanation considered most plausible was that the fetal membrane attachment was not complete and therefore not secure enough to prevent the leakage of the contrast medium from the caruncular blood vessels. If there was some other explanation, it would be reasonable to expect leakage in some of the other uteri. Roberts (1956) lists the period of loose fetal membrane attachment as the first third of gestation. In the cow, the attachment is incomplete up to 120 days of pregnancy after which very easy separation of the fetal and maternal membranes is not possible.

In all specimens, the vasculature to the CL is well injected except in the case of the 273 day pregnancy. This can be explained by the fact that collateral circulation was relied upon for injection of the ovary instead of direct injection of the utero-ovarian artery, as was required in some of the other uteri in advanced pregnancy. Reynolds (1950) and (1952) demonstrated that sufficient circulation to a part is maintained by efficient blood flow. Therefore, it would be normal for the least resistance to blood flow to be in the uterine vessels, due to their greatly increased size. Thus, during injection of the middle uterine artery, the contrast medium followed the path of least resistance and some of the ovaries failed to inject by the collateral circulation. It was necessary, therefore, to inject some of the utero-ovarian arteries directly to obtain injection of the CL. No definite statement can be made as to whether ovarian activity had any effect on the injection of the respective ovaries. It would seem plausible that ovarian activity would have some effect on the injection of the vasculature in the ovary.

The description of the general ovarian vasculature by Greene (1951) and Reuber (1954) is generally corroborated by the radiographs of these specimens. The utero-ovarian and ovarian arteries show the characteristic spiralling in all specimens and there is a general increase in the size of the vessels to the ovary with the CL of pregnancy. However, these vessels do not seem to straighten out appreciably as pregnancy progresses. The typical "woven basket" appearance of the CL vessels is apparent in all specimens except the uninjected one of the 273 day pregnancy. The vessels in the corpora lutea at first seem to be fine with courser ones appearing in the 90 day pregnancy and then, appearing finer again in the 181 day specimen to term. The significance of this finding is undetermined. A definite regression of the vessels in the CL of the postpartum uterus is observed by the fact that the general vasculature of the ovary tends to obscure the outline of the CL. It can be noted that non-uniform results were obtained in the injection of the ovaries without the CL. If detailed studies of corpora lutea are desirable, it is recommended that an injection technique be developed which utilizes a direct injection of the ovarian vessels rather than one which relies upon collateral circulation for injection of the part. To gain further knowledge of the role of the CL during pregnancy, it is suggested that future studies include histochemical studies of the luteal cells, more extensive histological sectioning, and more numerous specimens throughout the gestation period.

The microscopic sections of the pregnancy corpora lutea seemed to show a definite trend in their vasculature. The general vasculature of the 90 day CL through the 150 day CL seemed to be more abundant than that of the CL at its most active stage postestrus. There is definitely a better development of arterioles. The capillaries also are as abundant as those of the postestrus period. The 150 day CL begins to show signs of some capillary degeneration and increase of fibrous tissue. From this stage of gestation to term, there appears to be a gradual decrease in the number of capillaries within the luteal tissue. The arterioles tend to become more prominent as a result of the capillary degeneration. There is a very rapid degeneration of luteal blood vessels in the postpartum CL. There is one definite exception to the trend just described. The CL from the 241 day pregnancy is more active looking than others of the gestation period. When compared to the most active corpora lutea of the postestrus period, it has a similar vascular development. There is only one explanation for this result and that is individual variability. The luteal cells of the pregnancy corpora lutea did not generally appear as uniform in size and staining properties as those from the postestrus ones, with the exception again of the 241 day pregnancy. The abundant vasculature to the pregnancy CL described by Foley and Reece (1953) closely corresponds with that found in the pregnancy corpora lutea of this study. The corpora lutea remained enlarged throughout the entire gestation period as reported by Benesch and Wright in 1951. The luteal cell activity seems to parallel the adequacy of the blood supply to the CL. The luteal cells begin to show signs of degeneration at the time that the luteal blood supply begins to show regression. The luteal activity, it would seem, might be directly dependent upon the blood supply to the gland. Without the aid of microscopic sections of the CL, it would have been very difficult to ascertain by the injection technique whether there was any change in the vessels during gestation. Even with the microscopic sections, it should be noted that there is much individual variability among the corpora lutea of pregnancy. Any attempt to correlate chronological events of gland activity with specific changes in the vasculature should not be without reservations. Before any specific statements are made, there should be a more extensive study made of the CL during all stages of pregnancy.

## Uterine Accommodation During Pregnancy

It is difficult to ascertain from the results of this study just when certain stages of uterine accommodation occur. Reynolds (1955) lists three distinct stages of uterine accommodation in all mammals. These are uterine preparation, uterine growth, and uterine stretching with the onset and length of each dependent upon the species involved. He maintains that only the pregnant horn undergoes growth initially, due to the interplay of hormones and the products of conception. Reynolds (1952) considers that the non-pregnant horn does not grow until the pregnant side has almost reached its maximum development. In this study, by comparing the pregnant horn to the non-pregnant one, it can be noted that there is a different rate of development between the two. Reynolds (1949b) feels that the longer the period of CL activity, the longer the period of uterine growth, and this depends upon the species, breed, and individual. Hammond (1927) found in the cow that the myometrium hypertrophies greatly up to the fifth or sixth month of pregnancy. Hatch (1940) observed noticeable stretching and thinning of the uterine tissue by the 12th week of gestation.

The radiographs in this study show a tendency for overlapping of the various stages of uterine accommodation. No definite demarcation is possible by the methods utilized in this study. It is apparent that the films of the 22 day, 30 day, 45 day, and possibly the 60 day pregnancies show evidence of uterine hyperplasia. Definite uterine hypertrophy seems to be occurring in the 60 day pregnancy and appears to continue through the 181 day pregnancy. From 181 days to term, the major accommodation of the uterine tissue tends to be one of stretching. It must be noted, however, that there is no definite demarcation between any of the three processes of accommodation. Uterine stretching is definitely occurring by the 120th day of gestation and there appears to be hypertrophy of some uterine tissue up to the 273 day pregnancy. The processes in the bovine are more complex than rodents. This is because the caruncular arrangement provides for some uterine growth throughout the gestation period and the vasculature is continually enlarging to accommodate the products of conception. Reynolds (1939) was able to show a distinct and definite time of conversion in the rabbit. It appears that in this study, conversion occurred between 90 and 120 days. The caruncles seem to attain their maximum size by the 241st day of pregnancy. It is also demonstrated that further development of the caruncular vasculature is possible to maintain the fetus, as is evidenced by the more extensive vasculature of the caruncles in the 273 day specimen over that of the 241 day uterus.

No experimental data were obtained to ascertain what events were responsible for parturition. It is assumed that the work by Reynolds (1952), Corner and Csapo (1953), Csapo (1956), and Csapo (1959) holds essentially true for all mammals and therefore would be found in the bovine. The radiograph of the postparturient uterus shows the remarkable capacity of the uterine tissue to involute after the expulsion of the products of conception. If one compares the size of the uterine tissue in the radiographs of the 241 and 273 day pregnancies with that of the postpartum one, it is clearly evident that involution is a rapidly occurring process. Much regression has already occurred by 12 hours after the expulsion of the uterine contents.

## Pregnancy Hormones

This experiment does not directly involve the determination of various hormone levels during pregnancy. The discussion of some of the hormones involved in pregnancy and parturition, in the literature review section, is only to provide background material. This was done to try and correlate some of the possible findings of this research.

Roberts (1956) reported that the CL of pregnancy was essential up to the 200th day of gestation. Its removal up to the 236th day of gestation had resulted in abortion in some instances. The results of McDonald et al. (1952 and 1953) showed this to be the case. McNutt (1927) determined that the CL remained present until parturition. Price (1956) could find no gross involution in the CL up to parturition and no cellular degeneration during the first five months. Gorski et al. (1958) isolated large amounts of progesterone from the CL and ovary of a 280 day gestation. In this study, it appears that degeneration of the luteal tissue begins to occur around the 150th day of gestation. No CL of pregnancy in this study showed sufficient regression to lead one to believe that progesterone production completely ceased at any time during the gestation period. In fact, the CL of pregnancy from the 241 day gestation period previously described is a good example of the variation that occurs in biological processes. It could be hypothesized that the more active the CL of pregnancy in progesterone production, the later the inhibitory action to the uterus is assumed by the pregnant uterus and its contents. If this hypothesis is correct, it could be an explanation for those abortions that occur after the 200th day when the CL is removed. It seems logical to suspect that the 241 day CL described above would have, upon removal, resulted in an abortion at this advanced stage of pregnancy. Thus, it is theorized that the inhibitory action of the CL of pregnancy is one of degree of progesterone production dependent, to a large extent, on the hemodynamics of the ovary and gland. McDonald et al. (1952 and 1953) reported an abortion in a cow 236 days pregnant following the removal of the CL of pregnancy.

Many investigators have tried to ascertain whether the bovine placenta takes over the production of progesterone or progesterone-like substance in late pregnancy. However, all the work to date can be summarized with the statement of Salisbury and VanDemark (1961) that there has been no work to date which clarifies whether the bovine placenta secretes progesterone or any like substance. Melampy et al. (1959) isolated progesterone from the placenta of pregnant cows. Robinson (1957) aptly pointed out that isolation of a hormone from a tissue does not necessarily mean that the tissue is actively secreting the hormone. Velle (1962)[1] stated that progesterone has been isolated from the CL up

---

[1] See Private Communication Page 21.

to 250 days of gestation. He also maintains that the production of progesterone by the adrenal gland is in minute quantities and constant. Melampy et al. (1959) were able to show an increase in progesterone concentration in the CL, placenta, fetal fluids, and adrenal up to the 200th day of gestation and then, a decreasing trend until term.

It must be remembered that the cow has the lowest sex hormone output requirement of all the domestic animals and therefore it is difficult to determine what these various results in hormone isolation mean. It is conceivable that due to this low requirement, the quantities required for physiological action are so low that they are not measurable with our present assay procedures. If this is the case, it could very well be that the CL is the only major source of progesterone necessary for pregnancy in the cow. In this study, it was noted that every CL of advanced pregnancy, and even the one from the postpartum animal, had some normal appearing luteal cells which could have been secreting progesterone. Csapo (1959) discusses the theory of local myometrial block by progesterone. If this is the case in the bovine species, it is conceivable that the placenta secretes small amounts of progesterone in the later stages of pregnancy which are utilized at the site of production. This would possibly explain the differing results obtained so far in experimentation with the hormone in pregnant cows. However, the extensive development of the vascular system in the uterus as pregnancy advances could account for the efficient local distribution of the hormone secreted by the CL. Short (1960) maintains that to date, no one has prolonged gestation in the cow by the parenteral administration of progesterone. This has been accomplished in some of the rodents which require their corpora lutea up to the time of parturition. This would tend to suggest that in the later stages of pregnancy in the cow, there is some other source of progesterone other than the CL.

Csapo (1959) feels that the placenta eventually takes over the control of pregnancy from the CL in all species of animals. He found that the progesterone response was very marked at local placental sites in the rabbit. Bengtsson (1961) observed that in the human, massive intravenous doses of progesterone near term were inadequate in preventing the contractile effect of oxytocin on the uterine musculature. The reason for this is still unexplained but might be due to the fact that at this stage of gestation the progesterone has only a local effect on the uterine muscle. It is clearly evident that there is much conflicting data in this field of hormone research and results in the cow are no exception.

Variations in hormonal responses between species (even animals of the same species) serve to emphasize the fallacy of attempting to apply the experimental results obtained in the rat or the rabbit to the cow.

## SUMMARY

The twelve cows utilized in this study were subjected to timed slaughter and recovery of their isolated pregnant uteri. Unusually accurate breeding and reproductive performance histories were available on all the cows used in this project. The cows included eleven pregnant and one postparturient. The modification of Lum's (1946) technique by Reuber (1954) proved quite satisfactory for these pregnant uteri.

A permanent record of the actual arterial architecture to the pregnant uteri and ovaries was obtained by making a total of 92 radiographs following injection of the arterial system with the contrast medium. There were progressive changes in the uterine vasculature as pregnancy advanced. The specialized maternal areas of fetal membrane attachment, the caruncles, showed a definite and progressive growth and complexity of arterial architecture. The general distribution of arteries in the uterus was easily recorded by this arteriographic technique. A study of the radiographs showed that there was very little or no increase in the blood volume of the pampiniform plexus of vessels when there was little or no activity in the ovary. The pampiniform plexus on the nongravid side is almost equal to that of the gravid side when the ovary showed follicular activity.

As the study progressed, it was discovered that additional aids in the form of histological and histochemical studies were needed to observe the degenerative or retrogressing processes taking place in the corpora lutea and caruncles. The ovaries with the corpora lutea from the cows in advanced stages of pregnancy were sectioned and stained for microscopic examination. The microscopic sections provided more accurate information as to the progressive cytological and vascular changes in the CL as pregnancy advanced. Gross changes in the CL were not evident.

# CONCLUSIONS

Arteriography provides a better panoramic mental picture of the arterial architecture of the pregnant bovine uterus than any other technique available at the present time.

This study, as well as Greene's (1951) and Reuber's (1954), impresses one more and more with the role of the circulation (hemodynamics) in not only assuring but also insuring and inducing the effect of specific hormones on specific target organs.

Arteriography does not allow the direct observation of degenerative processes. It is only indirectly that one can detect degeneration by arteriographically observed reductions in the blood supply, and then only in the more advanced retrogressions. It is recommended that future studies include the more direct observations of the organs or systems being studied by histological and histochemical means. Such aids will verify the arteriographic findings. It is entirely possible that the investigator could develop his radiographic interpretative skill by this means, so that he could recognize degenerative processes earlier and still retain the best method of determining the overall vascular picture. It is difficult and time consuming to study all of the microscopic preparations necessary to reconstruct the overall vascular picture that is seen at a glance in arteriography.

As pregnancy advances, the uterine vasculature progressively adapts itself to accommodate the products of conception. The caruncles in the mesometrial region have a larger and more intricate blood supply. The caruncles in this area are generally larger in size than those on the lateral walls. In the 273 day pregnant uterus the apical caruncles were very large; whereas, in the other uteri the apical caruncles were generally smaller. The mesometrial caruncular bed would provide an adequate blood supply to the fetus at those times when the circulation in the caruncles of the lateral walls become embarrassed, by increased intrauterine tension. The 31 enlarged caruncles in the apex of the uterine horn of the 273 day pregnancy are a perfect example of biological adaptation to stress.

The caruncles begin their period of organization and rapid vascular development at about 120 days of gestation.

The activity of the ovary on the non-gravid side is closely related to its circulation. The ovaries with active appearing follicles tend to have an increased blood supply over those ovaries that show no follicular activity.

There is extensive overlapping of the periods of uterine accommodation in the uteri of these cows. In general, it can be said that most of the hyperplasia occurs up to the 60th day, hypertrophy between 61 and 180 days, and stretching between 181 days and term.

Uterine conversion occurs between the 90th and 120 day of pregnancy. From 120 days to term rapid uterine distention is evident.

Fetal membrane attachment is not definitely complete until after the 150th day of gestation.

There is rapid involution of all uterine tissues postpartum. There is a great shrinkage of tissue and the extensive vascular network undergoes rapid regression.

The activity of the luteal cells is closely correlated to their blood supply. The degeneration of luteal cells and the regression of the associated vasculature are closely paralleled and begin to occur around the 150th day of pregnancy.

At no time during the gestation period is the CL devoid of all normal appearing luteal cells. Therefore, the CL always has some cells which appear capable of secreting progestins.

Individual variation must always be considered when dealing with biological processes. Care must be taken not to misinterpret information gathered in certain individuals, when trying to correlate these findings with those of other individuals, breeds, and species.

## LITERATURE CITED

Anderson, Dorothy H. 1926. Lymphatics and blood vessels of the ovary of the sow. Carnegie Institute of Washington. Contributions to Embryology. 17:107-124.

Asdell, S. A. 1955. Cattle fertility and sterility. Boston, Mass. Litte, Brown and Co.

Balfour, W. E., Comline, R. S. and Short, R. V. 1957. Secretion of progesterone by the adrenal gland. Nature. 180:1480-1481.

Barcroft, Joseph and Barron, Donald H. 1946. Observations upon the form and relations of the maternal and fetal vessels in the placenta of the sheep. Anatomical Record. 94:569-596.

Benesch, Franz and Wright, John G. 1951. Veterinary obstetrics. London, Eng. Bailliere, Tindall and Cox.

Bengtsson, Lars. 1961. The effects of progesterone on the maintenance of early pregnancy. In Brook Lodge Symposium: progesterone. pp. 49-52. Augusta, Mich. Brook Lodge Press.

Catchpole, Hubert R. 1959. Endocrine mechanisms during pregnancy. In Cole, H. H. and Cupps, P. T., eds. Reproduction in domestic animals. Vol. 1. pp. 469-507. New York, N. Y. Academic Press.

Corner, George W. and Csapo. Arpad. 1953. Action of the ovarian hormones on uterine muscle. British Medical Journal. 1:687-693.

Cowie, Alfred T. 1948. Pregnancy diagnosis tests: a review. Great Britian. Commonwealth Agricultural Bureau. Joint Publication. 13.

Csapo, Arpad. 1956. Progesterone "block". American Journal of Anatomy. 98:273-291.

_______. 1959. Function and regulation of the myometrium. Annals of the New York Academy of Sciences. 75:790-808.

_______. 1961. The role of progesterone in the maintenance and termination of pregnancy. In Brook Lodge Symposium: progesterone. pp. 7-23. Augusta, Mich. Brook Lodge Press.

Delson, Barnet. 1949. Non neoplastic ovarian cysts; their relation to spiral arteries in the human ovary. American Journal of Obstetrics and Gynecology. 57:1120-1132.

_______, Lubin, Samuel and Reynolds, S. R. M. 1949. Vascular patterns in the human ovary. American Journal of Obstetrics and Gynecology. 57:842-853.

Dorland, W. A. Newman. 1951. The american illustrated medical dictionary. 22nd ed. Philadelphia, Penn. W. B. Saunders Company.

Dukes, H. H. 1955. The physiology of domestic animals. 7th ed. Ithaca, N. Y. Comstock Publishing Associates.

Emmens, C. W. 1959. Role of gonadal hormones. In Cole, H. H. and Cupps, P. T., eds. Reproduction in domestic animals. Vol. 1. pp. 111-147. New York, N. Y. Academic Press.

Fitzpatrick, R. J. 1957. On oxytocin and uterine function. In Heller, H., ed. The neurohypophysis. pp. 203-220. London, Eng. Butterworth.

Foley, R. C. and Reece, R. P. 1953. Histological studies of the bovine uterus, placenta and corpus luteum. Massachusetts Agricultural Experiment Station Bulletin. 468.

Gorski, J. and Erb, R. E. 1959. Characterization of estrogens in the bovine. Endocrinology. 64:707-712.

_______, _______, Dickson, W. M. and Butler, H. C. 1958. Source of progestins in the pregnant cow. Journal of Dairy Science. 41:1380-1386.

Greene, William Arthur. 1951. Radiographic demonstration of circulatory (arterial) variations in isolated bovine female internal genitalia. Unpublished M.S. Thesis. Ames, Iowa. Library, Iowa State University of Science and Technology.

Guyton, Arthur C. 1961. Textbook of medical physiology. 2nd ed. Philadelphia, Penn. W. B. Saunders Company.

Ham, A. W. 1953. Histology. 2nd ed. Philadelphia, Penn. J. B. Lippincott Company.

Hammond, John. 1927. The physiology of reproduction in the cow. London, Eng. Cambridge University Press.

Hansel, William. 1949. A study of metestrus bleeding in dairy cattle. Unpublished Ph. D. Thesis. Ithaca, N. Y. Library, Cornell University.

Harvey, Elmer B. 1959. Implantation, development of the fetus and fetal membranes. In Cole, H. H. and Cupps, P. T., eds. Reproduction in domestic animals. Vol. 1. pp. 433-466. New York, N. Y. Academic Press.

Hatch, Ray D. 1940. Anatomical changes in the bovine uterus during pregnancy. Unpublished M.S. Thesis. Ames, Iowa. Library, Iowa State University of Science and Technology.

Heckel, George P. and Allen, Willard M. 1939. Maintenance of the corpus luteum and inhibition of parturition in the rabbit by injection of estrogenic hormone. Endocrinology. 24:137-148.

Hendricks, Charles H., Brenner, William E., Gabel, Ronald A. and Kerenyi, Thomas. 1961. The effects of progesterone administered intra-amniotically in late pregnancy. In Brook Lodge Symposium: progesterone. pp. 53-64. Augusta, Mich. Brook Lodge Press.

Lum, R. 1946. Notes on an elastic radio-opaque injection mass. Anatomical Record. 96:165-181.

Maximow, A. A. and Bloom, W. 1952. Histology. 6th ed. Philadelphia, Penn. W. B. Saunders Company.

McDonald, L. E., Nichols, R. E. and McNutt, S. H. 1952. Studies on corpus luteum ablation and progesterone replacement therapy during pregnancy in the cow. American Journal of Veterinary Research. 13:446-451.

_______, _______ and _______. 1953. On the essentiality of the bovine corpus luteum of pregnancy. American Journal of Veterinary Research. 14:539-541.

McLeod, W. M. 1956. Bovine Anatomy. Manhattan, Kansas. W. M. McLoed.

McNutt, G. W. 1924. The corpus luteum of the ox ovary in relation to the estrous cycle. American Veterinary Medical Association Journal. 65:556-597.

_______. 1927. The corpus luteum of pregnancy in the domestic cow (Bos taurus) and a brief discussion of cyclic ovarian changes. American Veterinary Medical Association Journal. 72:287-299.

Melampy, R. M., Hearn, W. R. and Rakes, J. M. 1959. Progesterone content of bovine reproductive organs and blood during pregnancy. Journal of Animal Science. 18:307-313.

Metcalfe, James, Romney, Seymour,L., Swartwout, Joseph R., Pitcairn, Donald M., Lethin, Anton N. Jr. and Barron, Donald H. 1959. Uterine blood flow and oxygen consumption in pregnant sheep and goats. American Journal of Physiology. 197:929-934.

Nalbandov, A. V. 1958. Reproductive physiology. San Francisco, Calif. W. H. Freeman and Company.

Parkes, A. S. 1952. Marshall's physiology of reproduction. Vol. 2. 3rd ed. London, Eng. Longmans, Green and Company.

_______. 1956. Marshall's physiology of reproduction. Vol. 1. Part 1. 3rd ed. London, Eng. Longmans, Green and Company.

Plotz, E. Jurgen. 1961. Studies with labelled progesterone in human pregnancy. In Brook Lodge Symposium: progesterone. pp. 91-104. Augusta, Mich. Brook Lodge Press.

Price, Alvin Audis. 1956. The relationship between luteal cholesterol and various stages of the bovine estrous cycle. Unpublished M.S. Thesis. College Station, Texas. Library, A and M College of Texas.

Ramsey, Elizabeth M. 1959. Vascular adaptations of the uterus to pregnancy. Annals of the New York Academy of Sciences. 75:726-745.

Reuber, Herbert W. 1954. Arteriography of the cyclic estrual changes in the internal genitalia of the cow (Bos Taurus). Unpublished M.S. Thesis. Ames, Iowa. Library, Iowa State University of Science and Technology.

Reynolds, S. R. M. 1937a. Hemodynamic factors in the uterus during the latter part of gestation. Nature. 140:546.

_______. 1937b. The nature of uterine contractility. Physiological Reviews. 17:304-334.

_______. 1939. Physical conditions in the uterus governing the duration of pregnancy. Anatomical Record. 75:175-193.

_______. 1946. The relation of hydrostatic conditions in the uterus to the size and shape of the conceptus during pregnancy: A concept of uterine accommodation. Anatomical Record. 95:283-296.

_______. 1948. Morphological determinants of the flow characteristics between an artery and its branch, with special reference to the ovarian spiral artery of the rabbit. Acta Anatomica. 5:1-16.

_______. 1949a. Adaptation of maternal uterine blood vessels and uterine accommodation of the products of conception. Carnegie Institute of Washington. Contributions to Embrology. 33:3-20.

_______. 1949b. Physiology of the uterus. 2nd ed. New York, N. Y. Paul B. Hoeber, Inc.

_______. 1950. The vasculature of the ovary and ovarian function. In Pincus, G., ed. Recent progress in hormone research. New York, N. Y. Academic Press. 5:65-100.

_______. 1952. Physiological bases of gynecology and obstetrics. Springfield, Ill. Charles C. Thomas.

_______. 1955. Gestation mechanisms. In Proceedings of the Centennial Symposium of Reproduction and Infertility. pp. 71-78. East Lansing, Mich. Michigan State University.

Roberts, Stephen J. 1956. Veterinary obstetrics and genital diseases. Ithaca, N. Y. Stephen J. Roberts.

Robinson, T. J. 1957. Pregnancy. In Hammond, J., ed. Progress in the physiology of farm animals. Vol. 3. pp. 793-904. London, Eng. Butterworths.

Robson, J. M. 1947. Recent advances in sex and reproductive physiology. 3rd ed. Philadelphia, Penn. The Blakiston Company.

Salisbury, G. W. and VanDemark, N. L. 1961. Physiology of reproduction and artificial insemination of cattle. San Francisco, Calif. W. H. Freeman and Company.

Schlegel, J. U. 1945:46. Arteriovenous anastomoses in the endometrium in man. Acta Anatomica. 1:284-325.

Schofield, Brenda M. 1961. The influence of progesterone on functional activity of the myometrium in the intact animal. In Brook Lodge Symposium: progesterone. pp. 45-48. Augusta, Mich. Brook Lodge Press.

Short, R. V. 1960. Blood progesterone levels in relation to parturition. Journal of Reproduction and Fertility. 1:61-70.

Sisson, Septimus and Grossman, James Daniels. 1953. The anatomy of domestic animals. 4th ed. rev. Philadelphia, Penn. W. B. Saunders Company.

Smith, P. E. and Copenhaver, W. M. 1953. Bailey's textbook of histology 13th ed. Baltimore, Md. The Williams and Wilkins Company.

Trautmann, Alfred and Fiebiger, Josef. 1952. Fundamentals of the histology of domestic animals. Ithaca, N. Y. Comstock Publishing Associates.

Turner, C. Donnell. 1960. General endocrinology. 3rd ed. Philadelphia, Penn. W. B. Saunders Company.

Uren, A. W. and Raeside, J. I. 1951. Preliminary report on the level of progesterone necessary to maintain pregnancy in dairy cattle. American Veterinary Medical Association. Proceedings. 1951:251-253.

Wright, Samson. 1952. Applied physiology. 9th ed. London, Eng. Oxford University Press.

Zander, Josef. 1961. The chemical estimation of progesterone and its metabolites in the body fluids and target organs. In Brook Lodge Symposium: progesterone. pp. 77-89. Augusta, Mich. Brook Lodge Press.

Zarrow, M. X. 1956. Maternal hormones in pregnancy. In Villee, C. A., ed. Gestation. pp. 17-52. New York, N. Y. Corlies, Macy and Company, Inc.

________ and Lazo-Wasem, E. A. 1955. Release of progesterone-like substance from the adrenal gland. Acta Endocrinologica. 18:273-280.

# ACKNOWLEDGEMENTS

For their kind and willing assistance, I am grateful to:

Dr. M. A. Emmerson for his suggestions, guidance, and criticism during this study.

Dr. F. K. Ramsey and Dr. D. E. Tyler for their aid in the interpretation of the histological sections.

Dr. C. H. Covault for his suggestions concerning the thesis contents.

Mr. L. A. Facto for his fine photographic reproductions of the research specimens.

Mrs. P. Alvina Owenson for her preparation of the microscopic slides.

My wife Connie for her help in proofreading this paper.

# APPENDIX A

## Legend

ABL - Anastomosing branch between the left utero-ovarian and branch of the middle uterine artery

ABR - Anastomosing branch between the right utero-ovarian and branch of the middle uterine artery

BP - Basal plexus of the caruncle

CA - Circumferential (arcuate) artery

CAR - Caruncle

CL - Corpus luteum

FS - Fetal skeleton

LMA - Left middle uterine artery

LO - Left ovary

LPP - Left pampiniform plexus

LPU - Left posterior uterine artery

LUO - Left utero-ovarian artery

MV - Myometrial vessels

RA - Radiate arteries of the caruncle

RMA - Right middle uterine artery

RO - Right ovary

RPP - Right pampiniform plexus

RPU - Right posterior uterine artery

RUO - Right utero-ovarian artery

SP - Subserous plexus

Note: All the reproductions in this appendix are reduced two and one half times over the originals except #106-2; View L-4; which is enlarged three times.

Figure 1. #106-2; View L-1: Pregnant 22 days. Intact uterus and ovaries. Note the slight increase in the blood supply to the left horn. The subserous plexus is clearly evident.

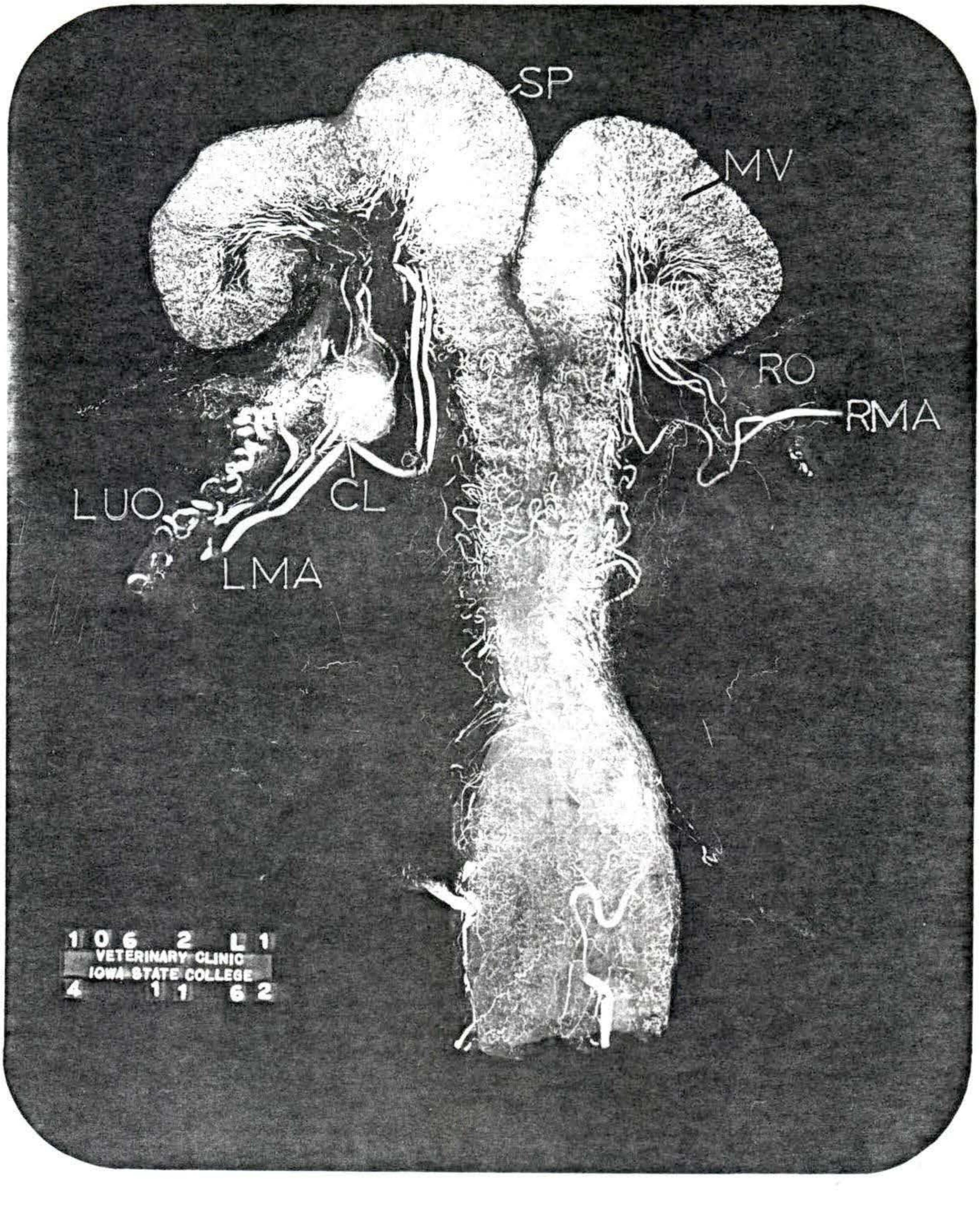
SP
MV
RO
RMA
CL
LUO
LMA
1 0 6 2 L 1
VETERINARY CLINIC
IOWA STATE COLLEGE
4 1 1 6 2

Figure 2. #106-2; View L-4: Pregnant 22 days. The left ovary contains the CL (photograph enlarged 3x actual size). Note the extensive "woven basket" vasculature in the luteal tissue.

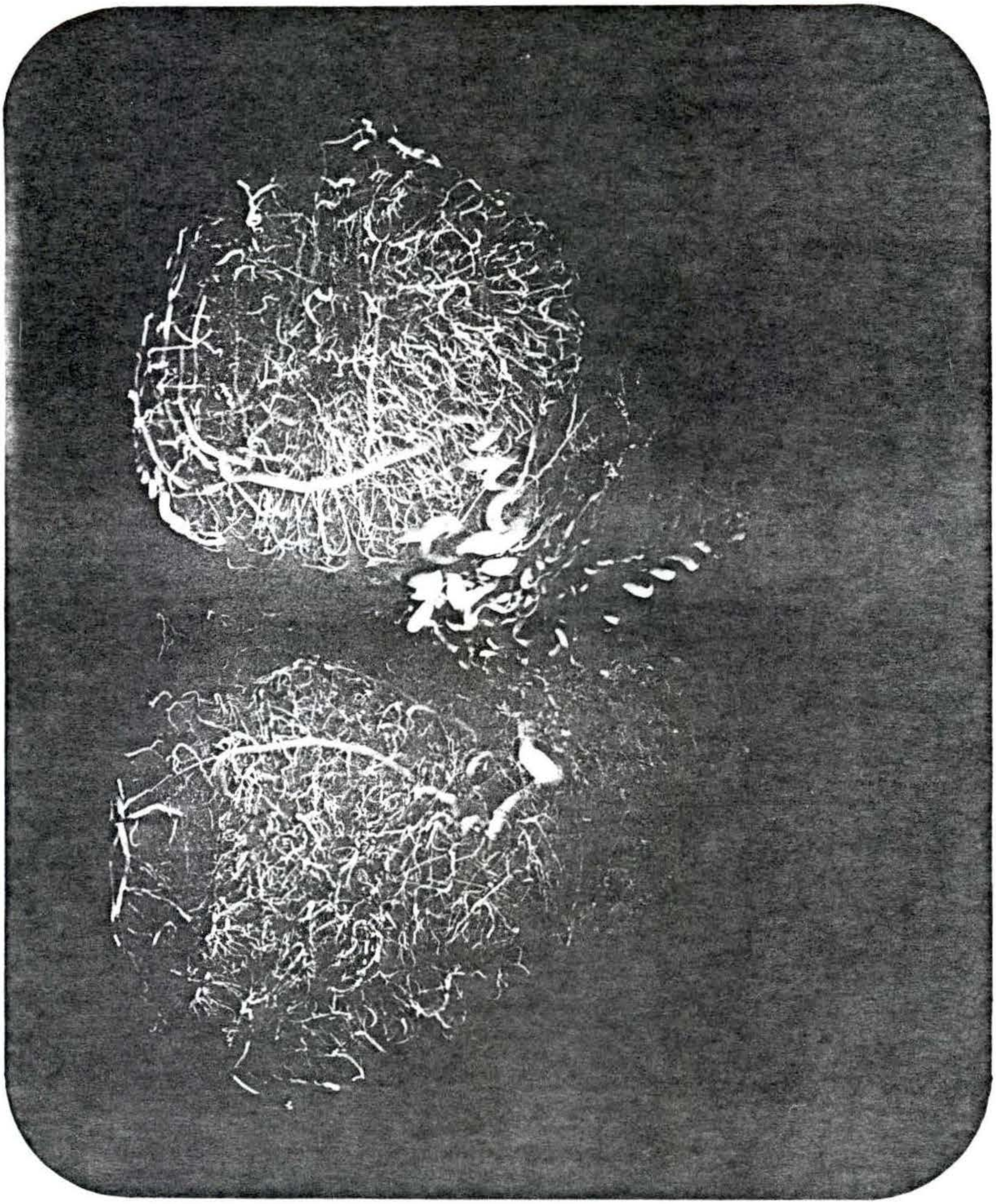

Figure 3. #106-8; View L-2: Pregnant 30 days. Intact uterus and ovaries. The vasculature in the left horn is increased over that of the right. The circumferential arteries are more prominent in the left uterine horn.

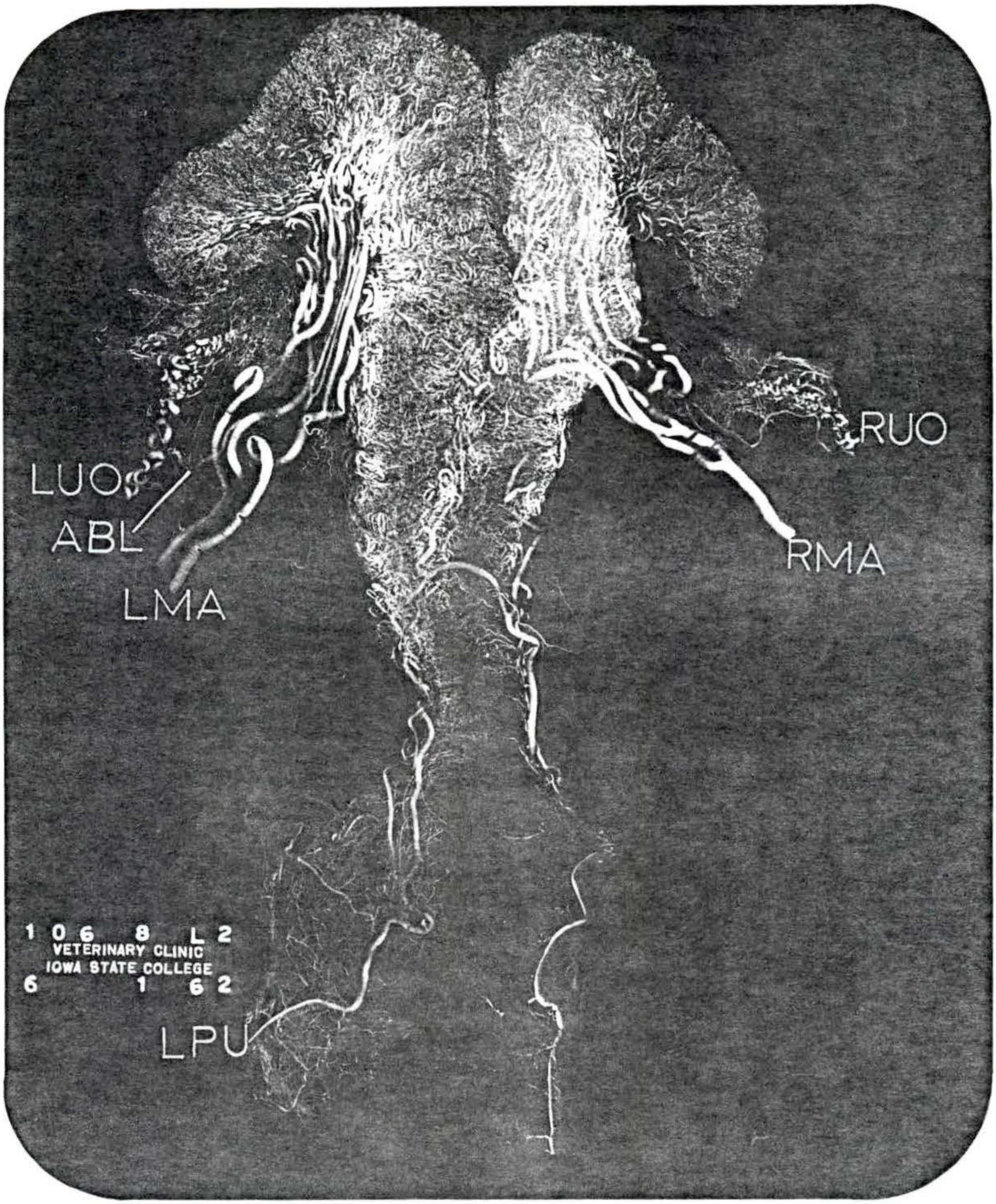
RUO
LUO
ABL
LMA
RMA
1 0 6 8 L 2
VETERINARY CLINIC
IOWA STATE COLLEGE
6 1 6 2
LPU

Figure 4. #106-8; View L-4: Pregnant 30 days. The dorsal (right) and ventral (left) halves of the uterus, and both sectioned ovaries. The separation of the uterus in half allows a better view of the individual vessels.

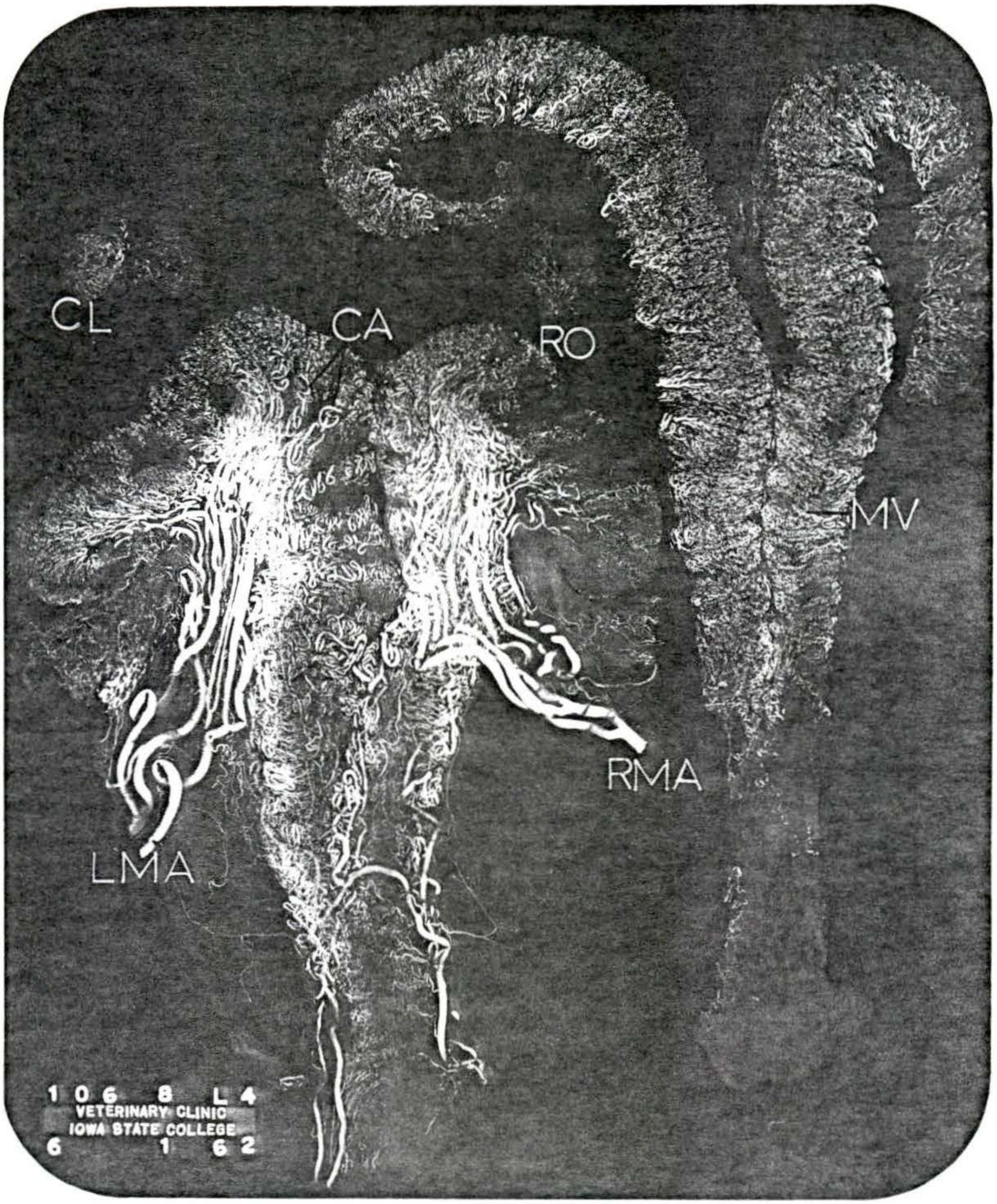
CL
CA
RO
MV
RMA
LMA
1 0 6 8 L 4
VETERINARY CLINIC
IOWA STATE COLLEGE
6 1 6 2

Figure 5. #106-9; View R-2: Pregnant 45 days. Intact uterus and ovaries. The vessels to the right uterine horn show some reduction in coiling.

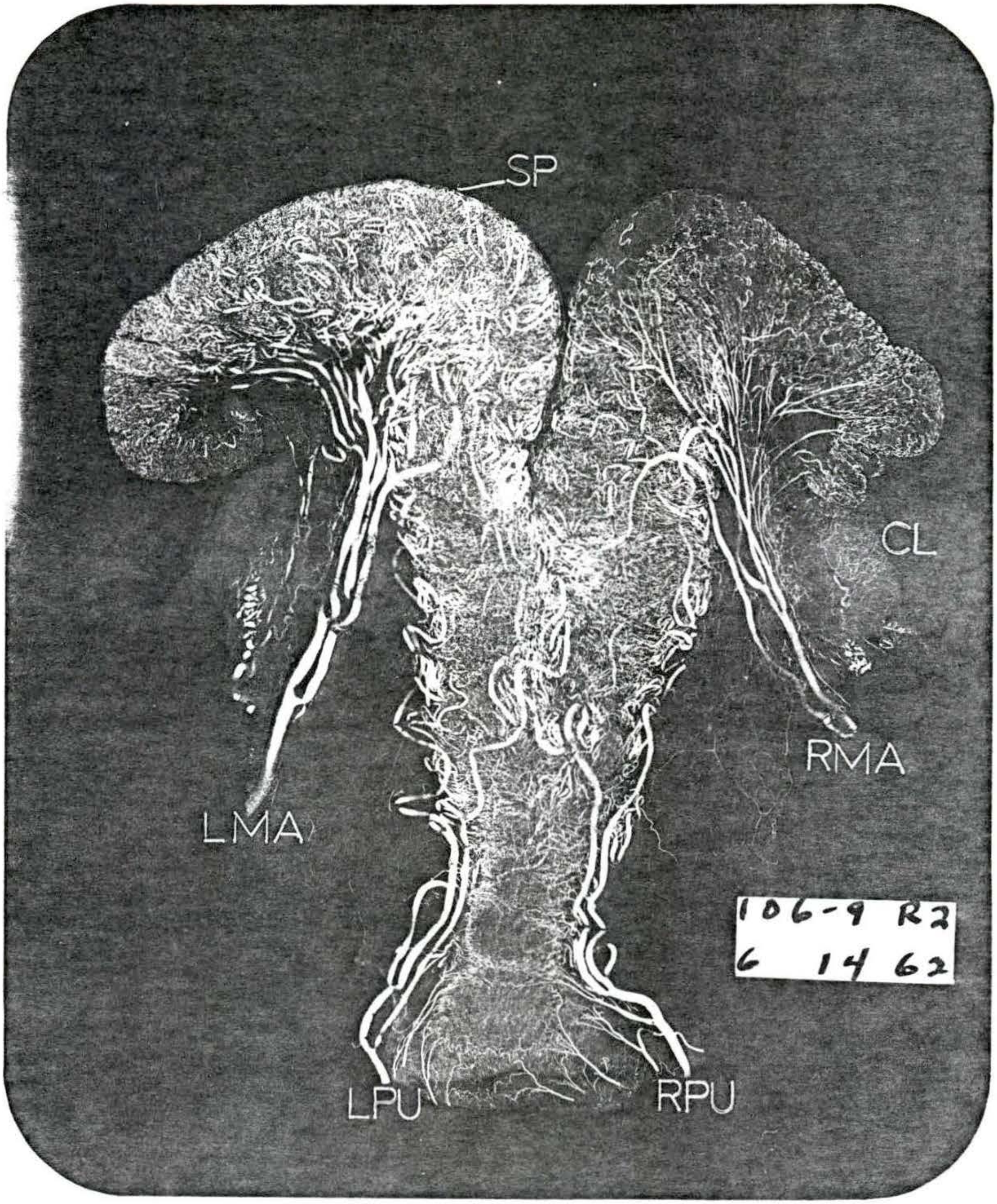
SP
CL
RMA
LMA
LPU
RPU
106-9 R2
6 14 62

Figure 6. #106-9; View R-3: Pregnant 45 days. The dorsal (left) and ventral (right) halves of the uterus, and both sectioned ovaries. The amniotic vesicle (outlined in black) is observed in the right uterine horn.


1 0 6 9 R 3
VETERINARY CLINIC
IOWA STATE COLLEGE
6 1 4 6 2
CA
LO
LMA
RMA
CL

Figure 7. #106-10; View L-1: Pregnant 60 days. Intact uterus and ovaries. The left uterine horn shows definite enlargement and increased blood supply with decreased coiling of the vessels.

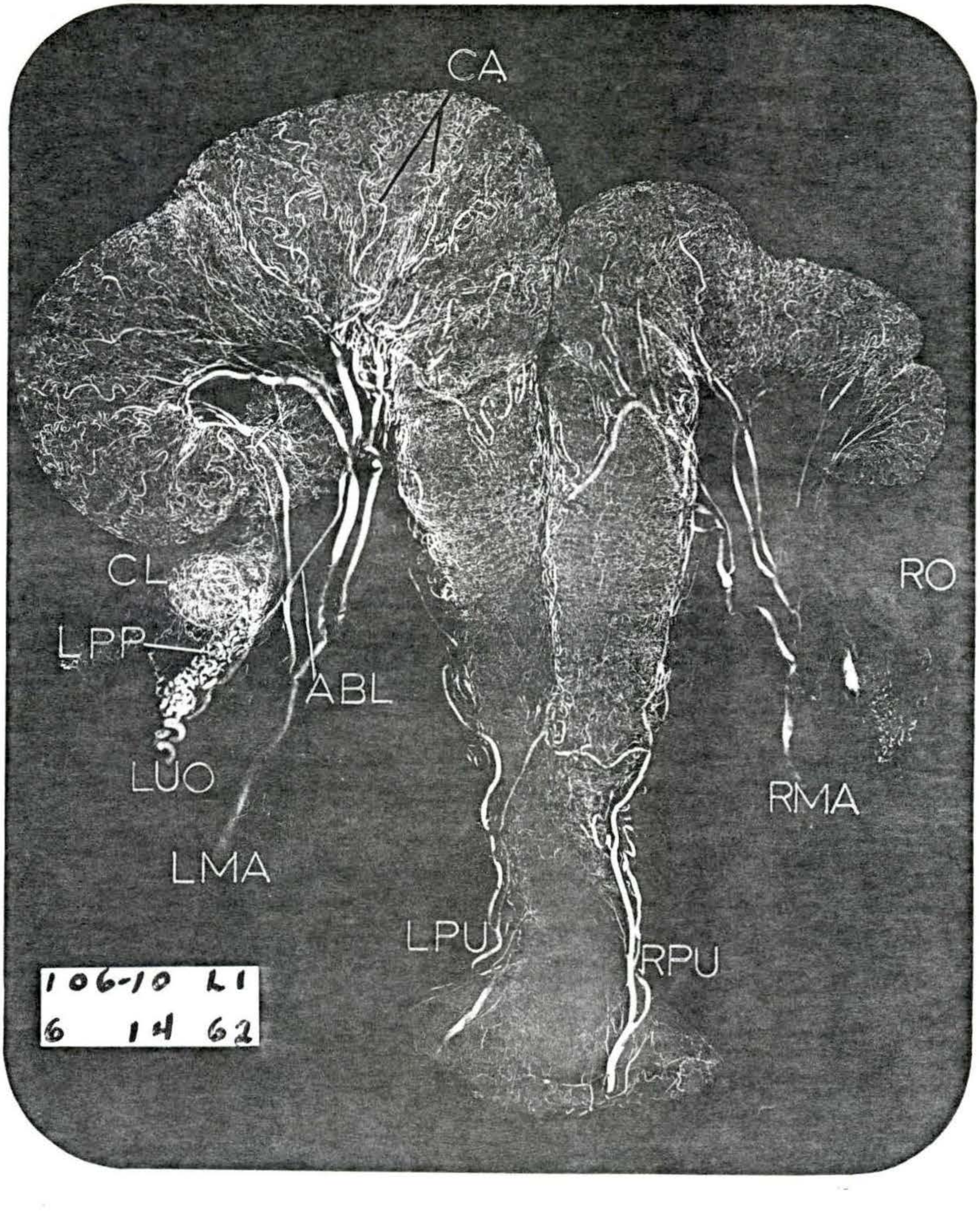
CA
CL
LPP
ABL
LUO
LMA
RO
RMA
LPU
RPU
106-10 L1
6 14 62

Figure 8. #106-10; View L-3: Pregnant 60 days. The ventral half of the uterus, fluid filled membranes, and both sectioned ovaries. The shadow of the fluid filled membranes is clearly evident with the amniotic vesicle outlined in black.

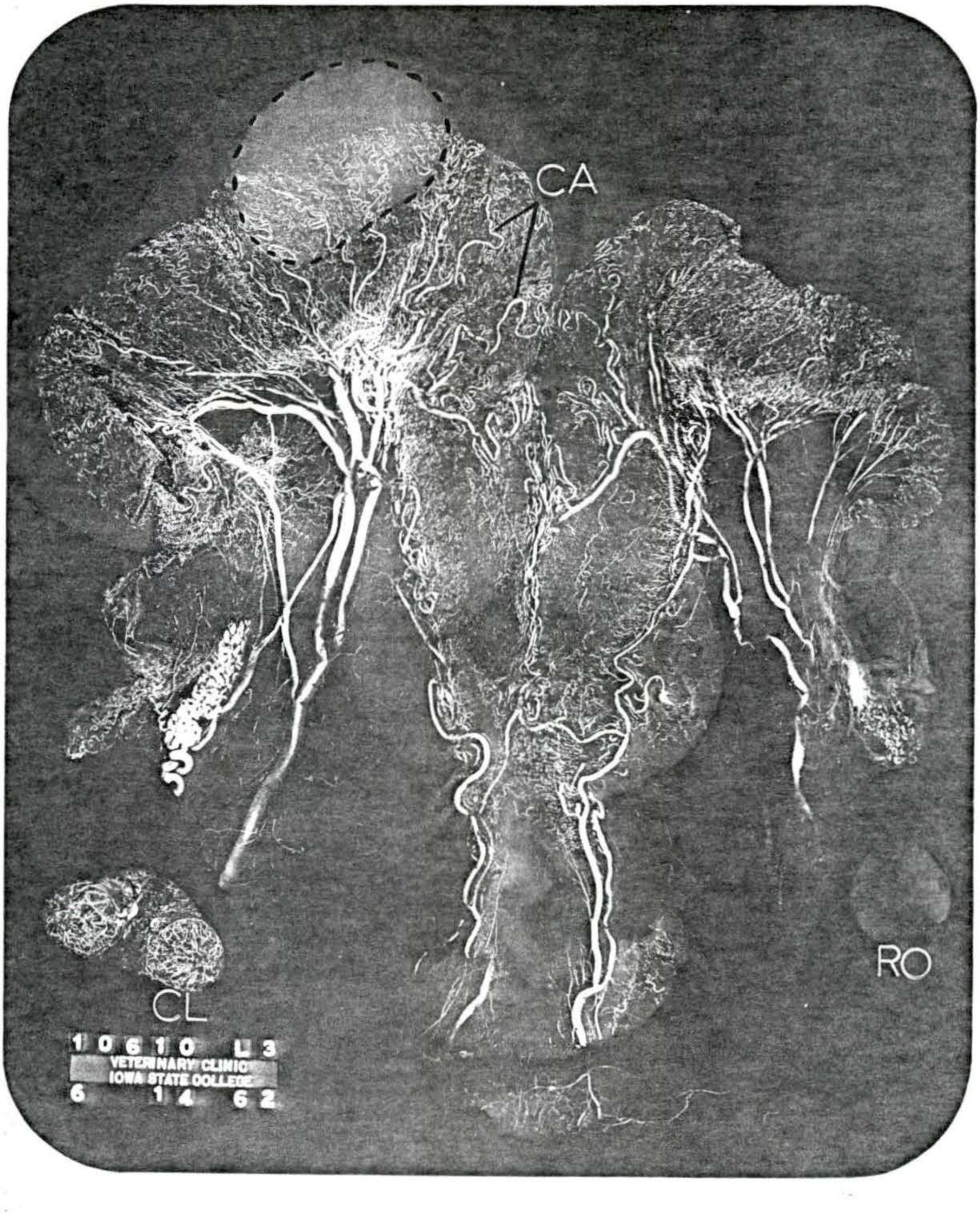
CA
CL
RO
1 0 6 1 0 L 3
VETERINARY CLINIC
IOWA STATE COLLEGE
6 14 62

Figure 9. #106-10; View L-5: Pregnant 60 days. The dorsal half of the uterus. This shows the detailed vascular architecture of the dorsal uterine wall only.

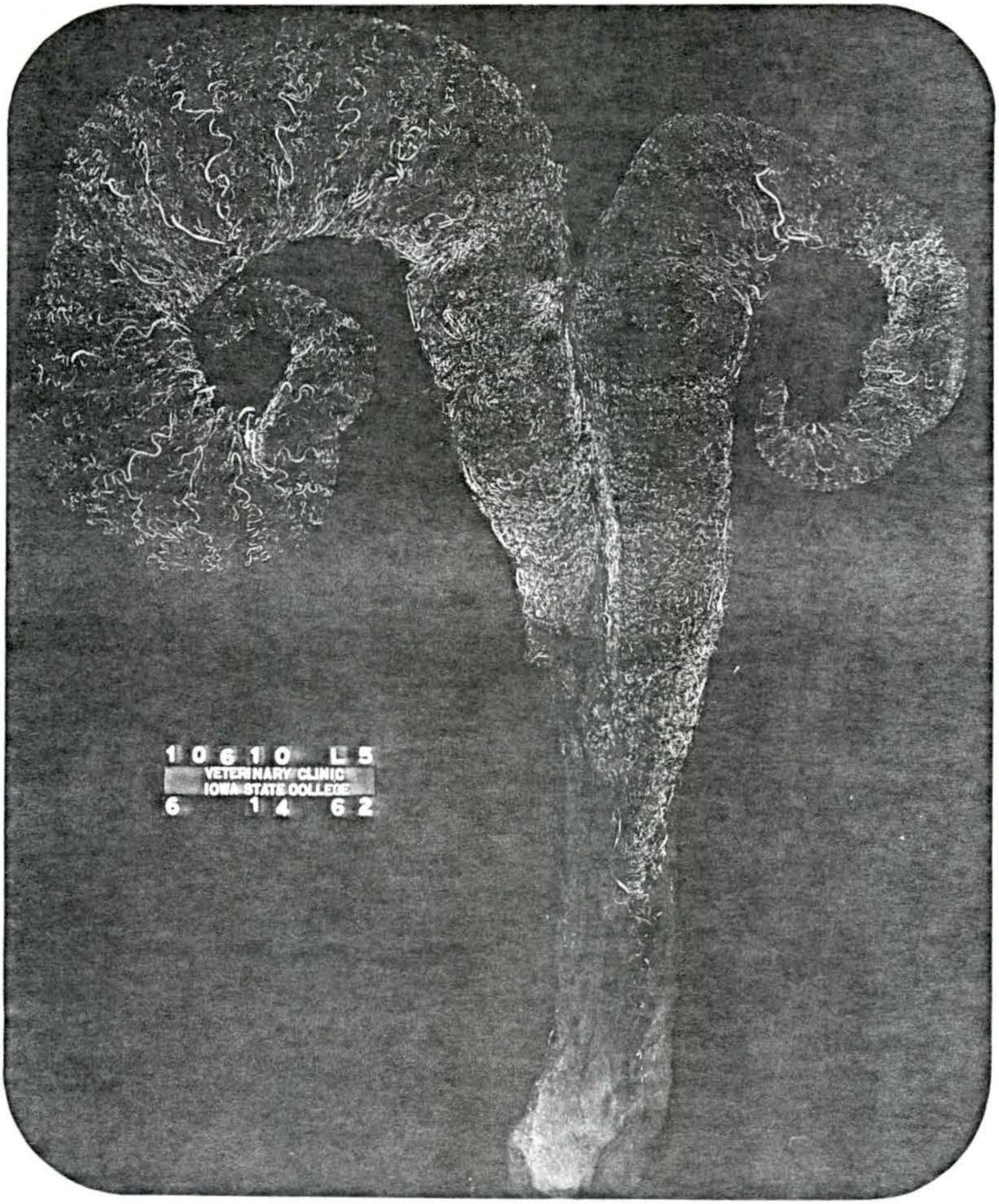
1 0 6 1 0 L 5
VETERINARY CLINIC
IOWA STATE COLLEGE
6 14 62

Figure 10. #106-12; View L-2: Pregnant 90 days. Intact uterus and ovaries. The left uterine horn shows evidence of distention with the vessels appearing almost straight. The fetal skeleton is faintly visible.

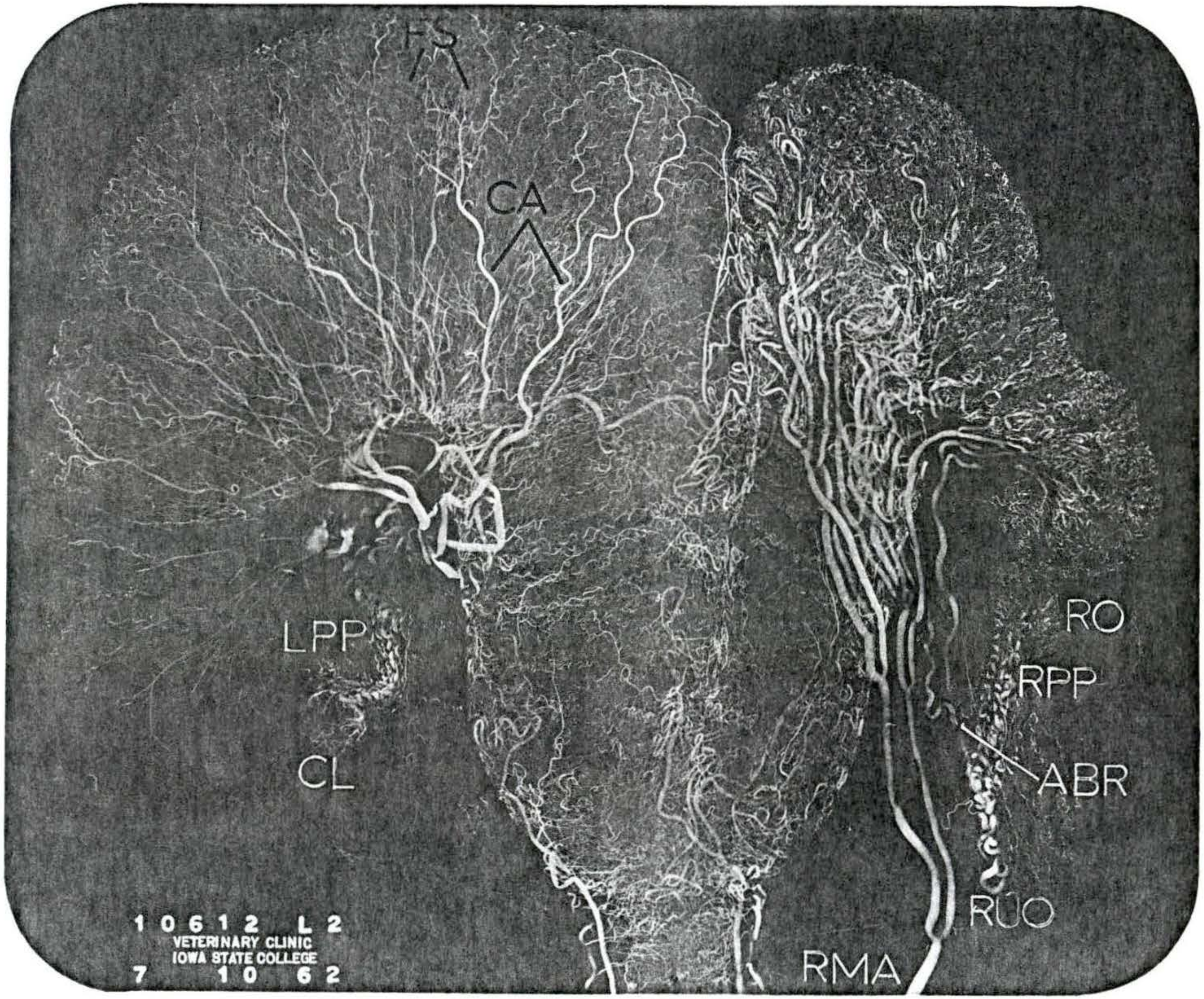
FS
CA
LPP
CL
RO
RPP
ABR
RUO
RMA
10612 L2
VETERINARY CLINIC
IOWA STATE COLLEGE
7 10 62

Figure 11. #106-12; View L-4: Pregnant 90 days. The ventral half of the uterus and both sectioned ovaries. The removal of the dorsal half of the uterus allows one to observe the beginning of the caruncular vasculature (outlined in black).

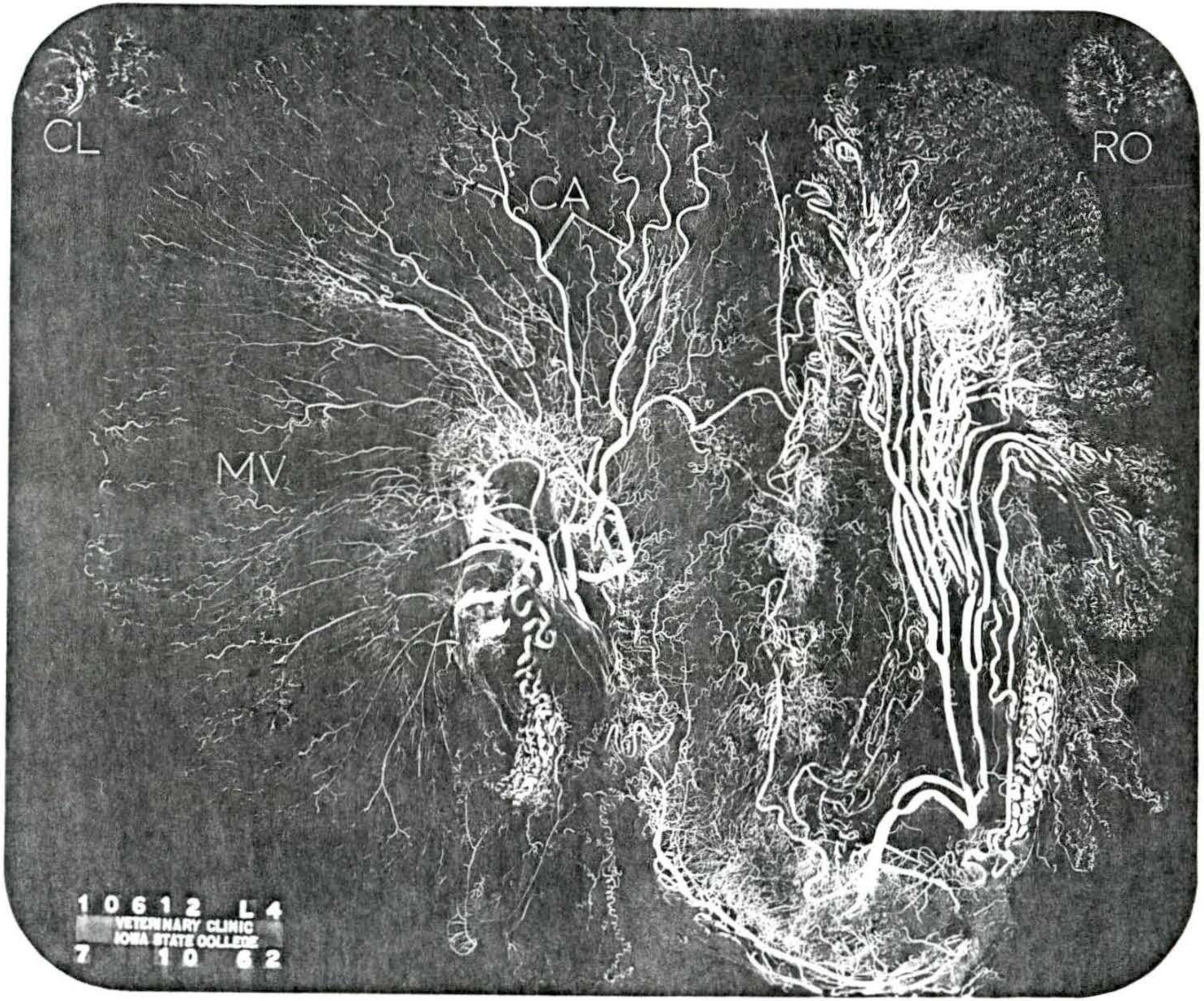
CL
RO
CA
MV
1 0 6 1 2 L 4
VETERINARY CLINIC
IOWA STATE COLLEGE
7 10 62

Figure 12. #106-14; View R-1: Pregnant 120 days. Intact right uterine horn and ovary. The pregnant horn shows increased vessel coiling over that of the previous specimen. The developing vasculature within the placentomes (outlined in black) can be noted. The fetal skeleton can be seen in the right horn.

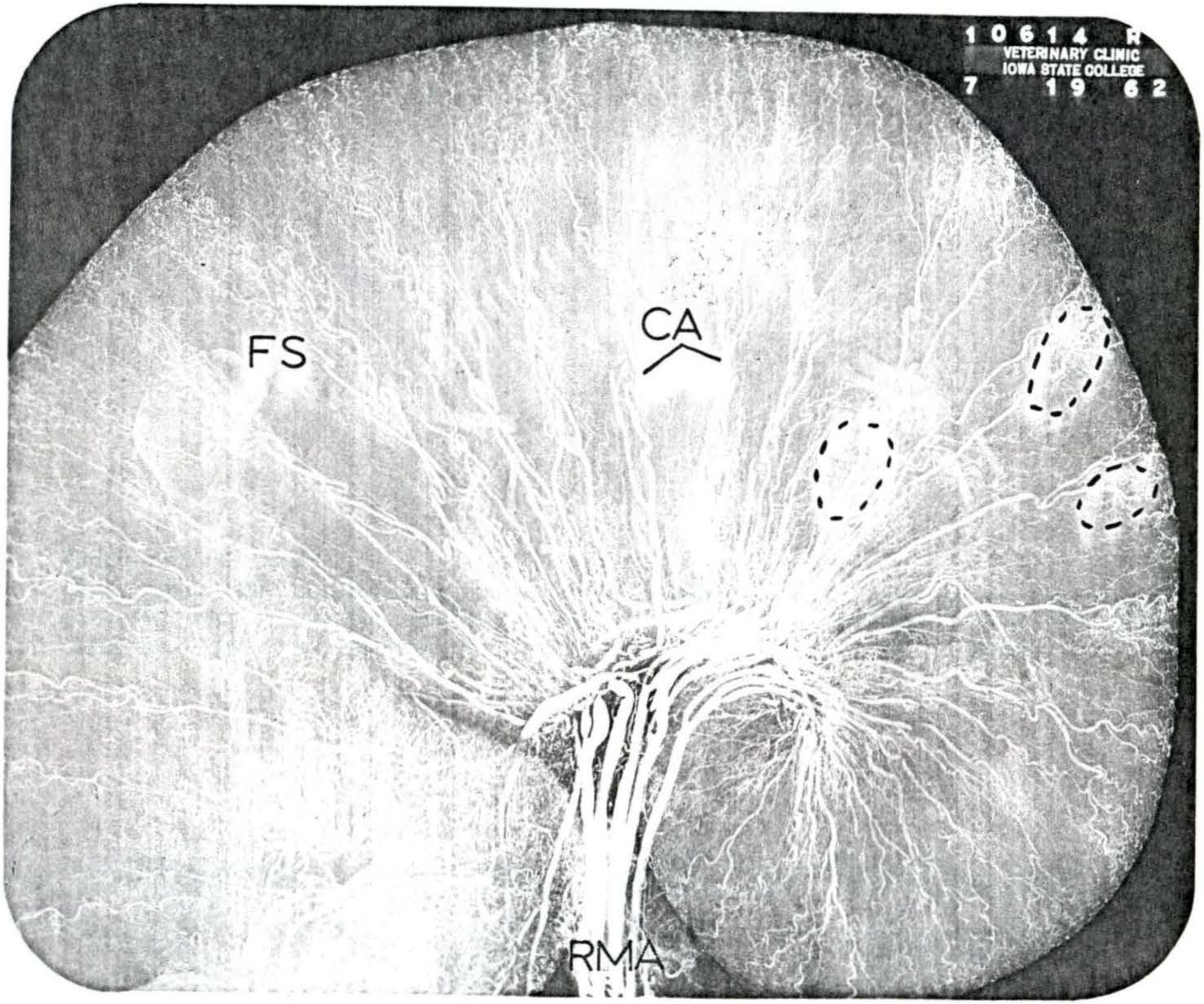
1 0 6 1 4 R
VETERINARY CLINIC
IOWA STATE COLLEGE
7 1 9 6 2
FS
CA
RMA

Figure 13. #106-14; View R-4: Pregnant 120 days. Intact apex of the non-pregnant left horn, ventral half of the body and right horn, and both ovaries. The non-pregnant horn still shows the coiled vasculature. The increased vessel size to the pregnant horn is very prominent.

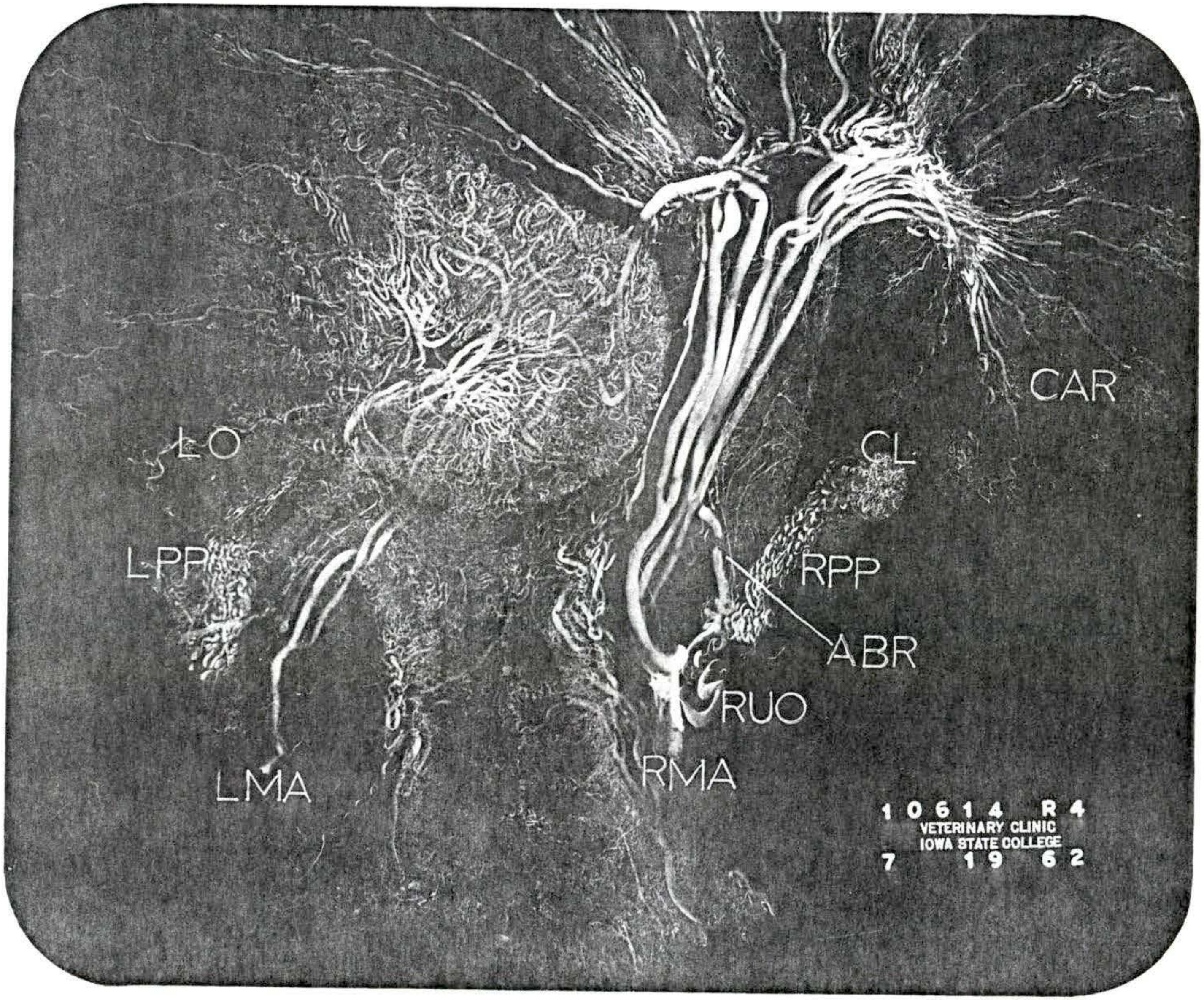
LO
LPP
LMA
RMA
RUO
ABR
RPP
CL
CAR
1 0 6 1 4 R 4
VETERINARY CLINIC
IOWA STATE COLLEGE
7 19 62

Figure 14. #106-14; View R-6: Pregnant 120 days. Dorsal half of the right uterine horn. The general vasculature to the uterus is very clearly defined. The black lines encircle the enlarging caruncles.

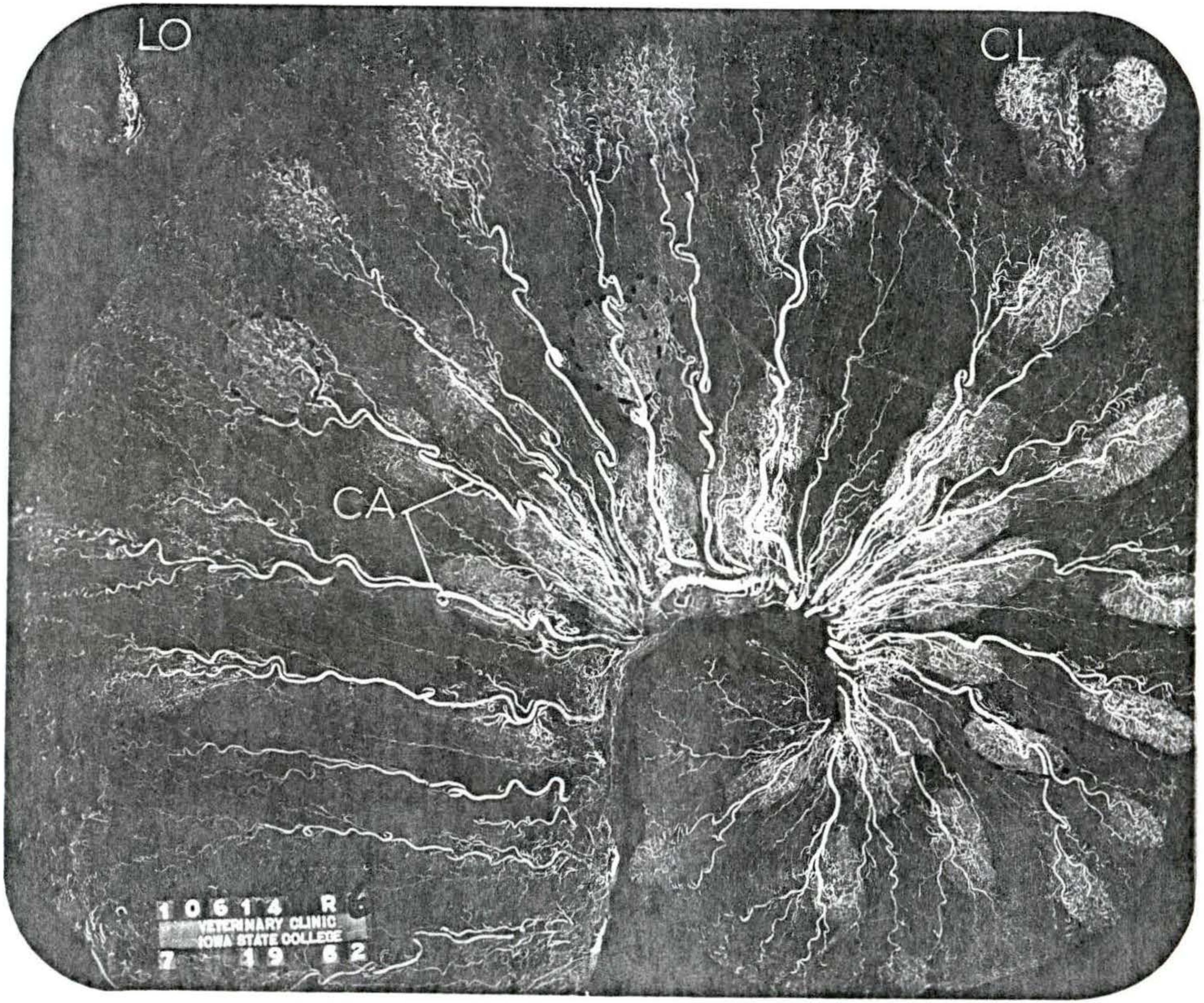
LO
CL
CA
10614 R
VETERINARY CLINIC
IOWA STATE COLLEGE
7 19 62

Figure 15. #106-18; View L-1: Pregnant 150 days. Intact apex of the left uterine horn and ovary with the fetus and fluids removed. The developing vasculature in the caruncles have a radiating appearance. The circumferential vessels are very straight when compared to the previous specimens.

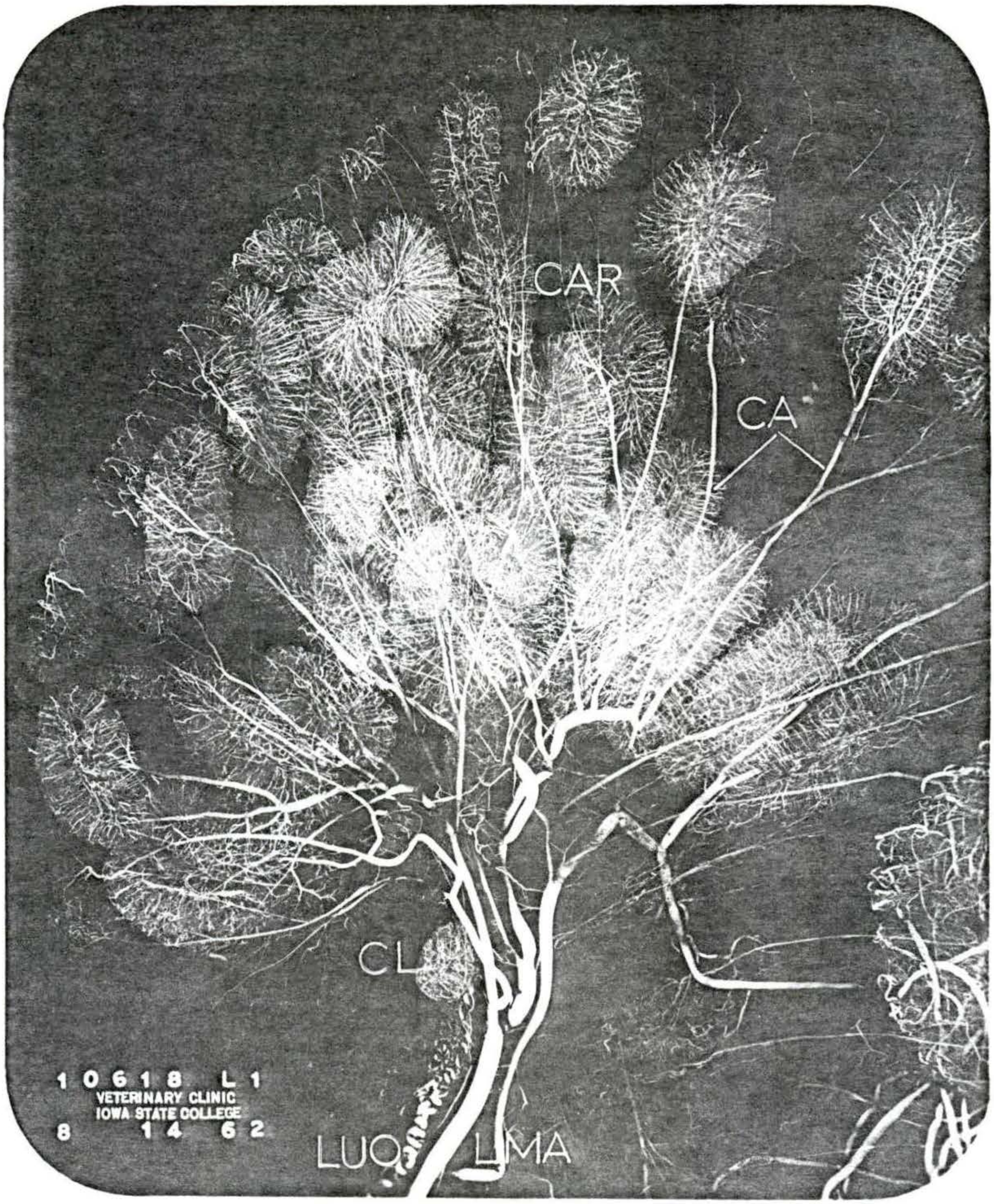
CAR
CA
CL
1 0 6 1 8 L 1
VETERINARY CLINIC
IOWA STATE COLLEGE
8 14 62
LUO
LMA

Figure 16. #106-18; View L-5: Pregnant 150 days. The junction of the ventral and dorsal halves of the pregnant uterine horn at the greater curvature. Observe the detail vasculature in the caruncles and the fine anastomosing vessels in the intercaruncular spaces of the myometrium across the greater curvature of the uterus.

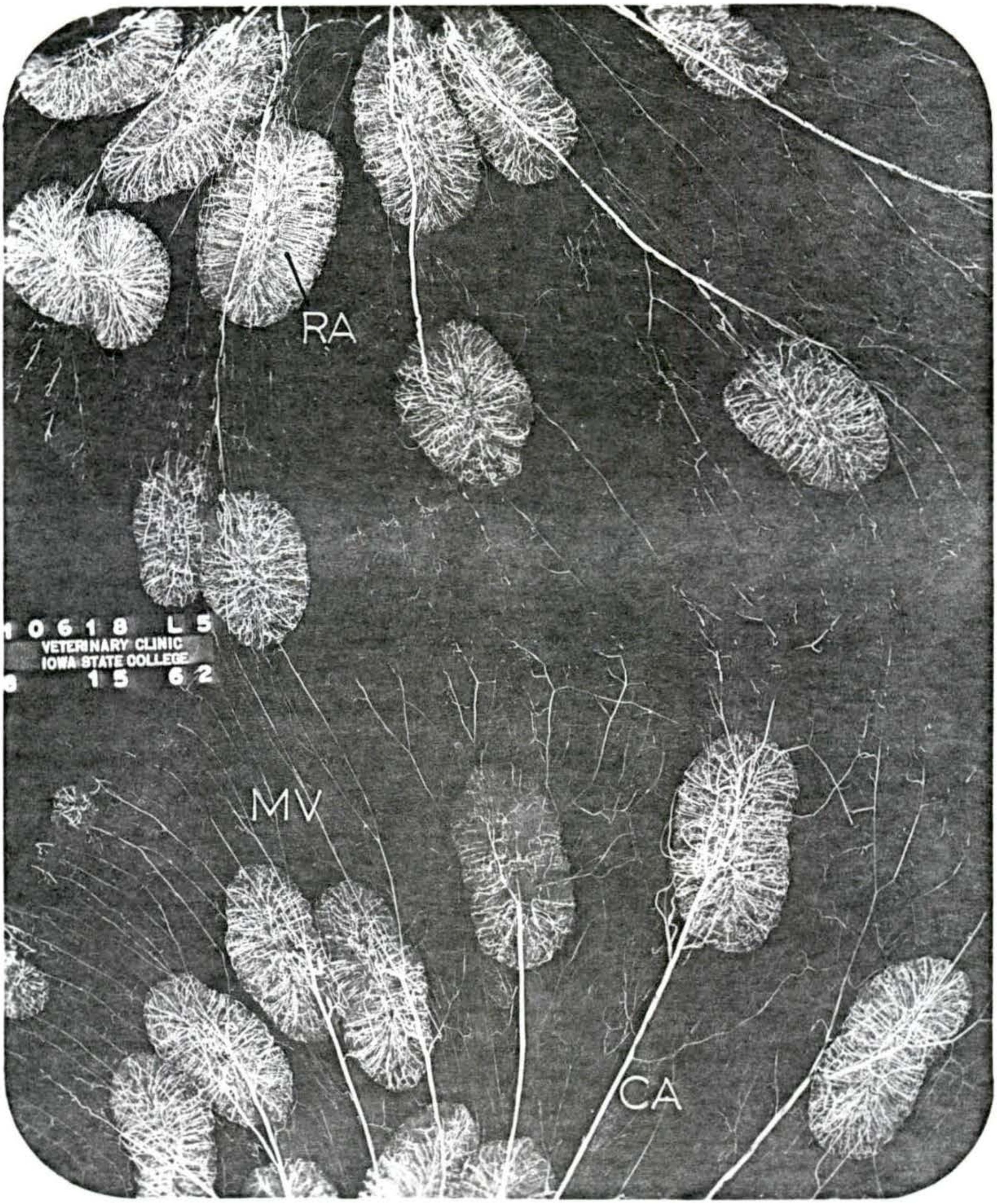
RA
0618 L5
VETERINARY CLINIC
IOWA STATE COLLEGE
15 62
MV
CA

Figure 17. #106-18; View L-7: Pregnant 150 days. Dorsal half of the apex of the non-pregnant right horn, four sectioned caruncles, and sectioned ovaries. The caruncles show the vessels entering their base through the stalk and the radiating arteries within the caruncular tissue. The apex of the non-pregnant horn still contains coiled vessels.

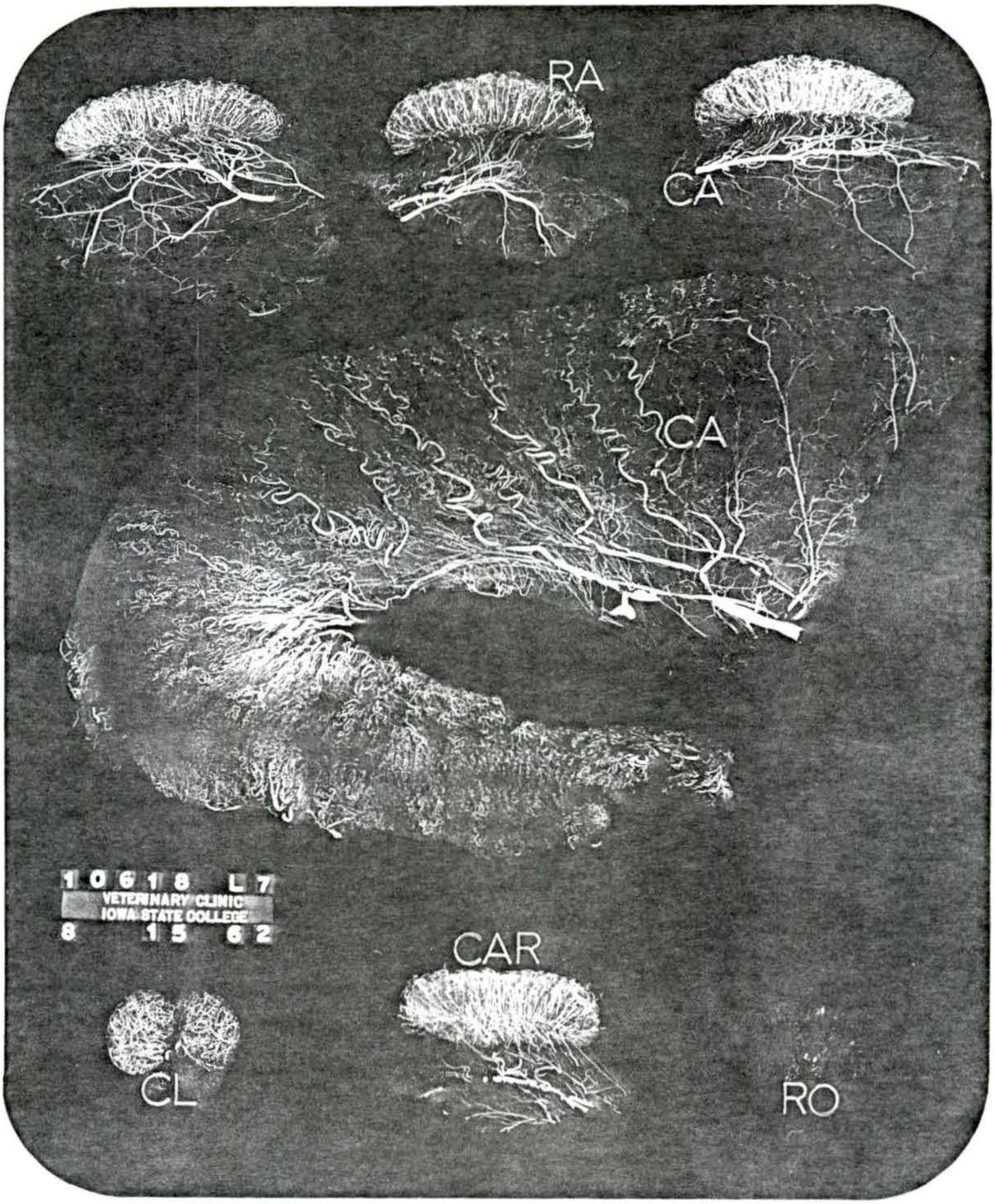
RA
CA
CA
1 0 6 1 8 L 7
VETERINARY CLINIC
IOWA STATE COLLEGE
8 15 62
CAR
CL
RO

Figure 18. #106-16; View R-1: Pregnant 181 days. Intact apex of the right uterine horn and ovary with the fetus and fluids removed. Observe the rapidly developing caruncular vasculature.

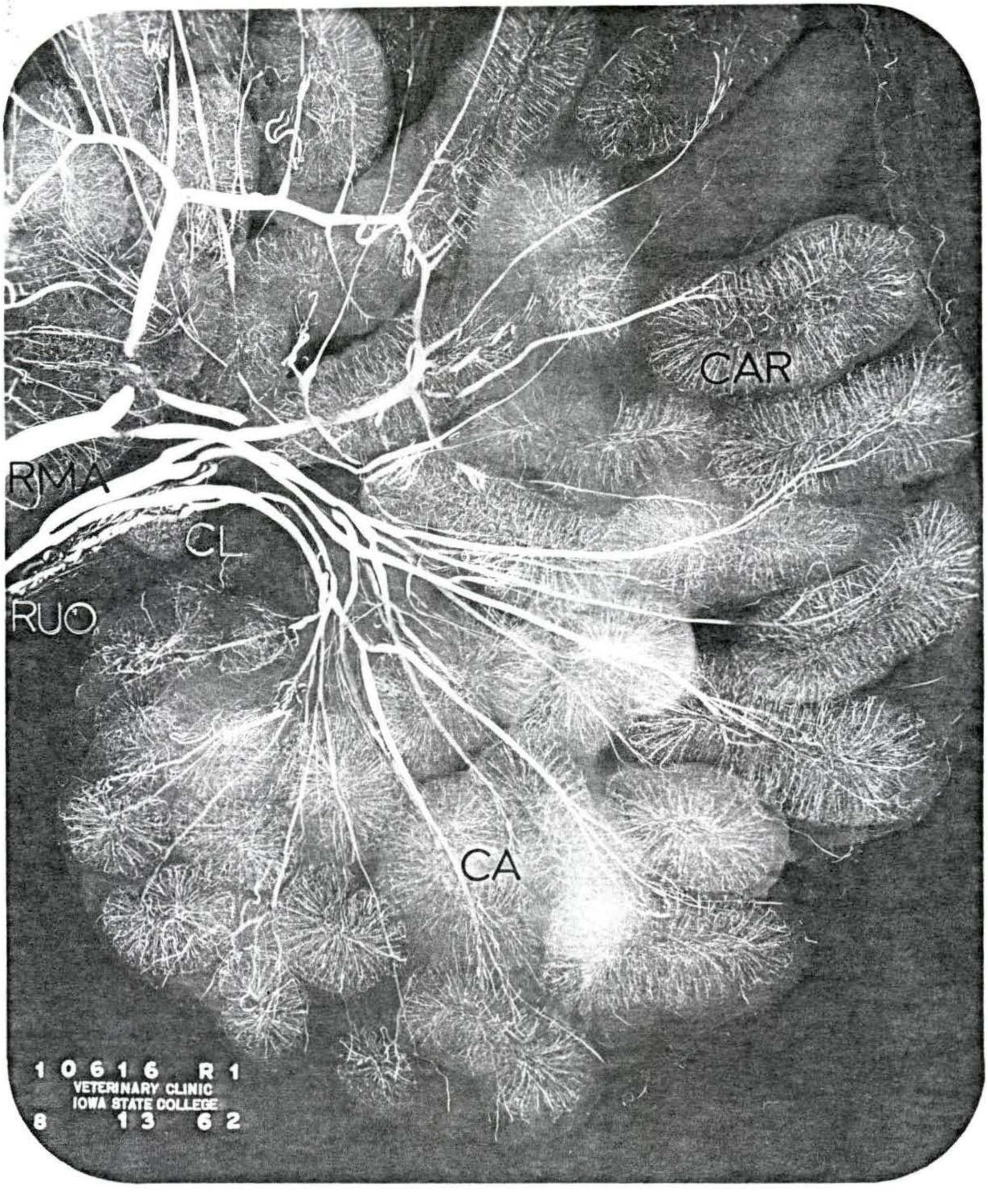
CAR
RMA
CL
RUO
CA
1 0 6 1 6 R 1
VETERINARY CLINIC
IOWA STATE COLLEGE
8 1 3 6 2

Figure 19. #106-16; View R-7: Pregnant 181 days. Ventral half of the apex of the non-pregnant left horn, four sectioned caruncles, and sectioned ovaries. The apex of the non-pregnant horn is showing signs of distention as evidenced by the straightened vessels.

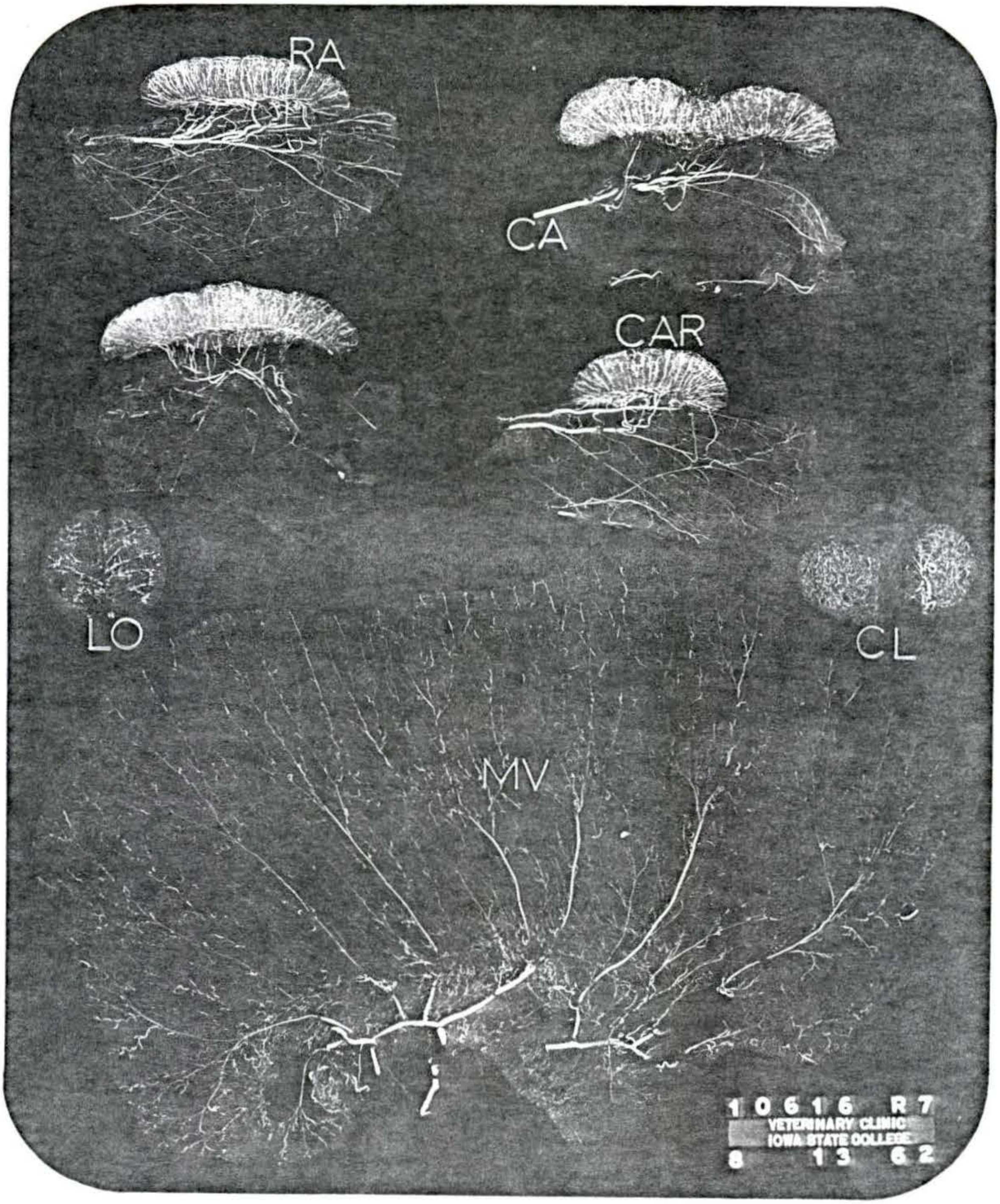
RA
CA
CAR
LO
CL
MV
1 0 6 1 6 R 7
VETERINARY CLINIC
IOWA STATE COLLEGE
8 13 62

Figure 20. #106-15; View R-2: Pregnant 210 days. Intact apex of the right uterine horn, uterine body, and right ovary with the fetus and fluids removed. This shows the two branches of the right middle uterine artery which supplied the right horn of this uterus.

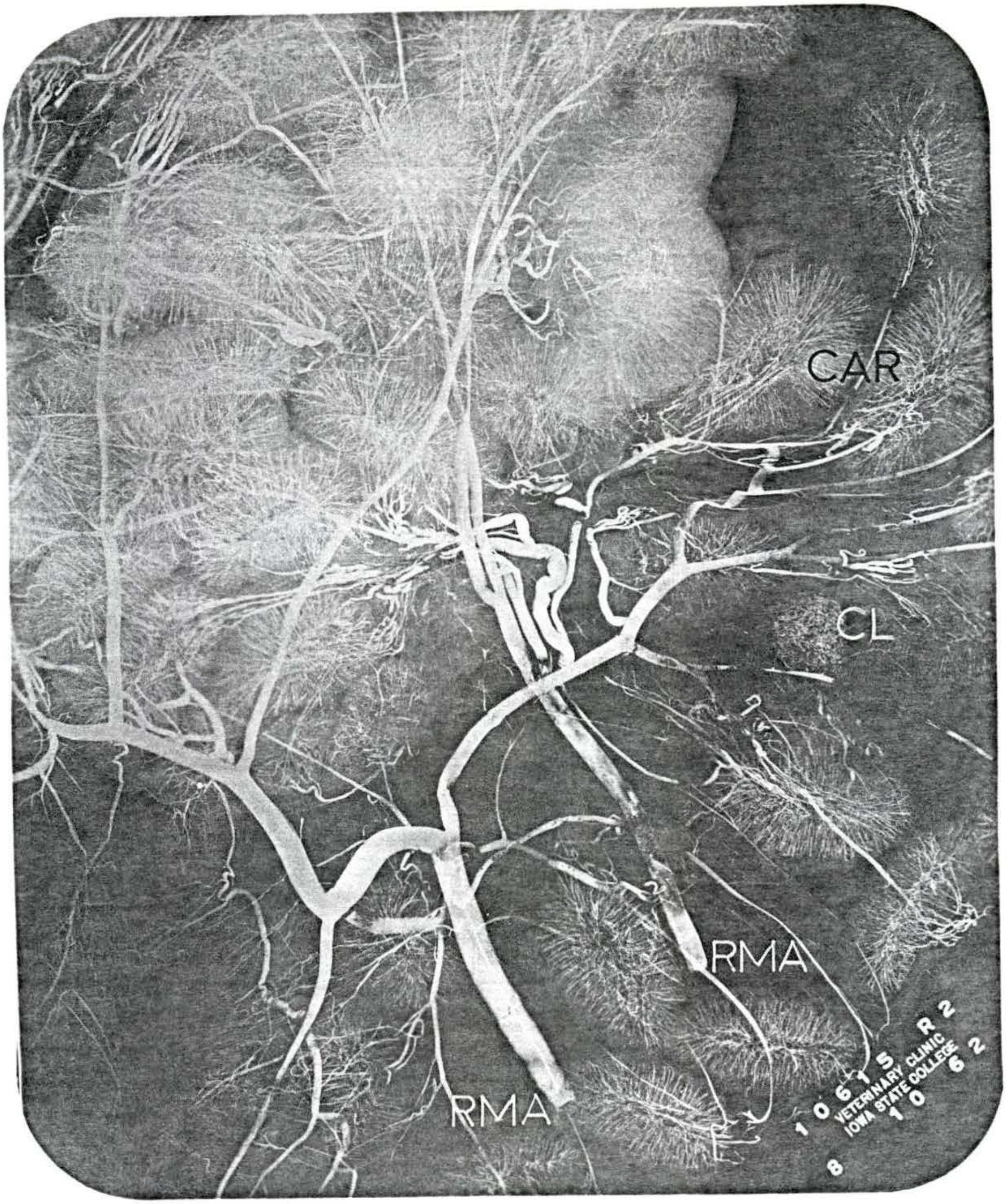
CAR
CL
RMA
RMA
1 0 6 1 5 R 2
VETERINARY CLINIC
IOWA STATE COLLEGE
8 1 0 6 2

Figure 21. #106-15; View R-6: Pregnant 210 days. Ventral apex of the right horn and both ovaries. Notice the basal plexus and radiate arteries in the caruncles.

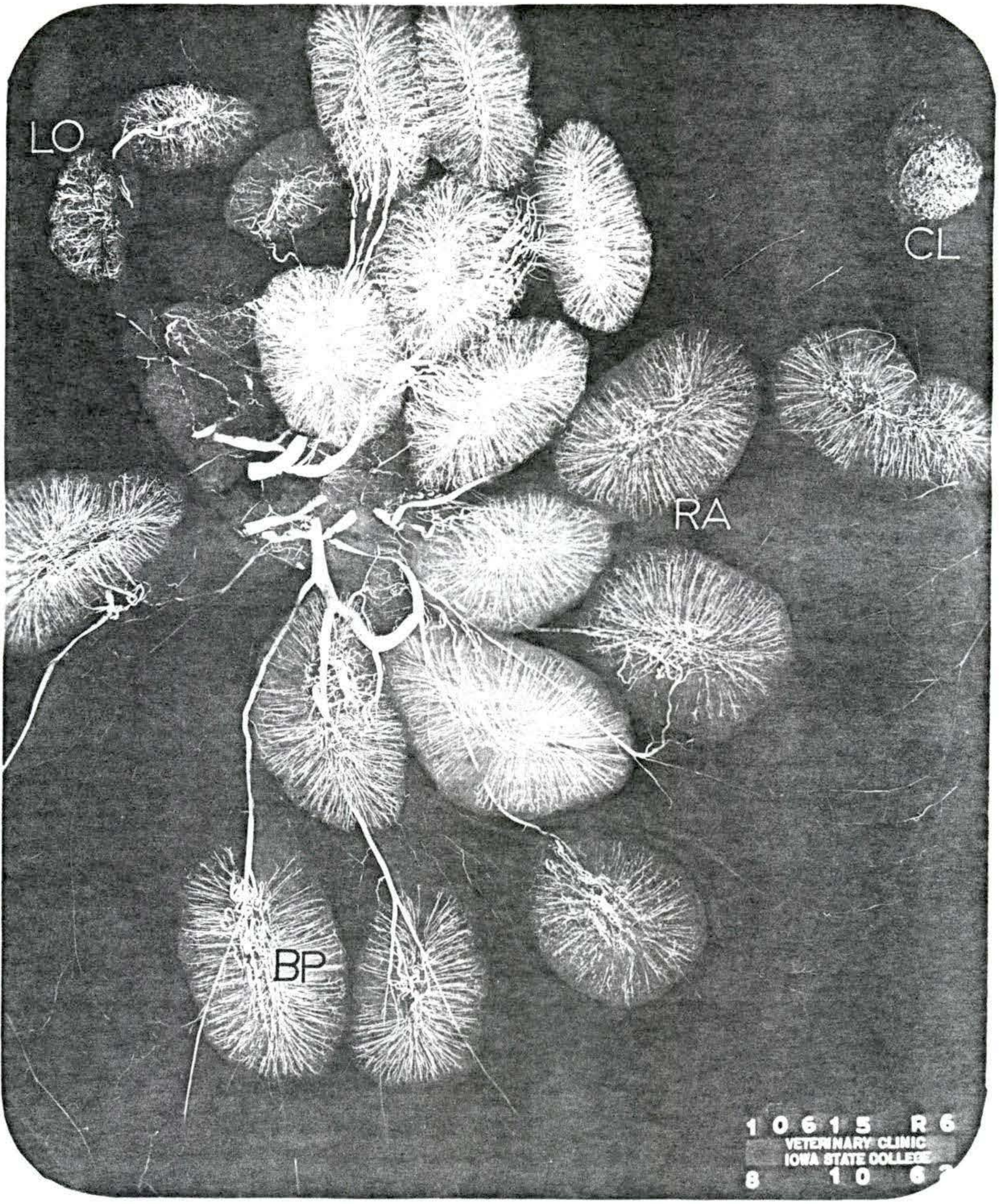
LO
CL
RA
BP
10615 R6
VETERINARY CLINIC
IOWA STATE COLLEGE
8 10 6

Figure 22. #106-15; View R-8: Pregnant 210 days. Ventral half of the cervix, four sectioned caruncles, and sectioned ovaries. The caruncles show the basal plexus with the arteries radiating out from it into the caruncular tissue.

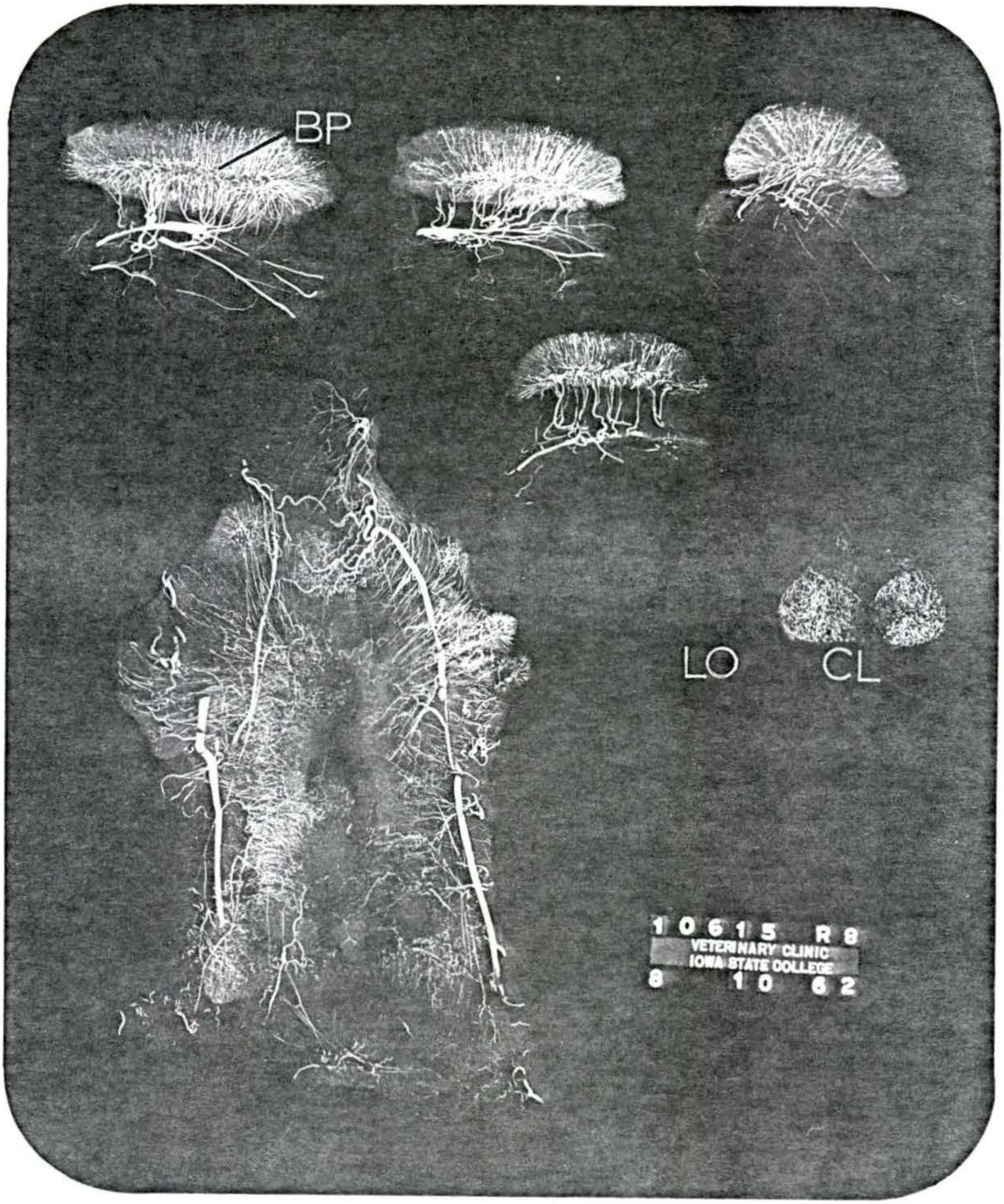
BP
LO
CL
1 0 6 1 5 R 8
VETERINARY CLINIC
IOWA STATE COLLEGE
8 1 0 6 2

Figure 23. #106-13; View R-1: Pregnant 241 days. Intact apex of the right uterine horn and ovary with the fetus and fluids removed. Observe the extensive development of the uterine and caruncular vasculature.

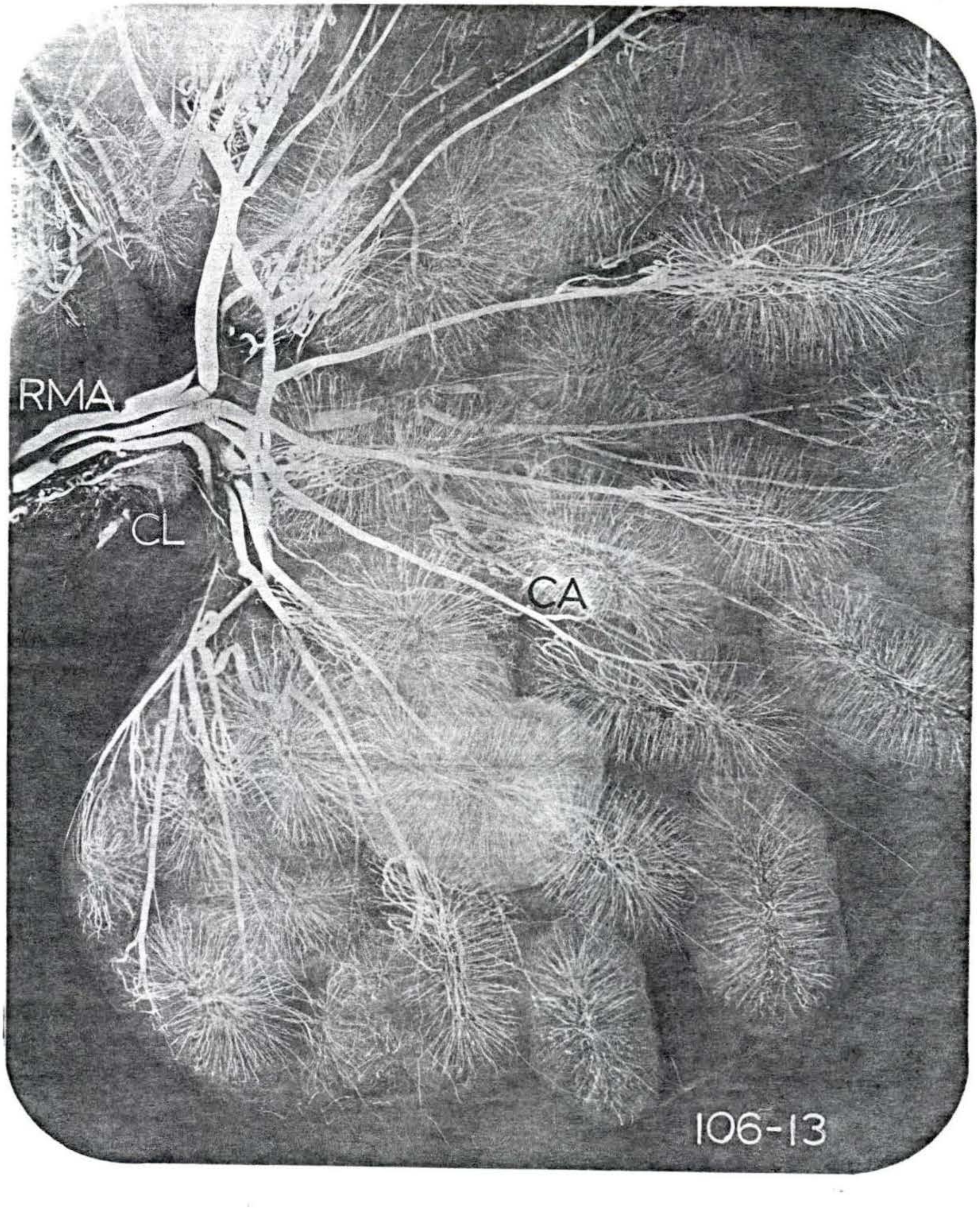
RMA
CL
CA
106-13

Figure 24. #106-13; View R-6: Pregnant 241 days. Dorsal half of the apex of the non-pregnant left uterine horn and three caruncles. The caruncles show the basal plexus and radiate arteries with their fine lateral branchings. The apex of the non-pregnant horn shows signs of vessel coiling.

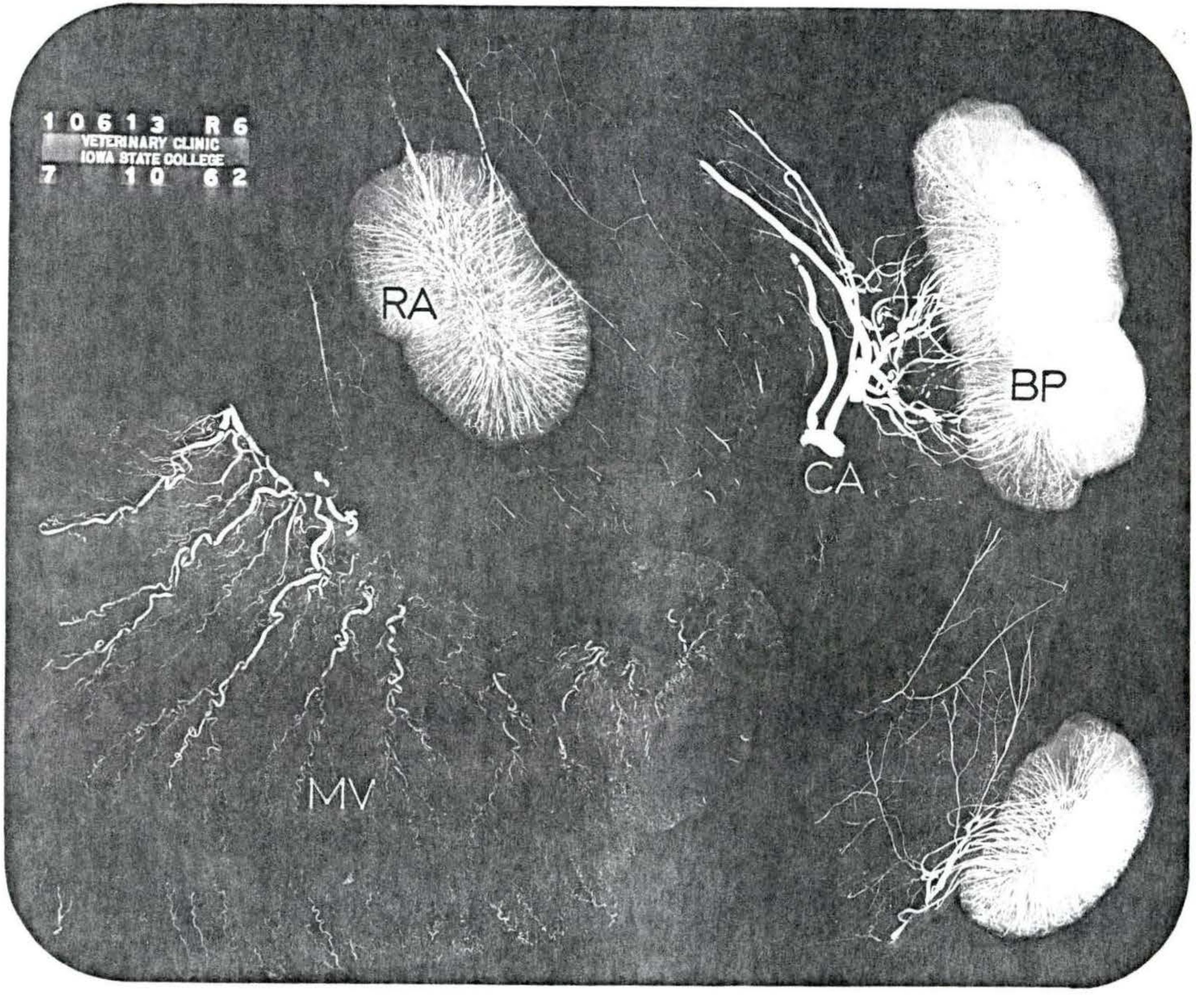
1 0 6 1 3 R 6
VETERINARY CLINIC
IOWA STATE COLLEGE
7 10 62
RA
CA
BP
MV

Figure 25. #106-13; View R-7: Pregnant 241 days. Both sectioned ovaries and three sectioned caruncles. The caruncle in the upper right shows two separate blood supplies. Again note the basal plexus and radiate arteries.

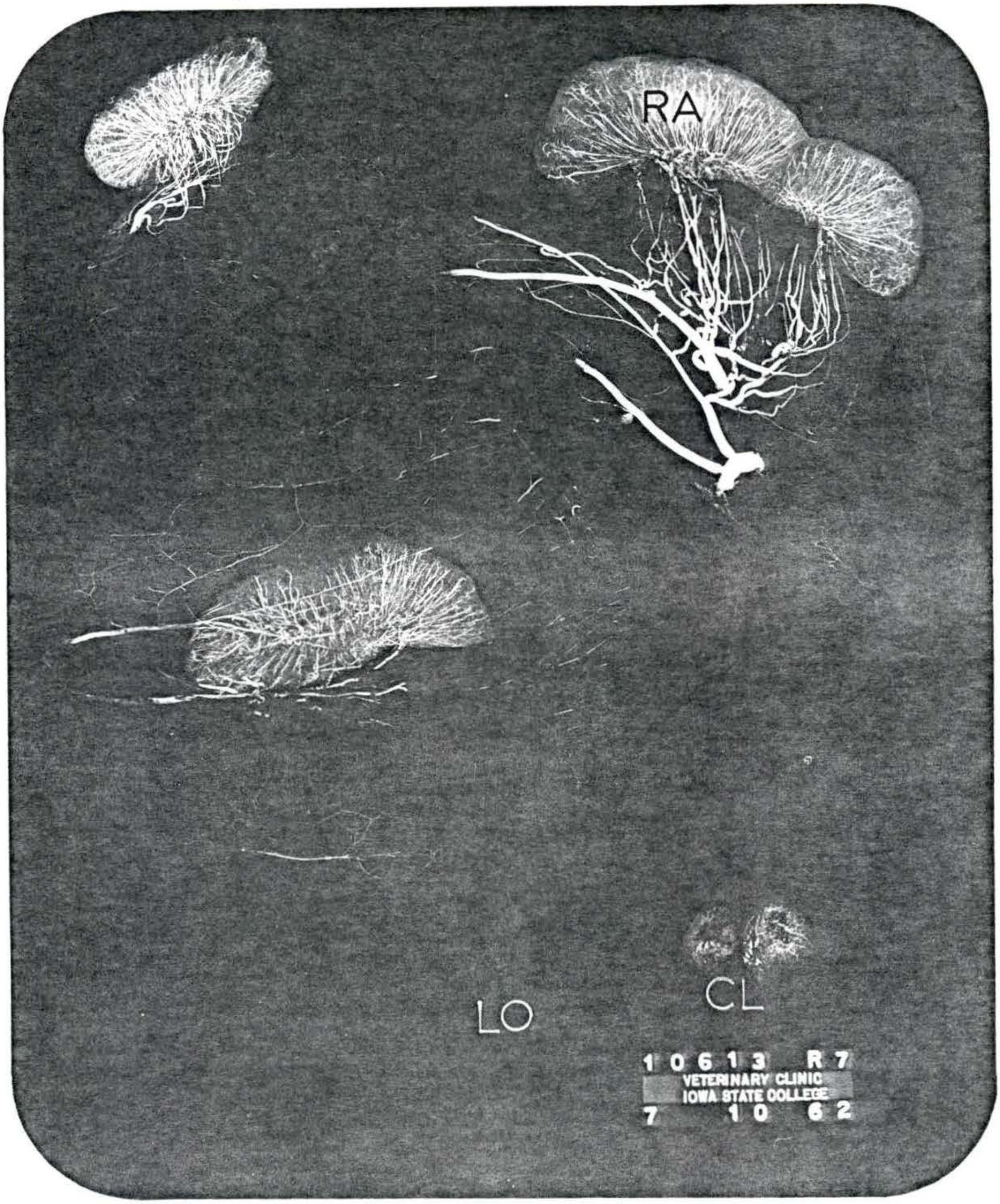
RA
LO
CL
1 0 6 1 3 R 7
VETERINARY CLINIC
IOWA STATE COLLEGE
7 10 62

Figure 26. #106-11; View L-1: Pregnant 273 days. Intact apex of the left uterine horn and ovary with the fetus and fluids removed. The caruncles show a greatly increased vasculature. The lateral branching from the radiate arteries is very extensive. The anastomotic branch from the left utero-ovarian artery to a branch of the left middle uterine artery is very distinct.

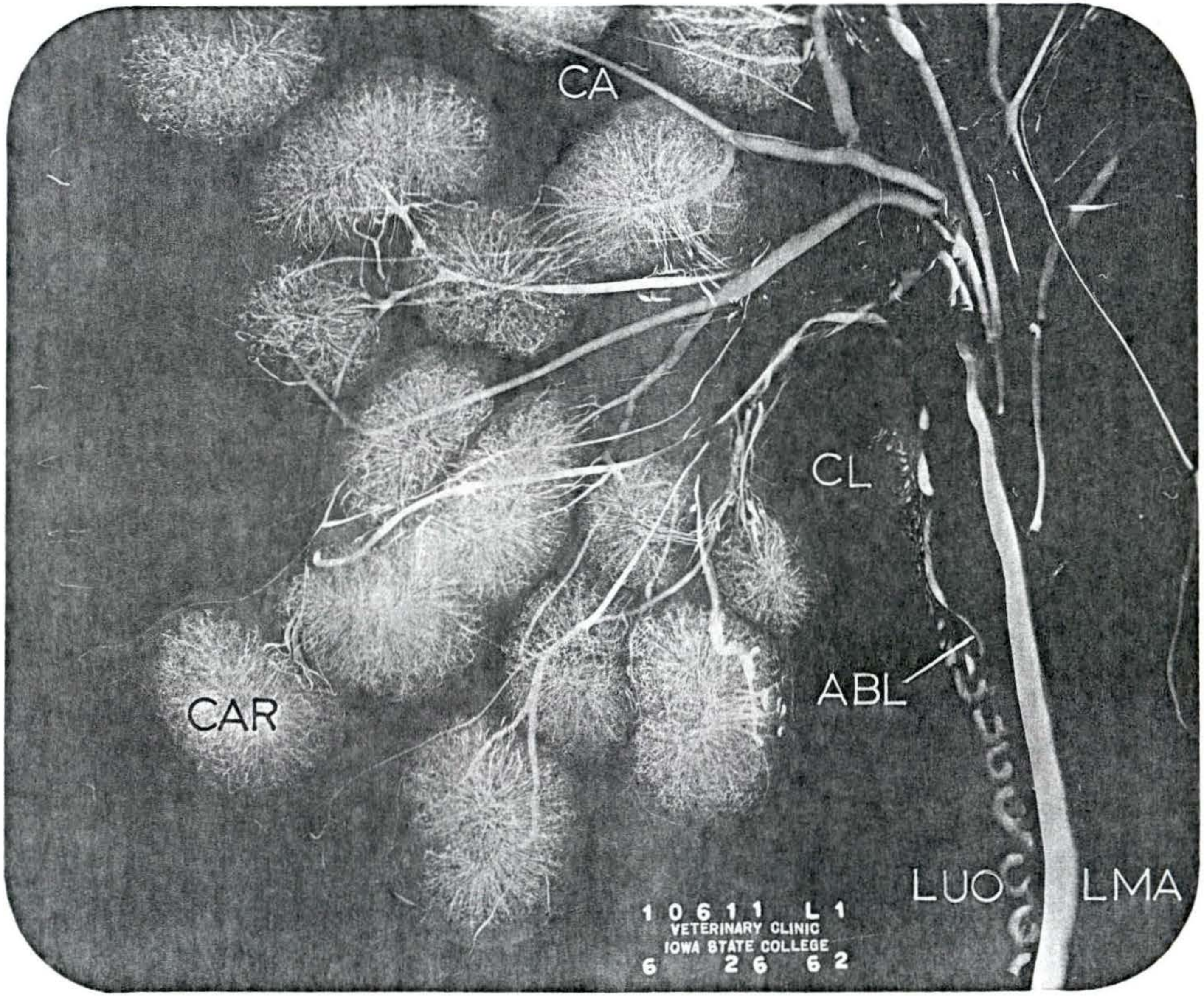
CA
CL
ABL
CAR
LUO
LMA
10611 L1
VETERINARY CLINIC
IOWA STATE COLLEGE
6 26 62

Figure 27. #106-11; View 1-6: Pregnant 273 days. The junction of the ventral and dorsal halves of the pregnant uterine horn at the greater curvature (section near the uterine body). This area of the uterine horn was completely devoid of caruncles. Observe the general vasculature in the myometrium.

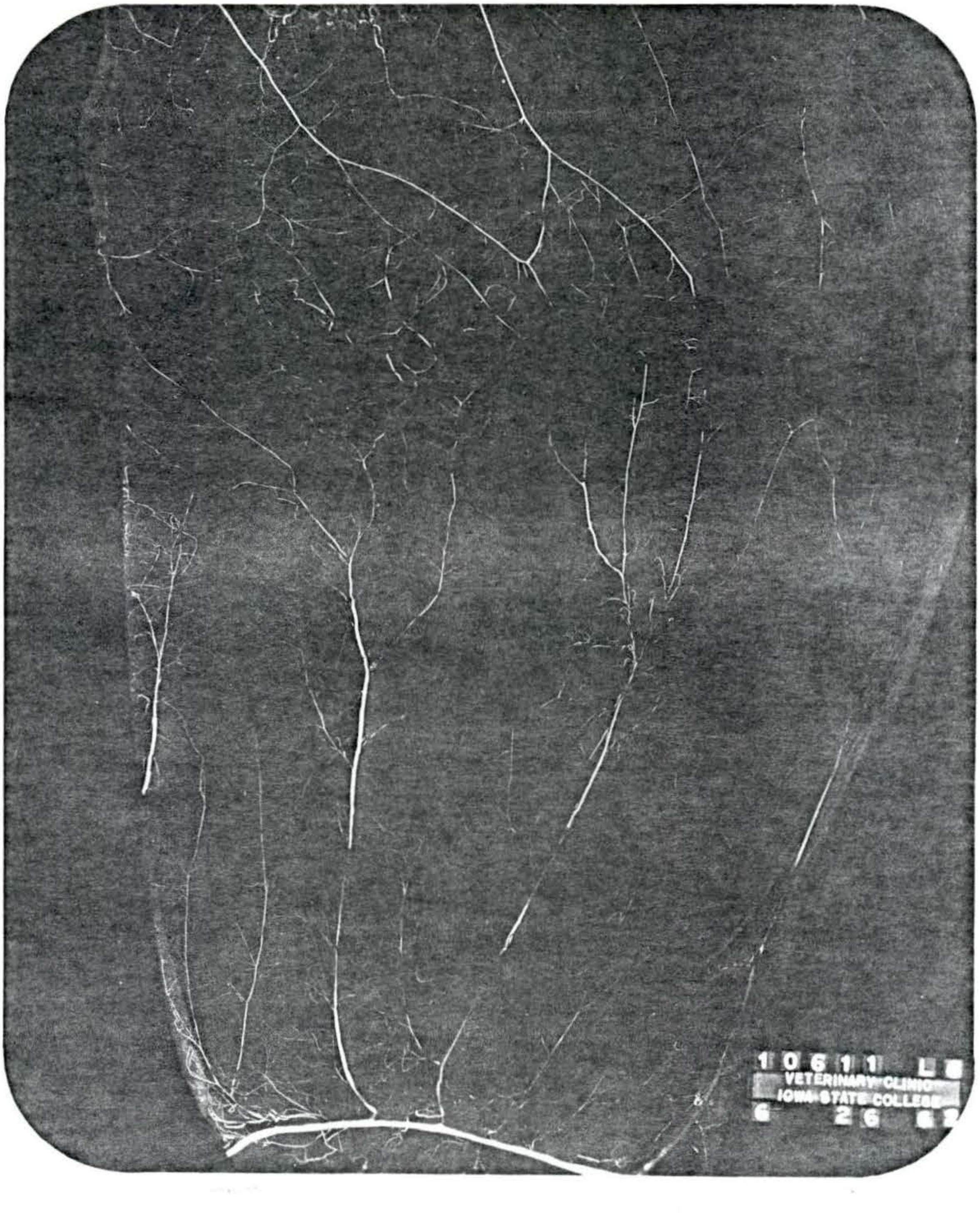
10611 L
VETERINARY CLINIC
IOWA STATE COLLEGE
6 26 62

Figure 28. #106-11; View L-7: Pregnant 273 days. Both sectioned ovaries and two sectioned caruncles. Observe the very dense network of vessels within the caruncular tissue.

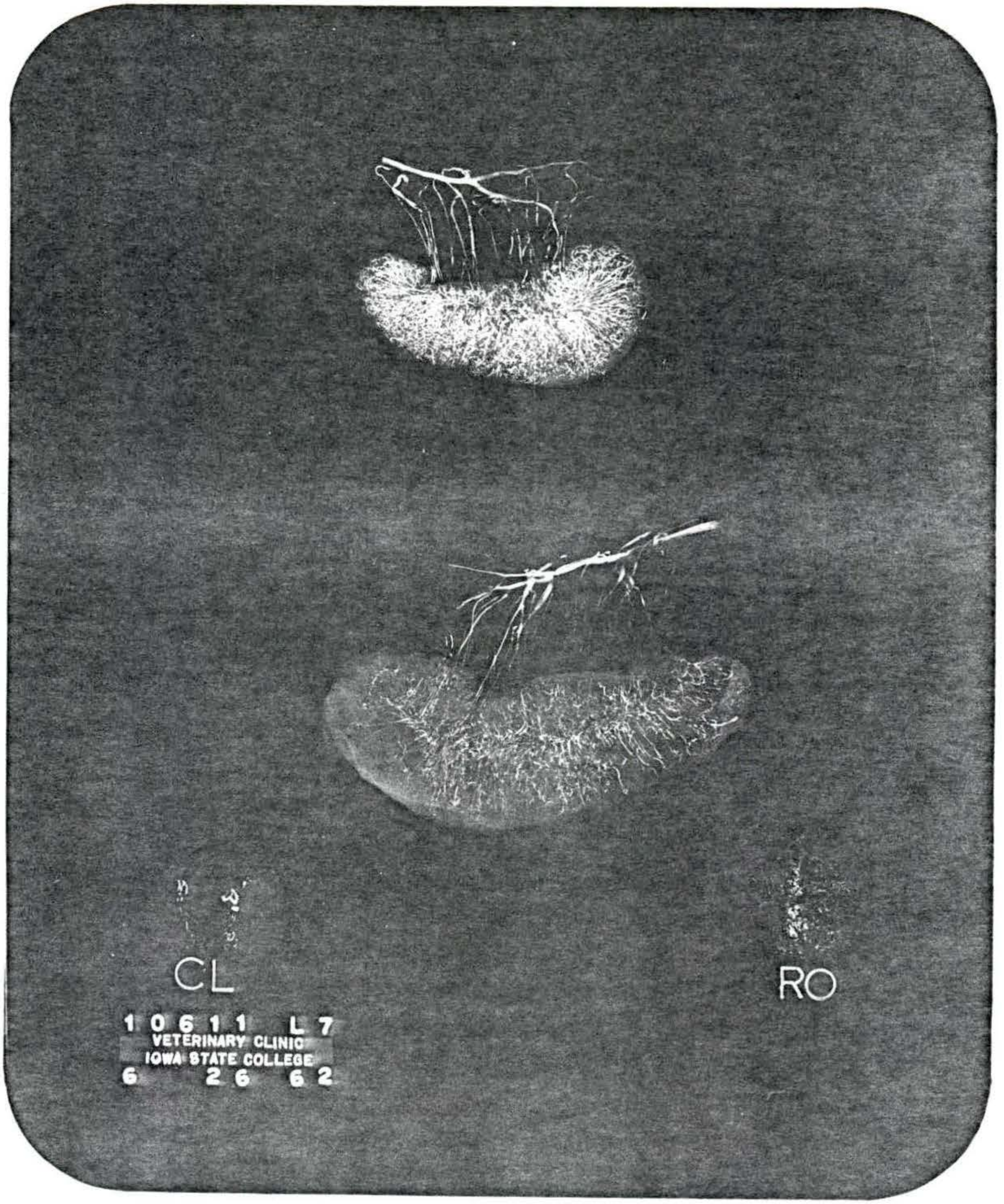
CL
RO
1 0 6 1 1 L 7
VETERINARY CLINIC
IOWA STATE COLLEGE
6 26 62

Figure 29. #106-17; View R-1: 12 hours post parturient. Intact apex of the right uterine horn and ovary. Observe the effect of rapid uterine involution on the uterine vasculature. Note the apparent lack of fine vessels and the great prominence of the courser vessels.

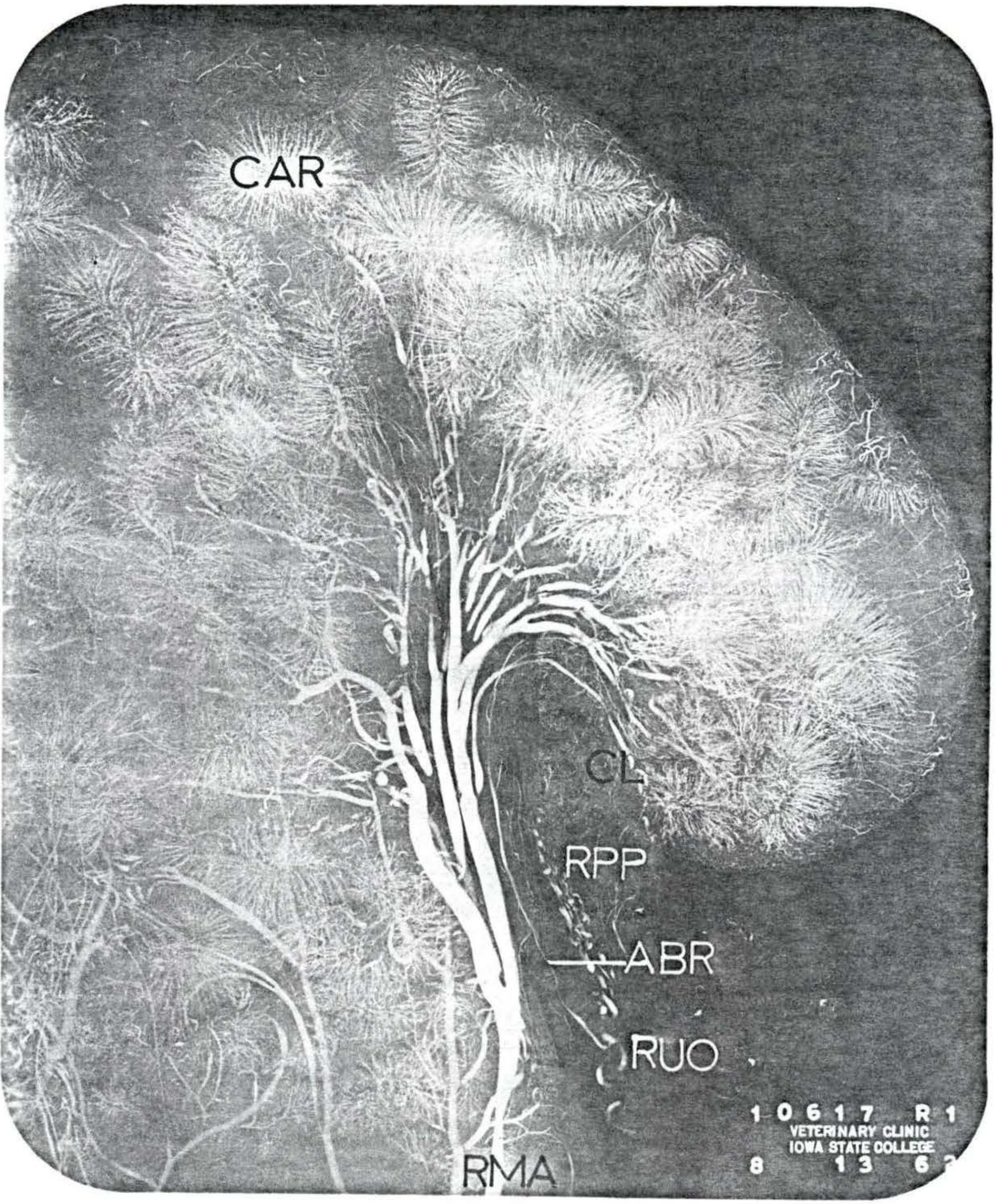
CAR
CL
RPP
ABR
RUO
RMA
1 0 6 1 7 R 1
VETERINARY CLINIC
IOWA STATE COLLEGE
8 13 6

Figure 30. #106-17; View R-3: 12 hours post parturient. Ventral half of the right uterine horn. Observe the uneven regression of the vasculature as evidenced by the caruncles.


CAR
RMA
1 0 6 1 7 R 3
VETERINARY CLINIC
IOWA STATE COLLEGE
8 13 62

Figure 31. #106-17; View R-6: 12 hours post parturient. Dorsal half of the cervix and apex of the non-pregnant left uterine horn, three sectioned caruncles, and sectioned ovaries. Note the shrunken caruncles and their dense course vasculature. The apex of the non-pregnant horn shows evidence of vessel coiling. The dorsal half of the cervix shows a very limited blood supply. The CL in the right ovary shows decreased blood supply as noted by its lack of contrast from the rest of the ovarian tissue.

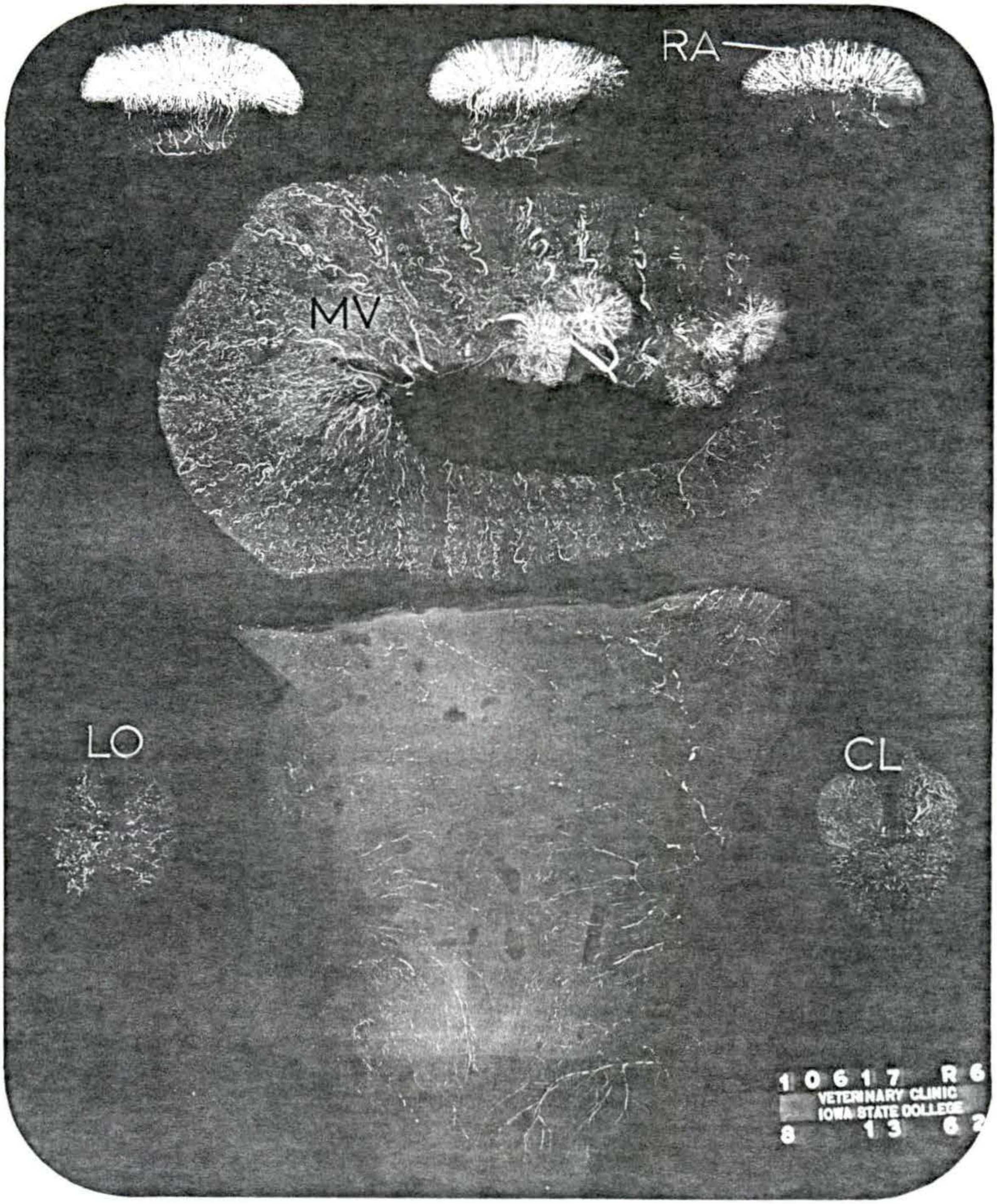
RA
MV
LO
CL
1 0 6 1 7 R 6
VETERINARY CLINIC
IOWA STATE COLLEGE
8 13 62

# APPENDIX B

## Legend

A - Arteriole

C - Capillary

CT - Fibrous connective tissue

D - Degenerating luteal cell

F - Fibroblast

J - Juvenile luteal cell

L - Luteal cell with deep staining pigment

M - Mature luteal cell

MA - Macrophage

N - Neutrophil

Note: The color photographs were taken of the luteal tissue magnified 160 times. The black and white photographs were taken of the luteal tissue magnified 400 times using a Patton #29 red filter. The black staining material observed in some of the blood vessels is contrast medium.

Figure 32. CL five days postestrus, 160x.
This view shows the developing luteal tissue and vasculature.

Figure 33. CL five days postestrus, 400x.
Note the juvenile luteal cells and the developing luteal stroma.


A
CT
C

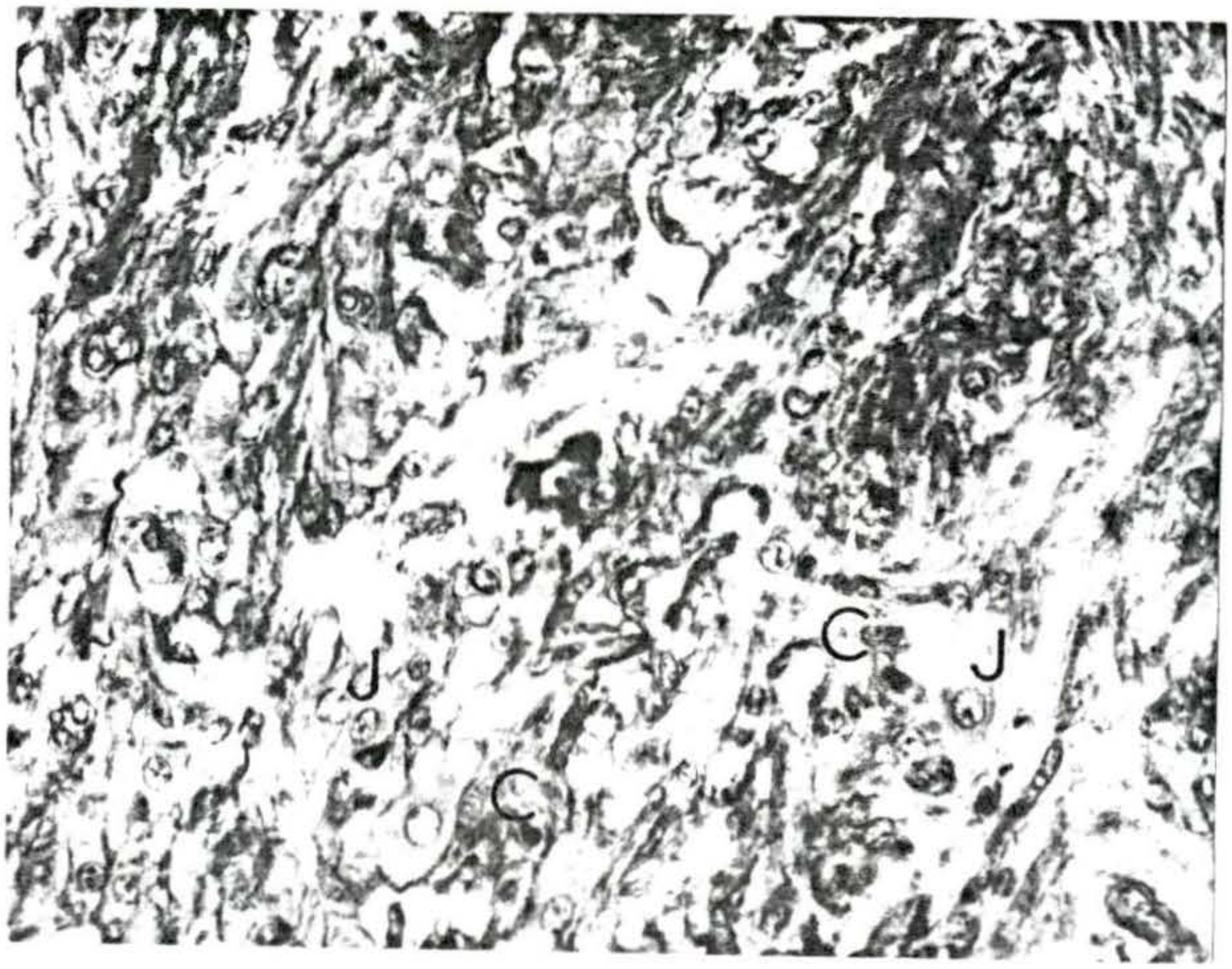
J
C
J
C

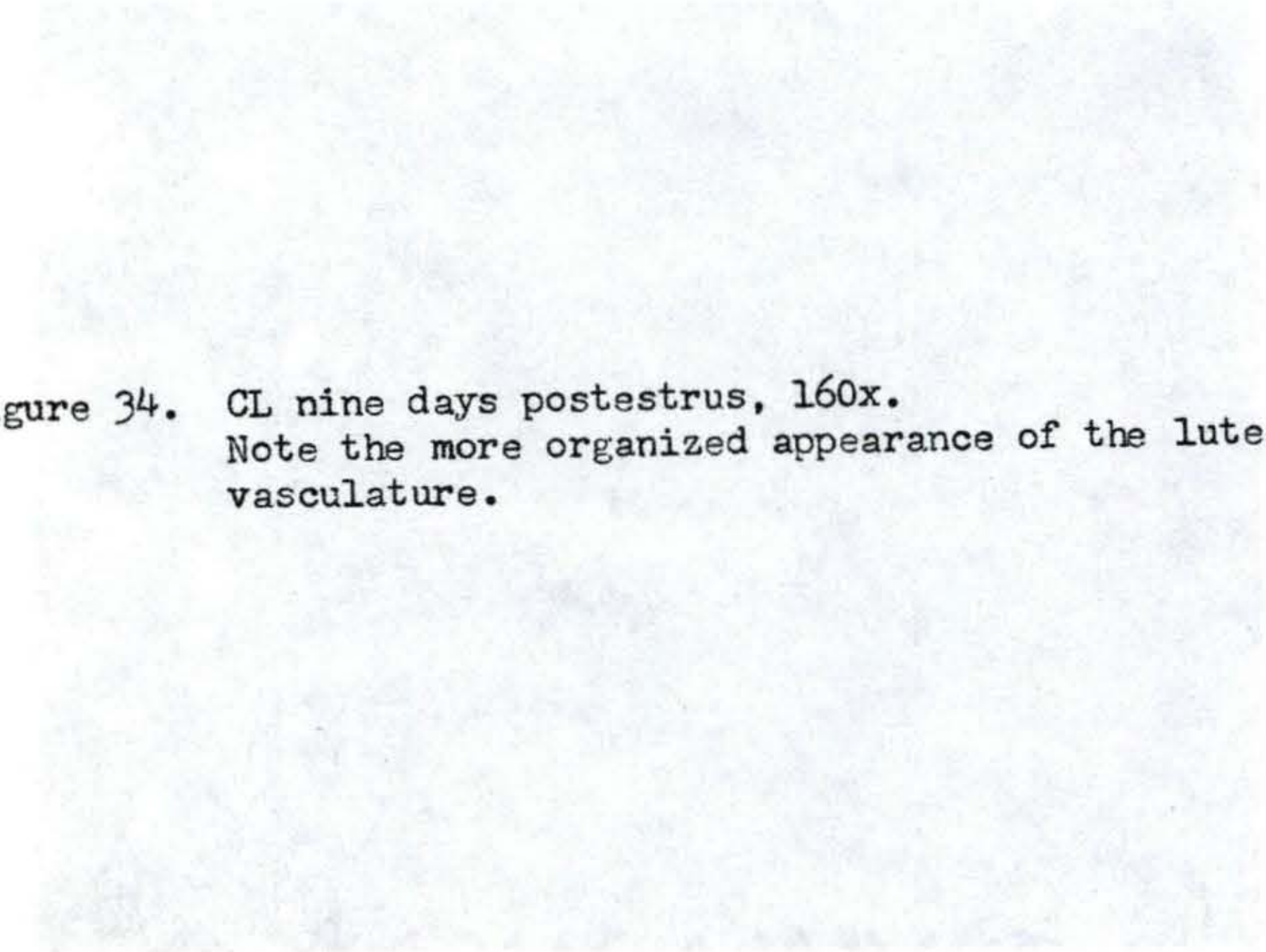

Figure 34. CL nine days postestrus, 160x.
Note the more organized appearance of the luteal tissue and vasculature.

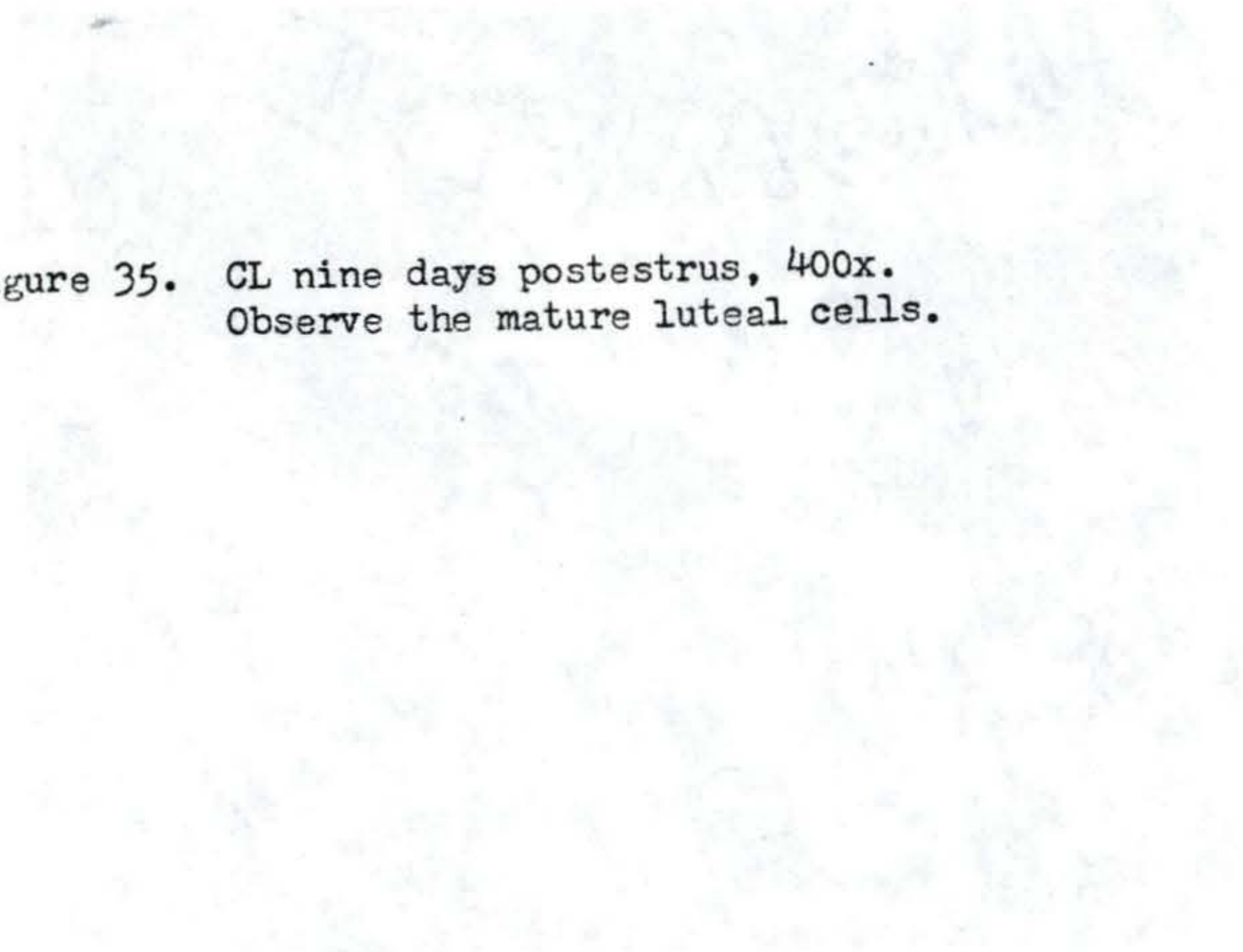

Figure 35. CL nine days postestrus, 400x.
Observe the mature luteal cells.

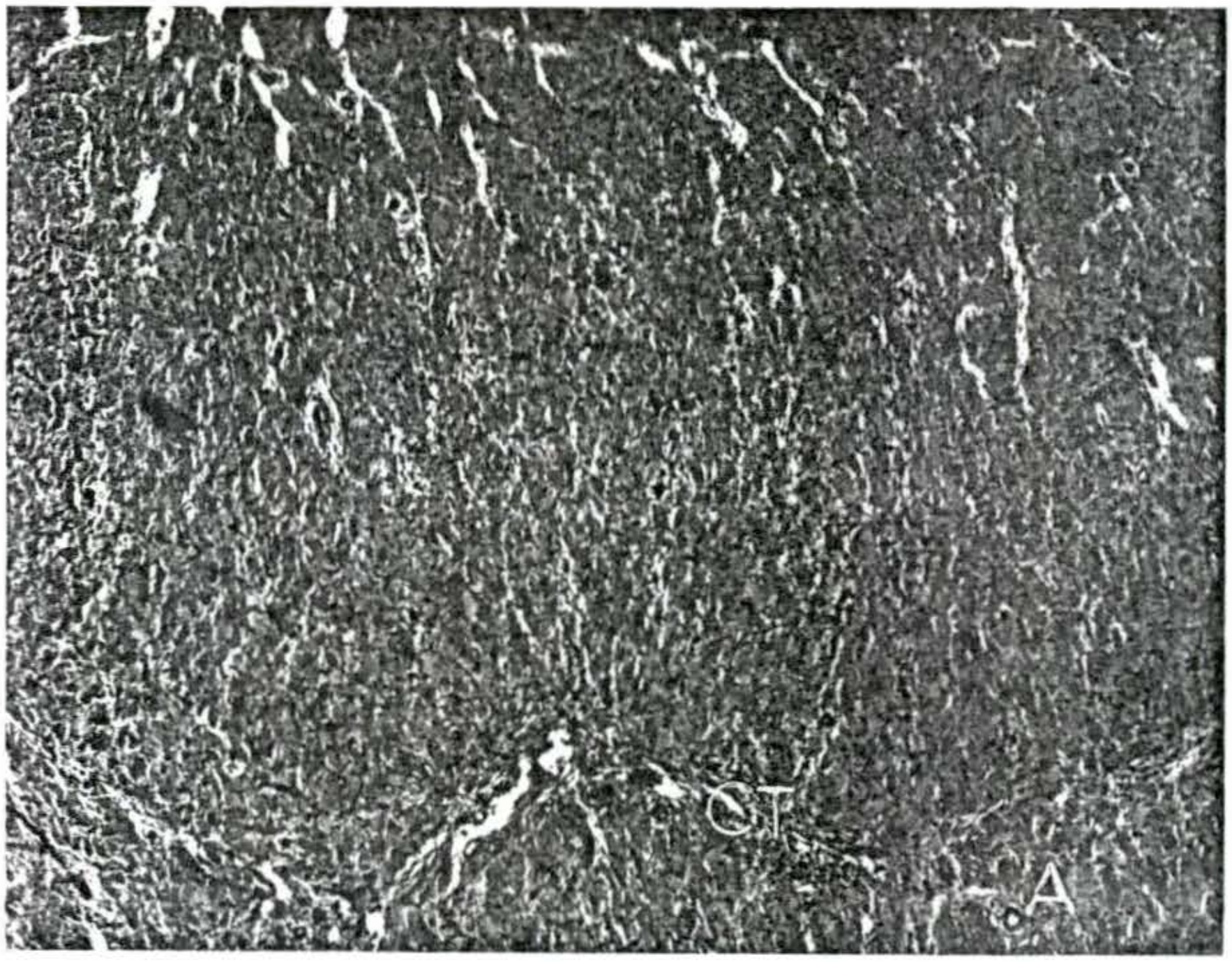
CT
A

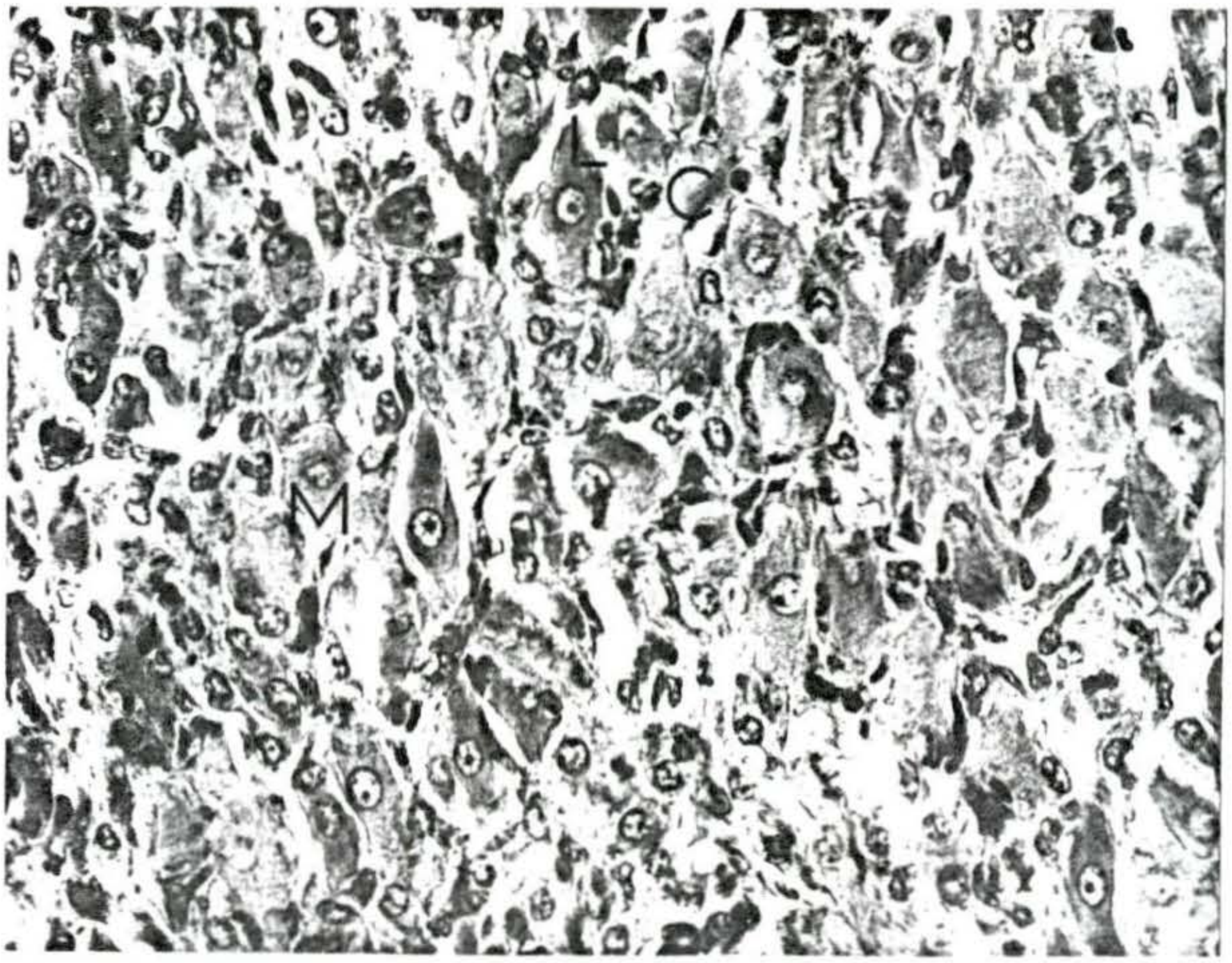
L
C
M

Figure 36. CL 12 days postestrus, 160x.
This view is similar to the nine day specimen except that it appears to have a better developed vasculature.

Figure 37. CL 12 days postestrus, 400x.
The majority of the luteal cells are still mature and uniform appearing. The vasculature is well developed.


A
CT

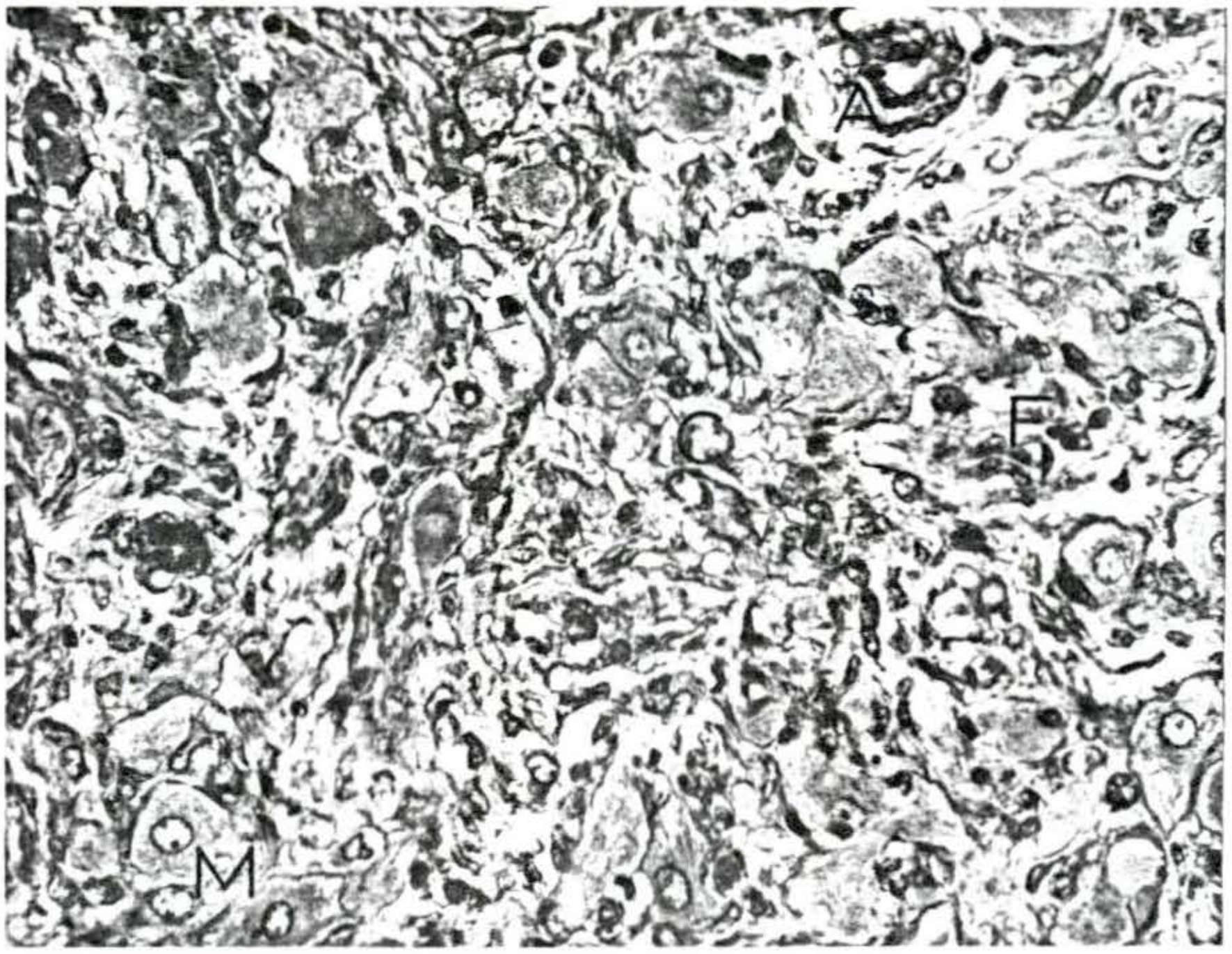
A
C
F
M

Figure 38. CL 21 days postestrus, 160x.
The luteal tissue shows evidence of degeneration with increased space between the luteal cells.

Figure 39. CL 21 days postestrus, 400x.
This view shows degenerating luteal cells and regression of the vasculature.

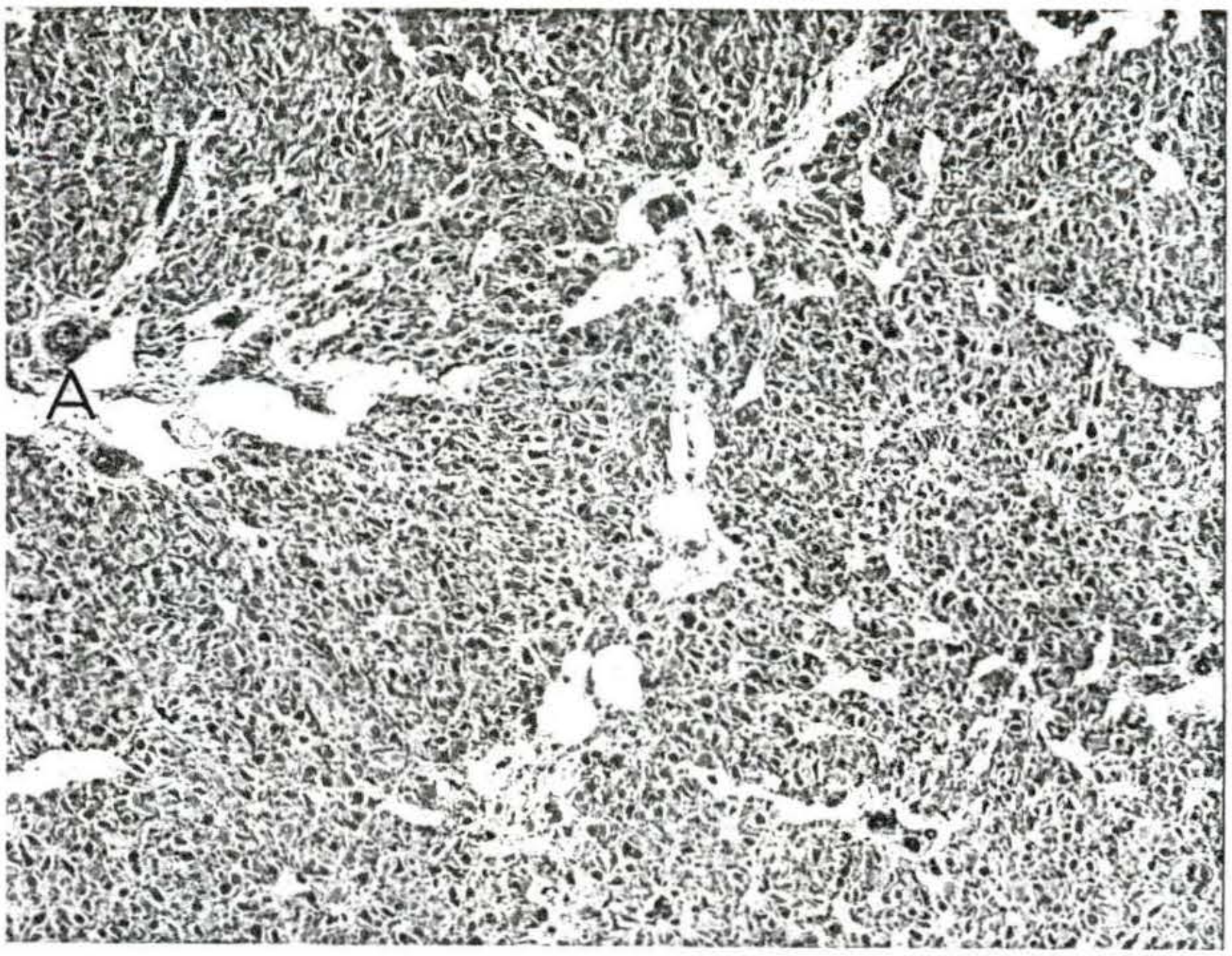
A

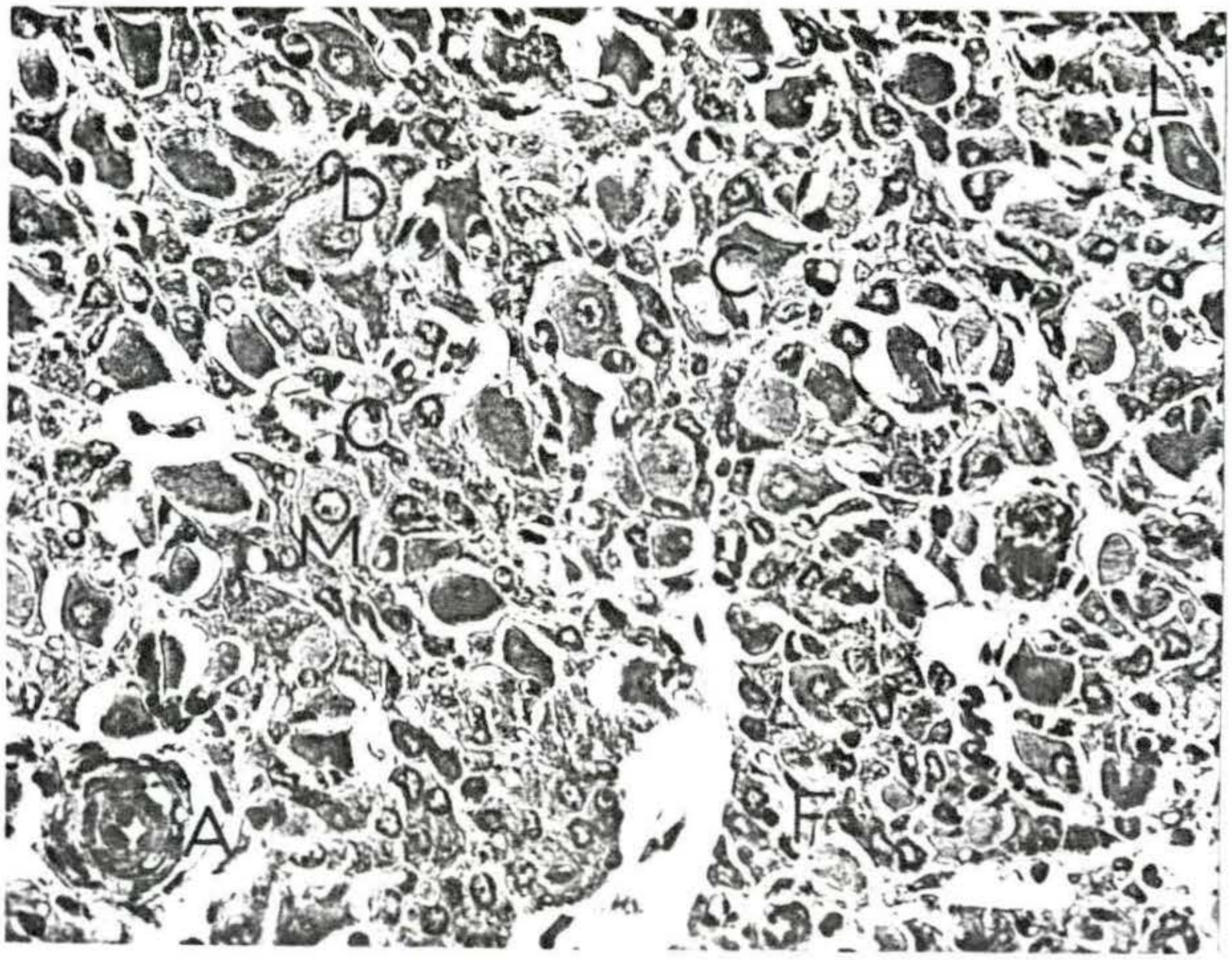
L
D
C
C
M
F
A

Figure 40. CL from 90 day pregnancy, 160x.
Notice the organized appearance and the abundant vasculature.

Figure 41. CL from 90 day pregnancy, 400x.
Note the deeper staining and more angular luteal cells. There is a well developed capillary network within the luteal stroma.

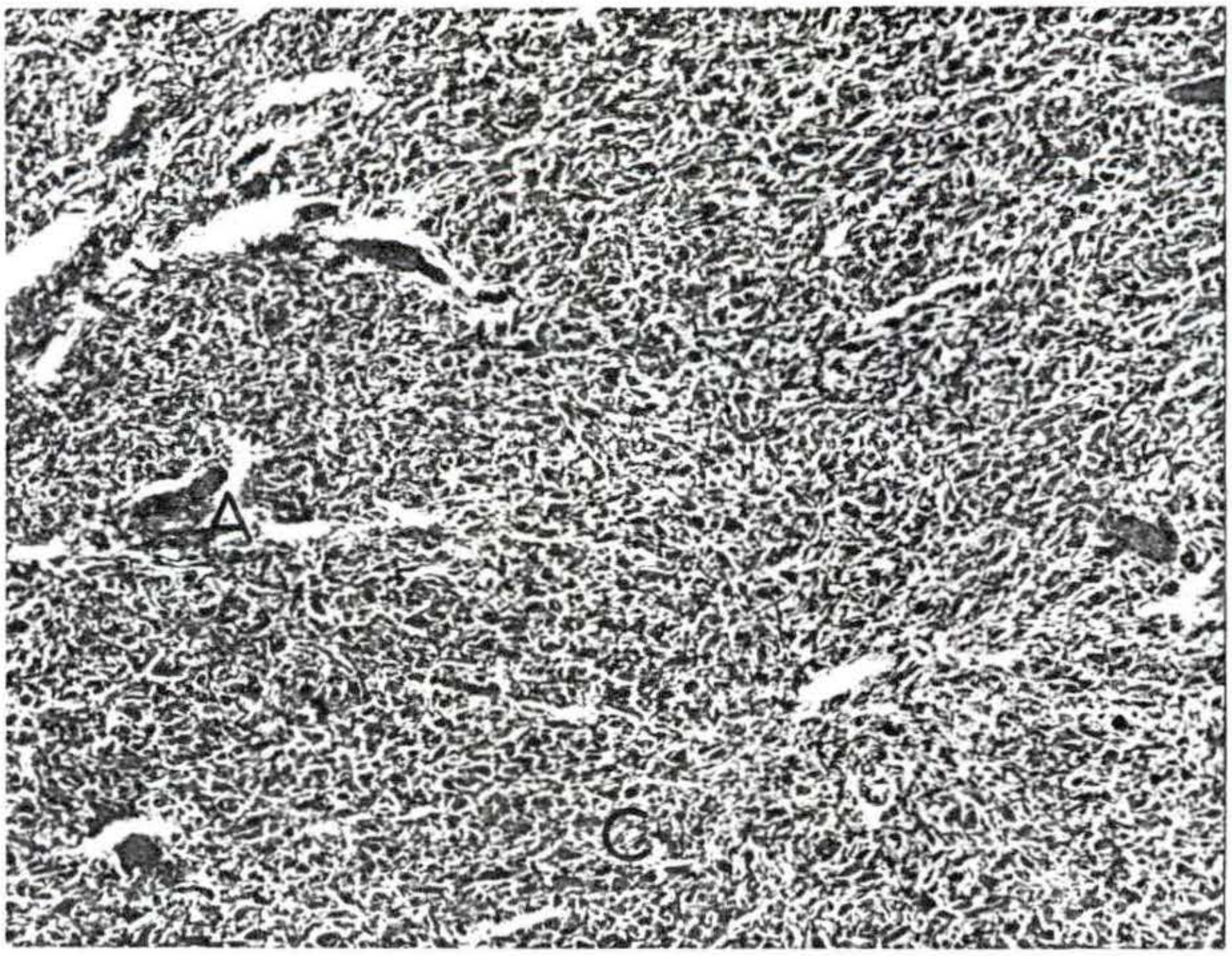
A
C

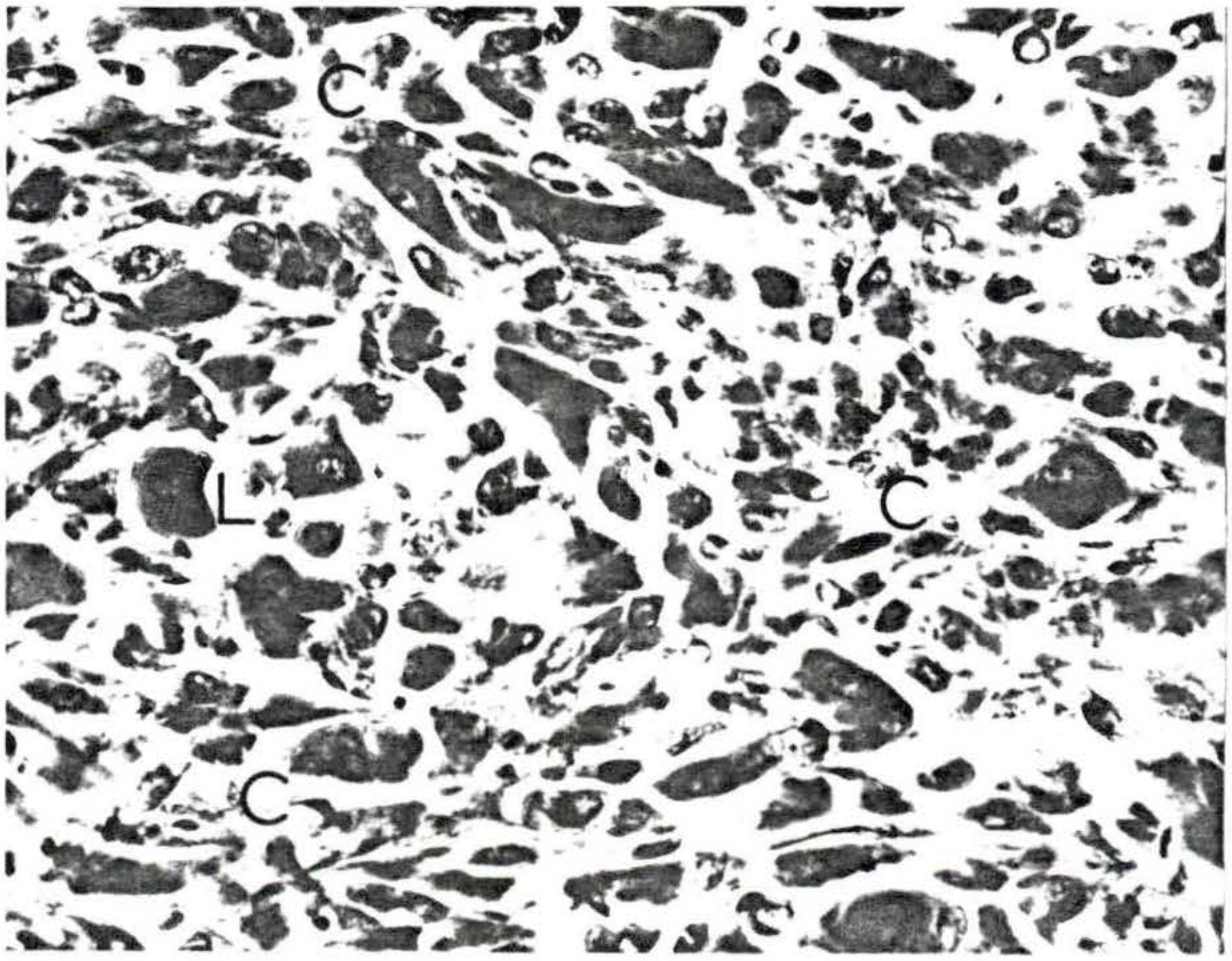
C
L
C
C

Figure 42. CL from 120 day pregnancy, 160x.
Observe the abundant blood supply.

Figure 43. CL from 120 day pregnancy, 400x.
The vasculature is well developed in this specimen.

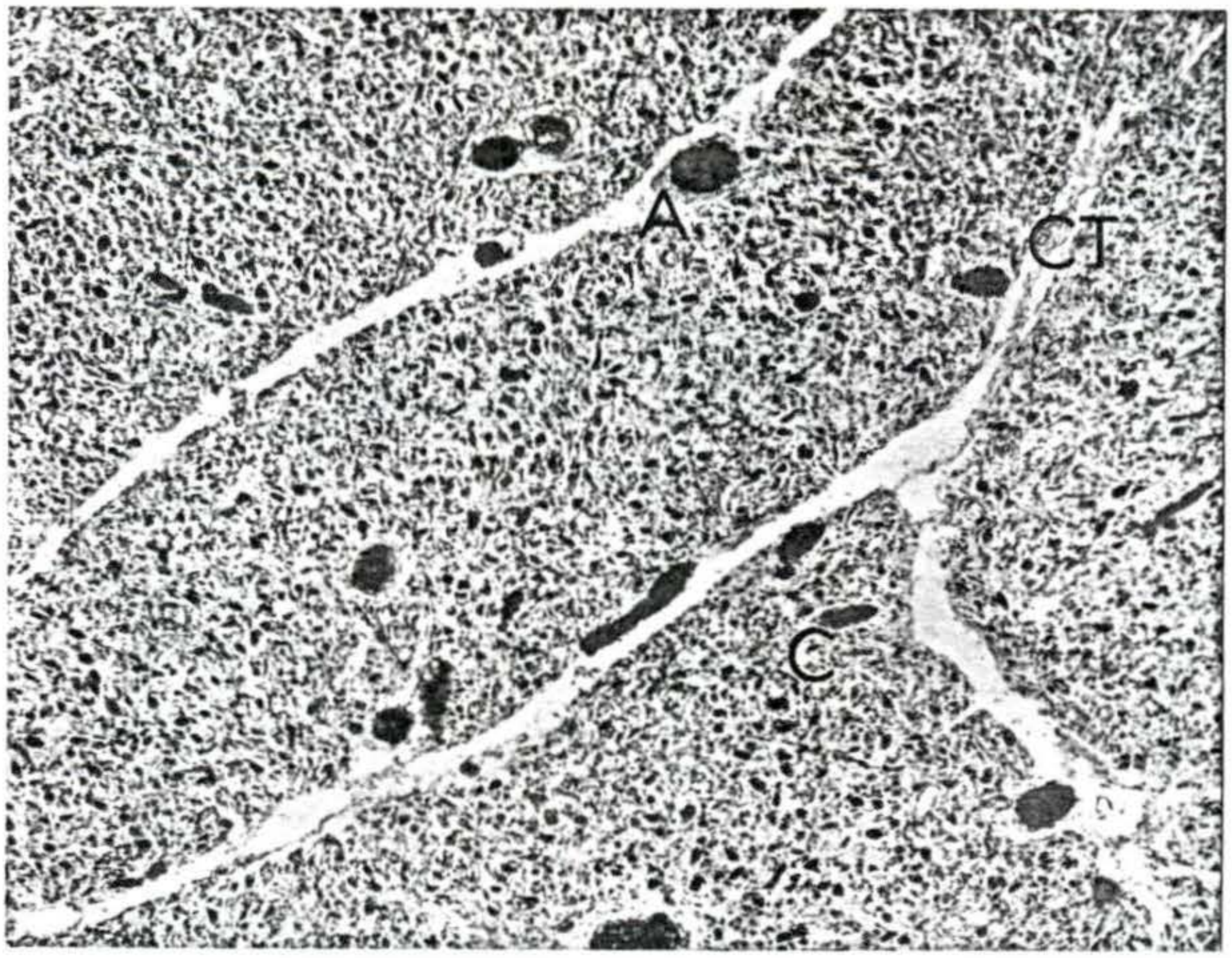
A
CT
C


L
F
C
C

Figure 44. CL from 150 day pregnancy, 160x.
The vasculature shows some signs of regression and fibroplasia is now clearly evident.

Figure 45. CL from 150 day pregnancy, 400x.
The fibroplastic infiltration between the luteal cells is easily noticed. Some luteal cells contain cytoplasmic granules.

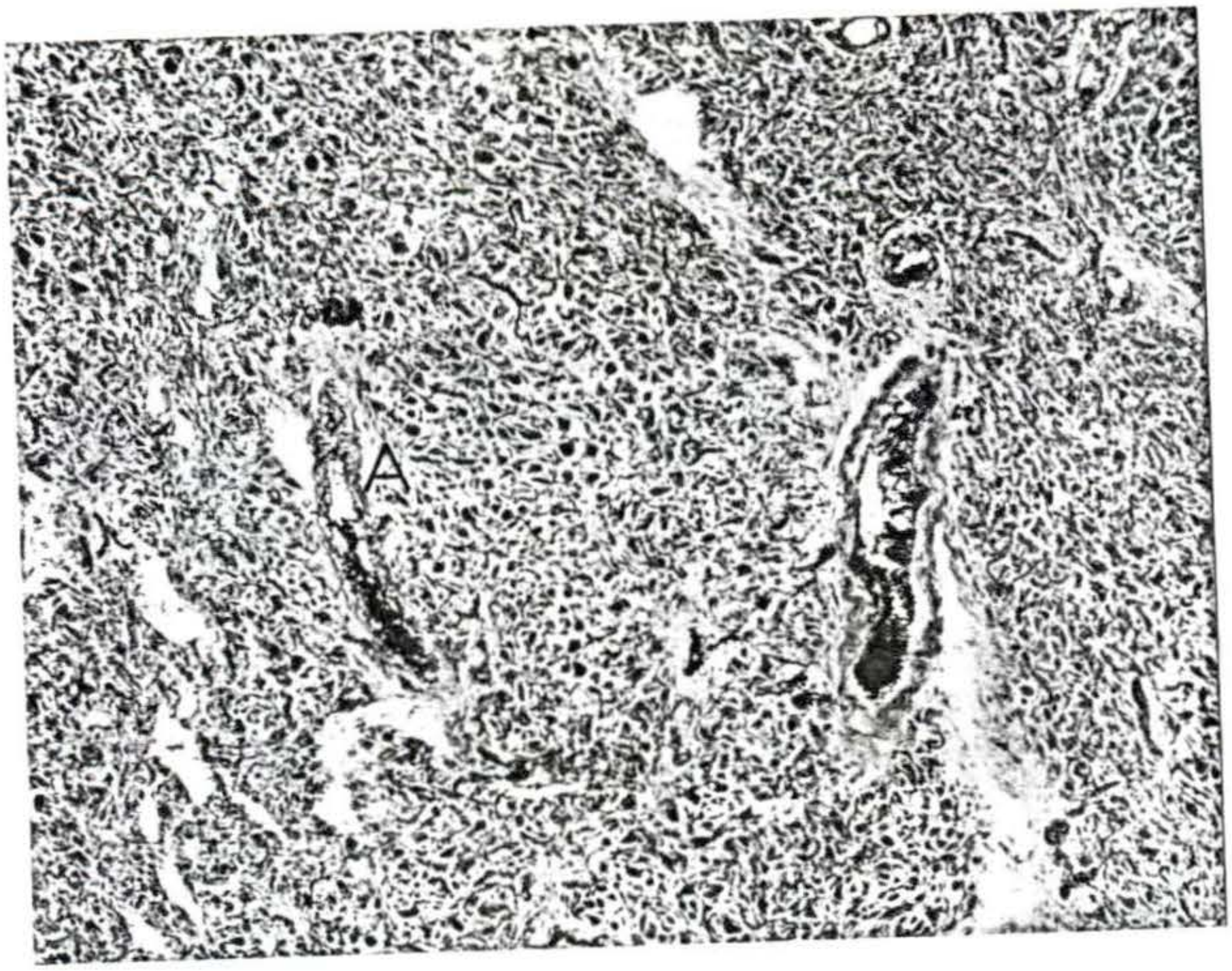
A


D
C
C
F
L

Figure 46. CL from 181 day pregnancy, 160x.
Observe the increased fibroplasia with marked leucocytic infiltration and the regression of capillaries.

Figure 47. CL from 181 day pregnancy, 400x.
The marked infiltration of neutrophils and macrophages is very evident. Note the large spaces between luteal cells.

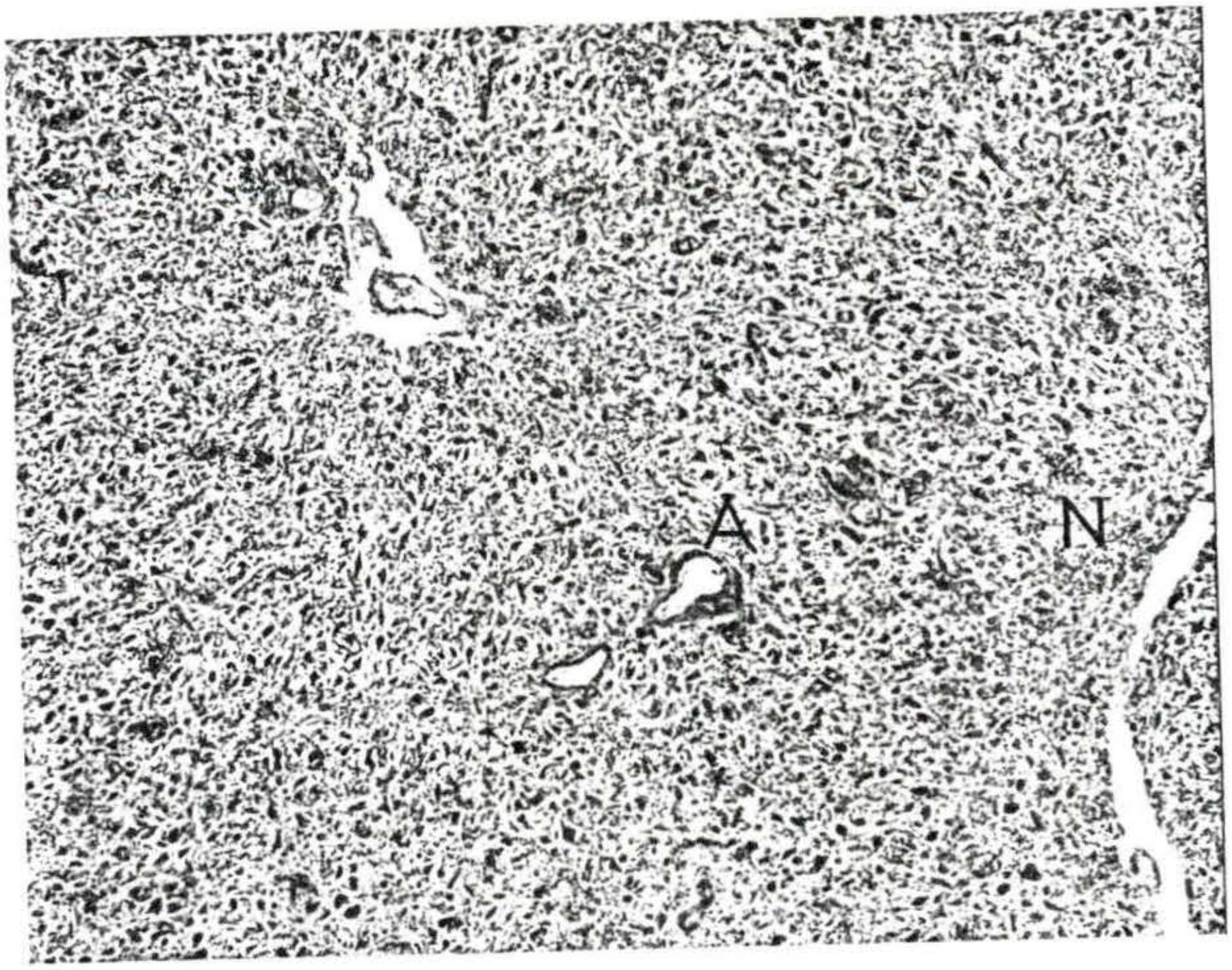
A
N


L
C
MA
N

Figure 48. CL from 210 day pregnancy, 160x.
Again note the vascular regression and increased fibroplasia.

Figure 49. CL from 210 day pregnancy, 400x.
Numerous fibroblasts and abundant fibrous tissue occupies nearly all of the area in this view.

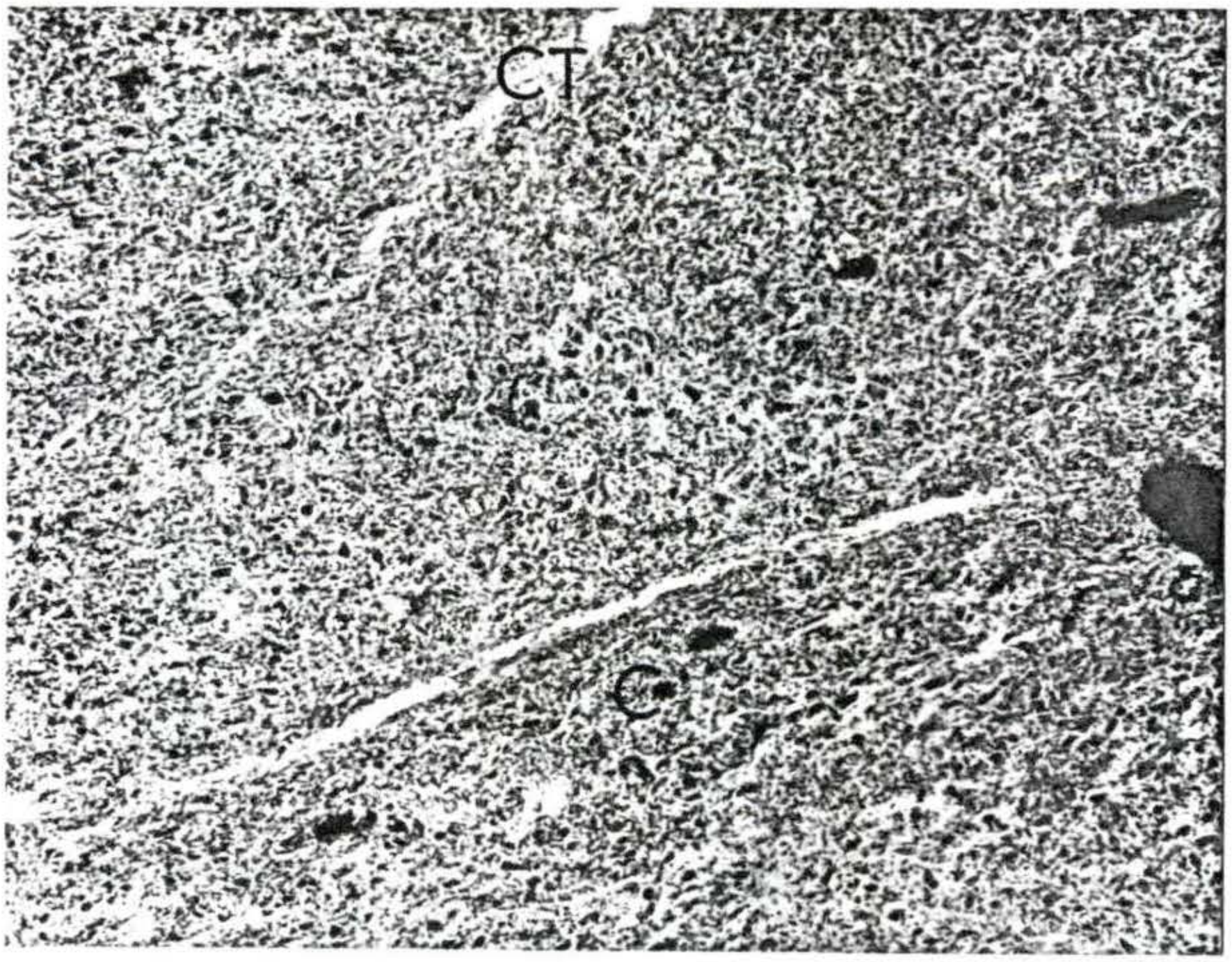
CT
C
C

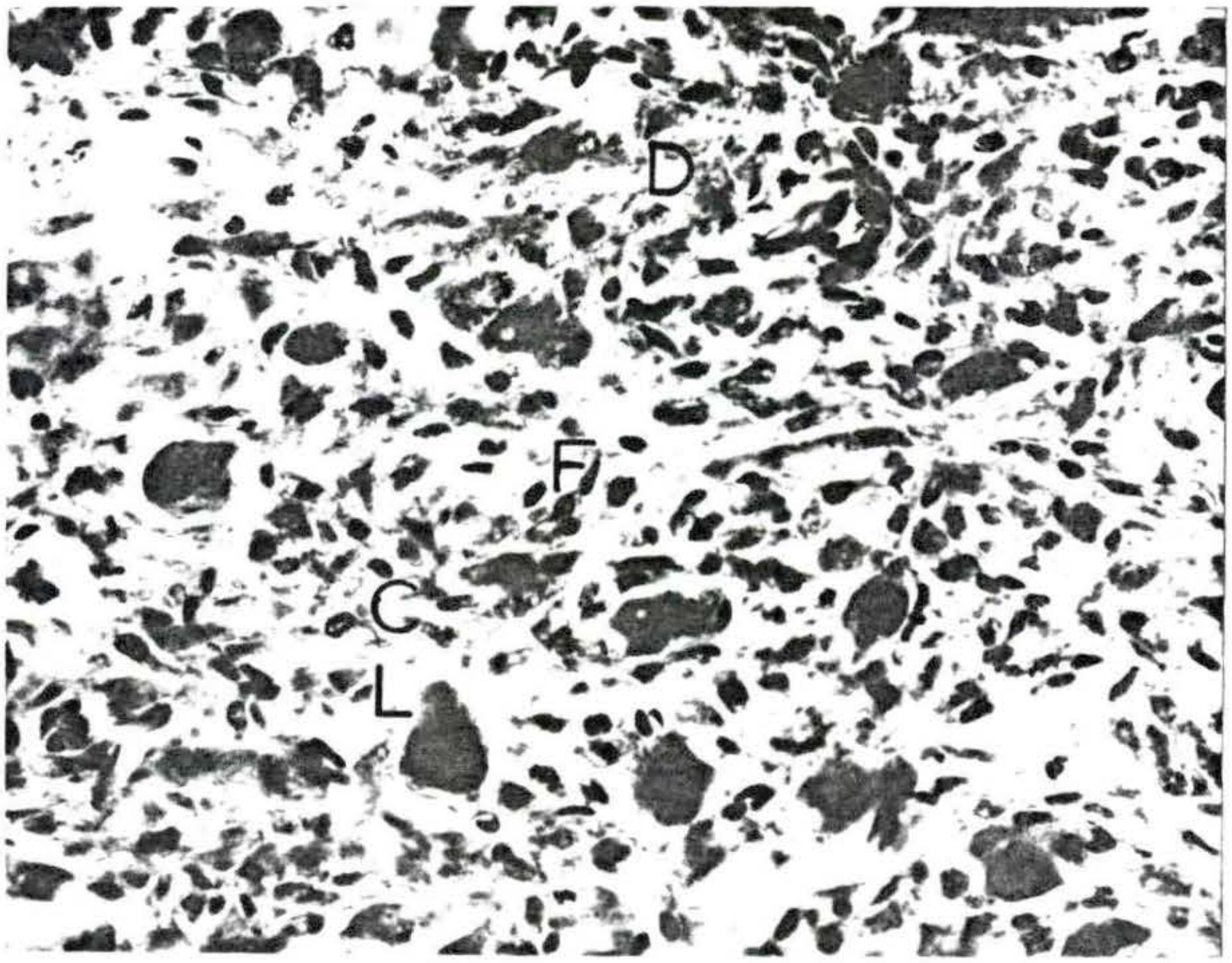
D
F
C
L

Figure 50. CL from 241 day pregnancy, 160x.
Note the marked contrast to the trend by this specimen. The luteal stroma is still well developed with minimal amounts of fibroplasia. This appears to be an active glandular tissue.

Figure 51. CL from 241 day pregnancy, 400x.
Note the luteal cells are more uniform in size and staining. The vasculature is abundant. Some degeneration is occurring as observed by the granularity of some of the luteal cells.

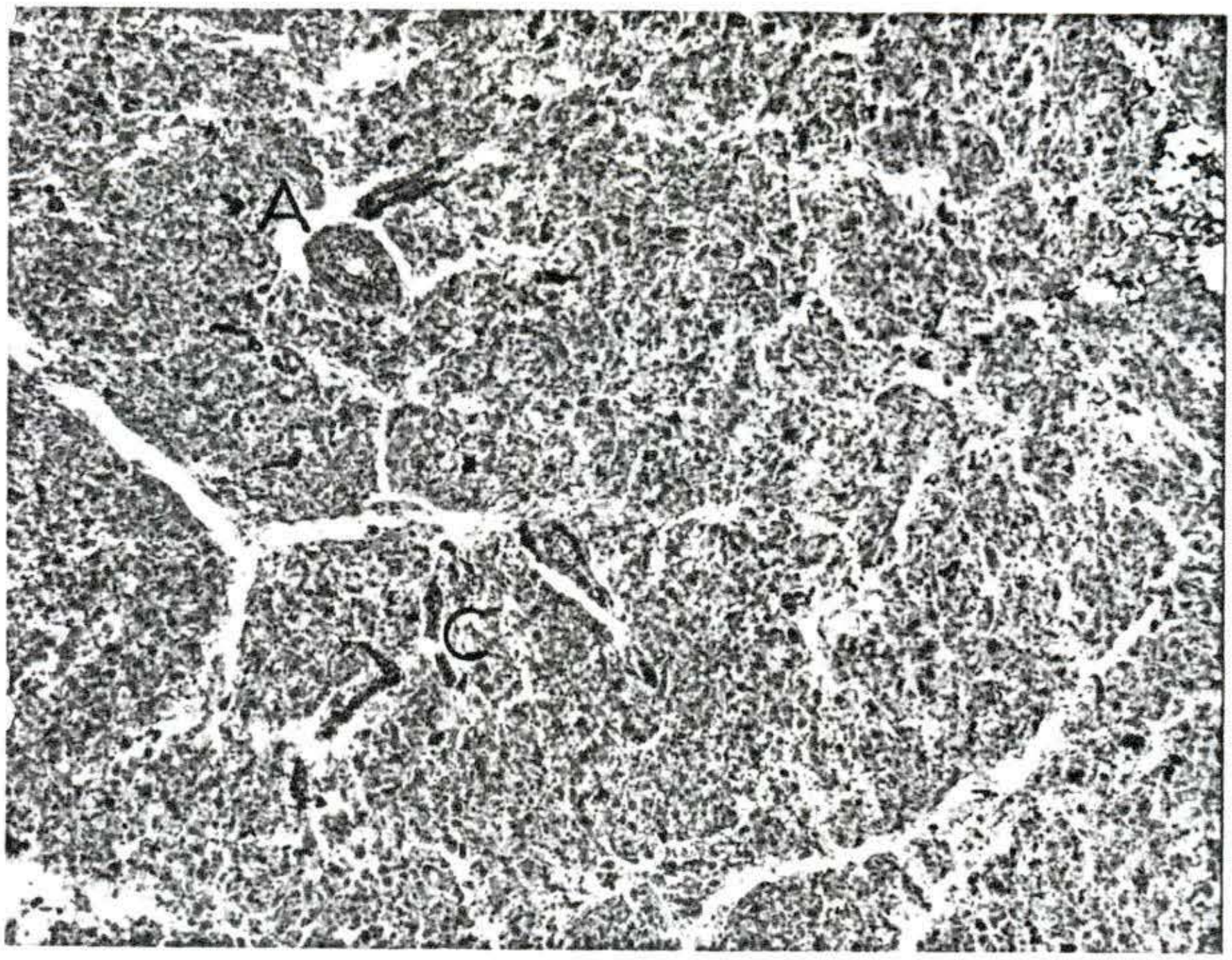
A
C

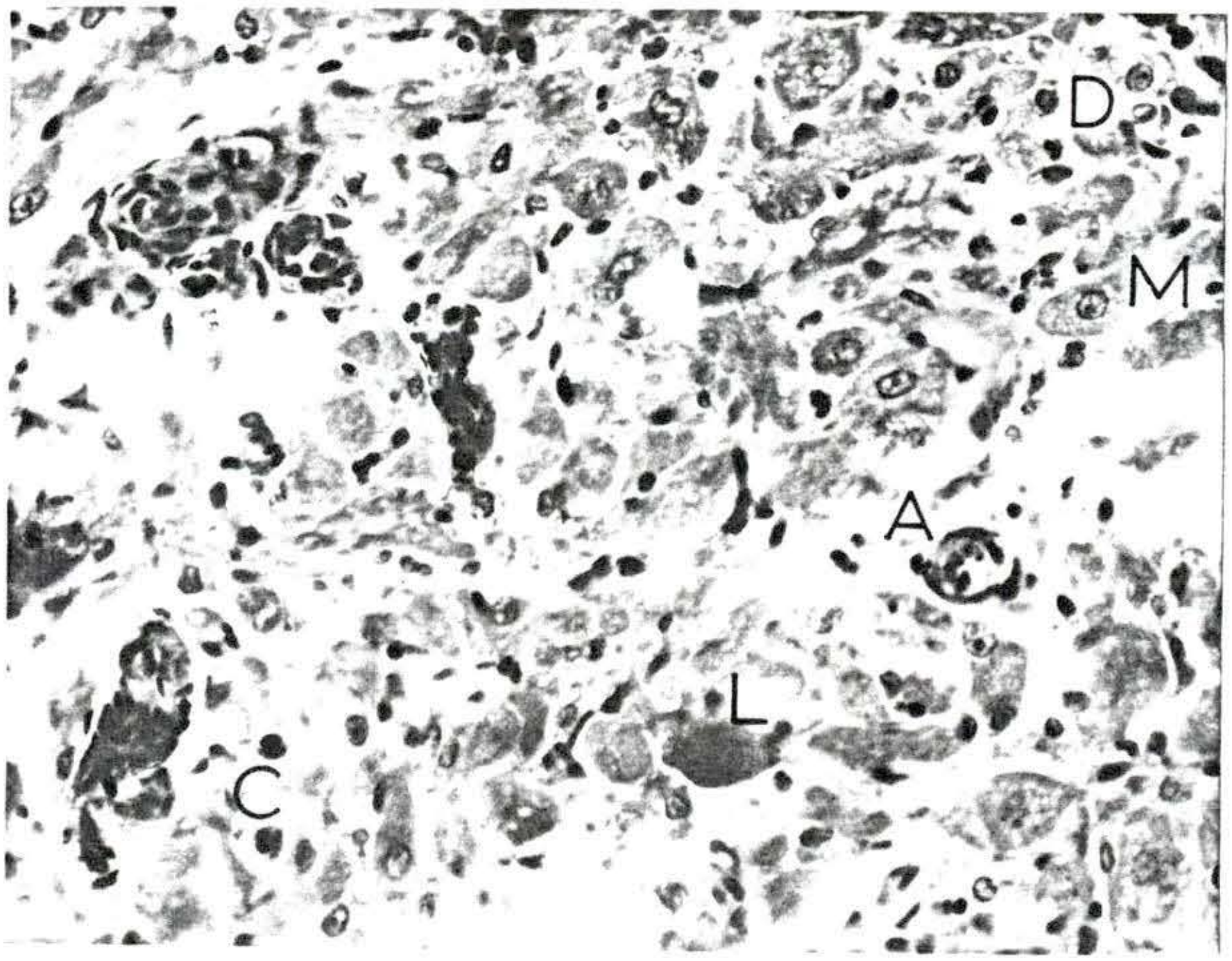
D
M
A
L
C

Figure 52. CL from 273 day pregnancy, 160x.
Note the return to the pattern of fibroplasia. There is an abundant blood supply but a definite regression is occurring in the luteal tissue.

Figure 53. CL from 273 day pregnancy, 400x.
Note the almost complete absence of active luteal cells and the advanced fibroplasia. The luteal cells visible show definite granular degeneration.

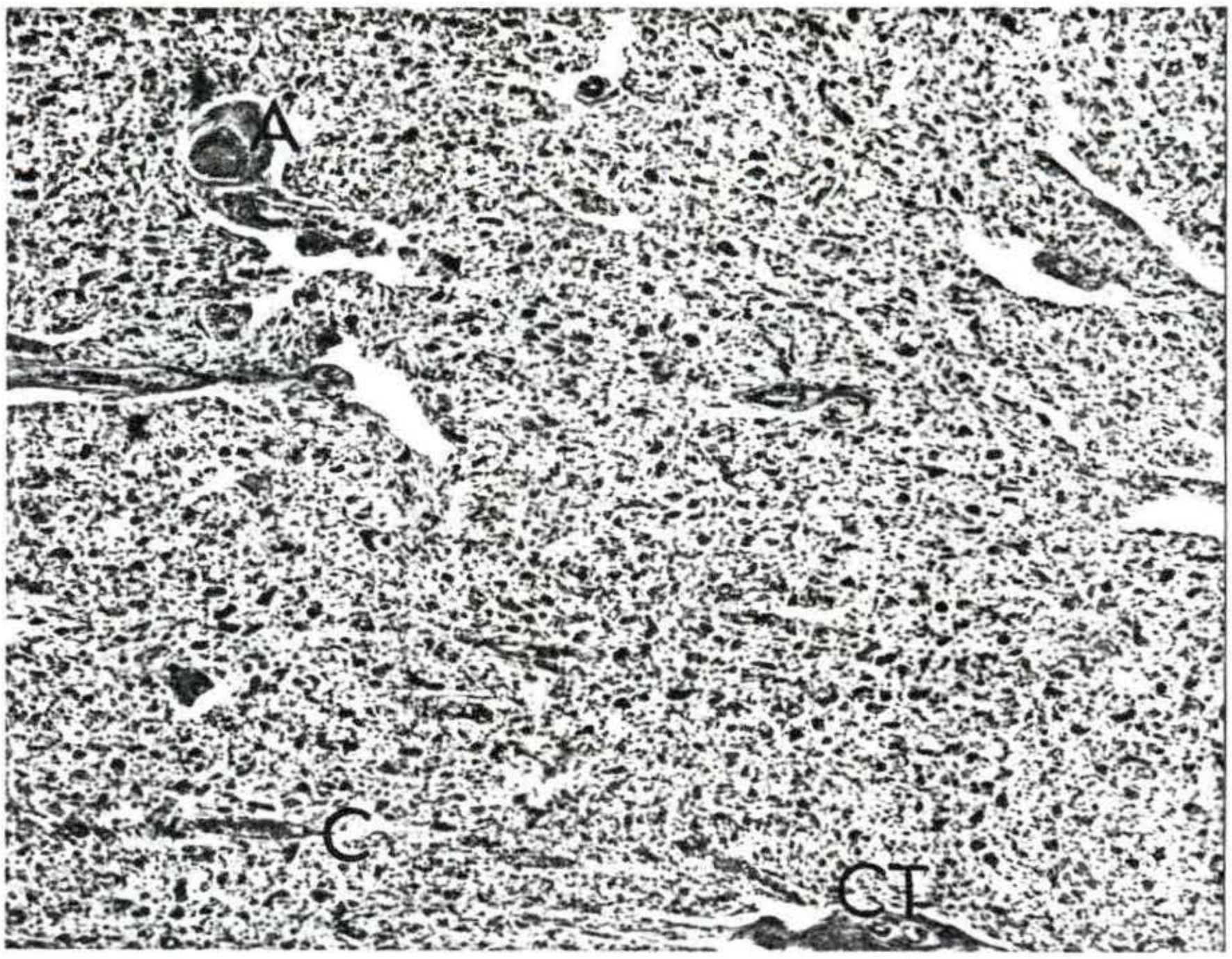
A
C
CT


D
C
A
F
C

Figure 54. CL from cow 12 hours postparturient, 160x.
Note the advanced fibroplasia and marked regression of small blood vessels.

Figure 55. CL from cow 12 hours postparturient, 400x
Note the shrunken angular appearance of the luteal cells. Just about every luteal cell is surrounded by collagen fibers.

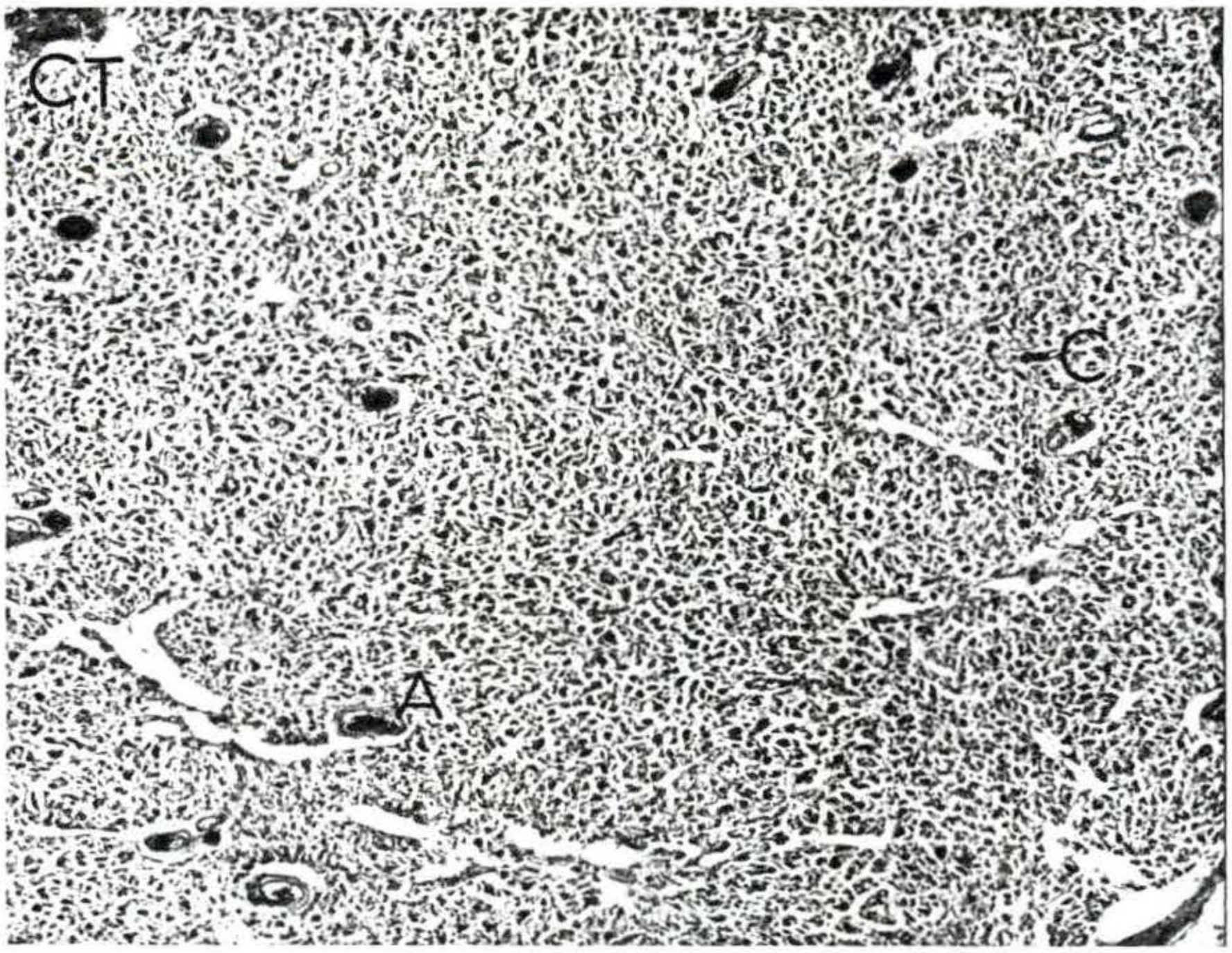
CT
C
A


F
L
D
C
A