

SF 971  
D532p  
C. 2

207

THE PATHOGENESIS OF BRUCELLOSIS IN MALE SWINE

by

Billy Lee Deyoe

A Thesis Submitted to the  
Graduate Faculty in Partial Fulfillment of  
The Requirements for the Degree of  
MASTER OF SCIENCE

Major Subject: Veterinary Pathology

---

Signatures have been redacted for privacy

Iowa State University  
Of Science and Technology  
Ames, Iowa

1965

1486600

## TABLE OF CONTENTS

	Page
INTRODUCTION	1
REVIEW OF LITERATURE	3
METHOD OF PROCEDURE	18
Boars	18
Exposure Cultures	20
Clinical Observations	24
Serologic Examinations	24
Bacteriologic Examinations	26
Pathologic Examinations	29
RESULTS	33
Clinical Observations	33
Serologic Examinations	35
Bacteriologic Examinations	37
Pathologic Examinations	41
DISCUSSION	79
SUMMARY	87
LITERATURE CITED	90
ACKNOWLEDGEMENTS	99

## INTRODUCTION

Swine brucellosis was first recognized as a specific infectious disease in 1914. It still causes considerable economic loss to the swine industry as well as being a serious public health problem. Two biotypes of Brucella suis, namely Br. suis, type 1, and Br. suis, type 3, are responsible for the majority of swine brucellosis in the United States. Although there are many avenues by which Br. suis can be spread, venereal transmission is one of the most important. During enzootics infected boars are often incriminated as the primary spreaders.

Most of the research on swine brucellosis in the past has been concentrated on the clinical, serologic, immunologic, bacteriologic, and epizootiologic aspects of the disease. Studies of the histopathologic aspects have usually been conducted only on tissues bearing gross lesions. In most of these cases, infection had existed for long periods of time or the postexposure interval was unknown.

To determine the evolution of a disease process, it is necessary to know the extent to which the etiologic agent is disseminated in the body and how it becomes localized in particular organs soon after exposure. The pathogenesis of

swine brucellosis has not been thoroughly investigated. Therefore, this study was undertaken to gain more information about the pathogenesis of brucellosis in sexually mature boars during the early postexposure period.

## REVIEW OF LITERATURE

Jacob Traum is credited with the first isolation of an organism later to be known as Br. suis. In 1914 he isolated the organism from aborted swine fetuses (77). Since that time swine brucellosis has been recognized as a specific entity but the incidence has never been definitely determined. Various surveys between 1935 and 1960, using the serum agglutination test as a diagnostic tool, have estimated the incidence to vary between 1% and 6.5% of all swine (6, 27, 31, 39, 55, 57, 58). McCullough et al. (55) isolated Brucella from the submaxillary lymph nodes of 0.7% of 5,000 randomly selected swine in a packing plant. In another packing house survey, McNutt (58) isolated Brucella from the tissues of 1.2% of 1,547 swine. Recently, comprehensive data compiled by the Animal Disease Eradication Division of the United States Department of Agriculture in connection with swine brucellosis eradication activities indicates that approximately 2.5% of the swine herds in the United States of America are infected (66).

At present there are three recognized biotypes of Br. suis involved in the etiology of swine brucellosis. Brucella suis, type 1, and Br. suis, type 3, occur in the United

States, while Br. suis, type 2, is thought to be present only in Europe. Huddleson (33), Manthei (60), Meyer (64), and Stableforth and Jones (73) all discuss adequately the characteristics and recent methods of classification of the genus Brucella.

Early in the history of swine brucellosis in the United States, the organism now recognized as Br. suis, type 1, was thought to be the primary cause of the disease. However, in 1943 Jordan and Borts (48) isolated an organism they classified as Brucella melitensis from two packing house workers. So-called Br. melitensis associated with bacteriologically proven human brucellosis was first recovered from naturally infected swine in Iowa in 1946 by Borts et al. (5). Damon and Scruggs (17) duplicated this feat in 1950. Beal et al. (4) credits Huddleson with typing a culture isolated from a Minnesota hog as Br. melitensis in 1933. Although there is no evidence available comparing the ease of isolation and virulence of Br. suis, type 1, and this so-called Br. melitensis from humans, the incidence of the latter in humans has been increasing. Of the Brucella strains recovered from 1927 to 1945 in Iowa, 7.7% were classified as Br. melitensis (48). During the 1930-1961 period, 15% of the human isolates in Iowa were classed as Br. melitensis, while during the last

two years of that period 50% of such isolates were classed as Br. melitensis (27, 28). Out of 23 isolations from humans by the Iowa State Hygienic Laboratory in 1963, 21 were classified as Br. melitensis and 2 were Br. suis (74). This evidence also emphasizes the importance of swine brucellosis as a public health problem.

These so-called Br. melitensis isolates from humans and swine have been classified as such by older recognized methods (34, 35). However, they were recognized as being somewhat different than typical European Br. melitensis and were differentiated into "American type" and "Mediterranean type" on the basis of differences in urease activity (4). In recent years more refined methods of speciation have been developed and thereby clarified some of the confusion about these organisms. In the words of Meyer (64):

Considerable misunderstanding has arisen concerning the susceptibility of swine to infection with Br. melitensis. It is now realized that the organisms being recovered from infected swine in the midwestern United States, and initially identified as Br. melitensis are, in fact, Br. suis, type 3. Swine are apparently poor hosts for Br. melitensis, as there are no instances where there has been an unquestionable isolation of Br. melitensis from swine tissues.

The origin of Br. suis, type 3, has never been determined. However, Meyer (65) has found that in vitro mutations can occur whereby Br. suis, type 1 organisms become identical

metabolically to Br. suis, type 3, and vice versa.

Brucellosis of boars is usually subclinical or asymptomatic with no detectable physical signs pathognomonic of the disease, except for a few which occur in limited circumstances. The only characteristic sign in boars is severe progressive epididymitis and/or orchitis, which is often unilateral (49, 59). Although there is no difference in age susceptibility (43, 61), Manthei (60) stated that orchitis seldom develops in boars before they reach sexual maturity. Lameness is occasionally observed, but has not always been proven to be due to Brucella (29, 37, 40, 45). Arthritis and spondylitis with posterior paralysis has also been observed (37, 40, 45, 56, 61). Hadley and Beach (25) and McNutt (56) observed that injection of swine with a heavy dose of Brucella may result in a high fever and prostration a short time later. However, Manthei (60) states that there is no consistent rise or undulating type of fever during the course of Br. suis, type 1, infection in swine. Decreased sexual desire, decreased semen quality, and even sterility has been attributed to brucellosis in boars (2, 37, 40, 41, 42, 61, 75). Hutchings et al. (42) records two cases of infected boars which lost weight and commonly showed muscular tremors when aroused. Death is rare but both McNutt (56) and King



and Kinross (51) record cases of fatal brucellosis in swine.

The general consensus is that ingestion and copulation are the principal avenues of transmission of swine brucellosis. Many (25, 34, 60, 61, 62) feel that ingestion is more important, while others (37, 75) hold the opposite view.

Most authors agree that swine brucellosis is a self-limiting disease, but it is seldom that a large herd, once infected, is ever free of the disease unless control measures are instituted. It has been stated (9, 57) that hogs show considerable resistance to Br. suis. In fact, Cameron et al. (10, 11) were successful in developing a strain of hogs that were highly resistant to Br. suis. Manthei (60) states that Br. suis, type 1, fails to persist in 15% of swine that show a bacteremia. The course of brucellosis in swine is variable, with the organism usually persisting in the blood stream or tissues from 1 to 6 months (24, 40, 46, 57, 61). However, infection may persist for years, especially in genital organs of infected boars (41, 51, 57, 60, 61). Hoerlein (29) has been the only investigator to study the pathogenesis of experimental Br. suis, type 3, infection in swine. From his work with sows, he concluded that the disease caused by Br. suis, type 3 was similar to that caused by infection with Br. suis, type 1.

The serum agglutination test is the most practical method of diagnosing swine brucellosis at present, although it has limitations in individual swine. Hutchings (38), as well as others, have demonstrated that serum agglutination tests are adequate as a herd diagnostic procedure but are not reliable in an individual animal. Numerous reports, including those by Feldman and Olson (21), Hutchings and Andrews (41), Johnson et al. (47), and Mateev et al. (63), documented the isolation of Br. suis from swine with doubtful or negative serologic tests.

It has been well established that Br. suis may invade almost any tissue of the body. In a very comprehensive study, Hutchings (40) listed the most common sites for recovery of Br. suis as lymph nodes, sex organs, spleen, liver, spinal cord, lungs, muscles, vertebrae, bone marrow, urine, urinary bladder, kidneys, and joints in that order of frequency. In a similar study, Manthei (61) listed lymph nodes, spleen, vertebral column, urogenital organs, and liver in that order. Other workers (36, 46, 47) found the spleen to be most often infected, lymph nodes frequently infected, and liver and kidneys less frequent sites of infection. On the basis of their bacteriologic findings, Johnson and Huddleson (46) expressed the opinion that

Brucella infection in swine is not essentially an abortion disease but is a disease chiefly of the lymphatic tissues.

Brucella suis is frequently isolated from the genital organs of infected boars (41, 50, 51, 61, 75). Work by Thomsen (75), Manthei (61), and DeKeyser et al. (18) indicates that among genital organs, the seminal vesicles are the primary sites of localization, with the prostate and epididymides being secondary in importance. Data by Thomsen (75) indicate that isolation of Br. suis, type 2 from the testes is rare. Hayes and Phipps (26) failed to isolate brucellae from the testes of 18 infected boars. However, Kernkamp et al. (50) isolated Br. suis from the testes of 14 out of 18 infected boars.

Only Hutchings (40) has reported the isolation of Brucella from the central nervous system of infected swine, in the absence of gross lesions.

Although extensive gross lesions caused by Br. suis in swine are uncommon, many such lesions have been described, especially in sex organs and bones. Gross changes in male genital organs have been described as: swelling or atrophy and fibrosis, along with abscessation, of testes and epididymides (9, 14, 41, 42, 50, 56, 60, 75); and necrosis, abscessation, and fibrosis of seminal vesicles (14, 60, 62,

75).

Spondylitis attributed to Brucella infection in swine has been studied by several workers. The earliest and most extensive work on this aspect of swine brucellosis was done by United States Department of Agriculture scientists (61, 78-81). During the years 1930-1933 nearly 200 specimens were examined by this group. Manthei (60) credited this early work to G. T. Creech. In general, the gross appearance of spondylitis has been described as focal necroses which vary from 0.5 cm to 3 cm in size. Occasionally there is exostosis involving the intervertebral cartilage and bodies of adjacent vertebrae. Feldman and Olson (22, 23) stated that the contents of these necrotic foci were caseous to semipurulent, occasionally containing a sequestrum of bone. Their data indicates that most of these lesions are situated in the lumbar vertebrae or lumbosacral articulation, originate in the vertebral epiphyses, and are of hematogenous origin. They estimated the incidence of gross spondylitis to be 1 per 6,000 swine slaughtered. Various combinations of pyemic bursitis, arthritis, or osteomyelitis associated with long bones of swine have been described (45, 53, 56, 75). Lowbeer (54) says that osteomyelitis occurs frequently in guinea pigs infected with Brucella. However, Braude (7) and

Braude and Anderson (8), after studying hundreds of guinea pigs experimentally infected with all species of Brucella, stated that gross deformities of bone were seldom seen.

Enlargement, softening, congestion, scarring, and focal necrosis are gross changes which have been described in lymph nodes affected by Br. suis (9, 46, 56, 60).

Necrotic foci have been observed in the liver, spleen, kidneys, subcutis, and various other body tissues of infected swine (1, 15, 16, 46, 51, 60, 75). Anderson and Davis (1) studied several cases of what they designated nodular splenitis and concluded that such a finding, in the absence of other lesions, justified a presumptive diagnosis of brucellosis. Manthei (60) stated that the frequency of occurrence of nodular splenitis is too low to be useful in diagnosing swine brucellosis.

In a review of fatal brucellosis in humans Peery and Belter (69) stated that there was some form of cardiac damage in 86% of such cases. Chronic valvular endocarditis, particularly affecting the aortic valve, was the most common lesion. Search of the literature has not revealed any evidence that carditis occurs in swine due to Brucella infection.

Most histopathologic studies of brucellosis in boars have been conducted on tissues bearing gross lesions, and of

these, the testes and osseous tissues have received the most attention. In the testes, necrotic foci, proliferation of interstitial tissue with infiltration of lymphocytes, histiocytes, eosinophils, and Langhan's giant cells, sloughing of germinal epithelium, small abscesses, fibrosis, and calcification of necrotic material have been described (9, 14, 42, 50). Similar alterations were observed in the epididymis by Brown et al. (9) and in epididymides and seminal vesicles by Christiansen and Thomsen (14).

Feldman and Olson (23) and Lowbeer (53, 54) described the histologic appearance of most osseous lesions as consisting of central caseous necrosis surrounded by epithelioid cells and usually a thick fibrous capsule, with many lymphoid, monocytic, and a few giant cells in the area. Braude (7) stated that although gross osseous deformities due to brucellosis seldom occur in guinea pigs, microscopic granulomas in the bone marrow are often present.

Anderson and Davis (1) and Brown et al. (9) described the microscopic appearance of nodular splenitis as: caseous centers surrounded by a narrow zone of cells consisting of epithelioid cells, small round cells, eosinophils, and an occasional giant cell. These lesions were encapsulated and were often undergoing mineralization. According to Braude

(7), in the absence of necrotic foci, one cannot accurately distinguish between spleens of normal and infected animals on the basis of microscopic study.

McNutt (56) observed that microscopic lesions in porcine lymph nodes, due to brucellosis, resemble those caused by a pyogenic infection. In affected nodes, there was a great increase in interstitial tissue and numerous areas between lymph follicles were heavily infiltrated by polymorphonuclear cells. Brown et al. (9) inoculated weanling pigs with multiple parenteral injections of massive doses of Br. suis over long periods of time. Under these conditions, the histopathologic alterations in lymph nodes consisted of: marked proliferation of reticuloendothelial cells with development into mature macrophages, the presence of multinucleated giant cells, marked infiltration of eosinophils, occasional foci of necrosis, followed by calcification, and replacement of the lymphoid structure by a dense reticular scar.

Focal granulomas or abscesses and diffuse periportal infiltrations have been described in the livers of infected swine (9) and guinea pigs (8). Diffuse interstitial cellular infiltrations in the renal cortex have been reported in bovines (68) and guinea pigs (8). Murgia (67) concluded that

Brucella has a predilection for the adrenals after he found congestion, hemorrhage, increased lipids, and interstitial inflammatory infiltrations consisting of neutrophils, lymphocytes, and histiocytes in the adrenal glands of infected guinea pigs.

An unexcelled description of the gross and microscopic lesions produced by Brucella abortus in guinea pigs was published by Fabyan (20) in 1912. He describes histopathologic alterations in the lymph nodes, spleen, liver, kidneys, adrenals, testes, epididymides, heart, lungs, salivary glands, thymus, bones, and joints. He stated that the alterations were chronic inflammatory changes, resembling those of tuberculosis. Lesions were small and occurred chiefly in perivascular areas with the focal lesion consisting of epithelioid cells admixed with some lymphoid cells. Plasma cells, giant cells, and occasionally neutrophils were seen in some cases. In more chronic cases, connective tissue proliferation was seen. In their work with brucellosis in guinea pigs, Braude (7) and Braude and Anderson (8) emphasized that Br. suis has a much greater tendency to produce widespread destructive abscesses than other species of Brucella.

Information on the evolution of histopathologic altera-



tions in Br. suis infected swine is limited. Delez et al. (19) injected soluble nucleoprotein fractions of Br. suis intracutaneously in swine and biopsied the tissue at sites of inoculation periodically thereafter. After 6 hours they observed hyperemia of the superficial cutis with slight infiltration by neutrophils. Within 24 hours the neutrophil infiltration was extensive, proliferative endarteritis was observed, and some areas contained many mononuclear cells. After 72 hours the cellular reaction had become predominantly mononuclear with some lymphocytes and eosinophils. The infiltration was primarily perivascular. Epithelioid cells and Langhan's giant cells were also beginning to appear as was necrosis of the surface epithelium. Marked edema was present at 24-72 hours. At 4-5 days after inoculation, the necrosis was more severe and eosinophils and giant cells were more prominent. After one week the reactions began to subside and by 17-23 days most had completely subsided.

According to Brown et al. (9) lesions in testes and epididymides of swine seem to develop in the following manner: Br. suis localizes in the interstitial tissue, then a granulomatous reaction develops and extends through the lining of the tubules, finally filling the lumen, the exudate becomes necrotic and the epithelium of the tubules is des-

troyed, necrosis is followed by mineralization and the appearance of giant cells, then the whole process heals, leaving a hyaline scar.

Braude and Anderson (8) described the sequence of events in the formation of hepatic granulomas due to Br. abortus in guinea pigs and mice. First, Brucella appeared in circulating neutrophils, then in neutrophils and Kupffer cells located in hepatic sinusoids. Following that, focal aggregations of parasitized Kupffer cells increased in size to form early granulomas which then fused to form larger lesions. Coagulative necrosis occurred in the center of granulomas, and Langhan's giant cells appeared in the vicinity. They reported that it took 3 months for full development of the granulomatous reaction after which there was gradual abatement. After a year granulomas had disappeared leaving no demonstrable scar. The same changes occurred in Br. suis infected laboratory animals, except there was continuing activity of neutrophils and abscess formation. These hepatic granulomas resulted from infection in the absence of hypersensitivity but the response to antigens by sensitized tissues were qualitatively the same.

In cows exposed to Br. abortus by the conjunctival route, Payne (68) concluded that the organisms penetrate the

conjunctival epithelium and proceed directly to local lymph nodes. He also pointed out that some of the organisms may drain into the pharynx via the lacrimal duct and penetrate the pharyngeal mucosa. Up to the 15th day in his experiment, histologic changes were confined to lymph nodes of the head. Afterwards, the infection spread to lymphoid tissue elsewhere and a mild acute lymphadenitis developed in each affected node. The predominant early change in lymphatic tissue was hyperplasia of the lymphoid tissue with large numbers of plasma cells in the medullary cords. Large numbers of neutrophils and eosinophils accumulated at the cortico-medullary junction and eventually there was some proliferation of reticuloendothelial cells.

Huddleson (32) made several statements pertaining to the role of certain host cells in bovine brucellosis.

Brucella are ingested by neutrophils soon after entering the body. The neutrophils serve to convey Brucella cells to various regions of the body rather than contributing to the defense mechanism of the host. The parasitized neutrophils rupture and pass the bacteria to other leucocytes or fixed tissue cells, especially epithelium. Epithelial cells furnish the most suitable environment for the multiplication and persistence of Brucella cells in the host. The monocyte plays an important role in preventing and controlling the spread of Brucella cells in the host.

## METHOD OF PROCEDURE

## Boars

Sixteen Yorkshire boars were utilized. These boars originated from a herd which has been maintained as a brucellosis-free closed herd. Seven 24-25 week old boars were exposed to Br. suis, type 1, strain 3b. One boar was killed at each of the following postexposure intervals: 1 week, 2 weeks, 3 weeks, 4 weeks, 6 weeks, 8 weeks, and 12 weeks. Seven other 25-27 week old boars were exposed to Br. suis, type 3, strain 617 and killed at the same postexposure intervals. The remaining two boars were used as unexposed controls.

The boars were maintained in isolation units within a closed large animal experimental animal building from 2 weeks pre-exposure until they were killed. The boars in each group were maintained in a pen together unless excessive fighting occurred, then troublemakers were removed to separate pens. All boars were fed the same pelleted, balanced ration. The pens were cleaned and boars fed and watered twice a day.

Line breeding has been the usual practice in the herd from which these boars originated. The genetic relationship, times of necropsy, and exposure strain for boars utilized in

this experiment are outlined in Table 1.

Table 1. Genetic relationship of boars, times of necropsy, and strain of Brucella suis used in the experiment

Sire No.	Dam No.	Progeny		
		Boar No.	Exposure strain	Necropsy (week postexposure)
2083	2055	2664	unexposed control	0
2083	2055	2663	strain 3b	1
2083	2055	2661	strain 3b	2
2083	2055	2660	strain 3b	3
2083	2066	2790	strain 617	1
2083	2066	2791	strain 617	2
2083	2066	2792	strain 617	3
2083	2066	2793	strain 617	4
2083	2066	2794	strain 617	6
1098	1264	2633	strain 3b	4
1098	1264	2632	strain 3b	6
1098	1264	2631	strain 3b	8
1098	1264	2630	strain 3b	12
1098	1132	2840	strain 617	8
1098	1132	2842	strain 617	12
1098	1205	2850	unexposed control	10

Each boar was exposed by dropping 0.05 ml. of a suspension of Br. suis into the conjunctival sac of each eye, then holding the eyelids shut and massaging the eye for 2-3 minutes. A 0.5 ml. syringe with a blunt-pointed 24 gauge needle was used to dispense the bacterial suspension.

#### Exposure Cultures

Strain 3b was chosen as a representative strain of Br. suis, type 1. This strain has been used in numerous previous experiments by Manthei et al. (62). It was originally obtained from aborted fetuses of a sow which had been exposed to a polyvalent suspension of three strains of Br. suis. The three strains had previously been isolated from boars originating from three sources. Brucella suis, type 1, strain 3b has been stocked as a lyophilized culture since 1942.

Strain 617 was chosen as a representative of Br. suis, type 3. This strain was isolated from one of the experimental swine in experiments conducted by Hoerlein (29). It has been maintained in a lyophilized state since its isolation.

To be certain that the above strains were true to type, and remained so, the following differential tests were

conducted on a sample of every transfer: basic fuchsin, thionin, and safranin O sensitivity; erythritol sensitivity; agglutination of monospecific serum; brucellaphage sensitivity; H<sub>2</sub>S, urease, and catalase production; nitrate reduction; carbohydrate fermentation; and colonial and cellular morphology. Both strains consistently produced large quantities of urease and catalase; reduced nitrates to nitrites; fermented dextrose, maltose, sucrose, trehalose, and mannose, but not lactose, inositol, or rhamnose; agglutinated anti-abortus monospecific serum but not anti-melitensis monospecific serum; were not inhibited by erythritol; were not lysed by brucellaphage; and both grew on thionin concentrations as high as 40 mg./liter of medium. Strain 3b was consistently inhibited by basic fuchsin and safranin O and produced large quantities of H<sub>2</sub>S for 4 days or more. Strain 617 produced no detectable H<sub>2</sub>S but grew well on safranin O and 10 mg./liter or less of basic fuchsin.

The guinea pig virulence of the exposure strains was determined by using fifty, 450-500 gram, male guinea pigs to titrate each strain. For each Br. suis strain the guinea pigs were divided into groups of 5 guinea pigs each, weighed, and inoculated subcutaneously with the following dose for each group:  $10^{0.5}$ ,  $10^1$ ,  $10^{1.5}$ ,  $10^2$ ,  $10^{2.5}$ ,  $10^3$ ,  $10^4$ ,  $10^6$ ,

$10^8$ , and  $10^{10}$  viable organisms. Twenty-eight days postinoculation the guinea pigs were weighed, bled, killed, and necropsies were performed. Serum agglutination tests were conducted and spleens were examined bacteriologically for the presence of Br. suis. All guinea pigs given  $10^{10}$  viable organisms of each Br. suis strain died within two weeks postinoculation. Guinea pigs infected with Br. suis, type 1, strain 3b lost an average of 38 Gm. body weight, those infected with Br. suis, type 3, strain 617 gained an average of 12 Gm., and the noninfected ones gained an average of 106 Gm. during the 28 day period. Gross lesions were observed in the spleen, liver, and genital organs of 94%, 51%, and 54% of the guinea pigs infected with strain 3b, while lesions were observed in the same organs of 82%, 72%, and 12% of the guinea pigs infected with strain 617. The median serum agglutinin titer of guinea pigs infected with strain 3b was 800 while that of guinea pigs infected with strain 617 was 200. Using isolation of Brucella from the spleen as the criterion for infection, the infective dose for 50% of the guinea pigs was approximately 13 viable Br. suis, strain 3b organisms or approximately 16 viable Br. suis, strain 617 organisms.

Preparation of exposure suspensions was initiated by



reconstituting lyophilized cultures with sterile 1% peptone-saline, distributing this material on potato infusion agar (76), then incubating it for 3-5 days at 37°C. From this growth, colonies representative of the smooth phase were selected and transferred to additional plates of the same medium. Again, several smooth colonies were selected from the last transfer and emulsified in sterile physiological saline, then 1 ml. of the emulsion was used to inoculate each of several slants of potato infusion agar in cotton-stoppered 29 x 200 mm. tubes. The slants were incubated for 44 hours at 37°C. Then the bacterial growth was washed off the slants with sterile physiological saline, appropriate dilutions made, and absorbancy of the suspensions measured.<sup>1</sup> By the use of previously determined absorbancy-cell concentration ratios, it was possible to adjust the suspensions to near the desired cell concentration. Suspensions of both strains of Br. suis were adjusted to contain approximately  $1.25 \times 10^{11}$  viable cells/ml. Aliquots of the suspensions were withdrawn for differential tests and viability counts both before and after exposing the boars. The boars were

---

<sup>1</sup>Spectronic 20 Colorimeter, Bausch and Lomb, Inc., Rochester, New York.

exposed within 2 hours after each Br. suis strain was harvested. Viability counts on potato infusion agar plates provided the opportunity to check for contamination and observe the colonial characteristics.

As a result of the viability counts, the exposure dose/boar of Br. suis, type 1, strain 3b, was determined to be  $1.28 \times 10^{10}$  viable organisms of a pure culture in the smooth phase. Boars exposed to Br. suis, type 3, strain 617, each received a pure culture of  $1.24 \times 10^{10}$  viable organisms in the smooth phase.

#### Clinical Observations

Rectal temperatures of all boars were taken twice a day from 2 days pre-exposure to 10 days postexposure. Thereafter, temperatures were taken daily until 5 weeks postexposure. If a boar showed signs of illness, his temperature was taken twice a day until it subsided to a normal range or signs of illness disappeared. The boars were observed for clinical signs of brucellosis twice daily throughout the experiment.

#### Serologic Examinations

Blood samples were obtained from all boars at 2 weeks pre-exposure and 1 day pre-exposure, 3 times a week for 3

weeks postexposure, then twice a week for the next 3 weeks, and weekly thereafter. The boars were bled from the anterior vena cava using a 15 gauge, 3-1/2 inch needle with a 50 ml. syringe. The bleeding procedure was patterned after methods described by Carle and Dewhirst (12) and Hoerlein et al. (30). Approximately 50 ml. of blood was obtained aseptically at each bleeding, with approximately 20 ml. being saved for the serum. The remainder was used for hemoculture.

Standard tube and plate agglutination tests (76) were conducted on all serums in order to follow the serologic response of the boars to Br. suis. Tube agglutination tests on pre-exposure and early postexposure serums were conducted at dilutions as low as 1:6.25 and all tube tests were conducted at sufficiently high dilutions to establish the end-point titer.

Fluid or exudate was withdrawn from the seminal vesicles at the time of necropsy. This material was centrifuged to sediment cellular or particulate matter and the supernatant fluid was tested by standard tube and plate agglutination tests.

## Bacteriologic Examinations

All bacteriologic examinations of tissues, fluids, and hemocultures were conducted using solid media in petri dishes. For bacterial isolation purposes potato infusion agar (76) was fortified with bovine serum (7% final concentration). A modified "W-medium," designed for the isolation of Brucella from contaminated materials, was also used routinely. The original formula prescribed by Kuzdas and Morse (52) was modified in the following way: Tryptose agar<sup>1</sup> was used as a base rather than Albimi Brucella agar, Circulin<sup>R</sup> was not incorporated because it is no longer manufactured, the crystal violet was replaced with the less toxic ethyl violet (1:700,000 final conc.), and the medium was fortified with 7% bovine serum. After media were inoculated, the plates were placed in museum jars, 5% (v/v) CO<sub>2</sub> added, and the jars sealed and incubated at 37°C for a maximum of 7 days.

Each time a blood sample was obtained from a boar, approximately 15 ml. of it was aseptically placed in each of

---

<sup>1</sup>Difco Laboratories, Detroit, Michigan.

two bottles containing 50 ml. of citrated trypticase-soy<sup>1</sup> broth. The bottles were sealed and placed in a 37°C incubator. After 48-72 hours and again after 7 days, one ml. of the hemoculture material was removed and subcultured on plates of both solid media. After 3-5 days incubation, the plates were observed for the presence of Brucella. Hemoculture bottles from which Br. suis had been isolated were discarded, but those which did not contain detectable numbers of Br. suis were retained and subcultured again 2-3 weeks later.

At the time of necropsy, samples of the following tissues or fluids from the different anatomic systems (71) were saved and examined bacteriologically for the presence of Br. suis:

- a) Lymphatic system--retropharyngeal, parotid, mandibular, cervical, prescapular, bronchial, sternal, mediastinal, gastrohepatic, splenic, mesenteric, lumbar, prefemoral, superficial and deep inguinal, iliac, and popliteal lymph nodes. Bilateral nodes were pooled and examined as one.
- b) Urogenital system--kidneys, urine, adrenals, testes,

---

<sup>1</sup>Baltimore Biological Laboratory, Baltimore, Maryland.

head and tail of epididymides, seminal vesicles, seminal vesicle fluid, prostate, pelvic urethra, bulbo-urethral glands, serous fluid of the tunica vaginalis.

- c) Digestive system--mandibular salivary glands, tonsils, spleen, liver, bile, pancreas, and peritoneal fluid.
- d) Respiratory system--lungs, thymus, and thyroid gland.
- e) Musculoskeletal system--skeletal muscle (psoas and semimembranosus), joint fluid, bone marrow (from diaphysis of tibia).
- f) Other--brain, myocardium, pericardial fluid, and any other tissue with gross lesions.

Fluids were cultured by placing 0.2 ml. on each of several petri plates of media and spreading it over the surface with a triangular wire spreader. Tissues were cultured by searing the surface of the tissue with a hot spatula, entering the tissue with a flame-sterilized wire loop, homogenizing the tissue as much as possible with the loop, withdrawing a loopful of material, and streaking it on the surface of the media. Care was taken to sample each tissue in several locations, especially with large organs such as testes, spleen, liver, lung, brain, kidneys, and

muscles, and with each portion of aggregated lymph nodes.

In most instances, Br. suis colonies that grew on the media were identified by their morphologic characteristics. In cases where the identity of a colony was questionable, it was checked for urease and catalase production, gram reaction, cellular morphology, and agglutination of Brucella antiserum. Brucella suis isolated from at least one tissue of each boar was examined by the use of previously described differential tests.

All tissues were held at 4°C as much as was practicable until bacteriologic examinations of them were completed. In case no Br. suis was isolated by direct culture of tissues from a boar, all lymph nodes from that particular boar were pooled and homogenized. This lymph node homogenate was injected subcutaneously into 5 guinea pigs. The guinea pigs were held for 28 days and examined for any serologic, bacteriologic, or gross pathologic evidence of Brucella infection.

#### Pathologic Examinations

When the day scheduled for necropsy of a boar arrived he was killed by electrocution, and the necropsy performed immediately. During the necropsy, organs of the head, neck,

thorax, abdomen, and pelvic area were examined in that order. The post-mortem examination was concluded by inspecting joints and splitting the carcass through the vertebral column. Tissues for bacteriologic and histopathologic examination were removed at the time of the gross examination and placed in sterile containers or fixative, respectively.

Samples of all tissues saved for bacteriologic examination were also examined histopathologically. In addition, portions of the following tissues were taken for histopathologic examination alone:

- a) Urogenital system--urinary bladder, prepuce, penis, and ductus deferens.
- b) Digestive system--root of tongue, esophagus, stomach (esophageal, cardiac, fundic, and pyloric portions), duodenum, jejunum, ileum, Peyer's patch, ileocecal valve, cecum, colon, rectum, and gall bladder.
- c) Respiratory system--nasal turbinates, epiglottis, and trachea.
- d) Musculoskeletal system--tibio-tarsal joint (including distal epiphysis of tibia) and the 6th lumbar vertebra.
- e) Central nervous system--brain (upper and lower medulla, cerebellum, pons, midbrain, thalamus, basal



ganglia, and cerebral cortex), pituitary gland, and lumbar spinal cord.

- f) Other--eye, conjunctiva, and atrio-ventricular valve of heart.

This ultimately resulted in histopathologic examination of 87-104 different tissue samples from each boar. The average breakdown by systems was central nervous system--11, lymphatic--20, digestive--24, respiratory--7, urogenital--25, other--8.

The tissue fixative used was 25% formalin in tap water for the central nervous system and 10% formalin for all other tissues. Bones were decalcified by placing them in three weekly changes of 30% formic acid. Tissues were infiltrated by use of an Autotechnicon<sup>1</sup>, using Paraplast<sup>2</sup> as an infiltrating and embedding material. Sections were cut 8 microns thick with a rotary microtome<sup>3</sup> and affixed to glass slides. All sections were stained in an Autotechnicon with Mayer's

---

<sup>1</sup>Autotechnicon, The Technicon Company, Chauncey, New York.

<sup>2</sup>Aloe Scientific Co., 3501 Raleigh Ave., So. Minneapolis, Minnesota.

<sup>3</sup>Model 820, American Optical Company, Buffalo, New York.

hematoxylin and alcoholic eosin, according to staining procedures described by the Armed Forces Institute of Pathology (3).

## RESULTS

## Clinical Observations

Clinical signs of illness were exhibited by approximately half the boars following exposure to Br. suis. The clinical manifestations were divisible into earlier and later signs (Table 2). Five of 7 boars exposed to Br. suis, type 1, strain 3b exhibited clinical signs, whereas only two of 7 boars exposed to Br. suis, type 3, strain 617 showed clinical signs of illness.

Earlier signs consisted of short periods of fever, occasionally accompanied by partial anorexia. Pyrexia was considered to be present only when the rectal temperature was greater than 103.2°F., which was 1°F. higher than the average "normal" evening finding.

Later signs were more severe and occurred 10 days or longer after exposure. Prolonged periods of fever were accompanied by complete anorexia and depression. The three boars (2633, 2632, and 2794) which exhibited the most severe clinical signs also had gross lesions in their seminal vesicles. Of the boars showing later clinical signs only one (2632) had a detectable brucellemia during the time the signs were occurring.

Table 2. Clinical response of boars showing signs of illness after exposure to Brucella suis, type 1, strain 3b or Brucella suis, type 3, strain 617

Boar	Exposure strain	Earlier signs			Later signs			Other signs
		Days Persisted	Fever Maximum temp. (F°)	Day <sup>a</sup>	Days persisted	Fever Maximum temp. (F°)	Day <sup>a</sup>	
2661	3b	2	103.6	9	None		None	
2633	3b	1	104.0	8	6	106.0	20	Muscular tremors, anorexia, polydipsia, weight loss, depression, weakness
2632	3b	1/2 3	104.0 103.8	6 9	7	105.2	19	Anorexia (partial to complete), depression, weakness
2631	3b	1	105.8	4	None		Partial anorexia (day 12 to 17)	
2630	3b	1/2	104.6	2	None		None	
2793	617	1/2	104.2	2	3	105.2	20	Depression
2794	617	None			4	106.2	24	Anorexia, depression, weight loss

<sup>a</sup>Postexposure day on which the maximum rectal temperature occurred.

Two boars (2792 and 2793) developed short periods of lameness during the first week postexposure. Since they could have been injured while fighting with other boars, this was not considered a significant sign of brucellosis.

All 14 boars had excessive lacrimation soon after the conjunctival exposure and it was still present in some animals the following day, but no longer.

#### Serologic Examinations

All pre-exposure serums from all boars were negative for Brucella agglutinins at the 1:12.5 dilution. About one week after exposure, serum agglutinin titers began to rise, then increased rapidly to a peak, after which they receded gradually. Five of the 6 boars which were killed later than 4 weeks postexposure had a distinct rise in their serum agglutinin titers again at about 35 days postexposure. Titers in serums from boars exposed to Br. suis, strain 3b were considerably higher than those from boars exposed to Br. suis, strain 617 (Table 3).

All boars, except those killed at one week postexposure, had serum agglutinin titers greater than 100 at some time during the course of the disease. However, the titer of boar 2840 had receded to 25 by the time of necropsy. Boar

Table 3. Serum agglutinin titer response in boars exposed to Brucella suis, type 1, strain 3b or Brucella suis, type 3, strain 617

Exposure	Initial titer rise (Days postexposure)		Peak titer (Days postexposure)		Peak titer (range)	Median titer <sup>a</sup>
	Range	Mean	Range	Mean		
Strain 3b	6-8	6.6	10-15	11	400 to 1600	400
Strain 617	7-11	9.0	13-17	14	200 to 400	100

<sup>a</sup>Includes all serums with agglutinin titer higher than 12.5.

2630 had a serum agglutinin titer of 400 at necropsy but Br. suis was not isolated from his tissues.

Brucella agglutinins were present at a titer of 50 in fluids from each lobe of the seminal vesicles of boar 2633. Agglutinins were present in a titer of 200 in fluids from each lobe of the seminal vesicles of boar 2632. In boar 2794 seminal fluid from the right lobe had a titer of 800 while that from the left lobe was negative at the 1:25 dilution. The results of the standard agglutination test were positive only on fluids from those lobes of seminal vesicles which had severe gross lesions.

## Bacteriologic Examinations

Once the presence of Br. suis was detected in the blood stream, it was usually present in several consecutive blood samples, then absent in all subsequent samples. However, there were two exceptions. Brucella suis, type 1, strain 3b was present in blood samples from boar 2632 on days 6 through 17, 24, and 38, but not on days 21, 28, 31, and 35. Blood samples from boar 2842 collected on days 7 through 21, 28, and 35 contained Br. suis, type 3, strain 617, but those collected on days 24 and 31 did not. In general, the organisms persisted longer in the blood stream of boars infected with Br. suis, type 1, strain 3b than in the blood stream of boars infected with Br. suis, type 3, strain 617 (Table 4).

At necropsy Br. suis was isolated most frequently from lymph nodes and urogenital tissues. The infection was most widely disseminated in the body between 2 and 6 weeks post-exposure (Table 5).

Among lymph nodes, the best sources of both types of Br. suis were the suprapharyngeal, parotid, mandibular, cervical, gastrohepatic, deep inguinal, and iliac nodes. The organism was recovered from the suprapharyngeal, mandibular, and gastroheptic nodes of more than 60% of the infected boars.

Table 4. First appearance and persistence of brucellemia in boars exposed to Brucella suis, type 1, strain 3b or Brucella suis, type 3, strain 617

Exposure	First appearance (Days postexposure)		Persistence <sup>a</sup> (Days)	
	Range	Mean	Range	Mean
Strain 3b	6	6.0	15-36	23.2
Strain 617	6-9	6.9	8-31	17.6

<sup>a</sup>Excluding boars killed at 1 and 2 weeks postexposure.

Table 5. Distribution of Brucella suis isolations from tissues of boars at necropsy

	Week postexposure							Total
	1	2	3	4	6	8	12	
<u>Br. suis</u> , type 1, strain 3b								
Lymph nodes (18) <sup>a</sup>	3	18	17	9	5	2	0	54
Urogenital tissues (18)	0	3	0	10	5	1	0	19
Other tissues (20)	1	3	1	1	0	1	0	7
<u>Br. suis</u> , type 3, strain 617								
Lymph nodes (18)	3	15	17	17	8	2	0	62
Urogenital tissues (18)	0	0	0	1	4	0	0	5
Other tissues (20)	0	4	4	0	0	0	0	8
Total	7	43	39	38	22	6	0	

<sup>a</sup>Numbers in parentheses indicate average number of different organs examined from each boar.



As a group, the external nodes (prescapular, superficial inguinal, prefemoral, and popliteal) were the poorest sources of Br. suis.

In boars killed at one week postexposure, isolations were confined primarily to lymph nodes of the head. Thereafter, Br. suis was recovered from all areas, but most often from lymph nodes of the head and neck, pelvic lymph nodes, or gastrohepatic lymph nodes. An important feature of lymph node infection was that Br. suis was recovered from some parts of a single node or aggregate, but not from other parts.

Brucella suis was recovered from the genital system of four boars infected with strain 3b and from two boars (2793 and 2794) infected with strain 617 (Table 6).

Brucella suis was recovered from the bladder urine of boars 2633, 2632, and 2794. Brucella suis was also recovered from serous fluid of the tunica vaginalis of the left testis of boar 2633. The organism was never isolated from the testes of any boar.

Brucella suis, type 1, strain 3b was isolated from the lungs of boar 2663, from the spleen, liver, lungs, and mandibular salivary gland of boar 2661, and from the liver of boar 2660. Brucella suis, type 3, strain 617 was isolated

Table 6. Distribution of Brucella suis in genital organs of infected boars<sup>a</sup>

Organ	Boar and (week killed)					
	2661(2)	2633(4)	2632(6)	2631(8)	2793(4)	2794(6)
R. seminal vesicle	+	+	+	-	-	+
L. seminal vesicle	+	+	+	-	-	-
Prostate	+	+	+	-	-	-
Pelvic urethra	-	+	+	-	-	+
R. bulbo-urethral	-	+	-	-	-	-
L. bulbo-urethral	-	+	-	+	-	-
R. epididymis	-	+	-	-	+	+
L. epididymis	-	+	-	-	-	-

<sup>a</sup>+ = Br. suis isolated, - = not isolated.

from the spleen, liver, lungs, and thymus of boar 2791 and from the spleen, liver, mandibular salivary gland, and tonsils of boar 2792. Neither type of Br. suis was isolated from any of these organs in boars killed later than 3 weeks post-exposure. A subcutaneous abscess was present in the antero-

lateral cervical region of boar 2631. Brucella suis, type 1 was recovered from this abscess along with another organism tentatively identified as Corynebacterium sp. Brucella suis, type 1 was recovered from joint fluid of the right tibio-tarsal articulation of boar 2633.

Brucella suis was not recovered from boars 2630 and 2842, both killed at 12 weeks postexposure, either by direct cultural techniques or by guinea pig inoculation.

The results of differential tests on isolates from each boar were identical to results of tests on the culture used to expose that particular boar.

#### Pathologic Examinations

Gross pathologic changes attributable to both types of Br. suis infection were primarily limited to seminal vesicles and their regional lymph nodes. In boar 2633 there was a large sac, approximately 10 cm. in diameter, distended with purulent material which originated from the right seminal vesicle. The remainder of the seminal vesicles was smaller than usual and firm. The color was yellowish instead of the usual bluish-red. Upon cutting into these organs purulent material exuded from numerous focal points. The seminal vesicles of boar 2632 had a similar appearance, except no

large abscess was present and the purulent material was mixed with blood. Only the right seminal vesicle of boar 2794 was affected grossly and its appearance was similar to the left seminal vesicle of boar 2633. Either the deep inguinal or internal iliac lymph nodes were grossly affected in these boars. The pathologic nodes were greatly enlarged, yellowish in color, and firmer than usual.

The prostate gland of boar 2633 contained purulent material. The head of the right epididymis of boar 2794 contained a small abscess. An unusual nodule was present in an epididymis of boar 2792. It proved to be an aberrant lymph node upon microscopic examination. Some of the mediastinal lymph nodes from boar 2842 were markedly enlarged and soft although repeated attempts to isolate Brucella failed.

No gross lesions were observed in vertebrae or long bones at necropsy. However, upon subdivision of tissues prior to infiltration and embedding, a caseous focus, 7-8 mm. in diameter, was observed in the distal metaphysis of the right tibia of boar 2792.

Histopathologic alterations in tissues from infected boars were determined by comparison with like tissues from the unexposed control boars. Microscopic alterations were observed most frequently in lymph nodes, livers, and

accessory genital glands of infected boars (Table 7).

Table 7. Distribution of histopathologic changes in tissues of infected boars



Tissue	Sections examined (No.)	Sections with lesions (%)	Boars affected (No.)	(%)
Lymph nodes	269	31.6	14	100.0
Liver	47	31.9	8	57.1
Accessory genital glands	122	23.0	5	35.7
Bones	42	9.5	4	28.6
Genital organs (other than accessory glands)	178	2.2	4	28.6
Other	660	0.8	4	28.6

One of the common changes observed in lymph nodes was small collections of macrophages with a somewhat circular arrangement (Figure 1), usually located in lymphatic areas of the nodes. Sometimes cells in the centers of these foci were undergoing coagulative necrosis and often there were neutrophils infiltrating the foci (Figure 2).

Many times the only definite sign of reaction in a lymph node was the appearance of multinucleated giant cells. They were usually few in number but occasionally were numerous

Figure 1. Focus of macrophages in a mandibular lymph node from boar 2792. A giant cell is forming in the center of the lesion. Hematoxylin and eosin stain, X 125.

Figure 2. Focus of macrophages in a parotid lymph node from boar 2791. Some of the macrophages are undergoing coagulative necrosis and neutrophils are infiltrating the area. Hematoxylin and eosin stain, X 250.



(Figure 3). The majority of these giant cells were located near the trabeculae in the reticular substance. Usually there was proliferation of reticuloendothelial cells in the same area.

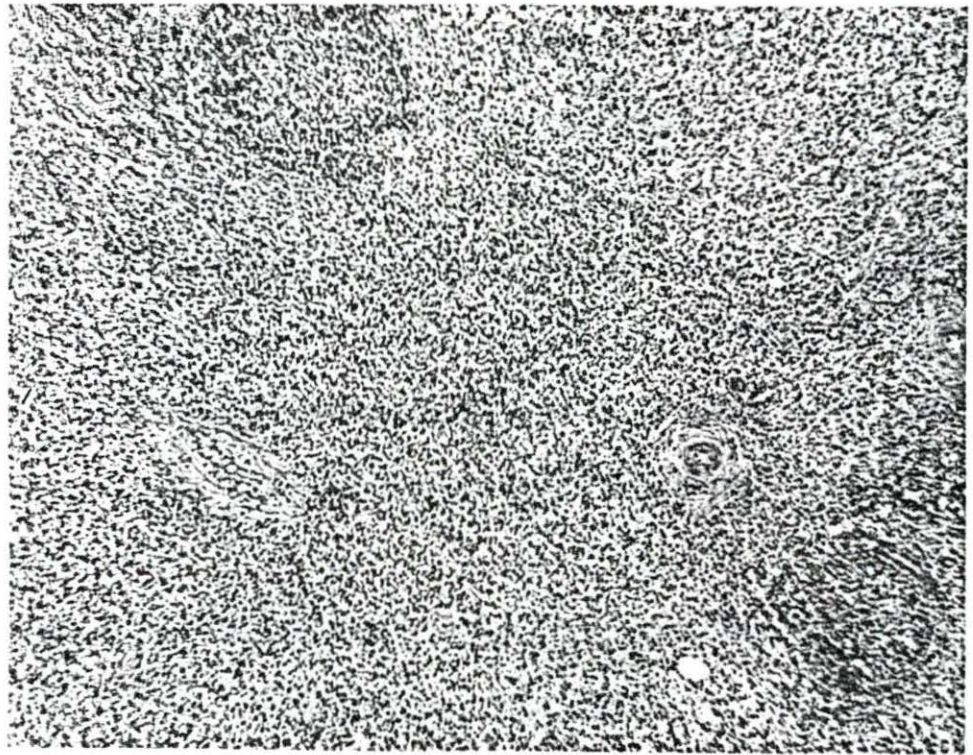
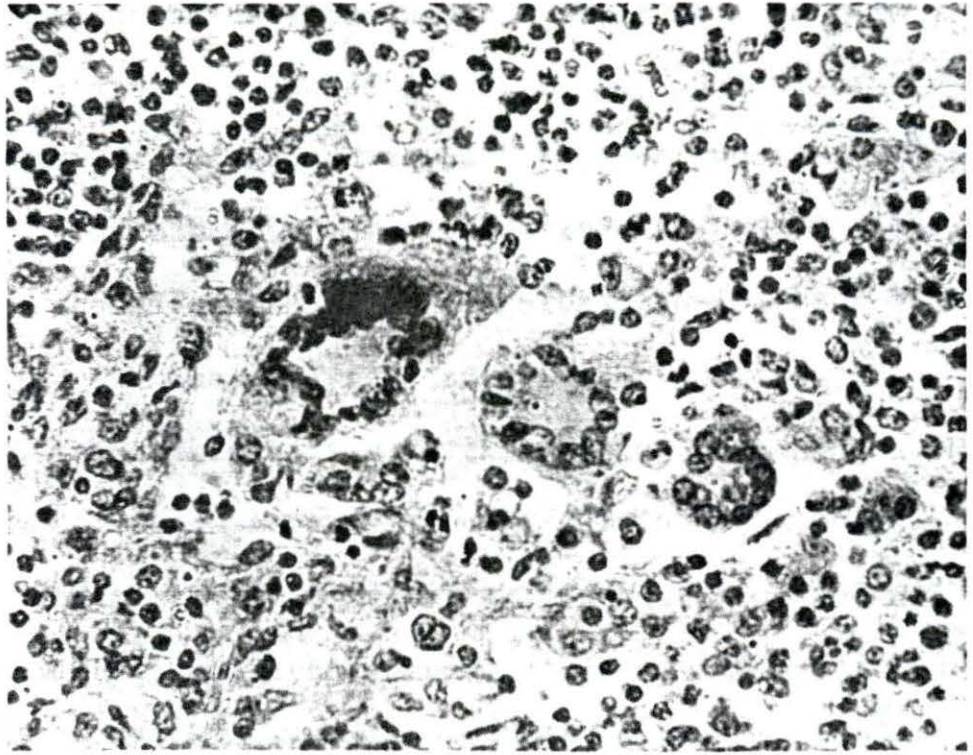
Occasionally there was a marked diffuse proliferation of the reticular tissue. In these areas only a few germinal centers remained, the lymphoid tissue being replaced by the proliferating reticuloendothelial tissue (Figure 4). This reaction was most commonly observed in grossly enlarged lymph nodes which were regional to severely affected seminal vesicles. In a few of these nodes there were also foci of caseous or liquefactive necrosis surrounded by macrophages and giant cells (Figure 5).

Suppurative reactions occurred in some lymph nodes but estimation of the frequency of this change was complicated by the occurrence of hemopoietic centers in the same tissue. Hemopoietic centers were present in lymph nodes of both control and infected boars. One group of five boars, which were progeny of sire 2083 and dam 2066, had these centers in 30-50% of their lymph nodes. However, hemopoietic centers were never present in more than 25% of the lymph nodes from other boars. The hemopoietic centers were characterized by the presence of immature neutrophils and eosinophils, stem



Figure 3. Giant cells and reticuloendothelial hyperplasia in an internal iliac lymph node from boar 2632. Hematoxylin and eosin stain, X 450.

Figure 4. Diffuse reticuloendothelial hyperplasia in the deep inguinal lymph node from boar 2794. Few lymphocytes are present surrounding the sparsely distributed germinal centers. Hematoxylin and eosin stain, X 45.




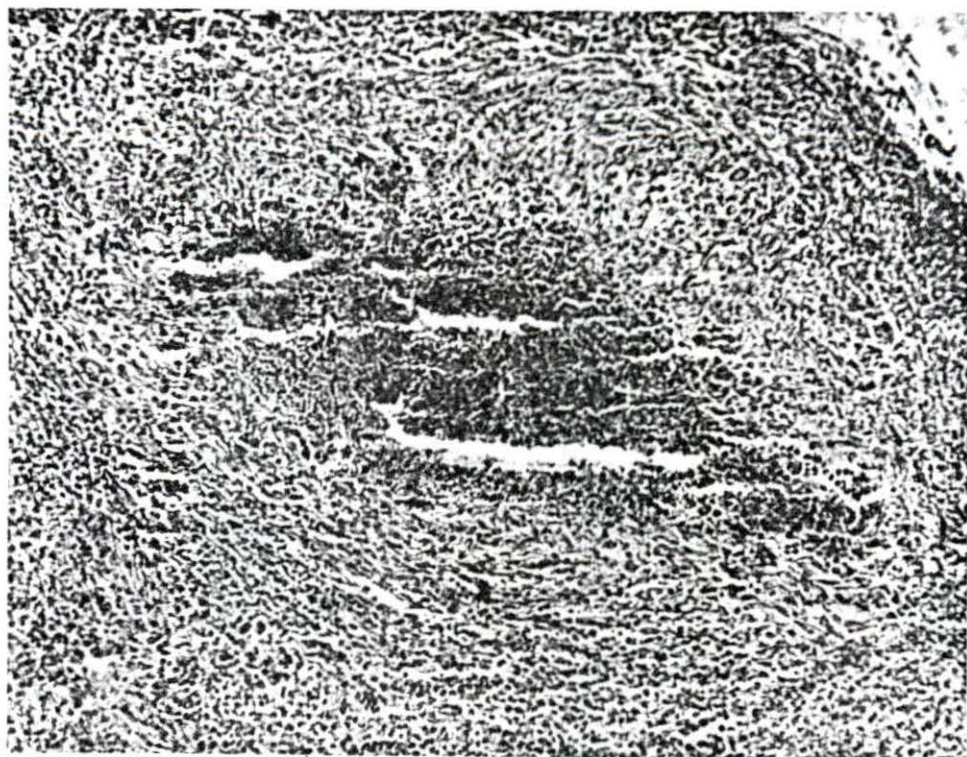
cells, megakaryocytes, and mature neutrophils and erythrocytes in a definite focus. The presence of neutrophils in a lymph node was considered to be a suppurative reaction only when all neutrophils present were mature and when no other cellular constituents indicative of a hemopoietic center were present in the area. A suppurative lymphadenitis was not found at any specific time in the postexposure period, but was more common in boars killed at 2 to 4 weeks. The distribution of most suppurative reactions within a node was diffuse with small focal accumulations (Figure 6).

Hyperplasia of the lymphoid elements in nodes from infected boars was occasionally observed. This was somewhat difficult to assess because of the marked variation in the normal amount of lymphatic tissue in nodes from different locations in the body of swine. However, a few nodes contained rather definite areas of lymphoid hyperplasia. This was characterized by overflowing of lymphocytes into the sinuses, enlargement of and increase in number of germinal centers, and increased mitotic figures within the germinal centers.

Large numbers of diffusely distributed eosinophils were present in all lymphoid tissues from both control and infected boars. The cause or significance of this tissue

Figure 5. Necrotic focus in a parotid lymph node from boar 2632. The caseous center is surrounded by macrophages and lymphoid cells with an outer zone of young fibrous connective tissue. Hematoxylin and eosin stain, X 125.

Figure 6. Suppurative focus in a hepatic lymph node from boar 2633. The predominant cells in the area are neutrophils. Hematoxylin and eosin stain, X 800.



eosinophilia has not been determined.

Occasionally more than one type of reaction was observed in a single lymph node. Histopathologic changes in lymph nodes occurred less often than isolation of Br. suis from the same groups of nodes. They were observed frequently in lymph nodes from boars killed at 2 to 6 weeks but were few in ones killed at 1, 8, and 12 weeks. Although it was not possible to examine exactly the same tissue with both bacteriologic and histologic techniques, the correlation between results of the two was 70%.

More histopathologic alterations in lymph nodes resulted from exposure to Br. suis type 1, strain 3b than did exposure to Br. suis, type 3, strain 617. Focal collections of macrophages or hyperplasia of reticuloendothelial tissues were observed in 35.0% and 24.6%, suppurative reactions in 5.8% and 4.0%, and lymphoid hyperplasia in 4.2% and 2.4% of the nodes examined. Qualitatively, the reactions caused by the two exposure strains were similar.

Microscopic lesions in the liver occurred almost entirely in those boars killed at 2 and 3 weeks postexposure. Lesions were rare in boars killed at 4 and 6 weeks and were not observed in livers of others. The lesions were focal and located at or near the edge of lobules. Macrophages and

lymphocytes were consistently present in these foci (Figure 7). Hyperemia was usually present, and occasionally there were also giant cells and neutrophils. Caseous necrosis occurred in the center of many of the larger foci and neutrophils had infiltrated the area (Figure 8). Infiltration of portal triads and interlobular tissue by macrophages and lymphocytes was observed occasionally (Figure 9). Because of the abundance of connective tissue already present in the livers it was impossible to determine whether the focal reactions had healed, leaving a scar. In general, the focal reactions were more numerous in liver sections from boars infected with Br. suis, type 1, strain 3b than with Br. suis, type 3, strain 617.

The most severe histopathologic alterations observed in any tissue occurred in the seminal vesicles of boars 2633, 2632, and 2794. The reaction was diffuse and was characterized by the presence of many lymphocytes, macrophages, plasma cells, some eosinophils and neutrophils, a few giant cells, and a marked increase of fibrous connective tissue in the interstitial tissue (Figure 10). The tissue proliferation in the affected glands had compressed and even obliterated most of the ducts. In many areas the epithelium had undergone coagulative necrosis or had sloughed (Figure 11).

Figure 7. Inflammatory focus near the periphery of a lobule in the liver of boar 2661. Cellular components of the focus consists of lymphocytes, macrophages, and a giant cell. Hematoxylin and eosin stain, X 125.

Figure 8. Necrotic focus in the liver from boar 2791. The center of the lesion is composed of coagulative to caseous necrotic cells with several neutrophils infiltrating the area. The outer zone consists primarily of macrophages and lymphocytes. Hematoxylin and eosin stain, X 250.




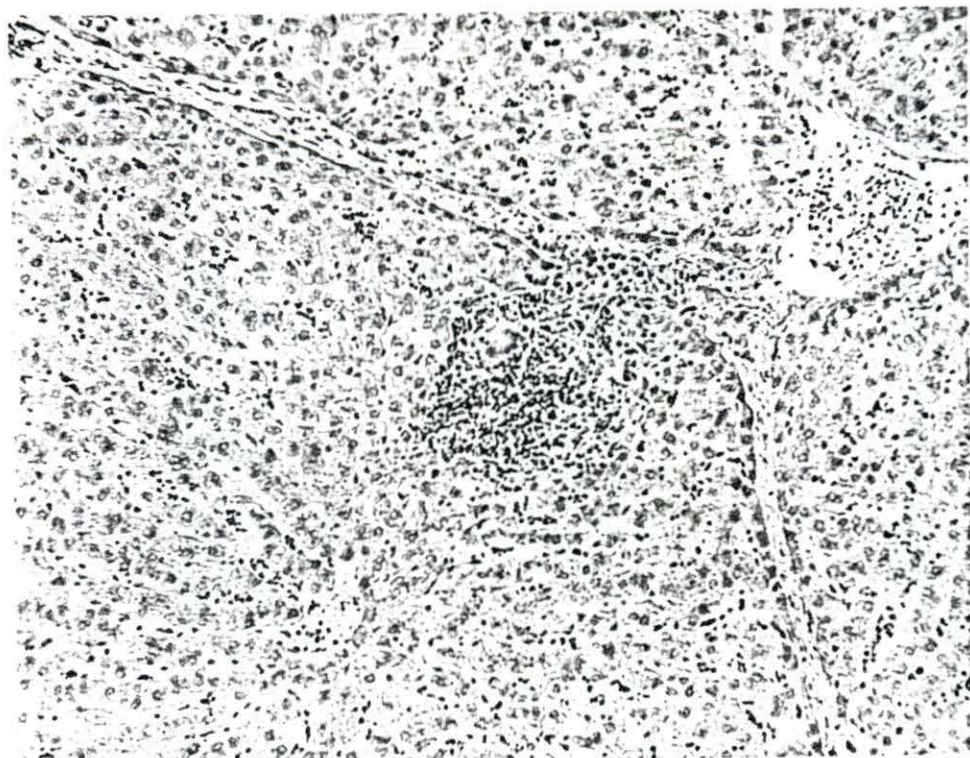
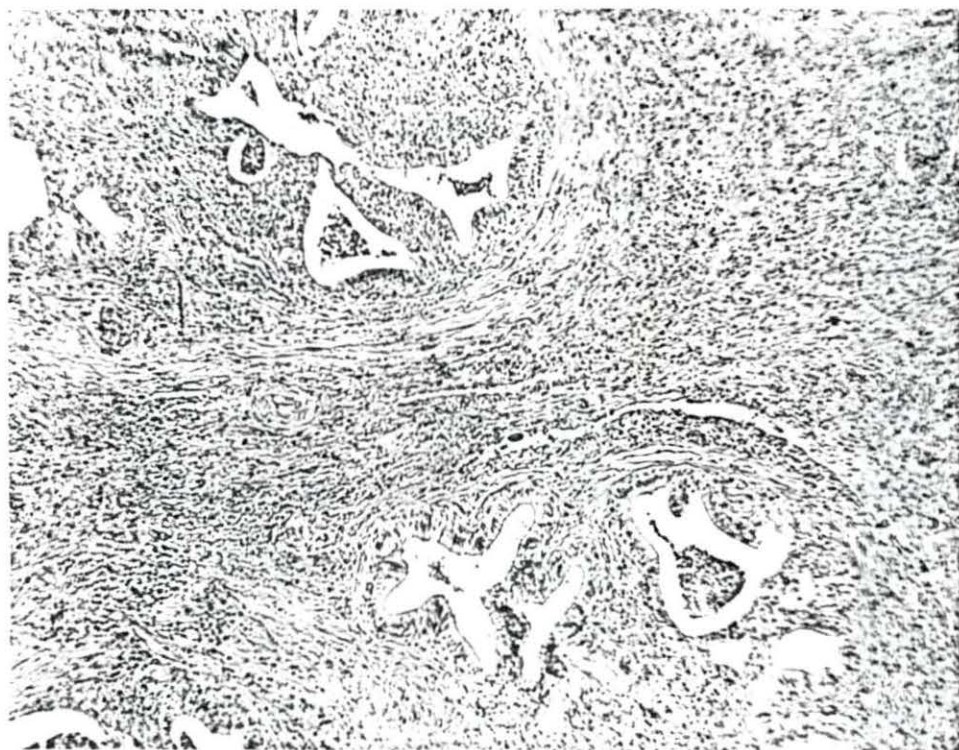
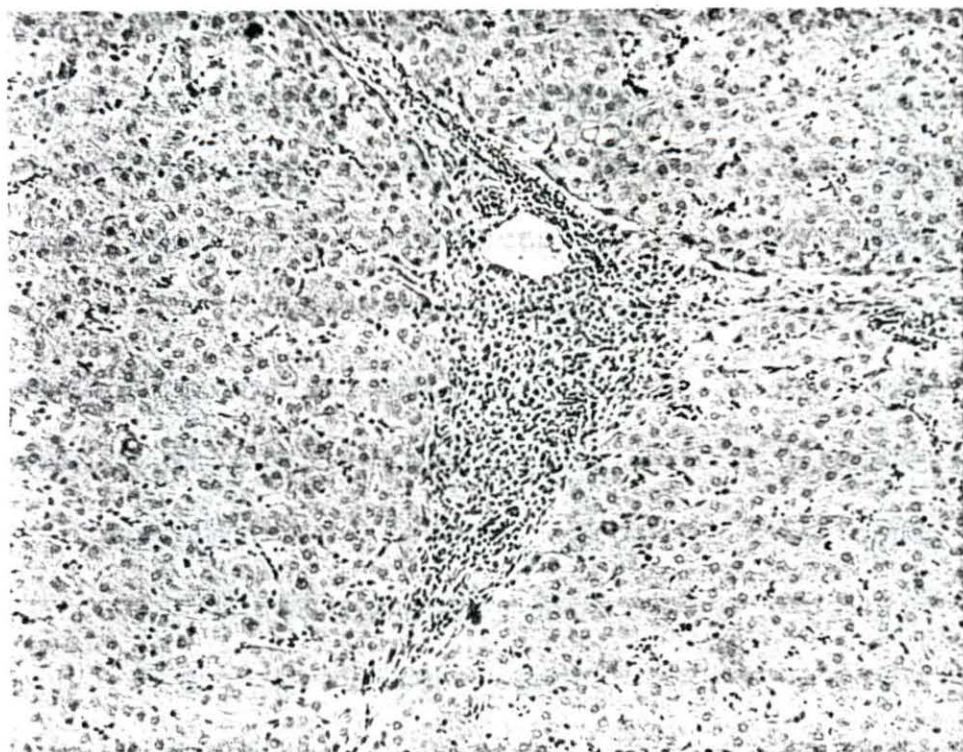


Figure 9. Lymphocytic infiltration of a portal triad in the liver of boar 2660. Hematoxylin and eosin stain, X 125.

Figure 10. Chronic interstitial vesiculitis in the right seminal vesicle from boar 2794. Hematoxylin and eosin stain, X 45.



There were many small abscesses present and occasionally foci of caseous necrosis (Figure 12). The contents of the ducts that remained consisted primarily of cellular debris and neutrophils (Figure 13). The ducts of the seminal vesicles of boar 2632 also contained blood.

Early histologic changes were present in both seminal vesicles of boar 2661 and in the left vesicle of boar 2794. These were multiple focal lymphocytic interstitial reactions. The foci consisted of collections of lymphocytes and macrophages and a few eosinophils located directly beneath the epithelium (Figure 14). In some foci the inflammatory cells seemed to be migrating through the epithelium into the lumen.

Histopathologic changes in the prostate glands also consisted of a multiple focal lymphocytic interstitial inflammation (Figure 15). These changes in prostatic tissue were observed only in boars with advanced changes in the seminal vesicles.

There was a multiple focal lymphocytic interstitial inflammation in the left bulbo-urethral gland of boar 2631 (Figure 16). This is the only instance in which changes were observed in a bulbo-urethral gland.

There was a focal lymphocytic interstitial epididymitis present in the head of the left epididymis of boar 2660

Figure 11. Section of right seminal vesicle from boar 2794. The epithelial lining of ducts has sloughed and ducts are being replaced by the inflammatory tissue. Hematoxylin and eosin stain, X 125.

Figure 12. Abscess in a seminal vesicle from boar 2632. The zone surrounding the focus of neutrophils consists primarily of macrophages. Hematoxylin and eosin stain, X 125.


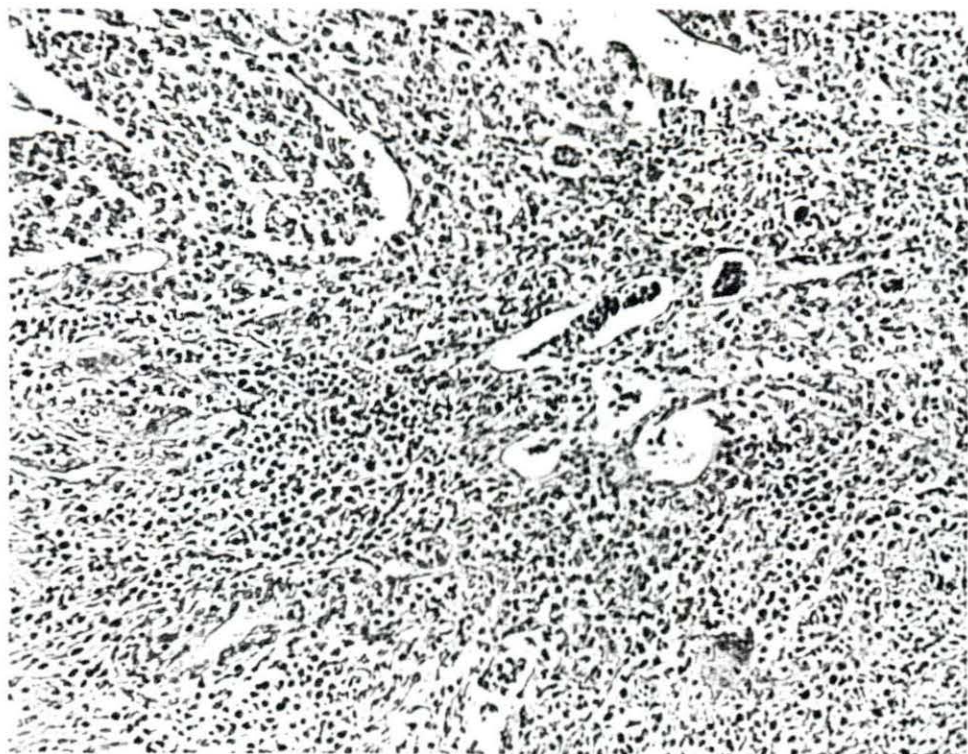


Figure 13. Wall of a duct in a seminal vesicle from boar 2633. The lumen contains many neutrophils. There are numerous macrophages, neutrophils, and lymphoid cells beneath the epithelial lining of the duct. Hematoxylin and eosin stain, X 250.

Figure 14. An early lesion in the left seminal vesicle from boar 2794. There is an interstitial focus of macrophages and lymphocytes beneath the epithelium and infiltrating through the epithelium. Hematoxylin and eosin stain, X 250.

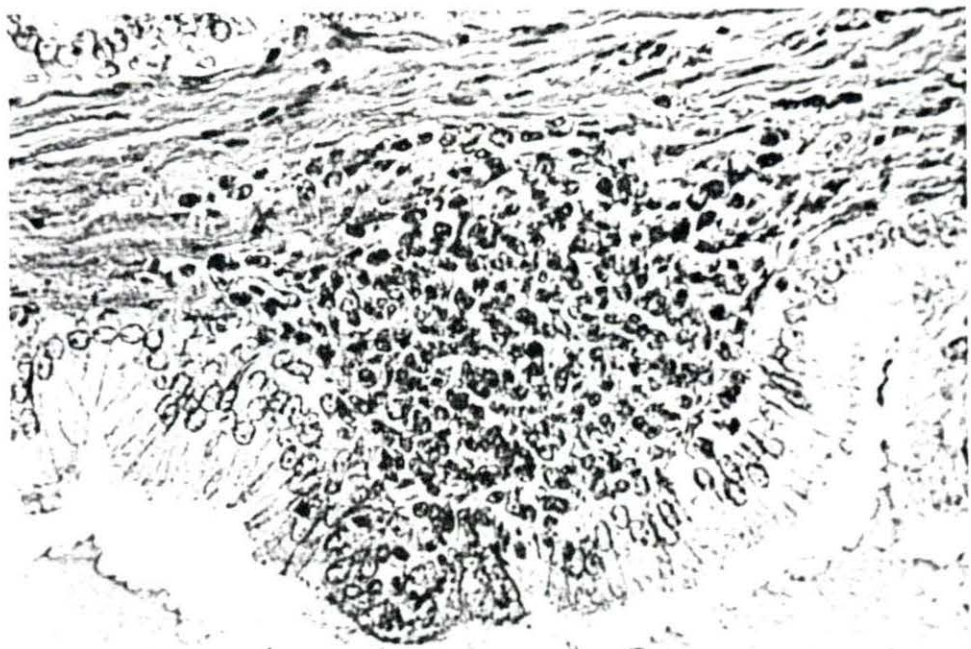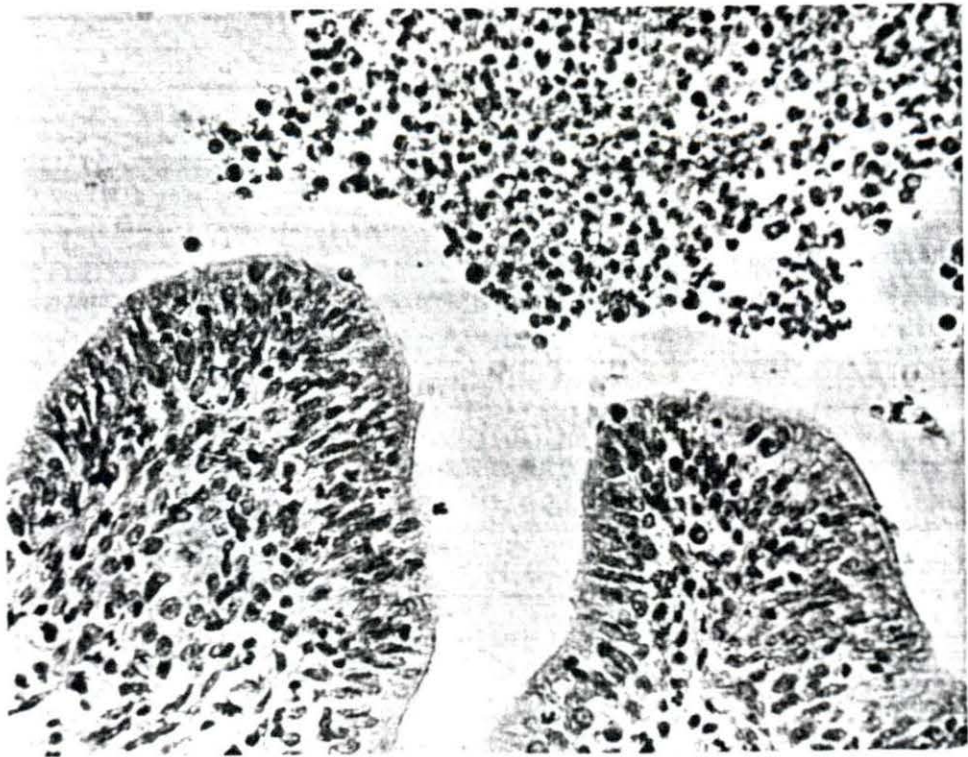

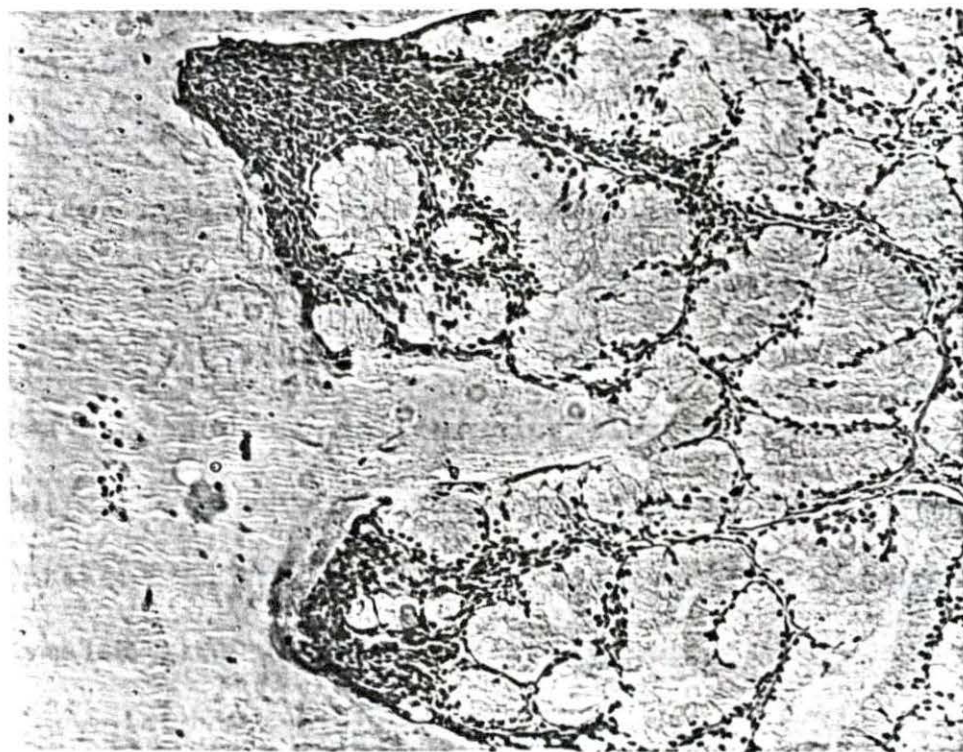


Figure 15. Focal interstitial lymphocytic reaction in the prostate gland from boar 2633. Hematoxylin and eosin stain, X 125.

Figure 16. Focal lymphocytic inflammation in the left bulbo-urethral gland from boar 2631. Hematoxylin and eosin stain, X 125.



(Figure 17). In the same section many epididymal tubules contained some unusual cells and spermatocytes along with the spermatozoa. The unidentified cells contained variable numbers and sizes of nuclei (Figure 18). The origin and significance of these cells were not determined. What appeared grossly to be an abscess in the head of the right epididymis of boar 2794 actually was a cyst. This structure was lined by swollen or necrotic epithelium (Figure 19). Some of it had sloughed into the lumen which was filled with sperm and cellular debris. The thick fibrous wall of the cyst contained isolated epithelial cells which appeared to have been trapped by proliferating fibrous tissue. Surrounding the wall of the cyst were foci of lymphocytes. Adjacent to this cyst was a group of tubules with hyperplastic epithelium arranged in a papillary formation (Figure 20). There was an aberrant lymph node associated with the head of the left epididymis of boar 2792. Most of this node was composed of proliferating fibrous tissue. The germinal centers were inactive and there were few lymphocytes present in the node. The tubules of the adjacent epididymal tissue were aspermic. Brucella suis was isolated from the epididymis of boar 2794, but not from the epididymides of boars 2660 and 2792.

Figure 17. Focal lymphocytic interstitial reaction in the left epididymis from boar 2660. Hematoxylin and eosin stain, X 125.

Figure 18. Unidentified multinucleated cell in the lumen of a tubule in the left epididymis from boar 2660. Hematoxylin and eosin stain, X 800.

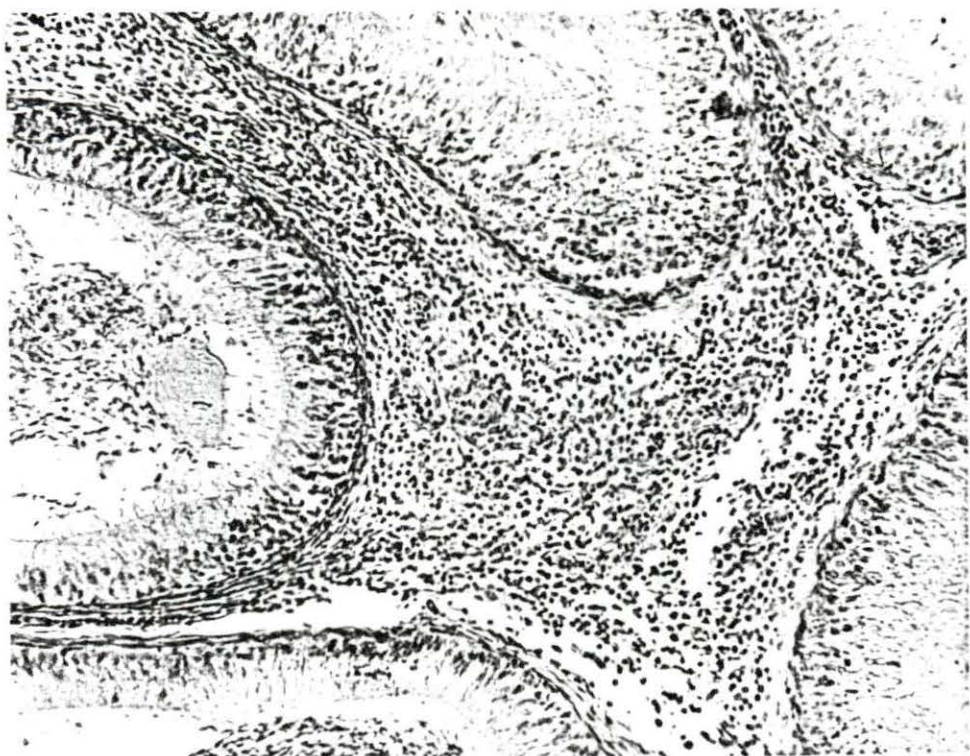
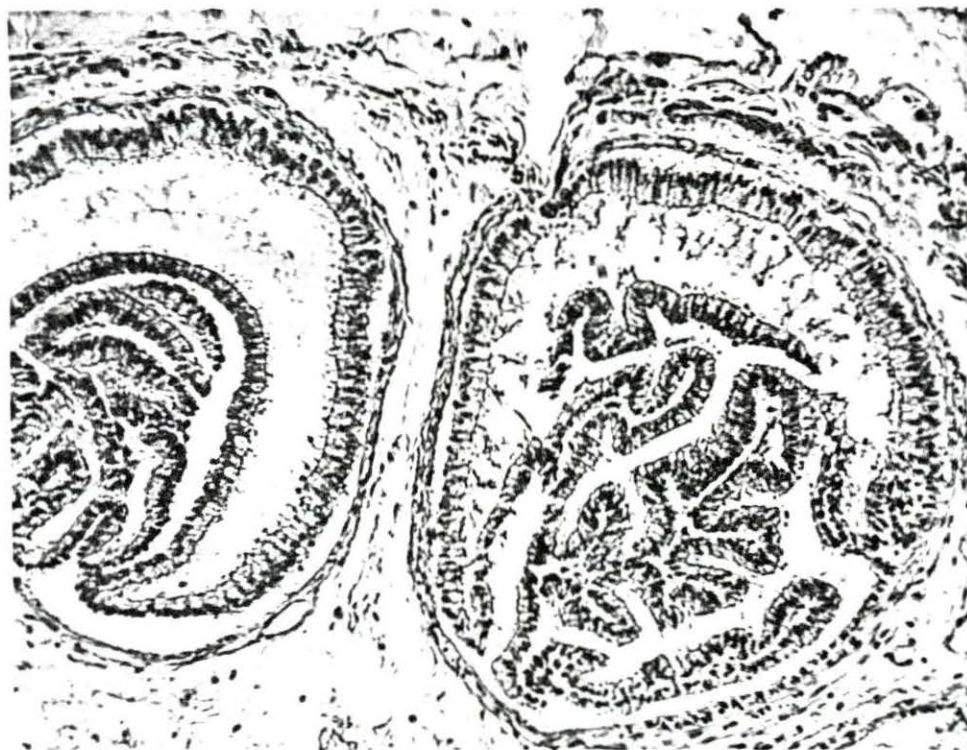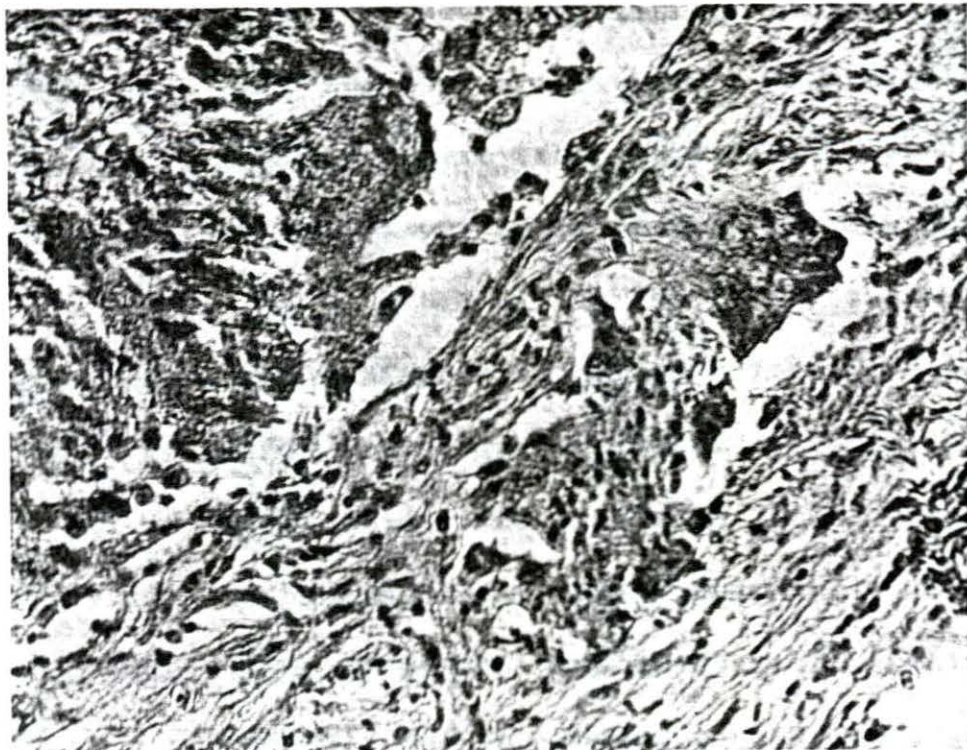


Figure 19. Wall of a cyst in the right epididymis from boar 2794. The epithelium lining the cyst was necrotic and sloughing and there are isolated epithelial cells within the fibrous wall. Hematoxylin and eosin stain, X 350.

Figure 20. Infolding papillary formation of tubular epithelium in the right epididymis from boar 2794. Hematoxylin and eosin stain, X 150.



A marked diffuse lymphocytic infiltration was present in the adventitia of each ductus deferens from boar 2633 (Figure 21). The sections were taken approximately 8-10 cm. from the urethral termination of the ductus deferens.

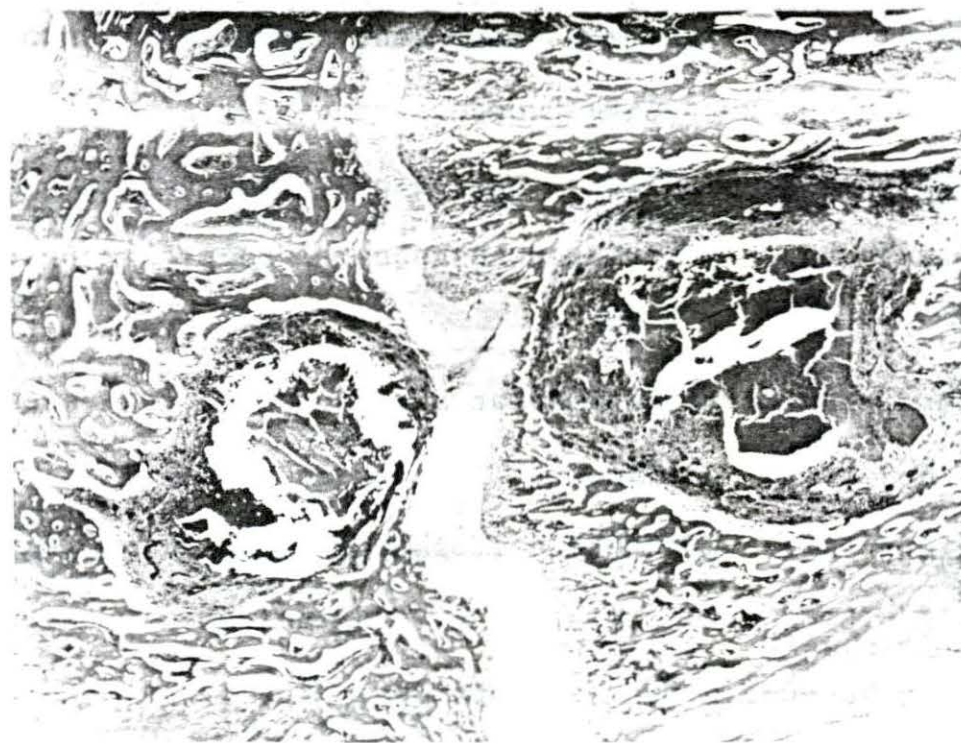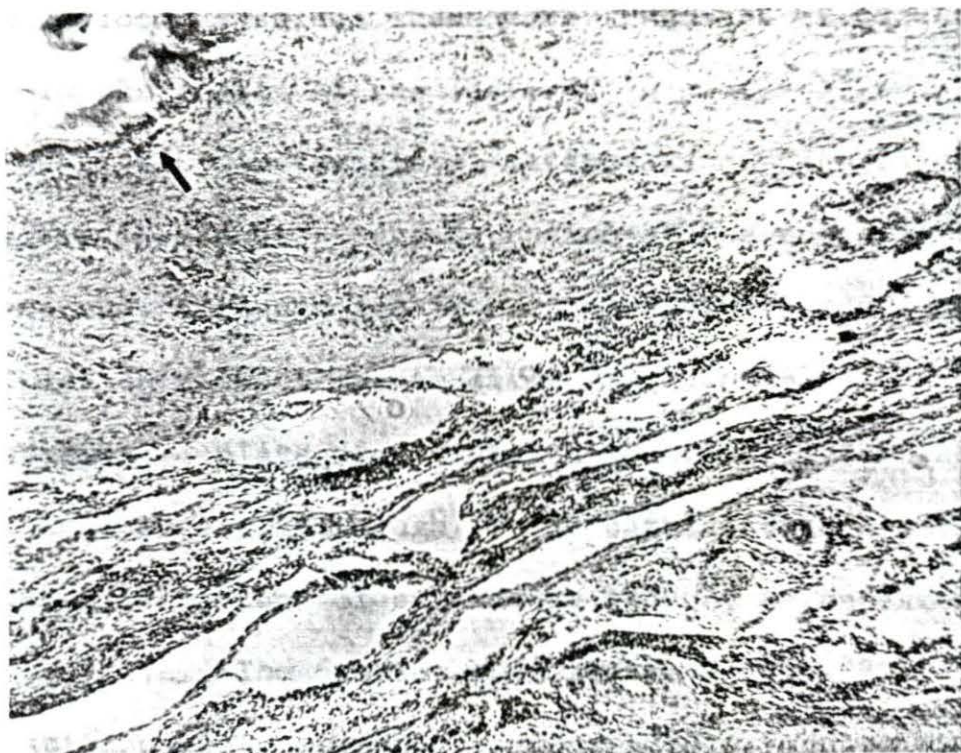Microscopic lesions and isolation of Br. suis from organs of the genital system correlated 94.6% of the time, with epididymides providing the greatest source of discrepancy. Observation of lesions and isolation of the organism from the same epididymis coincided only in the case of boar 2794. There were few detectable qualitative differences in lesions caused by the two biotypes of Br. suis. Lesions occurred more frequently in genital systems from boars infected with Br. suis, type 1, strain 3b. No histopathologic alterations were observed in the testes of any boar.

Granulomatous foci were observed in bones from four boars. A section of the tibia of boar 2793 contained two small foci, 3 mm. and 5 mm. in diameter. These were located adjacent to and separated by the distal epiphyseal cartilage (Figure 22). Each focus consisted of a caseous center, surrounded by a wide zone of macrophages, lymphoid cells and giant cells, and a thin outer zone of connective tissue (Figure 23). The intermediate zone also contained many small



Figure 21. Diffuse lymphocytic infiltration of the adventitia of a ductus deferens from boar 2633. The arrow points to the lumen of the ductus deferens. Hematoxylin and eosin stain, X 45.

Figure 22. Necrotic foci in the distal epiphysis and metaphysis of a tibia from boar 2793. The two foci are separated by the epiphyseal cartilage. Hematoxylin and eosin stain, X 2.



hyperemic blood vessels. There were fragments of bone trapped in the center of the lesions. A similar 7-8 mm. focus was present in the distal metaphysis of a tibia of boar 2792. It had destroyed a portion of the epiphyseal cartilage and, although focal, was not encapsulated. A similar lesion about 1 mm. in diameter was observed adjacent to an epiphyseal plate of a lumbar vertebra from boar 2842, killed at 12 weeks. Although it was partially encapsulated by a rather thick band of connective tissue, it appeared to be still active. The 6th lumbar vertebra of boar 2630, killed at 12 weeks postexposure, contained a focus similar to others observed. It was approximately 2 mm. in diameter and located adjacent to the epiphyseal cartilage. It was composed of a large central caseous mass surrounded by a narrow zone of granulation tissue and a thick fibrous capsule (Figure 24). This appeared to be a stationary or regressing lesion.

There were focal proliferative lesions in the lungs of boar 2792, killed at 3 weeks. The center of these foci consisted primarily of macrophages, some undergoing coagulative necrosis. Surrounding this was a zone of lymphoid cells, young fibroblasts, a few neutrophils, and a zone of hyperemia (Figure 25).

Figure 23. Higher magnification of a necrotic focus shown in Figure 22. The caseous mass at the upper left is surrounded by a zone of macrophages, lymphocytes, and giant cells. The dark circular structure at the lower right is a hyperemic blood vessel. Hematoxylin and eosin stain, X 200.

Figure 24. Necrotic focus adjacent to an epiphyseal plate of the 6th lumbar vertebra from boar 2630. The central zone is caseous and the lesion is well encapsulated. Hematoxylin and eosin stain, X 4.

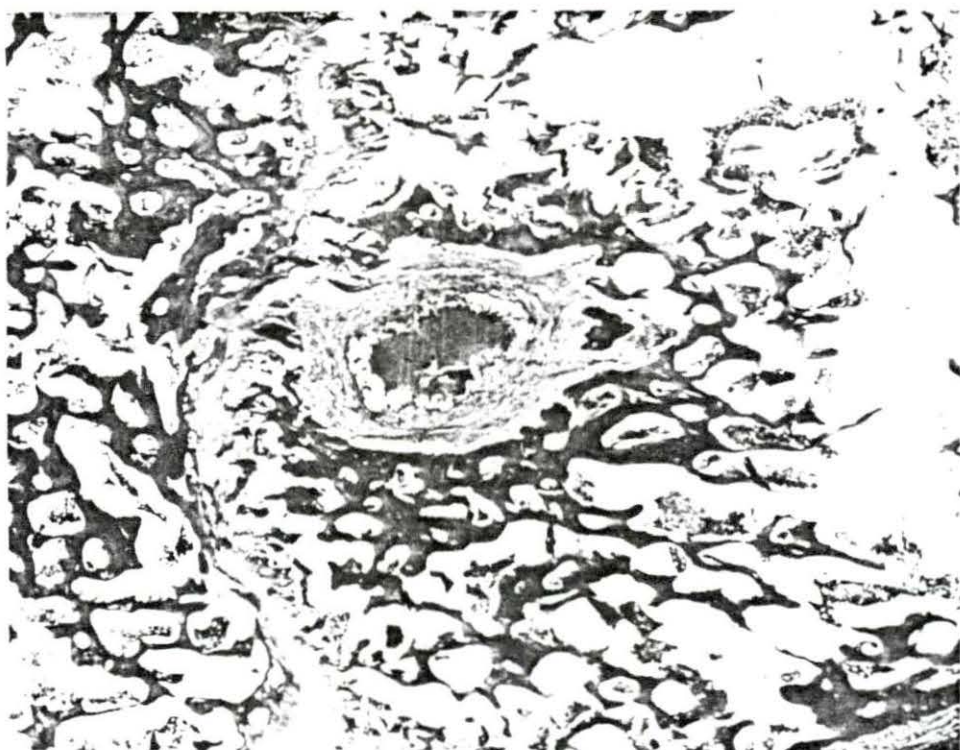
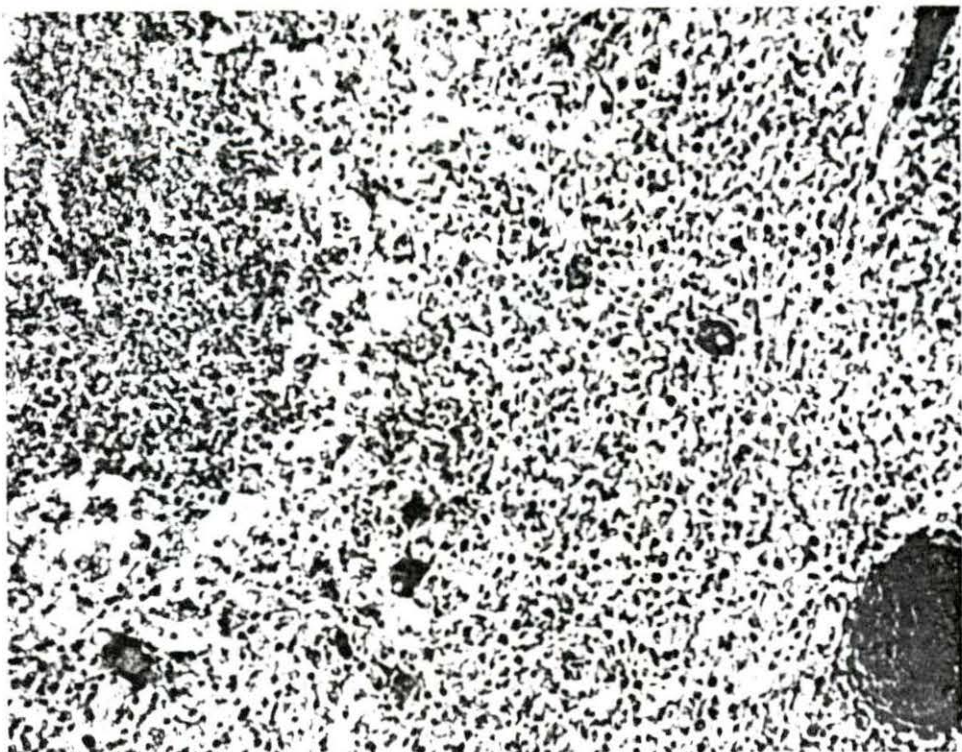



Figure 25. Focal proliferative lesion in a lung from boar 2792. Hematoxylin and eosin stain, X 125.



Mild histopathologic changes were present in the kidneys of boars 2792 and 2631. Cloudy swelling was present in many cells of the tubular epithelium and there were albuminous spherules within many tubules and Bowman's capsules.

There was a small inflammatory focus in the medulla of an adrenal gland from boar 2661, killed at 2 weeks post-exposure. This focus consisted primarily of lymphocytes with many neutrophils present.

Of all histopathologic alterations observed, 82% occurred in tissues from boars killed at 2 to 6 weeks post-exposure. Nearly 60% of the organs in which histopathologic changes occurred were from boars infected with Br. suis, type 1, strain 3b. No pathologic changes were observed in the following: digestive system (except for liver), spleen, respiratory system (except one lung), heart, skeletal muscle, eyes, and central nervous system.



## DISCUSSION

Boars in this experiment were subjected to a single large exposure to Br. suis by a natural route. This may have been unlike some natural infections where multiple exposure to low doses may occur before infection is established.

Under the conditions of this experiment, it is possible to propose a sequence of events taking place in the pathogenesis of brucellosis in boars. After exposure the organisms pass through the conjunctival epithelium and proceed to the regional lymph nodes via the lymph vessels. Organisms may also pass into the nasopharynx via the nasolacrimal duct and enter the nasopharyngeal mucosa. The organisms remain in the lymph nodes of the head and multiply there. Approximately one week after exposure brucellae begin to appear in detectable numbers in the blood stream and are rapidly disseminated throughout the body. A sustained bacteremic phase persists for a variable length of time. During this time the organism is extremely widespread in the body tissues. It is also during this period that the greatest health hazard for persons handling infected carcasses occurs.

After the sustained bacteremic phase passes, Br. suis cannot be isolated from most tissues. However, the organisms

remain localized in certain tissues, particularly lymph nodes, genital organs, and osseous tissues, for longer periods of time, probably within macrophages.

The presence of organisms may initiate tissue damage of varying severity. Most of the focal tissue damage is soon repaired and the organisms can no longer be isolated. Many boars probably completely recover from the infection, but those with severe destructive changes in the genital system may remain infected for life and spread the disease.

Brucella suis was not recovered from boars killed at 12 weeks postexposure. However, there were a few histopathologic changes present in their tissues which suggested that they may have been harboring some organisms.

Clinical signs consisting primarily of persistent fever, anorexia, weakness, depression, and weight loss occurred in a few of the infected boars. These signs could be correlated with localized inflammatory processes in accessory genital glands, but not with the presence of detectable brucellemia.

Brucella agglutinins were present in detectable amounts in fluid or exudate from seminal vesicles bearing severe pathologic changes but were not detectable in fluid from vesicles with early changes, even though Br. suis was isolated from them. This suggests that the production of

agglutinins in these organs was associated with the presence of large numbers of inflammatory cells. The presence of agglutinins, associated with pathologic changes, in the genital organs of bulls with brucellosis has been described by Christensen (13). Semen plasma agglutination tests are often used to diagnose brucellosis in bulls.

There are few specific bacterial infections which have a sustained or repeated bacteremic phase without producing hepatic lesions. Widely disseminated inflammatory foci in livers of boars in this experiment were observed primarily at 2-3 weeks postexposure. This coincided with the sustained bacteremic phase and the location of the foci indicated that entry of the causative organism was by way of the hepatic artery. In contrast, Braude and Anderson (8) stated that hepatic granulomas persist for 6-12 months in infected guinea pigs.

The lack of lesions in the spleen and the infrequent isolation of Br. suis from it during this experiment is consistent with information documented by Manthei (60) and Hutchings (40). Brown, et al. (9) also failed to observe lesions in spleens from experimentally infected swine. However, splenitis and isolation of Brucella from the spleen are almost constant features of brucellosis in guinea pigs.

With the limited number of bone sections taken in this study, the true incidence of osseous lesions in swine brucellosis probably was not determined. Many small granulomatous foci probably occur at the metaphysis or epiphysis of bones where the blood supply is abundant. However, the limited evidence accumulated in this experiment indicates that such lesions remain focal and undergo a slow but progressive encapsulation and healing. It is probably rare that they develop into large grossly apparent foci or extend into periosteous tissues, bringing about gross deformities of bone. This opinion is supported by the data of Braude (7) and Feldman and Olson (23). It has been stated that Br. suis is far more osteotropic than other species of Brucella (54). However, it must be pointed out that, when different Brucella species have been compared in guinea pigs, Br. suis has a tendency to produce more widespread destructive abscesses in all affected tissues (7).

The predominant effect of Br. suis on lymph nodes from boars in this experiment was a focal proliferation of the reticuloendothelial cells. Neither suppurative lymphadenitis, as described by McNutt (56), lymphoid hyperplasia, as observed by Payne (68), nor extensive scarring, as reported by Brown et al. (9), was the predominant characteristic of the

lymphadenopathy observed during this experiment. Suppurative reactions and lymphoid hyperplasia in lymph nodes occurred infrequently and inconsistently. However, all such reactions observed were characteristic of acute foci of inflammation. This would indicate that there may be a recurring acute lymphadenitis in an occasional node throughout the course of the disease. Diffuse reticuloendothelial hyperplasia was observed infrequently, and occurred only in grossly enlarged lymph nodes. The lymph nodes seem to be the only lymphatic tissue involved. Lymphoid nodules lining the digestive tract and in other locations, although quite prominent in swine, showed no definite changes.

Not all Br. suis infected boars will develop localized infection in the genital system. In those that do the primary site of localization seems to be the seminal vesicles. In this experiment the frequency of recovery of Br. suis and intensity of tissue changes were much greater in seminal vesicles than in other organs of the genital system. Inflammatory foci in other organs of the genital system may result from extension of infection from the seminal vesicles. In this experiment all focal inflammatory changes in prostatic tissue and ductus deferens, as well as isolation of Br. suis from bladder urine and serous fluid of the tunica vaginalis,

were accompanied by severe diffuse changes in seminal vesicles.

The literature offers little for comparison of microscopic alterations produced in accessory genital glands by different biotypes of Br. suis. Histopathologic changes due to Br. suis, type 2 have been described by Christiansen and Thomsen (14). Workers who conducted histopathologic studies on boars infected with Br. suis, type 1 apparently did not realize that accessory genital glands exist or were for some reason unable to examine them. No reported histopathologic studies have been conducted on any tissue of swine infected with Br. suis, type 3.

There was a complete lack of evidence of infection in testicles from boars in this experiment. Possible explanations are: (a) orchitis may be a feature of more chronic brucellosis and most of the boars were not retained long enough to develop orchitis, (b) some adverse environmental influence, not present in this experiment, predisposes to the development of orchitis, (c) agent-host combinations of Br. suis strains more prone to cause orchitis and boars with greater tendency to develop orchitis were not present, or (d) orchitis is not a common feature of brucellosis in boars.

Standard veterinary pathology texts (70, 72) classify

inflammations in which reticuloendothelial and fibrous proliferation is a principal feature as proliferative or hyperplastic. Diseases producing this type of inflammation are often called infectious granulomas. According to Jacob (44)

Brucellosis can lead to exudative and proliferative reactions. Granulomas, composed chiefly of reticulo-histiocytic elements, often occur in the course of the proliferative inflammation. In an anatomic classification, the Brucella infections belong to the infectious granulomas.

Judging from the histopathologic observations made in this study, Br. suis produces a subacute to chronic proliferative inflammation affecting primarily the reticuloendothelial system and genital system. The inflammation resembled the infectious granulomas or chronic systemic diseases. There was also a tendency to produce purulent reactions, bearing some resemblance to pyogenic infections. The lesions produced by Br. suis have limited specificity. None are pathognomonic.

Comparing the two strains used for exposure of the boars, Br. suis, type 1, strain 3b was more antigenic, produced more clinical signs, and caused more pathologic alterations. However, the bacteriologic evidence indicated that the two strains were about equal in virulence and persistence. Br. suis, type 3, strain 617 was recovered more often from

the lymphatic system but showed less tendency to localize in the genital system. It is interesting that practically the same relationships were observed in guinea pigs inoculated with the two strains.

There is a complete absence of published material describing histopathologic changes produced by Br. suis, type 3 in boars, and a limited amount of information concerning the other aspects of the pathogenesis of the disease produced by this biotype. Although the histopathologic evolution of the disease has not been fully investigated, there has been considerable research done with biotypes 1 and 2. Comparing the results of this experiment with the results of other researchers, it appears that there are no major differences in the pathogenesis of swine brucellosis caused by the three biotypes of Br. suis. However, there may be vast differences in the virulence of different strains of each biotype.



## SUMMARY

Sixteen sexually mature boars, 14 principals and 2 controls, were utilized in an experiment designed to gain more information on the pathogenesis of swine brucellosis in the early postexposure period. The principals were exposed via the conjunctival route to approximately  $1.25 \times 10^{10}$  viable cells of Brucella suis. Seven principals were exposed to a representative strain of Br. suis, type 1 and seven to a representative strain of Br. suis, type 3. One boar from each group was killed at each of the following postexposure intervals: 1, 2, 3, 4, 6, 8, and 12 weeks. After exposure, clinical signs were observed and bacteriologic and serologic examinations of periodic blood samples were conducted. After the boars were killed, careful post-mortem examinations were conducted. During necropsy, 54-58 different organs and 87-104 different tissue samples were subjected to bacteriologic and histopathologic examination, respectively. All anatomic systems were represented in the bacteriologic and pathologic examinations.

Severe clinical signs occurred in only a few boars and these signs were attributed to pathologic changes occurring in accessory genital glands.

Agglutinins appeared in detectable amounts in the serum of boars about one week postexposure, reached their maximum at two weeks, then gradually receded thereafter. The presence of agglutinins was also demonstrated in secretions or exudates from seminal vesicles bearing gross pathologic changes.

Considerable variation in the persistence of brucellemia was observed, but all boars experienced a period of sustained brucellemia after exposure.

At necropsy, 75% of the Br. suis isolations were made from lymph nodes, 15% from the urogenital system, and 10% from other tissues.

Gross pathologic changes attributable to both types of Br. suis were primarily confined to seminal vesicles and their regional lymph nodes. Histopathologic alterations were most frequently observed in lymph nodes, liver, accessory genital glands, and osseous tissues of infected boars.

The period of maximum infection extended from 2 through 6 weeks postexposure with 92% of the Br. suis isolations and 82% of the histopathologic alterations occurring in boars killed during that period.

The disease produced by Br. suis in boars could be classified as a subacute to chronic, proliferative disease

affecting primarily the reticuloendothelial system and accessory genital glands and resembling other infectious granulomas.

There was no qualitative difference in the characteristics of the disease produced by the two different biotypes of Br. suis.

## LITERATURE CITED

1. Anderson, W. A. and Davis, C. L. Nodular splenitis in swine associated with brucellosis. American Veterinary Medicine Association. Journal 131:141-145. 1957.
2. Andrews, F. N. and Hutchings, L. M. Studies on brucellosis in swine. IV. Semen quality in Brucella-infected boars. American Journal of Veterinary Research. 7: 385-387. 1946.
3. Armed Forces Institute of Pathology. Manual of histologic and special staining technics. 2nd ed. New York, N.Y., McGraw-Hill Book Company, Inc. 1960.
4. Beal, G. A., Taylor, D. B., McCullough, N. B., Claflin, R. M., and Hutchings, L. M. Experimental infection of swine with Brucella melitensis (Mediterranean type). American Journal of Veterinary Research 20:634-641. 1959.
5. Borts, I. H., McNutt, S. H., and Jordan, C. F. Brucella melitensis isolated from swine tissues in Iowa. American Medical Association. Journal 130:966. 1946.
6. Boyd, W. L., Kernkamp, H. C. H., Roepke, M. H., and Blye, C. E. Incidence of brucellosis in swine. U.S. Livestock Sanitary Association Proceedings 48:124-128. 1942.
7. Braude, A. I. Studies in the pathology and pathogenesis of experimental brucellosis. Journal of Infectious Diseases 89:76-94. 1951.
8. Braude, A. I. and Anderson, D. The pathogenesis and pathology of experimental brucellosis. In: Brucellosis: American Association for the Advancement of Science Symposium. pp. 50-62. Washington, D.C., Waverly Press, Inc. 1950.
9. Brown, I. W., Forbus, W. D., and Kerby, G. P. The reaction of the reticuloendothelial system in experimental and naturally acquired brucellosis of swine. American Journal of Pathology 21:205-231. 1945.

10. Cameron, H. S., Hughes, E. H., and Gregory, P. W. Studies on genetic resistance in swine to Brucella infection: preliminary report. Cornell Veterinarian 30:218-222. 1940.
11. Cameron, H. S., Gregory, P. W., and Hughes, E. H. Studies on genetic resistance in swine to Brucella infection. II. A bacteriological examination of resistant stock. Cornell Veterinarian 31:21-24. 1941.
12. Carle, B. N. and Dewhirst, W. H., Jr. A method for bleeding swine. American Veterinary Medicine Association. Journal 101:495-496. 1942.
13. Christensen, N. O. Studies on the agglutinin formation in brucellar infection of the genitals of the bull. Acta Pathologica et Microbiologica Scandinavica 25: 202-209. 1948.
14. Christiansen, M. J. and Thomsen, A. Histologische untersuchungen uber Brucella suis-infektion bei schweinen. Acta Pathologica et Microbiologica Scandinavica. Supplementum 18:64-85. 1934.
15. Creech, G. T. Brucella suis infection of the brain of swine. American Veterinary Medicine Association. Journal 89:584-589. 1936.
16. Creech, G. T. Organic lesions in swine caused by Brucella suis. American Veterinary Medicine Association. Journal 86:211-216. 1935.
17. Damon, S. R. and Scruggs, J. H. Recovery of Brucella melitensis from the hog. Public Health Reports 65:374. 1950.
18. DeKeyser, J., Spincemaille, J., and Brone, E. Brucella suis Thomsen in sperma en genitalia van natuurlyk besmette beren. Vlaams Diergeneeskundig Tijdschrift. 31:171-182. 1962. Original not available; abstracted in Veterinary Bulletin 33:447. 1963.

19. Delez, A. L., Hutchings, L. M., and Donham, C. R. Studies on brucellosis in swine. VI. Clinical and histologic features of intracutaneous reactions to fractions of Brucella suis. American Journal of Veterinary Research 8:225-234. 1947.
20. Fabyan, M. A contribution to the pathogenesis of B. abortus Bang. Journal of Medical Research 21:441-512. 1912.
21. Feldman, W. H. and Olson, C., Jr. Isolation of bacteria of the Brucella group from apparently healthy swine. Journal of Infectious Diseases 54:45-50. 1934.
22. Feldman, W. H. and Olson, C., Jr. Isolation of bacteria of the Brucella group in cases of spondylitis of swine: an additional study. American Veterinary Medicine Association. Journal 84:628-634. 1934.
23. Feldman, W. H. and Olson, C., Jr. Spondylitis of swine associated with bacteria of the Brucella group. Archives of Pathology 16:195-210. 1933.
24. Goode, E. R., Jr., Manthei, C. A., Blake, G. E., and Amerault, T. E. Brucella suis infection in suckling and weanling pigs. II. American Veterinary Medicine Association. Journal 121:456-464. 1952.
25. Hadley, F. B. and Beach, B. A. An experimental study of infectious abortion in swine. Wisconsin Agricultural Experiment Station. Bulletin 55. 1922.
26. Hayes, F. M. and Phipps, H. Studies in swine abortion. American Veterinary Medicine Association. Journal 60: 435-452. 1922.
27. Hendricks, S. L. Swine brucellosis as a public health problem. U.S. Livestock Sanitary Association Proceedings 65:100-107. 1961.
28. Hendricks, S. L., Borts, I. H., Heeren, R. H., Hausler, W. J., and Held, J. R. Brucellosis outbreak in an Iowa packing house. American Journal of Public Health 52: 1166-1178. 1962.

29. Hoerlein, A. B. Studies in swine brucellosis. I. The pathogenesis of artificial Brucella melitensis infection. American Journal of Veterinary Research 13:67-73. 1952.
30. Hoerlein, A. B., Hubbard, E. D., and Getty, R. The procurement and handling of swine blood samples on the farm. American Veterinary Medicine Association. Journal 119:357-362. 1951.
31. Howarth, J. A. and Hayes, F. M. Brucellosis in the swine herd of the University of California. American Veterinary Medicine Association. Journal 78:830-848. 1931.
32. Huddleson, I. F. Biochemical and histopathological reactions in the evolution of bovine brucellosis. Michigan State University. Centennial Symposium Report. Reproduction and Infertility. pp. 27-33. June, 1955.
33. Huddleson, I. F. Brucella. In Breed, R. S., Murray, E. G. D., and Smith, N. R., eds. Bergey's manual of determinative bacteriology. 7th ed. pp. 404-406. Baltimore, Md., The Williams and Wilkins Co. 1957.
34. Huddleson, I. F. Brucellosis in man and animals. New York, N.Y., The Commonwealth Fund. 1943.
35. Huddleson, I. F. Differentiation of the species of the genus Brucella. American Journal of Public Health 21: 491-498. 1931.
36. Huddleson, I. F., Johnson, H. W., and Hamann, E. E. A study of Brucella infection in swine and employees of packing-houses. American Veterinary Medicine Association. Journal 83:16-30. 1933.
37. Hutchings, L. M. Brucellosis in swine. U.S. Livestock Sanitary Association Proceedings 47:52-58. 1943.
38. Hutchings, L. M. Field control experiments with brucellosis in swine. U.S. Livestock Sanitary Association Proceedings 51:124-136. 1947.

39. Hutchings, L. M. Report of further studies of brucellosis in swine. U.S. Livestock Sanitary Association Proceedings 48:105-109. 1944.
40. Hutchings, L. M. Swine brucellosis. In Brucellosis: American Association for the Advancement of Science Symposium. pp. 188-198. Washington, D.C., Waverly Press, Inc. 1950.
41. Hutchings, L. M. and Andrews, F. N. Studies on brucellosis in swine. III. Brucella infection in the boar. American Journal of Veterinary Research 7:388-394. 1946.
42. Hutchings, L. M., Delez, A. L., and Donham, C. R. Brucellosis in swine. V. Reproduction studies with infected sows and boars. American Journal of Veterinary Research 7:388-394. 1946.
43. Hutchings, L. M., Delez, A. L., and Donham, C. R. Studies on brucellosis of swine. I. Infection experiments with weanling pigs. American Journal of Veterinary Research 5:195-208. 1944.
44. Jacob, K. Das bruzellose granulom (English summary). Pathologia Veterinaria 1:41-63. 1963.
45. James, W. A. and Graham, R. Porcine osteomyelitis, pyemic arthritis, and pyemic bursitis associated with Brucella suis (Traum). American Veterinary Medicine Association. Journal 77:774-782. 1930.
46. Johnson, H. W. and Huddleson, I. F. Natural Brucella infection in swine. American Veterinary Medicine Association. Journal 78:849-862. 1931.
47. Johnson, H. W., Huddleson, I. F., and Hamann, E. E. Further studies on natural Brucella infection in swine. American Veterinary Medicine Association. Journal 83: 727-746. 1933.
48. Jordan, C. F. and Borts, I. H. Occurrence of Brucella melitensis in Iowa. American Veterinary Medicine Association. Journal 130:72-75. 1946.



49. Kernkamp, H. C. H. Clinical diagnosis of brucellosis in swine. *Veterinary Medicine* 44:389-392. 1949.
50. Kernkamp, H. C. H., Roepke, M. H., and Jasper, D. E. Orchitis in swine due to Brucella suis. *American Veterinary Medicine Association. Journal* 108:215-221. 1946.
51. King, R. O. C. and Kinross, R. M. Notes of recent research work with Brucella suis infection. [Published in Newcastle, New South Wales] *Institute of Inspectors of Stock of New South Wales. Yearbook.* 4 pp. 1945. (Abstracted in *Veterinary Bulletin* 17:1506. 1947.)
52. Kuzdas, C. D. and Morse, E. V. A selective medium for the isolation of brucellae from contaminated materials. *Journal of Bacteriology* 66:502-504. 1953.
53. Lowbeer, L. Experimental and spontaneous brucellic osteomyelitis of the animal. (Abstract) *American Journal of Pathology* 23:911-912. 1947.
54. Lowbeer, L. Skeletal and articular involvement in brucellosis of animals. *Laboratory Investigation* 8: 1448-1460. 1959.
55. McCullough, N. B., Eisele, C. W., and Pavelchek, E. Survey of brucellosis in slaughtered hogs. *Public Health Reports* 66:205-208. 1951.
56. McNutt, S. H. Brucella infection of swine. *American Veterinary Medicine Association. Journal* 84:620-627. 1934.
57. McNutt, S. H. Brucella infection in swine. *U.S. Live-stock Sanitary Association Proceedings* 42:90-97. 1938.
58. McNutt, S. H. Incidence and importance of Brucella infection of swine in packing-houses. *American Veterinary Medicine Association. Journal* 86:183-191. 1935.
59. McNutt, S. H. and Leith, T. S. Swine brucellosis. *Michigan State College Veterinarian.* 4:28-35. Fall, 1943.

60. Manthei, C. A. Brucellosis. In Dunne, Howard W., ed. Diseases of swine. 2nd ed. pp. 338-362. Ames, Iowa, Iowa State University Press. c1964.
61. Manthei, C. A. Research on swine brucellosis by the Bureau of Animal Industry (1941-1947). American Journal of Veterinary Research 9:40-45. 1948.
62. Manthei, C. A., Mingle, C. K., and Carter, R. W. Brucella suis infection in suckling and weanling pigs. I. American Veterinary Medicine Association. Journal 121:373-382. 1952.
63. Mateev, M., Tsonev, T., Krustev, V., and Lyutskanov, D. Brucellosis in pigs. III. Isolation of Brucella from pigs with positive, doubtful, and negative serological tests. (Translated title) Sofia. Tsentralen Veterinaren Institut za Zarazni i Parazitni Bolesti. Izvestiya 8:147-152. 1963. Original not available; abstracted in Veterinary Bulletin 34:442. 1964.
64. Meyer, M. E. The epizootiology of brucellosis and its relationship to the identification of Brucella organisms. American Journal of Veterinary Research 25:553-557. 1964.
65. Meyer, M. E. Population studies of Brucella suis. (Abstract) American Society for Microbiology Bacteriological Proceedings 64:148. 1964.
66. Mingle, C. K. The cooperative state-federal brucellosis eradication program. National Brucellosis Committee Proceedings 1964:18-25. 1964.
67. Murgia, L. Le surrenali nella brucellosi sperimentale della cavia. Nuova Veterinaria 19:227-233. 1941. Original not available; abstracted in Biological Abstracts 21:14959. 1947.
68. Payne, J. M. The pathogenesis of experimental brucellosis in the pregnant cow. Journal of Pathology and Bacteriology 78:447-463. 1959.

69. Peery, T. M. and Belter, L. F. Brucellosis and heart disease. II. Fatal brucellosis: a review of the literature and report of new cases. *American Journal of Pathology* 36:673-697. 1960.
70. Runnells, Russell A., Monlux, William S., and Monlux, Andrew W. Principles of veterinary pathology. Ames, Iowa, Iowa State University Press. c1960.
71. Sisson, Septimus and Grossman, James D. The anatomy of the domestic animals. 4th ed. Philadelphia, Pa., W. B. Saunders Co. 1956.
72. Smith, Hilton A. and Jones, Thomas C. Veterinary pathology. 2nd ed. Philadelphia, Pa., Lea and Febiger. c1961.
73. Stableforth, A. W. and Jones, L. M. Speciation in the genus Brucella. World Health Organization Report WHO/Bruc/225. 1962.
74. Steele, J. H. Human brucellosis in the United States in 1963. National Brucellosis Committee Proceedings 1964:6-8. 1964.
75. Thomsen, A. Brucella infection in swine. *Acta Pathologica et Microbiologica Scandinavica. Supplementum* 21. 1934.
76. U.S. Department of Agriculture. Agricultural Research Service. Animal Disease Eradication Division. Methods used by A.R.S. in production and standardization of Brucella abortus tube and plate antigen and a description of the tube and plate tests (Revised). Washington, D.C., author. 1959.
77. U.S. Department of Agriculture. Bureau of Animal Industry. Annual Report of the Chief, 1914:30. 1914.
78. U.S. Department of Agriculture. Bureau of Animal Industry. Annual Report of the Chief, 1930:55. 1930.
79. U.S. Department of Agriculture. Bureau of Animal Industry. Annual Report of the Chief, 1931:55. 1931.

80. U.S. Department of Agriculture. Bureau of Animal Industry. Annual Report of the Chief, 1932:42. 1932.
81. U.S. Department of Agriculture. Bureau of Animal Industry. Annual Report of the Chief, 1933:17. 1933.

## ACKNOWLEDGEMENTS

The writer is indebted to Dr. F. K. Ramsey, Dr. E. A. Benbrook, Dr. W. S. Monlux, Dr. C. A. Manthei, and members of the staff of the National Animal Disease Laboratory for their generous assistance during the course of this experiment and the preparation of this thesis. The writer would especially like to acknowledge the technical assistance of Mr. L. R. Elliot, Mr. R. C. Germer, and Mr. J. M. Severtson.