

301

THE PREVALENCE AND PATHOGENICITY OF
CERTAIN BOVINE MYCOPLASMA SPECIES

SF967
M9
AL53P
c. 2

by

George Willoughby Allen

A Thesis Submitted to the
Graduate Faculty in Partial Fulfillment of
The Requirements for the Degree of
MASTER OF SCIENCE

Major Subject: Veterinary Medicine and Surgery

Signatures have been redacted for privacy

Iowa State University
Of Science and Technology
Ames, Iowa

1963

1492198

TABLE OF CONTENTS

	Page
INTRODUCTION	1
REVIEW OF LITERATURE	3
MATERIALS AND METHODS	13
I. Characterization of a <u>Mycoplasma sp.</u> (N-1) Isolated from Bovine Arthritis	13
II. Survey of Incidence of <u>Mycoplasma sp.</u> in Cattle	28
RESULTS	31
I. Characterization of a <u>Mycoplasma sp.</u> (N-1) Isolated from Bovine Arthritis	31
II. Survey of Incidence of <u>Mycoplasma sp.</u> in Cattle	102
DISCUSSION	130
SUMMARY AND CONCLUSIONS	136
REFERENCES CITED	138
ACKNOWLEDGMENTS	142

INTRODUCTION

In recent years, outbreaks of acute lameness in feeder cattle have occurred with increased frequency in the midwestern United States (20). Organisms belonging to the genus *Mycoplasma* were frequently suspected to be the etiological agents but were never isolated from affected material. Isolation of an organism of the genus *Mycoplasma* from an acute case of bovine arthritis was accomplished early in September, 1962*. This organism was recovered from aspirated synovial fluid of the affected left hock of a yearling Hereford feeder steer. Initial work with the organism consisted of inoculation of a culture of the organism into the left hocks of two Hereford feeder cattle with the subsequent production, three to five days postinoculation, of painful joint enlargement and limited mobility of the limb. One of these experimentally infected animals was necropsied and the affected hock showed periarticular edema, gross hyperemia and distention of the joint capsule and intra-articular fibrin clots. These observations stimulated the following studies: (a) characterization of the isolated *Mycoplasma* sp., (b) determination of pathogenicity of the organism for young feeder cattle and for experimental laboratory animals

*Ross, F. R., Ames, Iowa. Isolation of a *Mycoplasma* sp. from a case of bovine arthritis. Unpublished data. 1962.

and (c) a survey of feeder cattle affected with outbreaks of lameness in Iowa and surrounding states. The purpose of the survey was to determine the incidence of the original Mycoplasma sp. isolated in field cases of arthritis and its frequency in the nasal and vulvar flora.

REVIEW OF LITERATURE

As a result of the work of Borrel et al. (5) and Nocard and Roux (24) in the early part of this century, Mycoplasma spp. were recognized as bovine pathogens. Initially, attention was focused primarily on Mycoplasma mycoides var. mycoides, the etiological agent of bovine pleuropneumonia. Only in more recent years have reports appeared in the literature on bovine Mycoplasma other than Mycoplasma mycoides var. mycoides. Edward et al. (14) reported the isolation of Mycoplasma spp. from the bovine genital tract. Isolations were made from the uterine discharge of 18 of 64 cows examined and from the semen of six of seven bulls examined. All cattle were from herds affected with low fertility.

Later work by Edward (11) showed these isolates to consist of two main groups, the P strains and the S strains. The S strains were considered saprophytes as they did not require serum for growth. The P strains were regarded as a single species (Mycoplasma bovigenitalium) (15) and required serum or ascitic fluid for growth. They were believed to have some association with lowered fertility.

The serological examination of ten P strains (11) disclosed that they shared common antigens. The P strains produced a film and spots on horse serum agar but did not

produce acid from carbohydrates. They grew equally well throughout semisolid medium and produced a smooth growth. On solid medium the colonies sometimes reached one mm. in diameter after four days incubation. They had a dark central area while the remainder of the colony was translucent with a finely reticulated surface. The colonies were circular, had a regular edge, a smooth surface and a central depression although some were flat or umbonate on top. Impression smears made from colonies and stained by Giesma's method showed granules and globoid bodies.

Villemont et al. (34) made 39 isolations of Mycoplasma sp. from 134 Arabian Zebu cattle. Eleven strains from this group were examined in detail and five were found to have the biochemical properties of the P strains described by Edward (11).

Olson et al. (25) reported isolation of Mycoplasma sp. from the glans penis, sheath and nose of bulls as well as from the nose of cows. A total of 48 isolations were recorded from 353 samples. However, with the exception of one isolate, none of these organisms required serum for growth. They classified the colonies on solid medium on the third day of incubation into one of four groups: (a) smooth edges with center spots, (b) smooth edges without center spots, (c) rough edges with center spots and (d) rough edges without center spots. The authors noted, however, that

in older cultures all four types of growth were observed from any one isolate. The one bovine isolate which did require serum for growth was obtained from a bull's penis; it did not ferment carbohydrates and when infused into the anterior vagina of a cow caused only a mild hyperemia.

Bakos et al. (2) isolated Mycoplasma sp. from 64 percent of preputial samples collected and from 36.8 percent of semen samples collected. They contended that their results supported the view that Mycoplasma spp. isolated from the sexual organs are primary etiological agents in the production of inflammatory changes.

Carter (6), using Bacto-PPLO agar plus one percent Bacto-PPLO serum fraction medium, was frequently able to demonstrate microscopic colonies on primary culture of inoculum from lungs affected with bronchopneumonia. He was unsuccessful, however, in subculturing these colonies in all but two cases. He suggested that his failure to obtain subcultures may have been due to inadequate medium. With an improved medium, essentially that described by Edward (10), two additional isolations were made and successfully subcultured.

Carter and McSherry (7) later isolated Mycoplasma sp. from nasal swabs of cattle with shipping fever but did not ascertain the role of these organisms in bovine pneumonia.

Three strains of Mycoplasma sp. were isolated by

Hamdy et al. (17) from the respiratory tracts of calves with shipping fever. These organisms were obtained using either sterile cotton swabs moistened with buffered saline and inserted well into the nostrils of affected steers or from affected lung tissue at necropsy. The range of pathogenicity of these three strains was studied. Hamsters, rabbits and guinea pigs were refractory to all strains while exposure of three calves to these isolates, singularly or in combination with Pasteurella multocida and with or without stress, failed to produce the shipping fever syndrome. All three strains produced acid from glucose, maltose, sucrose and trehalose as determined by color change in phenol red and by measurement with a pH meter. On solid medium the organisms showed a dense central area after 48 to 72 hours incubation.

Moulton et al. (23) recovered an organism with the characteristics of a Mycoplasma sp. from a calf with a history of weakness and stiffness of one week duration and a serous nasal discharge of two days duration. On examination the calf had a temperature of 104.8 °F., hyperpnea, dyspnea, musical râles and pleuritic friction sounds. The calf had diarrhea and was in poor condition. One metacarpal-phalangeal joint, carpus, elbow, stifle and tarsus were enlarged and painful. Aspirated joint fluid contained neutrophils in large numbers. The calf showed little response to streptomycin and penicillin therapy and was necropsied five days

following admission. At necropsy the bronchi contained white froth and both apical and cardiac lobes of the lung contained focal areas of consolidation. The affected joints contained large yellowish plaques of fibrin adherent to the synovial membrane. The synovial fluid was not increased but was yellow and viscid while the synovial lining showed evidence of mild hyperemia and mild villous proliferation.

Experimental inoculation of young cattle with cultures of this organism caused clinical signs of stiffness, lameness and keratitis. Two inoculated lambs developed only keratitis (23). Pigs and mice were unaffected. Colonies of the isolated organism exhibited a dome shape with a dense central portion while Giemsa's stained preparations of fluid cultures revealed minute coccoid bodies. Fermentation reactions of the organism consisted of acid production from sucrose, dextrin, dextrose, mannitol, galactose and maltose.

Hudson and Etheridge (18) reported the occurrence of Mycoplasma sp. in the nasal cavity of cattle. In liquid medium the organism grew with uniform turbidity even though it did not grow on the surface of aerobic solid medium. In semisolid cultures growth of the organism began about one cm. below the surface of the medium and extended downwards. This indicated that a reduced oxygen tension was required for growth. The organism grew on agar plates incubated anaerobically and failed to produce acid from carbohydrates. This iso-

late differed both antigenically and biochemically from Mycoplasma mycoides.

Hale et al. (16) reported Mycoplasma sp. to be the etiological agent in an outbreak of bovine mastitis. The affected quarters were hard and swollen and yielded very little secretion. The only systemic abnormality reported was a moderate temperature rise. The isolated organism grew aerobically on solid medium. Colonies were visible after five days incubation and possessed the appearance of a fried egg. Hemolysis occurred in a small zone around the colony and Gram stains made from the colonies disclosed short gram negative rods, cocci and occasionally ring forms. The organism multiplied only slightly under aerobic conditions and failed to grow under anaerobic conditions.

An outbreak of mastitis caused by Mycoplasma sp. was also reported by Stuart et al. (29). The affected quarters became suddenly enlarged and tense, with little evidence of pain or of effect on the general health of the cattle. Body temperatures of affected animals did not exceed 103 °F. The affected glands secreted a milk slightly more yellow than normal. Flakes formed when the secretion was allowed to stand for a short time. The condition was reproduced in experimental cattle by infusing udder secretions from affected cattle into udders of normal cattle. Goats, mice and guinea pigs appeared resistant following inoculation of

the organism. Edward (12) studied isolates of this organism and found it to be culturally and biochemically identical to Mycoplasma bovigenitalium.

In 1963 Simmons and Johnston (27) reported an Australian outbreak of arthritis in young calves caused by Mycoplasma sp. The first affected calf observed was a seven to eight week old Jersey. It was admitted with a history of lameness of 13 days duration. The calf tended to walk on its toes. The left and right carpal, stifle and hock joints and biceps brachii bursae were enlarged and tender. At necropsy the calf was found to have a congested trachea and consolidation of the ventral two-thirds of the apical, cardiac and diaphragmatic lobes of both lungs. Large amounts of yellowish fluid containing yellowish clots were present in the synovial cavities of the left and right carpal, stifle and tarsal joints and in the biceps brachii bursae. Myco-
plasma sp. was isolated from both carpal and stifle joints but not from the lung and liver.

A second case (27) in a month old Jersey presented a similar clinical history. However, this calf also had a temperature of 103 °F., rapid respirations, slight mucopurulent nasal discharge and moist râles on auscultation. The calf was treated by injection both into the affected joints and intramuscularly with tetracyclines. Eight days later the calf continued to evidence joint swellings but was

not lame. Mycoplasma sp. was isolated from joint fluid aspirated before medication.

A third Jersey heifer was presented with a history of being sick for 11 days (27). The fetlock joints of all legs, as well as both carpal, tarsal and stifle joints were enlarged and painful. The animal's temperature was 102 °F. and respirations were rapid and shallow. A mucopurulent nasal discharge was evident. Moist râles were heard and the heart sounds were dull. Administration of tetracyclines for three days using both intramuscular and intra-articular routes resulted in the reduction of joint soreness and the general improvement of the calf. Mycoplasma sp. was recovered from premedication synovial fluid samples aspirated from affected joints. Five weeks postmedication the calf was necropsied and found to have some joint involvement. Mycoplasma sp. was isolated from some of the affected joints.

A month old male Illawarra Shorthorn calf was used in transmission experiments by Simmons and his associate (27). They inoculated one ml. of joint fluid from an infected joint into the left stifle joint and one ml. of a fluid culture of the isolated Mycoplasma sp. into the right carpal joint. On the third day postinoculation the calf was lame in the right front leg and by the fifth day the right carpal joint was enlarged and hot. On the sixth day the left stifle joint was swollen and sore. The fetlock joints of all four legs and

the left carpal, right stifle and both hock joints were enlarged from the seventh to seventeenth day postinoculation at which time the calf died. The temperature fluctuated between 103.4 °F. and 104.8 °F. from the fourth day after inoculation until the animal died. At necropsy the calf had a generalized arthritis. The synovial fluid was increased in volume and the joints contained yellow clots. Sections of the joint capsule of the right carpal joint showed a fibrinous arthritis with proliferation of synovial cells and the formation of many villi. No abnormalities were seen in the cartilage. Mycoplasma sp. was isolated from citrated blood samples collected 13 days postinoculation and from fluid aspirated from the right carpal joint on the tenth day. Mycoplasma sp. was isolated from material collected at necropsy from the left and right carpal and stifle joints, the right front fetlock and hock joints, the atlanto-occipital joint, the left and right popliteal and the right external iliac lymph nodes as well as from the liver. The etiological agent was not described in detail.

Many Mycoplasma spp. are reported to be the etiological agents of arthritis in various domesticated animals. Switzer (30, 31) and Roberts et al. (26) reported their occurrence in swine, Cordy (8) and Cordy et al. (9) reported their occurrence in goats and Adler (1) reported their occurrence in poultry. The pathogenicity of Myco-

plasma spp. in rodents has been described by Ward and Jones (35).

Although Turner and Trethewie (33) reported arthritis caused by Mycoplasma mycoides var. mycoides in some cattle affected with pleuropneumonia and Moulton et al. (23) and Simmons and Johnston (27) observed arthritis lesions attributable to Mycoplasma sp. in young calves, no reference was found in any of the literature to arthritis in epidemic form caused by a Mycoplasma sp. in feeder age cattle (approximately 6 to 24 months of age).

MATERIALS AND METHODS

I. Characterization of a Mycoplasma sp. (N-1)¹

Isolated from Bovine Arthritis

A. Fluid medium preparation

Throughout this study a beef heart infusion, swine gastric mucin, hemoglobin and turkey serum medium was the primary medium used (31). This medium was made by passing fresh ox heart, with the fat trimmed off, through a meat grinder and allowing one part ground heart to infuse in two parts distilled water for 15 to 16 hours at approximately 5 °C. The infusion was then heated at 90 °C. or higher in a boiling water bath for 30 minutes and filtered through gauze. Following adjustment of the resultant filtrate to pH 7.8 with 0.10 normal sodium hydroxide (NaOH), 0.2 percent bacto-hemoglobin², 0.5 percent sodium chloride (NaCl) and 0.5 percent swine gastric mucin³ were added. The infusion was heated a second time in a boiling water bath to 95 °C. and maintained at that temperature for 30 minutes, allowed to cool and filtered through Whatman No. 1 filter paper with the aid

¹Ibid., p. 1.

²Difco Laboratories, Detroit, Michigan.

³Wilson Laboratories, Chicago, Illinois.

of Celite Filter Aid¹. Heat inactivated (56 °C. for 30 minutes) turkey serum was then added to the infusion to make up 20 percent of the total volume. The completed medium was passed through Selas² No. 10 and 01 clarifying filters (19); it was sterilized by passage through a Selas 02 filter and dispensed in 13 by 125 mm. screw top tubes in seven to eight ml. amounts. Sterility was checked by incubation at 37 °C. for 24 to 48 hours; the tubed medium was then stored at 5 °C. until used. This medium will hereafter be called beef heart infusion (B.H.I.) medium.

B. Semisolid medium

Semisolid medium, also called sloppy agar medium, was prepared by the addition of adequate three percent melted sterile agar to sterile B.H.I. medium to give a final concentration of 0.2 percent agar. This medium was dispensed in tubes and stored in the same manner as the B.H.I. medium.

C. Solid medium

Solid medium was prepared by sterilizing B.H.I. medium minus serum plus two percent agar at 15 pounds pressure

¹Johns Mansville and Company; distributed by E. H. Sargent and Company, Chicago, Illinois.

²Selas Filter Corporation, Philadelphia, Pennsylvania.

(121 °C.) for 15 minutes, cooling the medium to 56 °C. and adding warm, sterile turkey serum adequate to constitute 20 percent of the medium. The resultant medium was then poured into sterile petri dishes. Both 15 by 100 mm. glass petri dishes and 60 by 15 mm. plastic tissue culture dishes¹ were used. Two or three representative plates were incubated at 37 °C. for 48 hours to check for sterility and then discarded. The remaining plates were stored in plastic bags at 5 °C. until used.

D. Subculturing and staining

All subcultures from B.H.I. liquid and semisolid media were accomplished with a one ml. pipette. Unless otherwise stated, 0.5 ml. was transferred each time subculturing was required. A pipette was also used to make a stab into the B.H.I. semisolid medium.

Cultures were transferred from fluid to solid medium with the aid of a sterile platinum wire loop; only one loop-full was used per plate. Subculturing from solid medium to solid medium was done by aseptically cutting out a block of agar containing colonies, inverting it and rubbing it across the surface of a fresh plate. All incubations were at 37 °C.

¹Falcon Plastics Division, B-D Laboratories, Incorporated, Baltimore, Maryland.

The original isolate, N-1¹ was subcultured every three to four days in B.H.I. medium. Positive identification of growth of the organism was made by examination of the tube for turbidity and sediment and by centrifugation of five ml. of a culture at 2,000 r.p.m. for 15 minutes, decanting the supernatant and mixing the sediment with the residual drop of medium by means of a Pasteur pipette before aspirating the contents and placing them on a clean microscope slide. The slides were then dried rapidly, fixed with heat, fixed with methyl alcohol and then stained with 1:35 Giemsa's stain for 75 minutes. The slides were then washed gently with distilled water and allowed to dry.

E. Sensitivity to penicillin and thallos acetate

Sensitivity of the isolate N-1 to these two bacterial inhibitors was determined. Inhibitors were added to tubes of B.H.I. medium and inoculated with N-1. The tubes were then incubated and examined daily. Control tubes containing N-1 but no inhibitor were also included. Seven days following inoculation, material from each tube was stained and examined. Penicillin was used at concentrations of 100, 200, 400, 600 and 1000 I.U. per ml. Thallos acetate was used at concentrations of 1:4000, 1:2000, 1:1500, 1:1000 and 1:500.

¹Ibid., p. 1.

F. Electron transfer indicators

Adequate methylene blue was added to B.H.I. medium just before filter sterilization to make a final concentration of 1:50,000. Inoculated tubes containing the N-1 isolate and uninoculated controls were incubated and examined daily. Two,3,5-triphenyl-2H-tetrazolium chloride¹ was added to B.H.I. medium to give a final concentration of 0.005 percent (28), dispensed and inoculated in a similar manner.

G. Carbohydrate utilization

One percent concentrations of various carbohydrates plus 0.005 percent phenol red were added to B.H.I. medium. The carbohydrates used were: glucose, lactose, maltose, sucrose, galactose, mannitol, levulose, raffinose, arabinose and xylose. Each medium was inoculated with the N-1 isolate and examined daily for growth and color change. Uninoculated controls were also examined daily. Seven days postinoculation the pH of each tube was checked with a Beckman pH meter².

H. Filterability

Ten ml. quantities of three day old cultures of N-1 isolate were passed through Selas 02, 03 and 05 filters

¹General Biochemicals, Incorporated, Chagrin Falls, Ohio.

²Beckman Instrument Company, Fullerton, California.

using negative pressure of up to 20 inches of mercury. Subculturing was then done by transferring one ml. of each filtrate into fresh B.H.I. medium. The tubes were examined for growth after three and five days incubation. On the sixth day the cultures were centrifuged and the sediment stained and examined for characteristic organisms.

I. Hemolysis of horse red blood cells

Solid B.H.I. medium plus two percent unwashed horse red blood cells was used to determine whether or not the N-1 isolate caused hemolysis. The red blood cells were added to the medium before the plates were poured. The inoculated plates were incubated in plastic bags to prevent dehydration. They were examined daily for six days.

J. Growth in embryonating hen's eggs

Embryonating hen's eggs used were obtained from the pathogen-free poultry flock at the Iowa State University Veterinary Medical Research Institute. Groups of six eggs were incubated seven days before intra-yolk sac inoculation with 0.2 ml. of a three day old B.H.I. medium culture of N-1 isolate. Other groups of eggs were inoculated after ten days incubation onto the dropped chorioallantoic membrane. Control eggs were inoculated with sterile B.H.I. medium in each trial. Eight days postinoculation all eggs were placed

in the refrigerator at 5 °C. and necropsied six hours later.

K. Growth in primary swine kidney cell cultures

Primary swine kidney cell culture (32) tubes three to five days of age were inoculated with 0.2 ml. of a three day old B.H.I. medium culture of N-1 isolate, incubated at 37 °C. and examined daily. Control tubes were also inoculated. Following five days of incubation, cell culture fluid from inoculated tubes was subcultured into B.H.I. medium. These cultures were then examined and stained four days post-inoculation.

L. Inoculation into experimental calves

1. Clinical examination and husbandry Eight

Hereford heifers weighing approximately 350 to 425 pounds were purchased and housed in individual pens in one large room. All heifers were sired by the same bull and came directly from one herd. The previous owner stated that, to his knowledge, his herd had been free of clinical disease for the previous year. These heifers were maintained in relative isolation for the duration of the experiment. All feed was in the unit before the experiment commenced and nothing was brought in during the trial. All pens were cleaned and bedded daily. A medium-to-good quality hay and water were fed ad libitum. Two pounds of a balanced, anti-

biotic-free grain ration were fed daily.

Each animal was examined daily; temperature, heart rate and rate of respirations were recorded. The lungs and heart were examined daily with the aid of a stethoscope. Both left and right carpal and tarsal joints were palpated daily. Any observable changes in other joints or in the systemic state of the animal were noted.

The cattle were maintained in the unit for ten days before inoculation. During this time the average temperature of the room was gradually increased from approximately 35 °F. to 65 °F. where it was maintained by thermostatically controlled heaters for the duration of the experiment. Ventilation in the unit was adequate.

Forty days following the purchase of the first eight cattle two more heifers were purchased from the same source. The later calves differed from the first only in body weight; they were approximately 50 pounds lighter. These two calves were housed in an isolation unit at the Veterinary Medical Research Institute and maintained as control animals. Husbandry was identical to that of the larger group.

2. Experimental inoculations and manipulations

Numbers and inoculation routes were assigned by randomization to each calf (Table 1).

Thirteen days after introduction into the isolation room the experimental calves were inoculated with two ml. of

Table 1. Routes of inoculation

Calf no.	Route	Inoculum
1	intravenous	N-1 isolate
2	intra-articular and intraperitoneal	sterile B.H.I. medium
3	intraperitoneal	N-1 isolate
4	intra-articular	N-1 isolate
5	intraperitoneal + stress	N-1 isolate
6	intra-articular + stress	N-1 isolate
7	intravenous + stress	N-1 isolate
8	intraperitoneal and intra-articular + stress	sterile B.H.I. medium
9	intraperitoneal and intra-articular	sterile B.H.I. medium
10	intraperitoneal and intra-articular	sterile B.H.I. medium

a 72 hour B.H.I. medium culture of the tenth subculture of N-1 isolate. The site of inoculation was prepared in the following manner: the area was clipped with a surgical clipper, scrubbed thoroughly with liquid Germicidal Detergent¹ and soaked for one minute in Merthiolate².

¹Parke, Davis, and Company, Detroit, Michigan.

²Corn States Laboratories, Incorporated, Omaha, Nebraska.

Each two ml. dose was aspirated from the culture tube with a four inch 18 ga. needle. The syringe was detached and attached to an appropriate inoculation needle. The control calves were inoculated with two ml. of sterile B.H.I. medium both intraperitoneally in the right paralumbar fossa and intra-articularly in the left tibio-tarsal joint. Intravenous inoculations were made into the left jugular vein, intraperitoneal inoculations were made into the right paralumbar fossa and the intra-articular inoculations were made into the left tibio-tarsal joint. The joint was invaded on its antero-medial surface with a sterile 20 ga. 1.5 inch needle. Five ml. of joint fluid were aspirated from the joint for culturing and examination. The syringe was detached leaving the needle in situ and another syringe containing the two ml. of inoculum was attached and the fluid expelled into the joint space. Care was taken to repaint the inoculation area with Merthiolate immediately after removal of the needle.

Stress for heifers No. 5, 6, 7 and 8 consisted of two strands of barbed wire 18 and 42 inches from the floor of one 8 by 14 foot pen. These wires ran around the pen 12 inches inside the walls of the pen and left room only for the calves to stand tightly side by side. Electricity was maintained in the fence for 72 hours. All water and feed was withheld for 72 hours. Minimal bedding was used. At the end of the 72 hour stress period the cattle were placed

in their own pens.

3. Bacteriological examination of experimental calves Nasal and vaginal swabs were collected from all experimental cattle immediately after their introduction into the isolation units. All swabs and samples were processed in the following manner. Tubes of B.H.I. medium containing penicillin and thallos acetate were inoculated as soon as possible after the samples were collected. After three days incubation the cultures were examined grossly for growth and subcultured. This procedure was repeated, the cultures were centrifuged and the sediment stained. All cultures found positive were again subcultured in B.H.I. medium and after three days growth, directly frozen to -20°C . All isolates made from the cattle were later studied along with those from the field survey (Section II).

4. Inoculum A pooled B.H.I. medium inoculum of N-1 isolate was used to inoculate all experimental calves. Sterile B.H.I. medium was used to inoculate the control calves. Tubes of N.I.H. thioglycollate broth medium¹, horse blood agar plates, B.H.I. solid medium plates and B.H.I. medium were inoculated with the culture used to inoculate the experimental calves. One inoculated plate of each type was incubated under 20 percent carbon dioxide (CO_2) atmosphere,

¹Difco Laboratories, Detroit, Michigan.

anaerobically and aerobically. All plates were incubated seven days and examined for growth. No extraneous organisms were detected.

After inoculation of the calves, the remaining inoculum and the sterile B.H.I. medium were incubated for four days and grossly examined for growth and stained.

Similar procedures were used to check the inoculum used to inoculate the laboratory animals.

5. Clinical pathology Ten ml. of citrated blood was collected every second day from each heifer, beginning seven days before inoculation. From 15 days postinoculation to 26 days postinoculation, citrated blood samples were collected every fourth day. Citrated blood samples were collected from the two control heifers maintained at the Veterinary Medical Research Institute every second day for two weeks postinoculation.

Total white and differential white blood cell counts were determined by the methods described by Benjamin (3). Giemsa's stain was used on all smears. Hemoglobin values were determined by use of a Spencer Hemoglobinometer¹ and the results were expressed in mgs. percent.

Smears of aspirated synovial fluid were made and examined by the same procedure used for differential white

¹American Optical Company, Buffalo 15, New York.

blood cell counts (3).

Eight days postinoculation, samples of synovial fluid were collected from the two calves inoculated intra-articularly and from the four control calves. This material was cultured and cellular determinations were made as previously described.

6. Radiographs Radiographs of the hocks, both lateral and posterior and anterior views, of heifers No. 4 and 6 were taken two days pre-inoculation and 40 days post-inoculation.

7. Necropsy All calves necropsied were killed with electrical current. Blood for culturing was collected during exsanguination. Sterile cotton tipped applicators were used to sample the nasal cavity, oral cavity, corneal surface, trachea, bronchi, pericardium, pleura, peritoneum, synovial fluid of both hocks and cerebrospinal fluid.

Tissues collected for both culturing and histopathologic examination included lung, pericardium, liver, spleen, kidney, mesenteric lymph node, both external iliac lymph nodes, both popliteal lymph nodes, joint capsules and synovial linings of both hocks and the brain. The brain was sectioned through the pons, cerebellum, thalamus, caudate nucleus, frontal, parietal and cerebral areas of the cerebral cortex and three areas of the medulla. The tissues for microscopic examination were fixed in ten percent formalin

and processed by the Department of Pathology, Iowa State University.

Tissues were collected aseptically and taken immediately to the laboratory, ground in a mortar with B.H.I. medium and alundum. One ml. of the resultant emulsion was then inoculated into B.H.I. medium and processed as described previously.

Heifer No. 8 (control) was necropsied 15 days postinoculation, No. 3, 39 days postinoculation, No. 6, 47 days postinoculation, No. 4, 48 days postinoculation and Heifers No. 9 and 10, 50 days postinoculation. Heifers No. 1, 2, 5 and 7 were sent to slaughter 50 days postinoculation. Only limited examination of the carcasses was possible during slaughter. The viscera and carpal and tarsal joints were examined in detail. From the latter four calves, cultures were taken only from the conjunctiva, nostrils and oral cavity.

M. Inoculation into laboratory animals

Twelve weanling C.F.W.¹ white mice, four adult guinea pigs, 12 six week old chicks and three young adult rabbits were placed in cages in an isolation unit. After one week these animals were inoculated as outlined in Table 2. An

¹Carworth Farms, New City, New York.

Table 2. Inoculation of laboratory animals with N-1 isolate

Animal	Number	Site	Inoculum	Amount
mouse	1, 2, 3	IM ^a	N-1 isolate	0.1 ml
mouse	4, 5, 6	IP ^b	N-1 isolate	0.1 ml
mouse	7, 8, 9	SC ^c	N-1 isolate	0.1 ml
mouse	10, 11, 12	IM, IP + SC	sterile B.H.I. medium	0.1 ml each site
guinea pig	1	IM	N-1 isolate	0.5 ml
guinea pig	2	IP	N-1 isolate	0.5 ml
guinea pig	3	SC	N-1 isolate	0.5 ml
guinea pig	4	IM, IP + SC	sterile B.H.I. medium	0.5 ml each site
chick	1, 2, 3	IM	N-1 isolate	0.5 ml
chick	4, 5, 6	SC	N-1 isolate	0.5 ml
chick	7, 8, 9	IP	N-1 isolate	0.5 ml
chick	10, 11, 12	IM, IP + SC	sterile B.H.I. medium	0.5 ml each site
rabbit	1	IM, IP + SC	sterile B.H.I. medium	0.5 ml each site
rabbit	2, 3	IM, IP + SC	N-1 isolate	0.5 ml each site

^aIntramuscular.

^bIntraperitoneal.

^cSubcutaneous.

eleventh subculture of N-1 isolate was used. Before inoculation, subcultures of the inoculum were checked for freedom from extraneous organisms as described previously. All laboratory animals were necropsied 14 days postinoculation. All grossly abnormal tissues were saved for culturing and microscopic examination.

II. Survey of Incidence of Mycoplasma sp. in Cattle

In order to gain some idea of the incidence of Mycoplasma resembling the N-1 isolate in cattle affected with lameness, 10 groups of feeder age cattle were visited at various locations in Iowa and Nebraska. The local Veterinarian was consulted for a history of the herd. A limited number of animals affected with respiratory disease or lameness and showing typical signs of the group were given a physical examination. All clinically affected animals were swabbed with sterile cotton tipped applicator sticks both intranasally and intravaginally. Synovial fluid from affected joint spaces was aspirated as aseptically as possible. For this purpose sterile, disposable five ml. syringes equipped with two inch, 20 ga. needles were used.

As soon as possible following collection, each swab and synovial fluid sample was inoculated into tubes of B.H.I. medium to which was added 1,000 I.U. of penicillin and 1:4000

thallous acetate as bacterial inhibitors. These cultures were incubated for three or four days, examined grossly for growth and subcultured into fresh B.H.I. medium containing the above inhibitors. A second subculturing was done three to four days later into the same medium minus the inhibitors. Three days later the last subcultures were examined grossly and stained. Those tubes found positive for Mycoplasma sp. were again subcultured. At 72 hours these cultures were frozen directly to -20°C . and maintained at this temperature for approximately four months. Cultures found contaminated by bacteria were filtered through a Selas 02 filter and one ml. of the subsequent filtrate was inoculated into fresh B.H.I. medium. Four days later these tubes were examined grossly for growth and stained. The tubes found to be positive for Mycoplasma sp. were immediately frozen to -20°C .

After all isolates had been accumulated they were thawed at approximately 37°C ., subcultured into B.H.I. medium and incubated at 37°C . for five days. They were then subcultured, allowed to grow at 37°C . for three days and subcultured into differential media. The differential media used were prepared as described previously and consisted of B.H.I. medium containing one of the following: methylene blue, 2,3,5-triphenyl-2H-tetrazolium chloride, dextrose, semisolid medium and solid medium with two percent

horse red blood cells added.

All cultures were incubated at 37 °C. and examined at three and six days postinoculation for growth or color change. The solid medium plates were examined again at nine days postinoculation.

RESULTS

I. Characterization of a Mycoplasma sp. (N-1)

Isolated from Bovine Arthritis

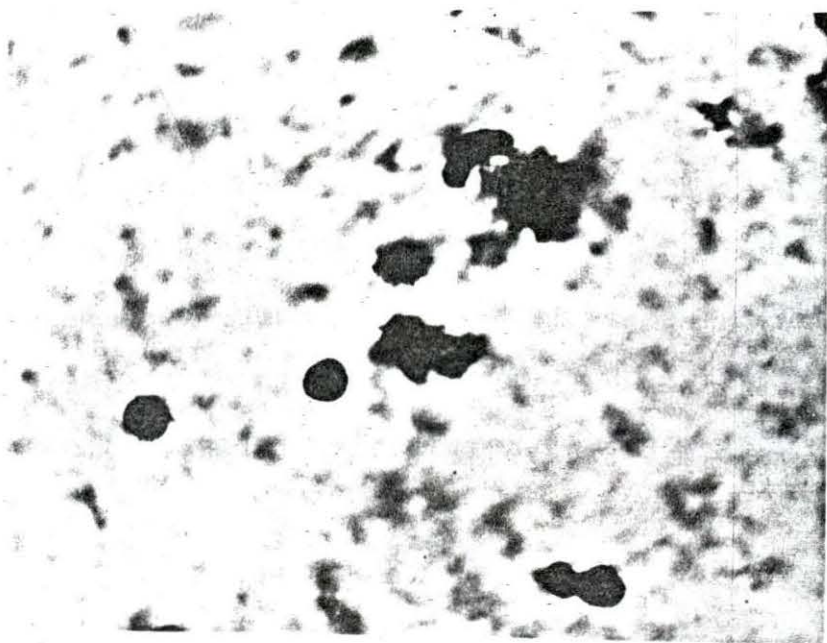

A. Growth in B.H.I. medium

After three days growth in B.H.I. medium the organism produced a general turbidity, a granular sediment and a delicate wax-like pellicle. After six days incubation, up to four mm. of granular sediment was present. The pellicle was heavier and the medium was quite cloudy throughout the tube. Cultures incubated for 30 days were viable on subculture. With progressive subculturing every three or four days the organism produced more abundant sediment.

Examination of Giemsa stained smears of 72 hour cultures of this organism revealed minute coccoid rods in abundance (Figure 1). These organisms were approximately 0.8 x 0.3 microns. Some of the organisms were almost spherical while others were coccobacillary. Six day old cultures, however, showed very few individual organisms; instead large numbers of deep red staining globoid bodies, approximately six microns in diameter (Figure 2), were seen. At the periphery of these bodies a few individual organisms could occasionally be seen. Preparations from 72 to 90 hour cultures were best for demonstrating this.

Figure 1a. Stained smear of the N-1 isolate after
72 hours growth (Mag x960)

Figure 1b. Stained smear of N-1 isolate after six days
growth (Mag x960)



B. Growth in B.H.I. semisolid medium

The organism grew very well on the surface of the medium and into the medium to a depth of two to four mm. following three days incubation at 37 °C. Growth in the stab at this time, however, was minimal but was clearly visible after six days incubation. The organism grew throughout the length of the stab.

C. Growth on B.H.I. solid medium

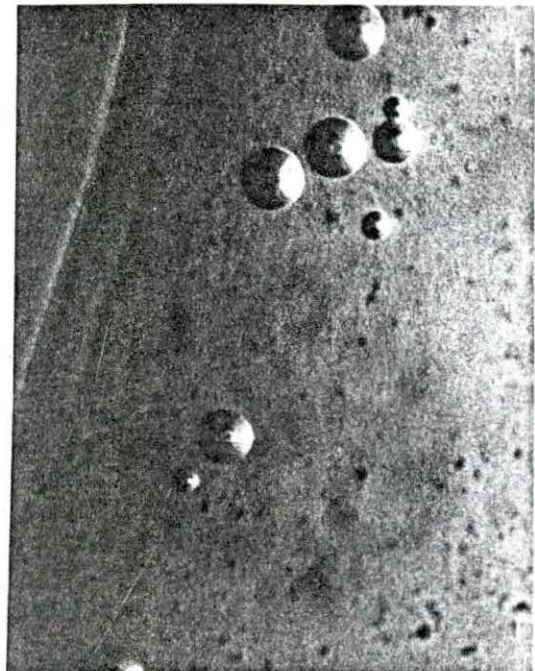

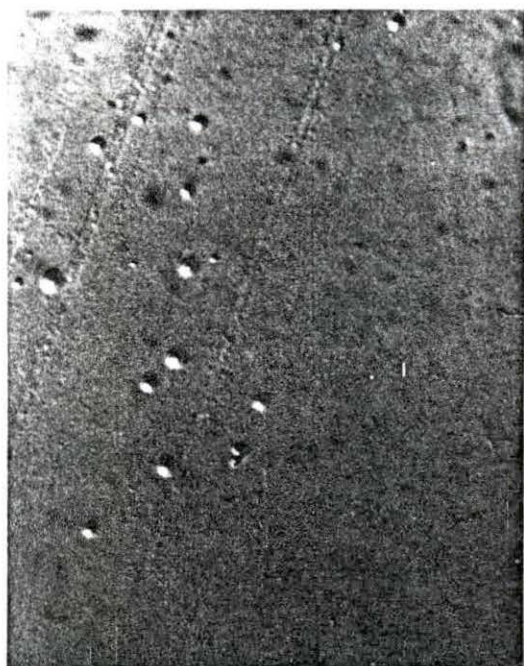
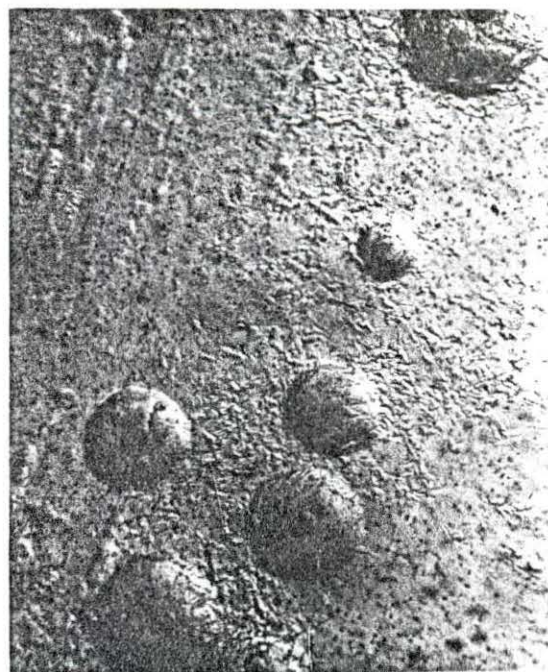
After 64 hours growth on B.H.I. solid medium, small colonies could be seen on the surface with the aid of a dissecting microscope (magnification x 30). These were smoothly circular with a dense protruding central portion (Figure 2) giving them an umbonate surface, approximately 0.1 mm. in diameter. After 72 hours growth the colonies were visible with the naked eye (approximately 0.5 mm. in diameter) when observed in reflected light. At this age, a wax-like film was produced around each colony and soon proceeded to completely cover the inoculated area of the plate. The colonies took on a granular appearance and small black dots were observed around their edges just before the wax-like film covered the colonies (Figure 2).

Figure 2a. (top left) Colonies of N-1 isolate on solid B.H.I. medium after 72 hours growth (Mag x30)

Figure 2b. (top right) Colonies of N-1 isolate on solid B.H.I. medium after 64 hours growth (Mag x30)

Figure 2c. (bottom left) Wax-like film over a heavily inoculated area of the N-1 isolate on solid B.H.I. medium after 72 hours growth

Figure 2d. (bottom right) Colonies of N-1 isolate on solid B.H.I. medium after 68 hours growth



D. Growth with inhibitors

The Mycoplasma, N-1 isolate, grew equally well in all dilutions of Penicillin and thallos acetate used. Growth was satisfactory in B.H.I. medium containing 1,000 I.U. of Penicillin per ml. and in tubes of B.H.I. medium containing a 1:500 dilution of thallos acetate.

E. Growth in electron transfer indicators

Methylene blue was reduced in less than 48 hours while reduction of 2,3,5-triphenyl-2H-tetrazolium chloride to a bright red was accomplished within 72 hours. Growth was satisfactory in all inoculated tubes of B.H.I. medium containing the indicators.

F. Carbohydrate fermentation

Fermentation of maltose, sucrose, galactose, mannitol, levulose, raffinose, arabinose and xylose in B.H.I. medium did not occur although growth in all inoculated tubes was satisfactory. The pH of the control carbohydrate tubes and the inoculated carbohydrate tubes did not differ by more than 0.4 units following seven days incubation.

G. Filterability

Cultures filtered through sterile 02, 03 and 05 Selas filters still contained the organism as evidenced by

five day old subcultures. The latter were positive for growth on gross observations and on staining.

H. Hemolysis

A narrow (approximately one mm.) area of alpha hemolysis was observable around each colony when grown on B.H.I. solid medium containing two percent horse red blood cells following 72 hours growth.

I. Growth in embryonating hen's eggs

No chicken embryo lesions were observed in the eggs inoculated intra-yolk sac. The organism was recovered from the yolk sac, however, when the latter was subcultured into B.H.I. medium at necropsy, eight days postinoculation.

Lesions on the dropped chorio-allantoic membranes eight days postinoculation consisted of a raised circumscribed plaque approximately one cm. in diameter at the point of inoculation in each embryo. No other lesions were observed.

No lesions were seen in the control eggs inoculated with B.H.I. medium.

J. Growth in primary swine kidney cell cultures

A cytopathogenic effect (C.P.E.) was first observable three days postinoculation near the bottom of the culture tubes. After six days incubation the cell sheet was starting

to loosen from the tube and gross C.P.E. was observable throughout most of the cell sheet. The Mycoplasma sp., N-1, was recovered in B.H.I. medium cultures inoculated from the cell culture tubes.

K. Inoculation into experimental calves

1. Calf No. 1 (intravenous inoculation with N-1 isolate)

a. Clinical manifestations Intravenous inoculation of N-1 isolate into this heifer produced an increase in body temperature to 102.5 °F. on day six (Figure 3). At this time she went off feed, was depressed and drank little but showed no abnormalities in heart or respiratory rates. She remained off feed until day nine. Her temperature dropped to below 102 °F. by day 10 and remained below that point for the duration of the trial. Distinct fluid râles were heard in the lower third of both lungs between days 6 and 14. The calf exhibited no other clinical signs throughout the experiment.

b. Clinical pathology No abnormalities were observed in the hemogram throughout the trial (Table 3).

c. Bacteriological examination Results of Mycoplasma sp. isolation attempts from calf No. 1 are shown in Table 4. No organisms of the genus Mycoplasma were isolated from this calf prior to inoculation. Cultures

Figure 3. Daily rectal temperatures of experimental calves 1, 2, 3, 4 and 5

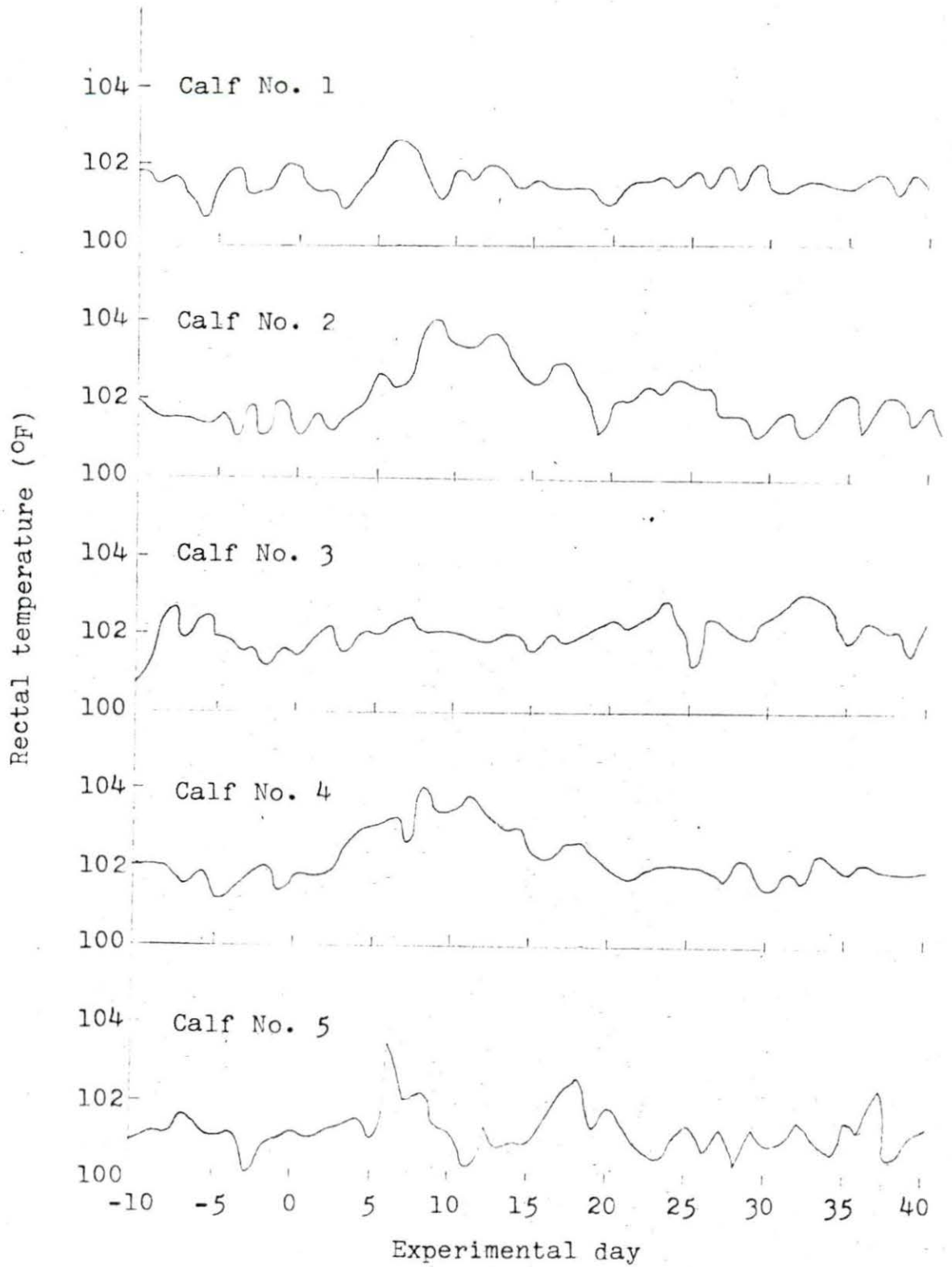


Table 3. Hematological results of calf No. 1

Experi- mental day	Hemo- globin (mg. %)	Total white cell count	Lympho- cyte count	Segmented neutrophil count	Band cell count	Mono- cyte count	Eosin- ophil count
-7	13.5	10,150	70	26	1	2	1
-5	14.0	9,900	58	36	2	3	3
-3	14.0	8,350	56	34	6	3	1
inoculation							
1	15.4	8,250	62	27	7	2	3
3	15.1	9,050	64	21	12	1	3
5	14.5	10,600	58	28	5	4	5
7	13.5	9,150	59	39	6	3	1
9	14.6	7,850	71	11	14	3	2
11	14.5	6,950	69	29	3	5	4
13	14.4	7,900	62	20	2	13	3
17	14.0	8,000	48	32	3	9	8
21	14.0	8,900	62	32	2	3	1
25	14.7	9,550	37	56	1	0	6
29	14.4	9,200	44	36	10	5	5
33	14.3	12,150	70	17	2	7	4
37	14.5	8,450	60	30	5	2	3

Table 4. Isolation of Mycoplasma sp. from calf No. 1

Isolation attempt	Time	Source	Visible growth on 3rd sub-culture	Organisms visible in 3rd subculture stains	MB ^a	TTC ^b	G ^c	SS ^d	Colony morphology ^e
1-1	preinoculation	nasal swab	-	-					
1-2	preinoculation	vaginal swab	-	-					
	inoculation	culture tube	typical N-1	+	+	+	-	+	typical N-1
1-3	50 days PI ^f	nasal swab	-	-					
1-4	50 days PI	vaginal swab	-	-					
1-5	50 days PI	conjunctival swab	-	-					

^aReduction of methylene blue.

^bReduction of 2,3,5-triphenyl-2H-tetrazolium chloride.

^cUtilization of glucose.

^dGrowth in semisolid B.H.I. medium.

^eColony morphology on solid B.H.I. medium.

^fPostinoculation.

of the inoculum were typical of the N-1 isolate. Bacteriological samples taken at slaughter, 50 days postinoculation, were also negative for Mycoplasma sp.

d. Necropsy No gross pathological lesions were observed. No abnormalities were noted in the sections taken for histopathology.

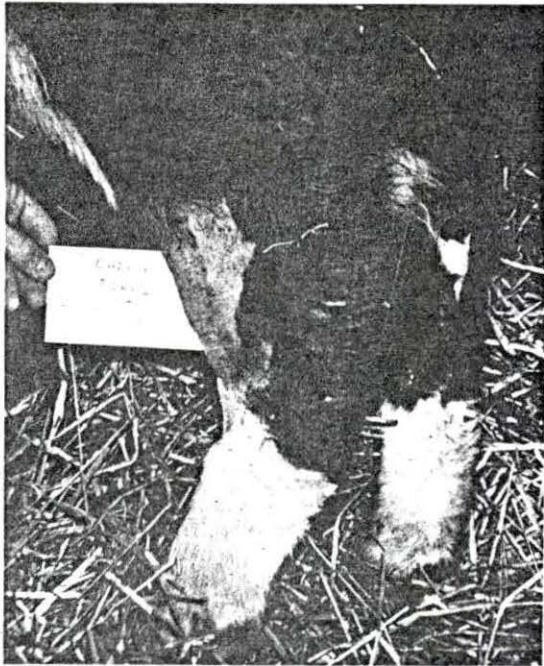2. Calf No. 2 (intraperitoneal and intra-articular inoculation with sterile B.H.I. medium)

a. Clinical manifestations This heifer showed evidence of hyperthermia seven days postinoculation. Her body temperature reached 104 °F. (Figure 3) on day nine and slowly receded to 102.8 °F. by day 19. During the period of hyperthermia her heart rate averaged 80 beats per minute (b.p.m.) with a maximum of 108 b.p.m. Her respiratory rate did not vary outside of 40 to 70 respirations per minute. Anorexia was evident from day six to nine. A mild swelling was noted in and around the inoculated hock on day one. The swelling progressed steadily, until by day six the hock was grossly enlarged (Figure 4), hot and very painful. The calf did not use the affected leg for approximately two weeks. By day 44 there ceased to be any evidence of clinical lameness, however, the affected hock remained enlarged. Digital palpation indicated extensive periarticular fibrosis but did not elicit a pain response.

During the period the calf was acutely lame on her

Figure 4a. (top) Antero-lateral view of left tarsus
of calf No. 2 eight days postinoculation

Figure 4b. (bottom) Lateral view of left tarsus of
calf No. 2 eight days postinoculation



left hind leg, her right hock showed an increase in intra-articular pressure. There was no other evidence of inflammation, however, and the hock returned to normal once the calf was able to walk properly.

From day 9 to 15 mild fluid râles were heard in the ventral one-third of the left lung. No other clinical signs were observed.

b. Clinical pathology The hematological picture did not indicate any gross blood changes in this calf (Table 5). The synovial fluid aspirated just before inoculation was clear, colorless, odorless and watery. It did not clot within two hours and contained a few lymphocytes. The fluid aspirated on day eight, however, was light yellow, contained fibrin flecks and was mucinous. It clotted within five minutes. Smears made from this synovia before it clotted showed a vast number of polymorphonuclear cells and only an occasional lymphocyte.

c. Bacteriological examination Culture results from calf No. 2 are given in Table 6. Pre-inoculation swabs of the nasal cavity, vagina and synovia of the left hock were found negative for organisms of the genus *Mycoplasma*. Following inoculation, however, the tubes containing supposedly sterile B.H.I. medium were found to contain the N-1 isolate. Synovial fluid obtained from the left hock eight days postinoculation was also found to

Table 5. Hematological results of calf No. 2

Experimental day	Hemoglobin (mg. %)	Total white cell count	Lymphocyte count	Segmented neutrophil count	Band cell count	Mono-cyte count	Eosinophil count
-7	13.5	12,700	61	35	4	0	0
-5	12.2	13,650	50	30	14	3	3
-3	14.5	11,450	46	34	10	4	6
inoculation							
1	12.4	12,850	41	54	2	0	3
3	14.4	11,400	40	38	9	0	13
5	14.0	10,650	42	53	0	4	1
7	14.0	13,300	31	57	4	7	2
9	12.2	10,700	38	44	12	0	5
11	11.0	6,350	49	43	4	1	3
13	11.5	10,050	42	50	2	2	5
17	10.5	8,850	56	36	6	2	0
21	10.0	14,350	37	39	18	5	2
25	11.9	10,450	60	37	1	3	0
29	12.9	8,350	40	40	12	2	6
33	12.0	11,850	56	34	8	1	1
37	14.5	10,000	48	42	4	3	3

Table 6. Isolation of Mycoplasma sp. from calf No. 2

Isolation attempt	Time	Source	Visible growth on 3rd sub-culture	Organisms visible in 3rd subculture stains	MB ^a	TTC ^b	G ^c	SS ^d	Colony morphology ^e
2-1	preinoculation	nasal swab	-	-					
2-2	preinoculation	vaginal swab	-	-					
2-3	preinoculation	synovia	-	-					
2-4	inoculation	control inoculum tube	typical N-1	+	+	+	-	+	typical N-1
2-5	postinoculation	synovia	typical N-1	+	+	+	-	+	typical N-1
2-6	50 days PIf	nasal swab	-	-					

^aReduction of methylene blue.

^bReduction of 2,3,5-triphenyl-2H-tetrazolium chloride.

^cUtilization of glucose.

^dGrowth in semisolid B.H.I. medium.

^eColony morphology on solid B.H.I. medium.

^fPostinoculation.

Table 6. (Continued)

Isolation attempt	Time	Source	Visible growth on 3rd subculture	Organisms visible in 3rd subculture stains	MBA	TTC ^b	G ^c	SS ^d	Colony morphology ^e
2-7	50 days PI	nasal swab	-	-					
2-8	50 days PI	conjunctival swab	-	-					
2-9	50 days PI	left hock	-	-					

contain the N-1 isolate. Nasal, vaginal and conjunctival swabs plus synovial tissue of the left hock were negative for the N-1 isolate at 50 days postinoculation.

d. Necropsy Gross examination disclosed a slight enlargement of the mesenteric, left popliteal and left internal iliac lymph nodes. The left hock showed extensive periarticular fibrosis and a moderate increase in synovial fluid which was serosanguineous in character. The synovial membrane was very fibrous and hyperemic in some areas. There was erosion of the articular surface of the distal end of the tibia, starting at the cartilage-bone junction.

Microscopic examination of tissue sections of the affected hock revealed a severe periarticular fibrosis with focal areas of lymphocytes and plasma cells in the fibrous tissue just below the synovial lining. The cells of the synovial lining were distinct and, in many areas, three to four cells thick. There was a loss of articular cartilage with an associated infiltration of plasma cells and lymphocytes in the adjacent area and a moderate increase in subchondral connective tissue.

3. Calf No. 3 (intraperitoneal inoculation with N-1 isolate)

a. Clinical manifestations This calf did not show any temperature rise during the experiment (Figure 3).

Her appetite remained good and she showed no clinical signs of disease. This heifer gained little or no weight during her stay in isolation while the rest of the calves all gained weight.

b. Clinical pathology The blood picture remained within normal limits throughout the period that samples were collected with the exceptions of days 29 and 33 (Table 7). On day 29 the total white blood cell count reached 19,700 and on day thirty-three, 18,550. No other abnormalities were noted.

c. Bacteriological examination The results of all bacteriological samples taken from calf No. 3 are given in Table 8. Pre-inoculation nasal and vaginal swabs were negative for Mycoplasma sp. When the calf was necropsied 39 days postinoculation the N-1 isolate was obtained from tissues of the soft palate and tonsil while a Mycoplasma sp. characterized by a fine smooth sediment in B.H.I. medium and negative 2,3,5-triphenyl-2H-tetrazolium chloride reduction was isolated from the nasal cavity and conjunctiva. The N-1 isolate was present in the inoculum.

d. Necropsy The only abnormalities noted at necropsy were enlargement of the mesenteric lymph nodes to twice normal size and one small area of consolidation in the apical lobe of the lung. Histopathological examination of the kidney, brain, synovial membrane of the left hock and

Table 7. Hematological results of calf No. 3

Experimental day	Hemo-globin (mg. %)	Total white cell count	Lymphocyte count	Segmented neutrophil count	Band cell count	Mono-cyte count	Eosinophil count
-7	13.6	13,900	66	29	5	0	0
-5	12.5	15,200	46	24	22	2	4
-3	13.0	13,050	48	32	8	6	6
inoculation							
1	14.1	9,400	38	44	7	0	11
3	13.2	12,500	70	16	6	4	3
5	12.0	16,700	68	22	0	5	6
7	11.5	13,300	65	25	10	0	5
9	13.0	17,700	73	14	3	1	9
11	12.0	10,750	69	22	1	2	6
13	13.6	9,400	67	19	3	9	4
17	11.4	11,950	57	29	2	2	10
21	11.5	15,900	52	27	1	3	6
25	12.4	15,850	58	18	5	3	13
29	12.8	19,700	48	24	18	5	5
33	11.9	18,550	62	21	10	4	3
37	12.5	10,850	51	26	14	4	5

Table 8. Isolation of Mycoplasma sp. from calf No. 3

Isolation attempt	Time	Source	Visible growth on 3rd subculture	Organisms visible in 3rd subculture stains	MB ^a	TTC ^b	G ^c	SS ^d	Colony morphology ^e
3-1	preinoculation	nasal swab	-	-					
3-2	preinoculation	vaginal swab	-	-					
3-3	inoculation	culture tube	typical N-1	+	+	+	-	+	typical N-1
3-4	39 days PI ^f	nasal swab	fine, smooth sediment	+	+	-	+	+	smooth, circular, a few depressed centers. No raised centers

^aReduction of methylene blue.

^bReduction of 2,3,5-triphenyl-2H-tetrazolium chloride.

^cUtilization of glucose.

^dGrowth in semisolid B.H.I. medium.

^eColony morphology on solid B.H.I. medium.

^fPostinoculation.

Table 8. (Continued)

Isolation attempt	Time	Source	Visible growth on 3rd sub-culture	Organisms visible in 3rd subculture stains	MB ^a	TTC ^b	G ^c	SS ^d	Colony morphology ^e
3-5	39 days PI	vaginal swab	-	-					
3-6	39 days PI	oral swab	-	-					
3-7	39 days PI	conjunctival swab	fine, smooth sediment	+	+	-	+	+	as No. 3-4
3-8	39 days PI	blood swab	-	-					
3-9	39 days PI	urine swab	-	-					
3-10	39 days PI	tracheal swab	-	-					
3-11	39 days PI	pleural swab	-	-					
3-12	39 days PI	pericardial swab	-	-					
3-13	39 days PI	soft palate	typical N-1	+	+	+	-	+	typical N-1

Table 8. (Continued)

Isolation attempt	Time	Source	Visible growth on 3rd sub-culture	Organisms visible in 3rd subculture stains	MB ^a	TTC ^b	G ^c	SS ^d	Colony morphology ^e
3-14	39 days PI	tonsil	typical N-1	+	+	+	-	+	typical N-1
3-15	39 days PI	mesenteric lymph node	-	-					
3-16	39 days PI	liver	-	-					
3-17	39 days PI	spleen	-	-					
3-18	39 days PI	lung lesion	-	-					
3-19	39 days PI	lung	-	-					
3-20	39 days PI	peri-cardium	-	-					
3-21	39 days PI	cerebro-spinal fluid	-	-					
3-22	39 days PI	right politeal lymph node	-	-					

Table 8. (Continued)

Isolation attempt	Time	Source	Visible growth on 3rd sub-culture	Organisms visible in 3rd subculture stains	MB ^a	TTC ^b	G ^c	SS ^d	Colony morphology ^e
3-23	39 days PI	right internal iliac lymph node	-	-					
3-24	39 days PI	right hock	-	-					
3-25	39 days PI	left internal iliac lymph node	-	-					
3-26	39 days PI	left hock	-	-					
3-27	39 days PI	left popliteal lymph node	-	-					

tonsil revealed no lesions. The edematous mesenteric lymph node was characterized by increased space in the sinusoids; the later contained a large number of macrophages. The left popliteal lymph node contained a serous lymphadenitis characterized by a marked increase in macrophages, neutrophils and reticulo-endothelial type cells in the sinusoids. Sections of the liver revealed small focal areas of inflammatory cell infiltration. The consolidated area of the lung was characterized by peribronchial lymphoid hyperplasia, scattered areas of atelectasis and emphysema throughout the affected lobules. Sections of other areas of the lung revealed no abnormalities.

4. Calf No. 4 (intra-articular inoculation with N-1 isolate)

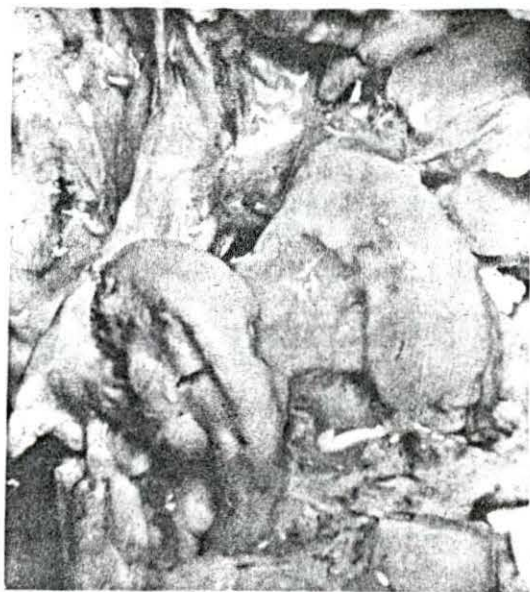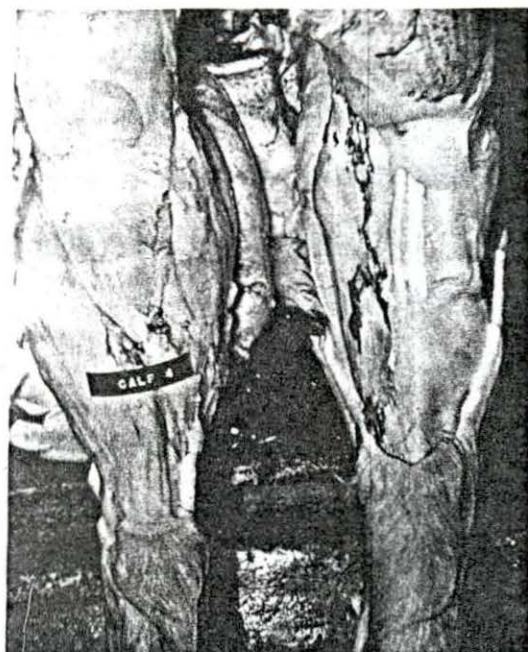
a. Clinical manifestations Pronounced swelling of the periarticular area, severe increase in intra-articular pressure, heat and extreme pain on palpation were all evident in the left hock of this heifer two days post-inoculation. Because of extreme pain on day three, the heifer was unable to use the affected leg (Figure 5). Her body temperature began to increase at this time, reaching 104 °F. by day seven (Figure 3). It did not recede below 102.5 °F. until day 13. Anorexia was evident throughout the period of acute lameness, from day two to day nine. Distinct fluid râles were heard in the lower half of both lungs from

Figure 5a. (top left) Antero-lateral view of left hock of calf No. 4 eight days post-inoculation

Figure 5b. (top right) Anterior view of both hocks of calf No. 4 at necropsy showing inoculated hock at left (labeled)

Figure 5c. (bottom left) Antero-medial view of left tibial tarsal bone of calf No. 4 showing erosion of articular cartilage

Figure 5d. (bottom right) Anterior view of tibial tarsal bone of right hock of calf No. 4



day 7 through day 13. During this period the heifer exhibited a frequent soft, moist cough. The heart and respiratory rates remained normal. The heifer was able to bear weight on the affected leg and walk normally by day 48. The hock area, however, was still greatly enlarged and fibrotic. The right hock showed some puffiness during the acute stages of lameness in the left leg. However, this too receded by day 48.

b. Clinical pathology There were no significant changes in the hemogram throughout the experiment (Table 9). The results of synovial fluid examinations both before inoculation and eight days postinoculation were identical to those reported for calf No. 2.

c. Radiology Pre-inoculation radiographs of the left hock of this calf showed a clean, normal articulation. Radiographs taken 40 days postinoculation, however, showed marked periarticular new bone formation (Figure 6) predominantly around the tibio-tarsal articulation.

d. Bacteriological examination Bacteriological results for calf No. 4 are given in Table 10. Pre-inoculation cultures obtained from the nasal swab of this calf revealed a Mycoplasma sp. exhibiting a smooth growth in B.H.I. medium and failure to grow on B.H.I. solid medium. Other pre-inoculation material did not reveal organisms of the genus Mycoplasma. Both the inoculum and the synovial

Table 9. Hematological results of calf No. 4

Experi- mental day	Hemo- globin (mg. %)	Total white cell count	Lympho- cyte count	Segmented neutrophil count	Band cell count	Mono- cyte count	Eosin- ophil count
-7	13.5	12,350	67	31	1	0	0
-5	14.3	12,600	40	46	10	3	3
-3	16.0	9,350	52	21	15	8	4
inoculation							
1	14.4	11,550	55	32	9	0	4
3	14.6	16,400	40	23	29	4	3
5	14.5	12,500	45	42	7	1	4
7	12.0	13,650	58	29	5	5	4
9	12.6	10,700	72	12	10	1	5
11	12.1	9,500	57	36	3	3	1
13	12.6	10,450	63	23	7	6	1
17	12.4	10,350	61	32	1	4	1
21	12.5	11,550	57	26	7	5	5
25	13.2	11,150	54	33	3	4	5
29	12.8	19,700	48	24	18	8	2
33	13.0	8,150	58	29	8	3	2
37	11.2	8,000	55	20	14	5	6

Figure 6a. (top left) Radiograph showing lateral view of the left hock of calf No. 4 before inoculation

Figure 6b. (top right) Radiograph showing lateral view of the left hock of calf No. 4 40 days postinoculation

Figure 6c. (bottom left) Radiograph showing lateral view of the left hock of calf No. 6 before inoculation

Figure 6d. (bottom right) Lateral view of the left hock of calf No. 6 40 days post-inoculation

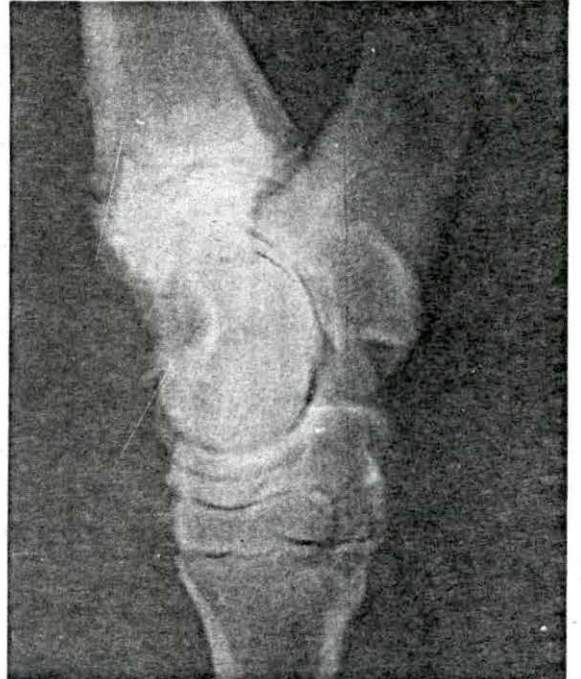
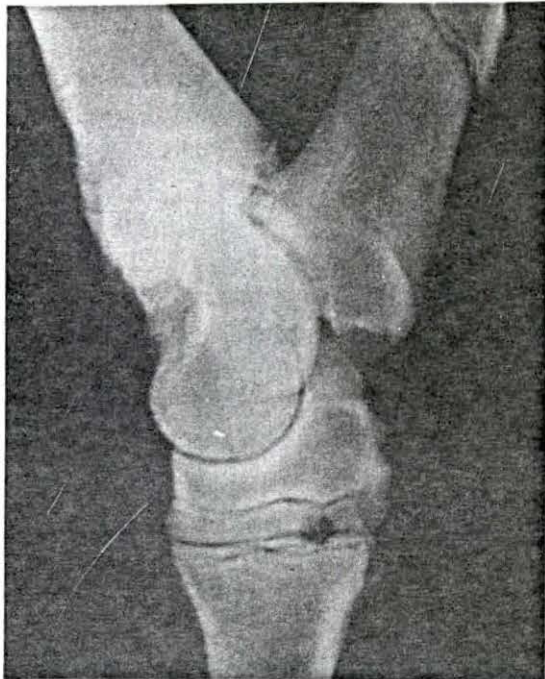
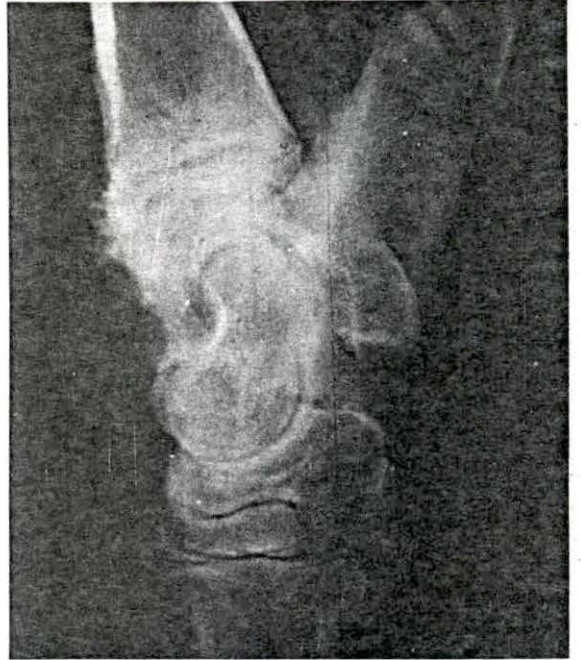
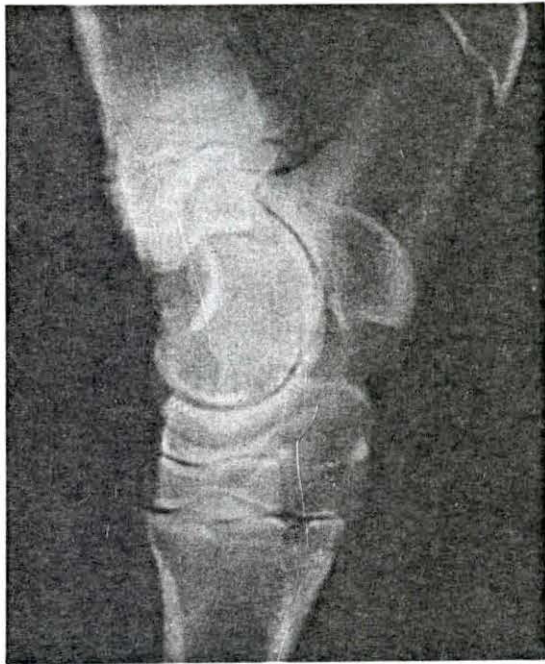

Table 10. Isolation of Mycoplasma sp. from calf No. 4

Isolation attempt	Time	Source	Visible growth on 3rd sub-culture	Organisms visible in 3rd subculture stains	MB ^a	TTC ^b	G ^c	SS ^d	Colony morphology ^e
4-1	preinoculation	nasal swab	minimal smooth sediment	+	-	-	-	-	no growth
4-2	preinoculation	vaginal swab	-	-					
4-3	preinoculation	synovia	-	-					
4-4	inoculation	culture tube	typical N-1	+	+	+	-	+	typical N-1
4-5	postinoculation	synovia	typical N-1	+	+	+	-	+	typical N-1
4-6	48 days PI ^f	nasal swab	-	-					

^aReduction of methylene blue.

^bReduction of 2,3,5-triphenyl-2H-tetrazolium chloride.

^cUtilization of glucose.

^dGrowth in semisolid B.H.I. medium.

^eColony morphology on solid B.H.I. medium.

^fPostinoculation.

Table 10. (Continued)

Isolation attempt	Time	Source	Visible growth on 3rd sub-culture	Organisms visible in 3rd subculture stains	MB ^a	TTC ^b	G ^c	SS ^d	Colony morphology ^e
4-7	48 days PI	vaginal swab	-	-					
4-8	48 days PI	conjunc-	-	-					
4-9	48 days PI	oral swab	-	-					
4-10	48 days PI	urine swab	-	-					
4-11	48 days PI	tracheal swab	-	-					
4-12	48 days PI	pleural swab	-	-					
4-13	48 days PI	pericardial swab	-	-					
4-14	48 days PI	cerebro-spinal fluid	-	-					
4-15	48 days PI	right hock swab	-	-					

Table 10. (Continued)

Isolation attempt	Time	Source	Visible growth on 3rd subculture	Organisms visible in 3rd subculture stains	MB ^a	TTC ^b	G ^c	SS ^d	Colony morphology ^e
4-16	48 days PI	left hock swab	-	-					
4-17	48 days PI	lung	-	-					
4-18	48 days PI	peri-cardium	-	-					
4-19	48 days PI	right internal iliac lymph node	-	-					
4-20	48 days PI	right hock	-	-					
4-21	48 days PI	left hock	typical N-1	+	+	+	-	+	typical N-1
4-22	48 days PI	left internal iliac lymph node	-	-					
4-23	48 days PI	right popliteal lymph node	-	-					

Table 10. (Continued)

Isolation attempt	Time	Source	Visible growth on 3rd sub-culture	Organisms visible in 3rd subculture stains	MB ^a	TTC ^b	G ^c	SS ^d	Colony morphology ^e
4-24	48 days PI	left popliteal lymph node	-	-					
4-25	48 days PI	kidney	-	-					
4-26	48 days PI	liver	-	-					
4-27	48 days PI	spleen	-	-					

fluid collected eight days postinoculation contained organisms typical of the N-1 isolate. At necropsy, 48 days postinoculation, the N-1 isolate was recovered only from the synovia of the left hock.

e. Necropsy At necropsy 20 ml. of fluid was aspirated from the pericardium. This contained an occasional fibrin tag. A slight enlargement of the left internal iliac and popliteal lymph nodes was evident. Arthritis was present in the left hock only and was characterized by periarticular fibrosis, slight hyperemia of the synovial membrane and a large amount of turbid sero-sanguineous synovial fluid. There was marked marginal osteophyte formation and extensive ulceration of the articular surface, especially affecting the tibio-tarsal bone. No other gross lesions were seen.

Histopathological examination of the brain, right hock and tonsils revealed no abnormalities. The left and right popliteal and internal iliac lymph nodes showed evidence of a serous lymphadenitis characterized by a few macrophages and neutrophils in the lymph node sinusoids. The kidney contained small focal areas of hemorrhage. The liver contained small focal accumulations of lymphocytes in Glisson's capsule. The left hock contained a severe arthritis characterized by periarticular fibrosis in which were scant focal areas of plasma cell and lymphocyte accumulations. In

some areas there was a prominent synovial cell layer which was three or four cells thick; in other areas it contained an inflammatory filtrate composed of plasma cells, lymphocytes and an occasional neutrophil. There were also small focal nodular areas of plasma cells and lymphocytes just below the synovial layer. The articular cartilage erosion was characterized by a general tendency of the cartilage cells to arrange themselves in vertical columns. In some areas the cartilage did not take up the stain. At the periphery of the cartilage there were areas of attempted new cartilage production and, in some instances, of cartilage metaplasia to connective tissue. Periosteal new bone formation was present in abundance.

5. Calf No. 5 (intraperitoneal inoculation with N-1 isolate and stressed)

a. Clinical manifestations This calf did not exhibit any clinical signs of disease (Figure 3).

b. Clinical pathology No significant results were observed (Table 11).

c. Bacteriological examination Culture results of calf No. 5 are given in Table 12. A Mycoplasma sp. exhibiting a smooth sediment in B.H.I. medium and no growth on B.H.I. solid medium was isolated from the pre-inoculation nasal swab. No other organisms were isolated from this calf before or following inoculation. The N-1

Table 11. Hematological results of calf No. 5

Experimental day	Hemoglobin (mg. %)	Total white cell count	Lymphocyte count	Segmented neutrophil count	Band cell count	Mono-cyte count	Eosinophil count
-7	12.8	12,100	79	15	4	1	1
-5	11.5	8,900	48	34	10	4	4
-3	14.5	8,900	46	32	18	3	1
inoculation							
1	14.5	10,600	37	55	4	1	4
3	13.7	7,050	53	32	8	1	6
5	14.5	6,800	64	27	1	0	8
7	12.5	9,400	60	25	3	4	12
9	14.5	11,850	58	33	5	3	2
11	13.8	10,100	54	39	4	1	2
13	13.8	11,550	48	35	8	6	3
17	12.8	12,300	40	49	9	2	0
21	15.0	15,500	58	30	6	3	3
25	15.8	10,700	31	56	5	2	6
29	14.4	12,250	51	33	10	3	3
33	12.6	9,950	40	46	10	2	2
37	15.0	8,700	46	24	18	8	4

Table 12. Isolation of Mycoplasma sp. from calf No. 5

Isolation attempt	Time	Source	Visible growth on 3rd sub-culture	Organisms visible in 3rd subculture strains	MB ^a	TTC ^b	G ^c	SS ^d	Colony morphology ^e
5-1	preinoculation	nasal swab	minimal smooth sediment	+	±	+	-	+	no growth
5-2	preinoculation	vaginal swab	-	-					
	inoculation	culture tube	typical N-1	+	+	+	-	+	typical N-1
5-3	50 days PI ^f	nasal swab	-	-					
5-4	50 days PI	vaginal swab	-	-					
5-5	50 days PI	conjunctival swab	-	-					

^aReduction of methylene blue.

^bReduction of 2,3,5-triphenyl-2H-tetrazolium chloride.

^cUtilization of glucose.

^dGrowth in semisolid B.H.I. medium.

^eColony morphology on solid B.H.I. medium.

^fPostinoculation.

isolate was recovered from the inoculum tube.

d. Necropsy No lesions were seen on gross examination or on microscopic examination of kidney, lung, lymph nodes and tonsil.

6. Calf No. 6 (intra-articular inoculation with N-1 isolate and stressed)

a. Clinical manifestations The clinical signs occurring in the inoculated hock of this heifer followed the same sequence as those of calf No. 2 (Figure 7). However, they did not occur with quite the same severity. The calf showed no other clinical signs of disease.

b. Clinical pathology The hemogram revealed nothing significant (Table 13).

c. Radiology Radiographs taken before inoculation showed clean, normal articulations of the tarsus. At 40 days postinoculation these articulations were characterized by excessive periarticular new bone formation (Figure 6).

d. Bacteriological examination Results of culture work from calf No. 6 are shown in Table 14. The only Mycoplasma sp. isolated from pre-inoculation material was an organism exhibiting a smooth sediment in B.H.I. medium and no evidence of growth on B.H.I. solid medium. Both the inoculation culture tube and the postinoculation (day eight) synovia were positive for the N-1 isolate. At necropsy, 47 days postinoculation, a Mycoplasma sp. characterized by fine

Figure 7. Daily rectal temperatures of experimental calves 6, 7, 8, 9 and 10

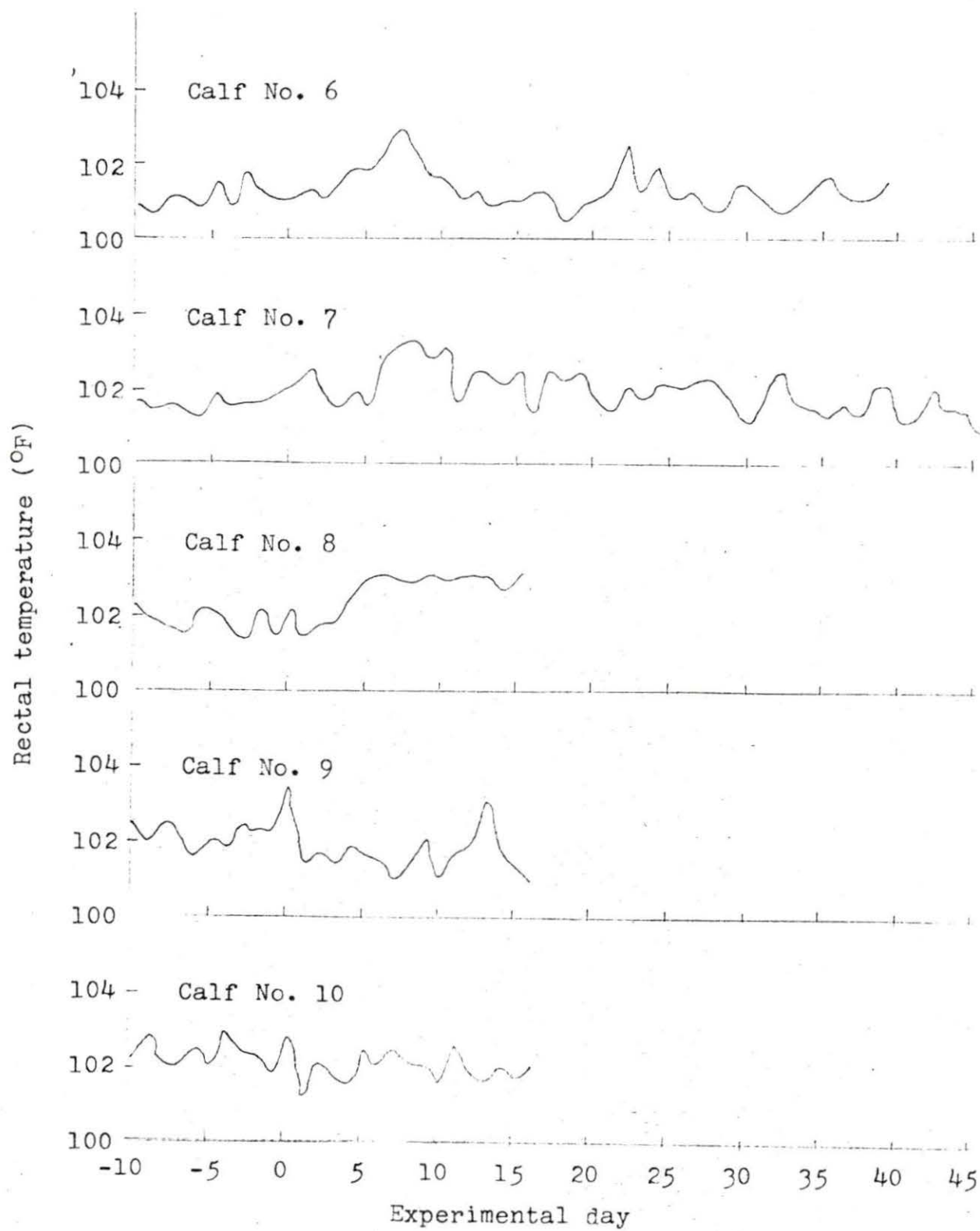


Table 13. Hematological results of calf No. 6

Experimental day	Hemoglobin (mg. %)	Total white cell count	Lymphocyte count	Segmented neutrophil count	Band cell count	Mono-cyte count	Eosinophil count
-7	12.6			sample clotted			
-5	15.0	10,800	46	38	6	8	2
-3	13.5	10,850	68	29	0	3	0
inoculation							
1	12.5	12,850	67	29	3	0	1
3	12.8	14,800	70	16	7	2	4
5	12.5	11,700	46	46	1	3	5
7	11.0	9,000	47	37	6	10	3
9	11.7	11,300	59	25	7	2	7
11	12.3	9,950	65	25	4	3	3
13	11.7	9,500	52	40	6	1	2
17	11.5	11,550	54	39	3	3	1
21	11.5	10,200	57	35	4	1	4
25	13.0	10,750	43	48	2	4	2
29	12.7	4,800	66	21	10	3	1
33	12.6	10,900	56	21	14	4	5
37	14.5	6,800	49	36	14	0	1

Table 14. Isolation of Mycoplasma sp. from calf No. 6

Isolation attempt	Time	Source	Visible growth on 3rd sub-culture	Organisms visible in 3rd subculture stains	MB ^a	TTC ^b	G ^c	SS ^d	Colony morphology ^e
6-1	preinoculation	nasal swab	minimal smooth, fine sediment	+	+	+	-	-	no growth
6-2	preinoculation	vaginal swab	-	-					
6-3	preinoculation	synovia	-	-					
6-4	inoculation	culture tube	typical N-1	+	+	+	-	+	typical N-1
6-5	postinoculation	synovia	typical	+	+	+	-	+	typical N-1

^aReduction of methylene blue.

^bReduction of 2,3,5-triphenyl-2H-tetrazolium chloride.

^cUtilization of glucose.

^dGrowth in semisolid B.H.I. medium.

^eColony morphology on solid B.H.I. medium.

Table 14. (Continued)

Isolation attempt	Time	Source	Visible growth on 3rd sub-culture	Organisms visible in 3rd subculture stains	MB ^a	TTC ^b	G ^c	SS ^d	Colony morphology ^e
6-6	47 days PI ^f	nasal swab	-	-					
6-7	47 days PI	vaginal swab	-	-					
6-8	47 days PI	conjunctival swab	-	-					
6-9	47 days PI	oral swab	minimal fine, granular sediment	+	-	-	-	+ ^g	very small, smooth colonies. No elevation.
6-10	47 days PI	pleural swab	-	-					
6-11	47 days PI	pericardial fluid	-	-					
6-12	47 days PI	right hock	-	-					

^fPostinoculation.

^gVery fine, granular growth in top third of semisolid B.H.I. medium.

Table 14. (Continued)

Isolation attempt	Time	Source	Visible growth on 3rd sub-culture	Organisms visible in 3rd subculture stains	MB ^a	TTC ^b	G ^c	SS ^d	Colony morphology ^e
6-13	necropsy	left hock	-	-					
6-14	necropsy	cerebro-spinal fluid	-	-					
6-15	necropsy	tracheal swab	-	-					
6-16	necropsy	pharyngeal abcess	typical N-1	+	+	+	-	+	typical N-1
6-17	necropsy	left internal iliac lymph node	-	-					
6-18	necropsy	right internal iliac lymph node	typical N-1	+	culture lost when stored at 20 °C.				
6-19	necropsy	left popliteal lymph node	typical N-1	+	culture lost when stored at 20 °C.				

Table 14. (Continued)

Isolation attempt	Time	Source	Visible growth on 3rd sub-culture	Organisms visible in 3rd subculture stains	MB ^a	TTC ^b	G ^c	SS ^d	Colony morphology ^e
6-20	necropsy	right popliteal lymph node	-	-					
6-21	necropsy	mesenteric lymph node	typical N-1	+	+	+	-	+	typical N-1
6-22	necropsy	soft palate	typical N-1	+	+	+	-	+	typical N-1
6-23	necropsy	kidney	-	-					
6-24	necropsy	liver	-	-					
6-25	necropsy	lung	-	-					
6-26	necropsy	brain	-	-					
6-27	necropsy	spleen	-	-					

granular sediment in B.H.I. medium and very small round smooth colonies on B.H.I. solid medium was isolated from the oral cavity. The N-1 isolate was recovered from a pharyngeal abscess, right internal iliac, left popliteal and mesenteric lymph nodes plus the soft palate. Corynebacterium pyogenes was also isolated from the pharyngeal abscess.

e. Necropsy Necropsy examination of this calf revealed a few small focal areas of atelectasis of the left diaphragmatic lobe of the lung. Twenty ml. of fluid containing a few strands of fibrin was present in the pericardium. The left internal iliac and popliteal lymph nodes were enlarged to twice normal size.

Arthritis was present in the left hock. It was characterized by periarticular fibrosis, an increase in and turbidity of the synovial fluid, mottling of the articular cartilage and abundant periarticular new bone formation. The synovial membrane, although fibrotic, appeared normal.

On microscopic examination, the right hock, brain and tonsil appeared normal. The left popliteal lymph node revealed a serous lymphadenitis characterized by a marked increase in reticular type cells, neutrophils and a few macrophages in the sinusoids. Consolidated areas of the lung showed profuse peribronchial lymphoid hyperplasia, atelectasis, and scattered areas of emphysema in the affected lobules. An increase in neutrophils was evident in

the red pulp of the spleen.

The arthritis of the left hock was characterized microscopically by pericapsular fibrosis and loss of areas of cartilage. The fibrosis consisted of mature connective tissue among which appeared small focal accumulations of lymphocytes and plasma cells. The cells of the synovial membrane contained much cytoplasm and, in some areas, were three to four cells thick. Focal areas of inflammatory cell accumulations appeared in those areas free of articular cartilage. Profuse numbers of plasma cells and lymphocytes were present throughout this damaged cartilage area.

7. Calf No. 7 (intravenous inoculation with N-1 isolate and stressed)

a. Clinical manipulations This heifer exhibited clinical signs similar, both in frequency and severity, to those of calf No. 1 (Figure 7).

b. Clinical pathology No significant results were recorded (Table 15).

c. Bacteriological examination Bacteriological results from calf No. 7 are recorded in Table 16. The isolate N-1 was not recovered from either pre-inoculation or postinoculation material collected from this calf. However, the N-1 isolate was recovered from the inoculation culture tube.

d. Necropsy No significant lesions were

Table 15. Hematological results of calf No. 7

Experimental day	Hemoglobin (mg. %)	Total white cell count	Lymphocyte count	Segmented neutrophil count	Band cell count	Mono-cyte count	Eosinophil count
-7	13.3	12,500	37	58	1	2	1
-5	15.0	8,300	42	41	9	6	2
-3	15.0	12,550	40	51	5	3	1
inoculation							
1	13.8	10,550	17	64	12	1	6
3	13.1	9,150	43	37	12	0	7
5	14.0	8,300	40	31	3	3	3
7	13.0	14,550	51	35	6	6	3
9	13.4	8,550	60	29	5	3	3
11	12.5	9,000	60	25	5	4	6
13	12.6	7,400	55	41	1	1	3
17	11.5	8,050	51	38	7	3	1
21	12.5	7,550	60	27	3	4	6
25	12.2	8,550	62	29	5	2	2
29	11.5	6,500	60	31	4	3	2
33	12.1	12,400	43	30	26	0	1
37	12.0	5,500	48	24	12	4	8

Table 16. Isolation of Mycoplasma sp. from calf No. 7

Isolation attempt	Time	Source	Visible growth on 3rd sub-culture	Organisms visible in 3rd subculture stains	MB ^a	TTC ^b	G ^c	SS ^d	Colony morphology ^e
7-1	preinoculation	nasal swab	-	-					
7-2	preinoculation	vaginal swab	-	-					
7-3	inoculation	culture tube	typical N-1	+	+	+	-	+	typical N-1
7-4	50 days PI ^f	nasal swab	-	-					
7-5	50 days PI	vaginal swab	-	-					
7-6	50 days PI	conjunctival swab	-	-					

^aReduction of methylene blue.

^bReduction of 2,3,5-triphenyl-2H-tetrazolium chloride.

^cUtilization of glucose.

^dGrowth in semisolid B.H.I. medium.

^eColony morphology on solid B.H.I. medium.

^fPostinoculation.

observed at slaughter. Tissues were not collected for microscopic examination.

8. Calf No. 8 (intra-articular and intraperitoneal inoculation with sterile B.H.I. medium and stressed)

a. Clinical manifestations Slight joint swelling and heat was present in the inoculated hock one day postinoculation. These early signs of inflammation progressed until day four when the calf was acutely lame (Figure 8). The affected hock was clinically identical to those described earlier. The calf remained acutely lame up to the time of necropsy (15 days postinoculation).

The rectal temperature of this heifer rose to 103 °F. on day six and was still above normal at necropsy (Figure 7). The calf became anorexic, depressed and drank very little water from days six to nine. It frequently exhibited a heart rate of 100 b.p.m. throughout the depression period. Fluid râles were first heard on day 10 and remained until necropsy on day 15.

b. Clinical pathology No abnormalities in the blood picture were observed (Table 17).

c. Bacteriological examination The results of all bacteriological samples taken from calf No. 8 are given in Table 18. The pre-inoculation nasal swab revealed a Mycoplasma sp. characterized by a smooth sediment in B.H.I. medium and lack of growth on B.H.I. solid medium. The pre-

Table 17. Hematological results of calf No. 8

Experi- mental day	Hemo- globin (mg. %)	Total white cell count	Lympho- cyte count	Segmented neutrophil count	Band cell count	Mono- cyte count	Eosin- ophil count
-7	14.5	19,900	65	25	7	4	0
-5	12.2	6,650	68	22	9	1	1
-3	13.5	8,850	46	45	5	3	1
inoculation							
1	14.1	10,250	24	71	4	0	1
3	13.5	8,600	58	27	7	2	5
5	12.5	10,150	52	32	10	5	2
7	12.0	9,450	55	37	6	2	0
9	11.8	6,550	69	22	4	4	0
11	12.4	7,300	48	36	6	5	5
13	11.7	7,400	56	33	5	3	4

Figure 8a. (top left) Antero-lateral view of the left hock of calf No. 8 eight days postinoculation

Figure 8b. (top right) Anterior view of left hock of calf No. 8 with skin removed

Figure 8c. (bottom left) Left tibial tarsal articulation of calf No. 8 exhibiting hyperemia of the synovial membrane

Figure 8d. (bottom right) Left tibial tarsal articulation of calf No. 8. Note the excessive fibrin in the articulation

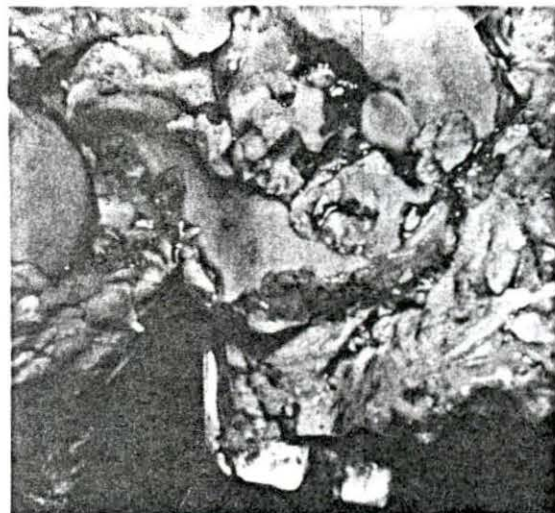
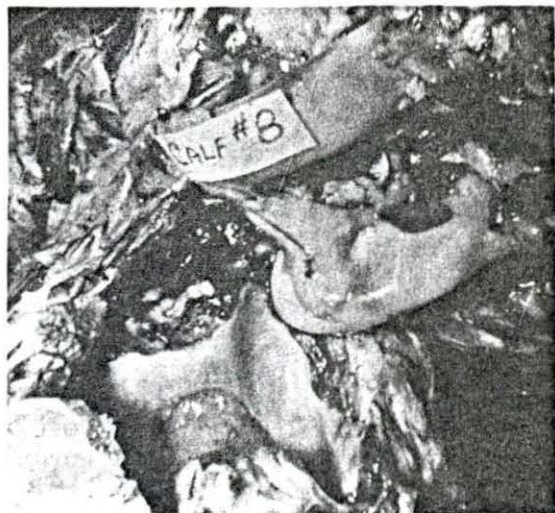
Table 18. Isolation of Mycoplasma sp. from calf No. 8

Isolation attempt	Time	Source	Visible growth on 3rd sub-culture	Organisms visible in 3rd subculture stains	MB ^a	TTC ^b	G ^c	SS ^d	Colony morphology ^e
8-1	preinoculation	nasal swab	fine, granular sediment	+	-	+	-	-	no growth
8-2	preinoculation	vaginal swab	-	-					
8-3	preinoculation	synovia	-	-					
8-4	inoculation	control inoculum tube	typical N-1	+	+	+	-	+	typical N-1
8-5	postinoculation	synovia	typical N-1	+	+	+	-	+	typical N-1

^aReduction of methylene blue.

^bReduction of 2,3,5-triphenyl-2H-tetrazolium chloride.

^cUtilization of glucose.

^dGrowth in semisolid B.H.I. medium.

^eColony morphology on solid B.H.I. medium.

Table 18. (Continued)

Isolation attempt	Time	Source	Visible growth on 3rd sub-culture	Organisms visible in 3rd subculture stains	Mg ^a	TTC ^b	G ^c	SS ^d	Colony morphology ^e
8-6	15 days PI ^f	nasal swab	-	-					
8-7	15 days PI	vaginal swab	typical N-1	+	+	+	-	+	typical N-1
8-8	15 days PI	pleural swab	-	-					
8-9	15 days PI	liver surface swab	-	-					
8-10	15 days PI	peri-cardium	-	-					
8-11	15 days PI	stifle swab	-	-					
8-12	15 days PI	left hock fibrin	typical	+	+	+	-	+	typical N-1

^fPostinoculation.

Table 18. (Continued)

Isolation attempt	Time	Source	Visible growth on 3rd sub-culture	Organisms visible in 3rd subculture stains	Mg ^a	TTC ^b	G ^c	SS ^d	Colony morphology ^e
8-13	15 days PI	left hock	typical N-1	+	+	+	-	+	typical N-1
8-14	15 days PI	tracheal swab	typical N-1	+	+	+	-	+	typical N-1
8-15	15 days PI	bronchial swab	-	-					
8-16	15 days PI	brain	-	-					
8-17	15 days PI	blood swab	-	-					
8-18	15 days PI	peri-cardial tag	typical N-1	+	+	+	-	+	typical N-1
8-19	15 days PI	kidney	-	-					
8-20	15 days PI	left popliteal lymph node	typical	+	+	+	-	+	typical N-1

Table 18. (Continued)

Isolation attempt	Time	Source	Visible growth on 3rd sub-culture	Organisms visible in 3rd subculture stains	Mg ^a	TTC ^b	G ^c	SS ^d	Colony morphology ^e
8-21	15 days PI	tonsil	-	-					
8-22	15 days PI	lung lesion	typical N-1	+	+	+	-	+	typical N-1
8-23	15 days PI	internal iliac lymph node	typical N-1	+	+	+	-	+	typical N-1
8-24	15 days PI	cerebrum	typical N-1	+	+	+	-	+	typical N-1
8-25	15 days PI	liver	-	-					
8-26	15 days PI	right	-	-					

inoculation vaginal swab was negative for Mycoplasma sp. Both the inoculation tube, theoretically containing sterile B.H.I. medium, and the eight day postinoculation synovia samples contained the N-1 isolate. This isolate was also recovered from the vagina, left hock, trachea, pericardium, left popliteal and internal iliac lymph nodes, the cerebrum and from the atelectic lesion of the lung.

d. Necropsy At necropsy a small area of atelectasis, 0.5 cm. by 1.0 cm., was observed in the dorsal portion of the right apical lobe of the lung. There was an excess of fluid in the bronchi and bronchioles throughout the ventral half of the lungs. The pericardial fluid was increased in amount and contained fibrin tags.

The left internal iliac and popliteal lymph nodes were enlarged and edematous. There was some enlargement of the tonsillar tissue. The inoculated hock showed marked periarticular fibrosis, marked hyperemia of the synovial membrane and an excessive amount of fibrin over most of the synovial surface. The synovial fluid was increased in amount, was pale yellow, contained numerous fibrin flakes and was without odor. The right hock was normal except for a small increase in normal synovial fluid. Subcutaneous hemorrhage was present over the anterior surface of the hock, presumably from trauma during synovial fluid collection on day eight.

Microscopic examination of sections of the lung lesion showed a peribronchiolar lymphoid hyperplasia with scattered areas of atelectasis and emphysema throughout the affected lobule. The left popliteal and internal iliac lymph nodes showed a serous lymphadenitis characterized by marked increase in reticular type cells and a moderate increase in macrophages and neutrophils.

The arthritis of the left hock was characterized by marked fibrosis of the joint capsule and synovial membrane. The synovial membrane was infiltrated with an infiltrate composed primarily of macrophages, lymphocytes and a few neutrophils. Focal accumulations of macrophages were located adjacent to blood vessels in the joint capsule. They were also in great abundance as a broad sheet under the synovial cell layer. Many of the capillaries in the fibrous tissue below the synovial membrane were damaged as was evidenced by the hyperchromatic, misshapen cells occluding their lumen. There was an inflammatory cell infiltration and fibrosis in the subchondral area, predominantly at the periarticular bone-cartilage junction. A mild osteomyelitis appeared to be starting at this periarticular junction. Periarticular new bone formation was present.

No microscopic lesions were observed in sections of the brain, tonsil or right hock.

9. Calves No. 9 and 10 (intraperitoneal and intra-articular inoculation with sterile B.H.I. medium)

a. Clinical manifestations Because these heifers were introduced into the isolation unit at the Veterinary Medical Research Institute concomitant with the onset of unseasonably hot weather, they both developed a few faint fluid râles in the anteroventral region of both apical lobes of their lungs before inoculation. The lungs, however, sounded normal on the day of inoculation and for the remainder of the experiment. No other clinical signs were observed in either calf (Figure 7). At no time did they show evidence of joint swelling or lameness.

b. Clinical pathology No abnormalities were noted in their hemograms (Tables 19 and 20). Pre-inoculation synovial fluid from both calves was identical to that aspirated from the other cattle before inoculation. The synovial fluid collected eight days postinoculation contained a few more mononuclear cells. The increase, however, was only minimal and no polymorphonuclear cells were observed from either calf.

c. Bacteriological examination The results of cultures taken from these two heifers appear in Tables 21 and 22 respectively. A granular organism unlike the N-1 isolated was isolated from the pre-inoculation vaginal swab of calf No. 9. No Mycoplasma spp., however, were isolated

Table 19. Hematological results of calf No. 9

Experi- mental day	Hemo- globin (mg. %)	Total white cell count	Lympho- cyte count	Segmented neutrophil count	Band cell count	Mono- cyte count	Eosin- ophil count
-16	12.9	12,950	68	22	8	1	1
-14	12.0	11,940	66	23	6	2	3
-12	12.0	6,400	60	26	10	3	1
-10	12.2	5,350	66	24	2	4	4
- 8	12.0	7,300	68	22	4	4	1
inoculation							
1	13.0	9,000	62	28	10	1	1
3	13.0	8,450	62	27	6	3	2
5	15.5	8,100	67	22	5	1	3
7	14.5	9,800	49	32	11	4	4
9	14.0	12,250	50	30	14	3	3
11	13.7	9,400	47	38	5	4	6

Table 20. Hematological results of calf No. 10

Experi- mental day	Hemo- globin (mg. %)	Total white cell count	Lympho- cyte count	Segmented neutrophil count	Band cell count	Mono- cyte count	Eosin- ophil count
-16	13.8	11,300	56	34	8	1	1
-14	13.2	10,100	56	32	6	3	3
-12	13.5	8,750	58	32	6	2	2
-10	13.2	10,650	66	22	5	5	2
- 8	14.2	10,950	59	32	5	5	0
inoculation							
1	14.0	11,800	56	34	8	1	1
3	14.0	11,300	56	23	11	4	6
5	16.0	8,200	61	27	6	4	1
7	13.5	10,300	56	32	10	1	1
9	13.0	11,800	48	30	10	8	4
11	14.5	8,300	36	38	14	5	7

Table 21. Bacteriological examination of calf No. 9

Isolation attempt	Time	Source	Visible growth on 3rd sub-culture	Organisms visible in 3rd subculture stains	MB ^a	TTC ^b	G ^c	SS ^d	Colony morphology ^e
9-1	preinoculation	nasal swab	-	-					
9-2	preinoculation	vaginal swab	fine, granular growth	+	culture lost when stored at -20 °C.				
9-3	inoculation	control inoculum tube	-	-					
9-4	50 days PI ^f	nasal swab	-	-					
9-5	50 days PI	vaginal swab	-	-					

^aReduction of methylene blue.

^bReduction of 2,3,5-triphenyl-2H-tetrazolium chloride.

^cUtilization of glucose.

^dGrowth in semisolid B.H.I. medium.

^eColony morphology on solid B.H.I. medium.

^fPostinoculation.

Table 21. (Continued)

Isolation attempt	Time	Source	Visible growth on 3rd sub-culture	Organisms visible in 3rd subculture stains	MB ^a	TTC ^b	G ^c	SS ^d	Colony morphology ^e
9-6	50 days PI	conjunctival swab	-	-					
9-7	50 days PI	oral swab	-	-					
9-8	50 days PI	pericardial swab	-	-					
9-9	50 days PI	pericardium	-	-					
9-10	50 days PI	left popliteal lymph node	-	-					
9-11	50 days PI	tonsil	-	-					
9-12	50 days PI	left hock	-	-					
9-13	50 days PI	left internal iliac lymph node	-	-					
9-14	50 days PI	lung							

Table 22. Bacteriological examination of calf No. 10

Isolation attempt	Time	Source	Visible growth on 3rd sub-culture	Organisms visible in 3rd subculture stains	MB ^a	TTC ^b	G ^c	SS ^d	Colony morphology ^e
10-1	preinoculation	nasal swab	-	-					
10-2	preinoculation	vaginal	-	-					
10-3	inoculation	control inoculum tube	-	-					
10-4	50 days PI ^f	nasal swab	-	-					
10-5	50 days PI	vaginal swab	-	-					

^aReduction of methylene blue.

^bReduction of 2,3,5-triphenyl-2H-tetrazolium chloride.

^cUtilization of glucose.

^dGrowth in semisolid B.H.I. medium.

^eColony morphology on solid B.H.I. medium.

^fPostinoculation.

Table 22. (Continued)

Isolation attempt	Time	Source	Visible growth on 3rd sub-culture	Organisms visible in 3rd subculture stains	MB ^a	TTC ^b	G ^c	SS ^d	Colony morphology ^e
10-6	50 days PI	conjunctival swab	-	-					
10-7	50 days PI	oral swab	-	-					
10-8	50 days PI	brain	-	-					
10-9	50 days PI	tonsil	-	-					
10-10	50 days PI	mesenteric lymph node	-	-					
10-11	50 days PI	left popliteal lymph node	-	-					
10-12	50 days PI	left hock	-	-					
10-13	50 days PI	cerebro-spinal fluid	-	-					
10-14	50 days PI	right coxo-femoral joint swab	-	-					

from the calves postinoculation.

d. Necropsy Both heifers showed focal areas of consolidation in the apical lobes of both lungs. Heifer No. 9 had 15 ml. of pericardial fluid. However, no fibrin tags were evident. No other lesions were observed at necropsy.

Microscopic examination of the affected lungs revealed healed lesions of mild bronchopneumonia. No other lesions were observed following microscopic examination of liver, kidney, spleen, articular cartilage of the left hock, lymph nodes, brain and lung.

L. Inoculation into laboratory animals

1. Rabbits, guinea pigs, mice and chickens
(inoculated with N-1 isolate or sterile B.H.I. medium)

a. Clinical manifestations No clinical signs were observed in any of the laboratory animals with the exception of guinea pig No. 2, injected intraperitoneally with N-1 isolate, which lost the use of both hind legs 12 days postinoculation. No swelling, heat or pain was observed in the affected limbs.

b. Necropsy No gross lesions were observed in any of the animals inoculated. Microscopic examination of sections of the hind limb of the guinea pig revealed no significant lesions.

II. Survey of Incidence of Mycoplasma sp. in CattleA. Field cases1. Field herd No. 1a. History and clinical manifestations A

group of 60 feeder steers, averaging 500 pounds, were shipped into Iowa by rail from Colorado. They were 3.5 days in transit, 24 hours of which was spent in the stock yards at Kansas City, Missouri. The calves were sampled for Mycoplasma sp. at the time they were vaccinated for infectious bovine rhinotracheitis and shipping fever two days after arrival. At that time they all appeared in good health.

Ten days following the vaccination, a severe outbreak of respiratory disease was diagnosed by the attending veterinarian as the shipping fever complex.

b. Bacteriological examination The

results of the swabs taken are indicated in Table 23. All isolates were lost during freezing at -20°C . or thawing. These organisms, isolated from nasal swabs, were characterized by a minimal smooth growth in B.H.I. medium.

2. Field herd No. 2a. History and clinical manifestations A

group of four hundred, 450 to 500 pound feeder cattle were shipped from Colorado to Iowa by railroad three weeks prior

Table 23. Results of sampling field herd No. 1 for Mycoplasma sp.

Isolation attempt	Clinical condition	Source	Visible growth on 3rd sub-culture	Organisms visible in 3rd subculture stains	MB ^a	TTC ^b	G ^c	SS ^d	Colony morphology ^e
H1-1	normal	nasal swab	minimal faint, smooth sediment	+					
H1-2	normal	nasal swab	-						
H1-3	normal	nasal swab	minimal smooth sediment	+	all cultures lost on freezing at -20° C. and thawing				
H1-4	normal	nasal swab	minimal smooth sediment	+					
H1-5	normal	nasal swab	minimal smooth sediment	+					

^aReduction of methylene blue.

^bReduction of 2,3,5-triphenyl-2H-tetrazolium chloride.

^cUtilization of glucose.

^dGrowth in semisolid B.H.I. medium.

^eColony morphology on solid B.H.I. medium.

Table 23. (Continued)

Isolation attempt	Clinical condition	Source	Visible growth on 3rd sub-culture	Organisms visible in 3rd subculture stains	MB ^a	TTC ^b	G ^c	SS ^d	Colony morphology ^e
H1-6	normal	nasal swab	minimal smooth sediment	+					
H1-7	normal	nasal swab	-	-					
H1-8	normal	nasal swab	-	-					
H1-9	normal	nasal swab	minimal smooth sediment	+					
H1-10	normal	nasal swab	minimal smooth sediment	+					

to being examined. Immediately following their arrival, respiratory symptoms, diagnosed by the attending veterinarian as part of the shipping fever complex, affected the majority of the herd. Thirty affected individuals were treated intravenously with Sulfamethazine¹ and various antibiotics but were slow to respond to treatment.

Examination of a representative sample of affected animals revealed rectal temperatures, heart rates and respiratory rates to be within normal ranges. Auscultation of the lungs revealed areas of consolidation in the ventral regions of the apical lobes and dry râles in the ventral portion of the remainder of the lungs. Of those affected with pneumonia, many were quite stiff while others were acutely lame on one or more legs. These latter animals showed no evidence of heat or swelling in or around affected articulations.

b. Bacteriological examination Results of material collected from this herd are given in Table 24. The Mycoplasma spp. isolated from five of the eight nasal swabs cultured were of two main types, those exhibiting a smooth sediment in B.H.I. medium and growth on B.H.I. solid medium and those appearing similar to the N-1 isolate.

¹ American Cyanamide, New York, New York.

Table 24. Results of sampling field herd No. 2 for Mycoplasma sp.

Isolation attempt	Clinical condition	Source	Visible growth on 3rd sub-culture	Organisms visible in 3rd subculture stains	MB ^a	TTC ^b	G ^c	SS ^d	Colony morphology ^e
H2-1	normal	nasal swab	smooth sediment	+	+	+	+	+	small, round and smooth at 6 days growth
H2-2	normal	vaginal swab	-	-					
H2-3	pneumonia and stiffness	nasal swab	-	-					
H2-4	pneumonia	nasal swab	-	-					
H2-5	pneumonia	vaginal swab	-	-					

^aReduction of methylene blue.

^bReduction of 2,3,5-triphenyl-2H-tetrazolium chloride.

^cUtilization of glucose.

^dGrowth in semisolid B.H.I. medium.

^eColony morphology on solid B.H.I. medium.

Table 24. (Continued)

Isolation attempt	Clinical condition	Source	Visible growth on 3rd sub-culture	Organisms visible in 3rd subculture stains	MB ^a	TTC ^b	G ^c	SS ^d	Colony morphology ^e
H2-6	pneumonia	nasal swab	typical N-1	+	+	+	-	+	typical N-1
H2-7	pneumonia	vaginal swab	-	-					
H2-8	pneumonia and lame	nasal swab	typical N-1	+	+	+	-	+	typical N-1
H2-9	pneumonia and lame	vaginal swab	-	-					
H2-10	stiffness	nasal swab	minimal smooth sediment	+	-	+	-	+	very small, round and smooth at 6 days growth
H2-11	stiffness	vaginal swab	-	-					
H2-12	stiffness	hock synovia	-	-					
H2-13	foot rot	nasal swab	-	+	culture lost on freezing				
H2-14	foot rot	vaginal swab	-	-					

Table 24. (Continued)

Isolation attempt	Clinical condition	Source	Visible growth on 3rd sub-culture	Organisms visible in 3rd subculture stains	MB ^a	TTC ^b	G ^c	SS ^d	Colony morphology ^e
H2-15	normal	nasal swab	-	-					
H2-16	normal	vaginal swab	-	-					

3. Field herd No. 3

a. History and clinical manifestations A group of finished feeder steers weighing between 1,000 and 1,200 pounds were visited following a report by the attending veterinarian that 30 out of a total of 152 head had become acutely lame the past four weeks. The larger steers would, according to the attending veterinarian, suddenly appear acutely lame on one or more limbs. Careful examination of affected joints revealed them to be swollen, hot and painful on palpation. Affected animals would not walk to the feed bunks to eat. No other clinical abnormalities were found. The affected steers improved enough to be marketed but were never able to walk in a sound manner.

b. Bacteriological examination Results from materials collected for culture are shown in Table 25. Two types of Mycoplasma spp. were isolated from this herd, those showing smooth sediment in B.H.I. medium and no growth in B.H.I. solid medium and those showing smooth growth in B.H.I. medium and small round reticular surfaced colonies on B.H.I. solid medium.

4. Field herd No. 4

a. History and clinical manifestations A group of 105 Hereford feedlot calves were shipped from Wyoming to Iowa late in the fall of the year. Upon arrival, a few animals showing signs of pneumonia were treated. They

Table 25. Results of sampling field herd No. 3 for Mycoplasma sp.

Isolation attempt	Clinical condition	Source	Visible growth on 3rd sub-culture	Organisms visible in 3rd subculture stains	MB ^a	TTC ^b	G ^c	SS ^d	Colony morphology ^e
H3-1	lame	nasal swab	-	+	-	-	-	-	no growth
H3-2	lame	hock synovia	-	-					
H3-3	normal	nasal swab	-	+	-	-	-	+	small, round colonies. Reticular surface. No elevation or depression
H3-4	normal	nasal swab	minimal smooth sediment	+	+	+	+	+	no growth

^aReduction of methylene blue.

^bReduction of 2,3,5-triphenyl-2H-tetrazolium chloride.

^cUtilization of glucose.

^dGrowth in semisolid B.H.I. medium.

^eColony morphology on solid B.H.I. medium.

Table 25. (Continued)

Isolation attempt	Clinical condition	Source	Visible growth on 3rd sub-culture	Organisms visible in 3rd subculture stains	MB ^a	TTC ^b	G ^c	SS ^d	Colony morphology ^e
H3-5	lame	hock synovia	-	-					
H3-6	lame	nasal swab	-	-					
H3-7	previously lame	nasal swab	minimal light, smooth sediment	+	<u>+</u>	+	-	+	same as isolate H3-3

responded. The cattle were then turned out on pasture. Two days later another outbreak of pneumonia occurred. When visited six weeks after their arrival, 80 percent of the group had been affected and five animals had died. On examination, most of the affected group exhibited a soft, moist cough. Severely affected animals had rectal temperatures between 105 and 107 °F. and were very depressed. On auscultation few râles were heard but sounds from the ventral third of the lungs suggested massive consolidation. All affected animals were treated orally and intraperitoneally with sulfas and intramuscularly with antibiotics. Limited response occurred.

b. Bacteriological examination Results of materials cultured from this herd are given in Table 26. Mycoplasma spp. characterized by a fine granular growth in B.H.I. medium and no growth on B.H.I. solid medium were the most common isolates from the nasal swabs of this herd.

5. Field herd No. 5

a. History and clinical manifestations On the day after arrival at the feedlot, a few of the 140 feeder calves, weighing 400 pounds, showed signs of pneumonia. The complete group was treated with Sulfamethazine¹ in the drinking water. A few of the more severely affected ones

¹American Cyanamide, New York, New York.

Table 26. Results of sampling field herd No. 4 for Mycoplasma sp.

Isolation attempt	Clinical condition	Source	Visible growth on 3rd sub-culture	Organisms visible in 3rd subculture stains	MB ^a	TTC ^b	G ^c	SS ^d	Colony morphology ^e
H4-1	pneumonia	nasal swab	minimal light, smooth sediment	+	<u>+</u>	+	-	+	small round colonies with reticular surface. No elevation or depression
H4-2	pneumonia	vaginal swab	-	-					
H4-3	pneumonia	nasal swab	very fine, granular sediment	+	-	+	-	-	no growth
H4-4	pneumonia	nasal swab	-	-					

^aReduction of methylene blue.

^bReduction of 2,3,5-triphenyl-2H-tetrazolium chloride.

^cUtilization of glucose.

^dGrowth in semisolid B.H.I. medium.

^eColony morphology on solid B.H.I. medium.

Table 26. (Continued)

Isolation attempt	Clinical condition	Source	Visible growth on 3rd sub-culture	Organisms visible in 3rd subculture stains	MB ^a	TTC ^b	G ^c	SS ^d	Colony morphology ^e
H4-5	pneumonia	nasal swab	very fine granular sediment	+	-	-	-	+ ^f	no growth
H4-6	pneumonia	vaginal swab	-	-					
H4-7	pneumonia	nasal swab	very fine granular sediment	+	-	-	-	-	no growth
H4-8	pneumonia	nasal swab	-	-					
H4-9	pneumonia	nasal swab	very fine granular sediment	+	-	-	-	+ ^f	no growth
H4-10	pneumonia	vaginal swab	-	-					
H4-11	pneumonia	nasal swab	-	-					
H4-12	pneumonia	vaginal swab	-	-					

^fVery fine reticular growth in top of tube.

were also treated intraperitoneally with the same drug. The complete group responded well to treatment. Ten days later some of the calves appeared acutely lame. Four days later about 25 calves were lame. Samples were taken for culture and examinations were made at this time. The calves appeared normal with the exception of the articular involvement. In a few cases, only one joint appeared to be involved. However, the majority showed evidence of polyarthritis. The tarsus and carpus were the joints most commonly involved but others such as the fetlock, elbow and stifle were occasionally affected. The affected joints were enlarged, hot and painful on palpation. Treatment with sulfonamides or antibiotics was of little value.

b. Bacteriological examination Results
from culture material collected from this herd are given in Table 27. Organisms showing similarity to the N-1 isolate were isolated only from the nasal cavities of this herd. Both granular and smooth sediment producing Mycoplasma spp. other than the N-1 isolate were also obtained from nasal cavities. No Mycoplasma sp. was isolated from affected synovial fluid.

6. Field herd No. 6

a. History and clinical manifestations The
500 pound feeder steers were brought onto the farm, turned into a corn stalk field and forgotten. One week later five

Table 27. Results of sampling field herd No. 5 for Mycoplasma sp.

Isolation attempt	Clinical condition	Source	Visible growth on 3rd sub-culture	Organisms visible in 3rd subculture stains	MB ^a	TTC ^b	G ^c	SS ^d	Colony morphology ^e
H5-1	poly-arthritis	nasal swab	typical N-1	+	+	+	-	+	typical N-1
H5-2	poly-arthritis	hock synovia	-	-					
H5-3	poly-arthritis	nasal swab	typical N-1	+	+	+	-	+	typical N-1 plus small smooth round colonies with no centers
H5-4	poly-arthritis	nasal swab	very fine, granular sediment	+	+	-	-	+ ^f	no growth

^aReduction of methylene blue.

^bReduction of 2,3,5-triphenyl-2H-tetrazolium chloride.

^cUtilization of glucose.

^dGrowth in semisolid B.H.I. medium.

^eColony morphology on solid B.H.I. medium.

^fFine reticular network in top of tube.

Table 27. (Continued)

Isolation attempt	Clinical condition	Source	Visible growth on 3rd sub-culture	Organisms visible in 3rd subculture stains	MB ^a	TTC ^b	G ^c	SS ^d	Colony morphology ^e
H5-5	poly-arthritis	carpus synovia	-	-					
H5-6	poly-arthritis	hock	-	-					
H5-7	poly-arthritis	nasal swab	-	-					
H5-8	poly-arthritis	nasal swab	typical N-1	+	+	+	-	+	typical N-1
H5-9	poly-arthritis	nasal swab	-	-					
H5-10	poly-arthritis	nasal swab	much smooth sediment	+	+	+	-	+	typical N-1 plus few small round smooth colonies without raised centers
H5-11	poly-arthritis	nasal swab	typical N-1	+	+	+	-	+	typical N-1

Table 27. (Continued)

Isolation attempt	Clinical condition	Source	Visible growth on 3rd sub-culture	Organisms visible in 3rd subculture stains	MB ^a	TTC ^b	G ^c	SS ^d	Colony morphology ^e
H5-12	poly-arthritis	nasal swab	typical N-1	+	-	+	-	+	typical N-1

steers died and six more were severely affected with pneumonia. Upon examination these calves exhibited a rectal temperature of 103 to 105 °F. and severe depression. On auscultation, fluid râles were heard over most of the lung area. These cattle responded slowly to treatment with antibiotics and sulfonamides.

b. Bacteriological examination Results
from the bacteriological examination are given in Table 28. Only two nasal swabs from this herd were positive for a Mycoplasma sp. exhibiting both a very fine granular sediment in B.H.I. medium and round reticular surfaced colonies on B.H.I. solid medium. No isolates typical of the N-1 isolate were obtained from this herd.

7. Field herd No. 7

a. History and clinical manifestations Two weeks after this group of 142 head of feeder calves had been brought to the feedlot by truck, signs of pneumonia began to appear. On examination, the calves had rectal temperatures between 103 and 105 °F., a soft moist cough, excessive salivation and lacrimation and a poor appetite. Few râles could be heard on auscultation but sounds indicating some degree of consolidation were heard in the ventral portions of all lungs examined. No other clinical signs were observed.

Table 28. Results of sampling field herd No. 6 for Mycoplasma sp.

Isolation attempt	Clinical condition	Source	Visible growth on 3rd sub-culture	Organisms visible in 3rd subculture stains	MB ^a	TTC ^b	G ^c	SS ^d	Colony morphology ^e
H6-1	pneumonia	nasal swab	-	-					
H6-2	pneumonia	nasal swab	-	-					
H6-3	pneumonia	nasal swab	-	-					
H6-4	pneumonia	nasal swab	very fine granular sediment	+	<u>+</u>	-	-	+	round, umbonate colonies with coarse reticular centers
H6-5	pneumonia	nasal swab	very fine granular sediment	+	<u>+</u>	-	+		same as isolate H6-4

^aReduction of methylene blue.

^bReduction of 2,3,5-triphenyl-2H-tetrazolium chloride.

^cUtilization of glucose.

^dGrowth in semisolid B.H.I. medium.

^eColony morphology on solid B.H.I. medium.

Table 28. (Continued)

Isolation attempt	Clinical condition	Source	Visible growth on 3rd sub-culture	Organisms visible in 3rd subculture stains	MB ^a	TTC ^b	G ^c	SS ^d	Colony morphology ^e
H6-6	pneumonia	nasal swab	-	-					
H6-7	normal	nasal swab	-	-					
H6-8	normal	nasal swab	-	-					
H6-9	normal	nasal swab	-	+	culture lost during freezing				

b. Bacteriological examination Results

from the examination of the swabs collected are given in Table 29. All swabs were found negative for Mycoplasma spp.

8. Field herd No. 8

a. History and clinical manifestations A

polled Hereford herd, under good management, continued to have outbreaks of acute arthritis in heifer and bull calves about nine months of age. The calves first developed diarrhea, a nasal discharge and mild joint swelling. Ten days after these initial signs, many became acutely lame. The affected articulations were hot, enlarged and very painful. No other clinical signs were observed.

b. Bacteriological examination Results

from culture material collected are given in Table 30. Because of inconclusive results on the third subculture stain, isolate H8-6 was inoculated into a swine kidney cell culture and a Mycoplasma sp., typical of the N-1 isolate, was recovered. All other samples were found negative for Myco-
plasma sp.

B. Miscellaneous cases

1. Miscellaneous isolations of Mycoplasma sp.

a. History and clinical manifestations The

steer from which the initial N-1 isolate had been obtained was readmitted to the Iowa State University Veterinary Clinic

Table 29. Results of sampling field herd No. 7 for Mycoplasma sp.

Isolation attempt	Clinical condition	Source	Visible growth on 3rd sub-culture	Organisms visible in 3rd subculture stains	MB ^a	TTC ^b	G ^c	SS ^d	Colony morphology ^e
H7-1	pneumonia	nasal swab	-	-					
H7-2	pneumonia	nasal swab	-	-					
H7-3	pneumonia	nasal swab	-	-					
H7-4	pneumonia	nasal swab	-	-					
H7-5	pneumonia	nasal swab	-	-					
H7-6	pneumonia	nasal swab	-	-					

^aReduction of methylene blue.

^bReduction of 2,3,5-triphenyl-2H-tetrazolium chloride.

^cUtilization of glucose.

^dGrowth in semisolid B.H.I. medium.

^eColony morphology on solid B.H.I. medium.

Table 30. Results of sampling field herd No. 8 for Mycoplasma sp.

Isolation attempt	Clinical condition	Source	Visible growth on 3rd sub-culture	Organisms visible in 3rd subculture stains	MB ^a	TTC ^b	G ^c	SS ^d	Colony morphology ^e
H8-1	lame	hock synovia	-	-					
H8-2	lame	hock synovia	-	-					
H8-3	lame	nasal swab	-	-					
H8-4	lame	oral swab	-	-					
H8-5	lame	nasal swab	+ ^f	+	+	+	-	+	typical N-1

^aReduction of methylene blue.

^bReduction of 2,3,5-triphenyl-2H-tetrazolium chloride.

^cUtilization of glucose.

^dGrowth in semisolid B.H.I. medium.

^eColony morphology on solid B.H.I. medium.

^fThird subculture inoculated into primary swine kidney cell cultures. A C.P.E. was noted after three days incubation. B.H.I. medium was inoculated from the cell culture tube and subsequent growth typical of the N-1 isolate occurred.

Table 30. (Continued)

Isolation attempt	Clinical condition	Source	Visible growth on 3rd sub-culture	Organisms visible in 3rd subculture stains	MB ^a	TTC ^b	G ^c	SS ^d	Colony morphology ^e
H8-6	lame	hock synovia	-	-					
H8-7	lame	nasal swab	-	-					
H8-8	lame	nasal swab	-	-					
H8-9	lame	nasal swab	-	-					

with a mild pneumonia and a severe unilateral hydrothorax from which it had partially recovered. Isolation No. H9-1 was obtained from five ml. of pleural effusion aspirated from the left thorax of the steer. The original N-1 isolate had been obtained four months previously from this same animal.

A fecal swab obtained from a month old Holstein calf resulted in isolation No. H9-2. This calf came from a herd where 90 percent of the calves in the herd had died from a severe polyserositis during the first ten days of life. A Mycoplasma sp. was isolated from pleural exudate of affected calves at necropsy but lost on subculture. The herd was then visited and nasal and fecal swabs taken of the five remaining calves. At this time all five calves appeared clinically normal. All swabs were negative for Mycoplasma sp. with the exception of No. H9-2.

Isolations No. H9-3 to H9-7 were made from the brain, meninges and visceral organs of a steer which died from a polyserositis. This was apparent clinically and was verified on necropsy.

b. Bacteriological examination Results
from culture material collected are shown in Table 31. The Mycoplasma sp. isolated from the thorax of steer No. H9-1 did not appear to be the same Mycoplasma sp. as the N-1 isolate obtained four months previously.

The Mycoplasma sp. isolated from the Holstein calf, H9-2, did not appear to be similar to Mycoplasma spp. isolated from other field herds.

An organism belonging to the genus Mycoplasma was isolated from all samples taken from the steer which died from a polyserositis. This organism grew in the first cultures and was positively identified by stained smears but failed to grow on subculture.

Table 31. Results of sampling miscellaneous cases for Mycoplasma sp.

Isolation attempt	Clinical condition	Source	Visible growth on 3rd sub-culture	Organisms visible in 3rd subculture stains	MB ^a	TTC ^b	G ^c	SS ^d	Colony morphology ^e
H9-1	hydro-thorax	pleural effusion	minimal granular sediment	+	+	+	-	+ ^f	no growth
H9-2	normal	fecal swab	moderate amount smooth sediment	+	+	+	+	+ ^g	no growth
H9-3	poly-serositis	meninges swab	very fine granular growth ^h	-					

^aReduction of methylene blue.

^bReduction of 2,3,5-triphenyl-2H-tetrazolium chloride.

^cUtilization of glucose.

^dGrowth in semisolid B.H.I. medium.

^eColony morphology on solid B.H.I. medium.

^fGrowth occurred in top eighth of tube.

^gVery fine growth only along stab.

^hGrowth in original culture only as indicated by examination of stained smears.

Table 31. (Continued)

Isolation attempt	Clinical condition	Source	Visible growth on 3rd sub-culture	Organisms visible in 3rd subculture stains	MB ^a	TTC ^b	G ^c	SS ^d	Colony morphology ^e
H9-4	poly-serositis	lung swab	very fine granular growth ^h	-					
H9-5	poly-serositis	peri-cardial swab	very fine granular growth ^h	-					
H9-6	poly-serositis	hock swab	very fine granular growth ^h	-					
H9-7	poly-serositis	lung swab	very fine granular growth ^h	-					

DISCUSSION

The Mycoplasma sp. isolated from the case of bovine arthritis and designated in this work as N-1 isolate grew abundantly in beef heart infusion medium. Its growth on solid medium, in methylene blue, in carbohydrates, in semi-solid medium and on solid medium containing horse red blood cells indicates a marked similarity to that of the P strains described by Edward (11). Edward did not mention the occurrence of a pellicle on the surface of his fluid cultures and describes growth of the organisms in fluid media as smooth rather than granular. It must be noted, however, that Edward grew his P strains in a medium much different from that used for the N-1 isolate. Photographs of the P strains reported by Edward (11) indicate too, a similarity in morphology between the N-1 isolate and the P strains, especially the presence of the large globoid bodies at 72 hours growth. The surface film and description of the black dots on the solid medium also indicate similarity. Serological tests would be required, however, before the N-1 isolate could be included with Edward's P strains which have been named Mycoplasma bovigenitalium.

Reports of bovine arthritis in which Mycoplasma spp. have been indicated as the etiological agent seldom indicate many of the isolated organism's characteristics. Thus,

comparisons are precluded. Moulton et al. (23), however, indicated that the Mycoplasma sp. which they isolated from an arthritic calf fermented dextrin, dextrose, mannitol, galactose and maltose, a characteristic not found with the N-1 isolate.

The Mycoplasma sp., isolated from the experimental calves and from the field herds, which grew with a smooth sediment in B.H.I. medium and did not show visible growth on B.H.I. solid medium resembles the Mycoplasma sp. reported by Hudson and Etheridge (18). Their isolate, obtained from the nasal cavities of cattle in Australia, was not related to Mycoplasma mycoides.

Production, under experimental conditions, of a natural infection with organisms of the genus Mycoplasma is difficult (21). Too, use of conditions to produce a measurable or reproducible amount of stress on a group of animals in order to aid in bringing about this natural infection is also difficult. The stress conditions employed in this experiment did not appear to alter the heifers' susceptibility to the Mycoplasma sp. (N-1 isolate) inoculated even though the electric barbed wire fence kept the heifers restless and on their feet. Possibly, a longer stress period would have more closely approximated the stress feedlot cattle receive in transit and would have lowered the resistance of the experimental heifers to a greater degree.

It is apparent from the bacteriological examination of calves No. 2 and 8 that the control inoculum tubes containing the sterile B.H.I. medium also contained the N-1 isolate after inoculation of the calves. Contamination of the inoculum tubes probably occurred when the long needles used to aspirate medium from the culture tubes became mixed up during the inoculation procedures and needles used to aspirate material containing the N-1 isolate were also used to aspirate the control media. The presence of the N-1 isolate in the eight day postinoculation synovial fluid of these two calves lends support to this theory. After the discovery of infection in both control calves, two more calves were purchased from the same source. Since the Mycoplasma sp. N-1 was isolated from the trachea of calf No. 8, it was decided to house the latter two control animals in a separate isolation unit.

There were a number of isolations of Mycoplasma spp. other than the N-1 isolate from the experimental cattle during the trial. These fell into three main groups: (a) those exhibiting smooth growth in B.H.I. medium and no visible growth on B.H.I. solid medium, (b) those with a fine smooth sediment in B.H.I. medium and growth on B.H.I. solid medium and (c) those exhibiting granular growth in B.H.I. medium and growth on B.H.I. solid medium. The first group includes the nasal swabs of calves No. 3, 4, 5, 6 and

8, the second includes the nasal and conjunctival swabs of calf No. 3 and the third, the oral swab of calf No. 6 and the vaginal swab of calf No. 9. It is suggested that these organisms are part of the normal flora of the nasal, vaginal and oral cavities of feeder age cattle. This theory is borne out in the isolation results of the survey where many organisms roughly fitting into these three groups were isolated.

Work with swine indicates that Mycoplasma hyorhinitis, isolated from the nasal cavity of swine, often causes a serious polyserositis when inoculated intraperitoneally into that species. Thus further research regarding the Mycoplasma sp. isolated from cattle is required to determine their true significance.

Those Mycoplasma spp. other than N-1 occurring in pre-inoculation swabs and not postinoculation swabs or vice versa may be explained by the fact that either they were present earlier and not cultured or, secondly, that they were in the air as an aerosol from one source calf and in the confined area other calves became infected.

The intra-articular route of inoculation of the N-1 isolate was the only route in which gross lesions and clinical signs were produced. Considering the post-inoculation isolation of the N-1 isolate from the soft palate and the mild serous mesenteric lymphadenitis of intra-

peritoneally inoculated calf No. 3, the intraperitoneal inoculation appears to be of some value. Perhaps this route of inoculation would be more satisfactory if adequate stress were applied. Intravenous inoculation was found to be unsatisfactory under the conditions of this experiment.

Laboratory animals were found to be of little value as diagnostic tools regarding the Mycoplasma sp. N-1.

The arthritic lesions found in calf No. 8 at 15 days postinoculation were of a fibrino-purulent nature while the lesions found in calves necropsied 37 days or more postinoculation were of a more fibrinous character. This finding agrees with cases of Mycoplasma arthritis reported in goats (9), in calves (27) and in some swine (22, 26). Lymphatic lesions found at necropsy in the experimental calves indicate that the organism was probably carried by the lymphatics. Clinical observations of hyperthermia, anorexia and depression in most of the experimental calves as well as the variety of tissues from which the organism was isolated, especially from calf No. 8, indicate that the Mycoplasma sp. N-1 probably went through a septicemia phase in some of the inoculated calves.

Simmons and Johnston (27) report that there is a long interval of time during which Mycoplasma sp. may be isolated from an infected joint. In the above experimental calves, however, some of the intra-articularly infected

joints appeared to be free of the organism by 50 days postinoculation.

The occurrence of fluid râles in those calves which exhibited hyperthermia, anorexia and depression suggests that perhaps the pneumonia often observed in conjunction with field cases of arthritis might have a more intimate association with the arthritis than just another stress factor.

Mycoplasma sp. have been isolated from sheep pneumonia (9) along with a virus, and are believed to be significant in the etiology of ovine pneumonias. Hamdy et al. (17) also suggest a possible association of Mycoplasma spp. with bovine pneumonia.

SUMMARY AND CONCLUSIONS

1. The Mycoplasma sp. N-1 isolated from the synovial fluid of a feeder age steer affected with severe arthritis grew as a circular umbonate colony on beef heart infusion solid medium. It exhibited a heavy granular sediment, a delicate pellicle and reduced methylene blue and 2,3,5-triphenyl-2H-tetrazolium chloride in beef heart infusion medium. Growth in semisolid medium was throughout the length of the stab. The organism grew in the presence of 1:500 concentration of thallos acetate and 1,000 I.U. of penicillin per ml. The organism passed a Selas 02 filter.

2. Experimental inoculation of the Mycoplasma sp. N-1 into eight approximately 400 pound Hereford heifer calves produced a serofibrinous arthritis when inoculated intra-articularly, a mild serous lymphadenitis of the mesenteric lymph nodes on intraperitoneal inoculation and no observable lesions on intravenous inoculation. The majority of the calves exhibited hyperthermia, depression and anorexia seven to ten days postinoculation and mild periodic fluid râles 10 to 20 days postinoculation. The organism produced no lesions in experimental rabbits, mice, guinea pigs or chickens following intraperitoneal and intramuscular inoculation.

3. Numerous isolations of Mycoplasma spp. were made

from nasal swabs of feeder age cattle in the field. A number of these isolations appeared to be similar to the Mycoplasma sp. N-1 isolated from the arthritis steer.

4. Growth of the N-1 isolate in beef heart infusion medium, beef heart infusion solid medium, and beef heart infusion medium containing methylene blue indicates a marked similarity of this organism to Mycoplasma bovigenitalium.

REFERENCES CITED

1. Adler, H.C. Arthritis in chicks caused by a Mycoplasma. *Lab. Investigation* 8: 1394-1405. 1959.
2. Bakos, K., Ban, A. and Thal, E. Mycoplasmen (PPLO) in Beziehung zur Fruchtbarkeit bei Bullen. *Zentralblatt für Veterinärmedizin* 9: 397-410. 1962.
3. Benjamin, M.M. Outline of veterinary pathology. 2nd ed. Ames, Iowa. The Iowa State University Press. 1961.
4. Boidin, A.G., Cordy, D.R. and Adler, H.E. A pleuropneumonia-like organism and a virus in ovine pneumonia in California. *Cornell Vet.* 47: 410-430. 1958.
5. Borrel (initials not given), Dujardin-Beaumetz (initials not given), Jeantet (initials not given) and Jovan (initials not given). *Le microbe de la péripneumonie. Annales L'Institut Pasteur* 24: 168-179. 1910.
6. Carter, G.R. Pleuropneumonia-like organisms isolated from bronchopneumonia of cattle. *Science* 120: 113. 1954.
7. Carter, G.R. and McSherry, B.J. Further observations on shipping fever in Canada. *Can. J. Comp. Med. and Vet. Sci.* 19: 177-181. 1955.
8. Cordy, D.R. Arthritis in ruminants due to pleuropneumonia-like organisms. *Lab. Investigation* 8: 1432-1433. 1959.
9. Cordy, D.R., Adler, H.E. and Yamamoto, R. A pathogenic pleuropneumonia-like organism from goats. *Cornell Vet.* 45: 50-68. 1955.
10. Edward, D.G. ff. A selective medium for pleuropneumonia-like organisms. *J. Gen. Microbiol.* 1: 238-243. 1947.
11. Edward, D.G. ff. An investigation of pleuropneumonia-like organisms isolated from the bovine genital tract. *J. Gen. Microbiol.* 4: 4-15. 1950.

12. Edward, D.G. ff. An investigation of the biological properties of organisms of the pleuropneumonia group, with suggestions regarding the identification of strains. *J. Gen. Microbiol.* 4: 311-329. 1950.
13. Edward, D.G. ff. The pleuropneumonia group of organisms: a review, together with some new observations. *J. Gen. Microbiol.* 10: 27-64. 1954.
14. Edward, D.G. ff., Hancock, J.L. and Hignett, S.L. Isolation of pleuropneumonia-like organisms from the bovine genital tract. *Vet. Rec.* 59: 329-330. 1947.
15. Freundt, E.A. *Mycoplasmatales Freundt.* 1955. In Breed, R.S., Murray, E.G.D. and Smith, N.R., eds. *Bergey's manual of determinative bacteriology.* pp. 914-926. Baltimore, Maryland. The Williams and Wilkins Company. 1957.
16. Hale, H.H., Helmbolt, C.F., Plastringe, W.N. and Stula, E.F. Bovine mastitis caused by a *Mycoplasma* species. *Cornell Vet.* 52: 582-591. 1962.
17. Hamdy, A.H., Gale, C. and King, N.B. Studies on shipping fever of cattle. II. Isolation of pleuropneumonia-like organisms. *Amer. J. Vet. Res.* 19: 818-821. 1951.
18. Hudson, J.R. and Etheridge, J.R. A new type of pleuropneumonia-like organism (PPL0) from the nose of cattle. *Aust. Vet. J.* 39: 1-5. 1963.
19. Jordon, G.V., Jr. Cleaning fluids by means of ceramic filter media. *Mech. Eng.* 24: 559-563. 1953.
20. Kingrey, B.W. Stiffness and lameness of cattle. *Rocky Mountain Vet.* 8: 32-40. 1960.
21. Klieneberger, N.E. Microorganisms of the pleuropneumonia group. *Biol. Rev.* 29: 154-160. 1960.
22. McNutt, S.H. Swine arthritis associated with pleuropneumonia-like organisms (PPL0). *Lab. Investigation* 8: 1427-1431. 1959.
23. Moulton, J.E., Boidin, A.G. and Rhode, E.A. A pathogenic pleuropneumonia-like organism from a calf. *J. Amer. Vet. Med. Assoc.* 129: 364-367. 1956.

24. Nocard (initials not given) and Roux (initials not given). Le microbe de la péripneumonie. Annales L'Institut Pasteur 24: 168-179. 1910.
25. Olson, N.O., Seymour, W.R., Boothe, A.D. and Doza, L. Characteristics of PPL0 isolated from the genital and respiratory tracts of cattle. N.Y. Academy of Science Annals. 79: 677-685. 1960.
26. Roberts, E.D., Switzer, W.P. and Ramsey, F.K. The pathology of Mycoplasma hyorhinis arthritis produced experimentally in swine. Amer. J. Vet. Res. 24: 19-31. 1963.
27. Simmons, G.C. and Johnston, L.A.Y. Arthritis in calves caused by Mycoplasma sp. Aust. Vet. J. 39: 11-14. 1963.
28. Somerson, N.L. and Morton, H.E. Reduction of tetrazolium salts by pleuropneumonia-like organisms. J. Bact. 65: 245-251. 1953.
29. Stuart, P., Davidson, I., Slavin, G., Edgson, F.A. and Howell, D. Bovine mastitis caused by Mycoplasma. Vet. Rec. 75: 59-64. 1963.
30. Switzer, W.P. Studies on infectious atrophic rhinitis of swine. II. Intraperitoneal and intranasal inoculation of young pigs with a filterable agent isolated from nasal mucosa of swine. Vet. Med. 48: 392-394. 1953.
31. Switzer, W.P. Studies on infectious atrophic rhinitis. IV. Characterization of a pleuropneumonia-like organism isolated from the nasal cavities of swine. Amer. J. Vet. Res. 16: 540-544. 1955.
32. Switzer, W.P. Action of certain viruses, Mycoplasma hyorhinis, and nasal trichomonads on swine tissue culture. Amer. J. Vet. Res. 20: 1010-1019. 1959.
33. Turner, A.W. and Trethewie, E.R. Preventive tail-tip inoculation of calves against bovine contagious pleuropneumonia. Aust. Vet. J. 37: 1-8. 1961.
34. Villemont, J.M. and Provost, A. Recherches immunologiques sur la péripneumonie. III. Isolement au tchad de PPL0 génitaux d'origine bovine. Revue D'Élevage et de Médecine Veterinaire des Pays Tropicaux 12, No. 4: 5-10. 1959.

35. Ward, J.R. and Jones, R.S. The pathogenesis of mycoplasmal (PPLO) arthritis in rats. *Arthritis and Rheumatism* 5: 163-175. 1962.

ACKNOWLEDGMENTS

The guidance and co-operation of many people contributed to this manuscript. The author sincerely wishes to thank Dr. W. P. Switzer for his guidance throughout the course of these experiments and the preparation of this thesis. Thanks are also extended to Drs. B. W. Kingrey, R. F. Bristol, F. K. Ramsey and R. Getty for their interest and co-operation.

The author wishes to express his appreciation to Dr. E. D. Roberts for his aid and advice regarding the pathology section of this thesis. Aid in management of the experimental cattle by Dr. D. Schickel is gratefully acknowledged.

Thanks are extended to Corn States Laboratories, Inc., Omaha, Nebraska, for their interest and financial support of this work.

The co-operation and aid given by the personnel of the Department of Veterinary Pathology, Iowa State University, and Iowa State University Veterinary Medical Research Institute are gratefully acknowledged.

The author wishes to thank his wife, Lynn, without whose encouragement, suggestions and aid this thesis would not be possible.